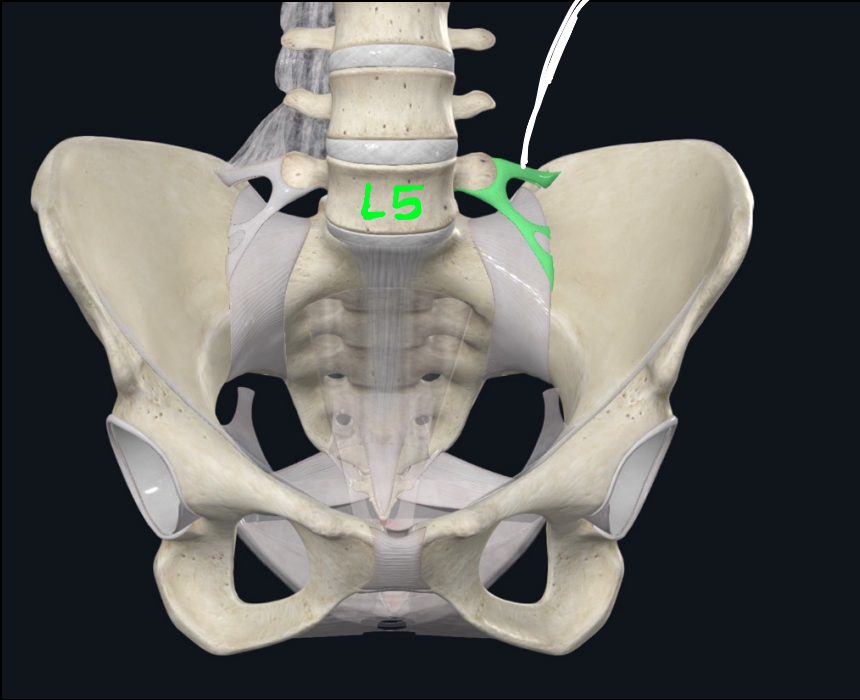


vertebropelvic ligaments

①

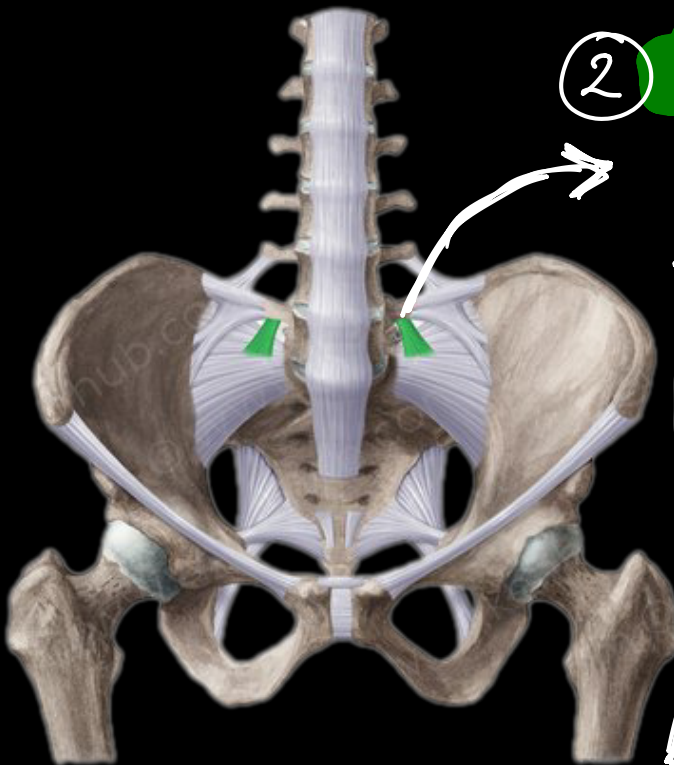
iliolumbar ligament



from L5 transverse process to the iliac crest

②

lumbosacral ligament

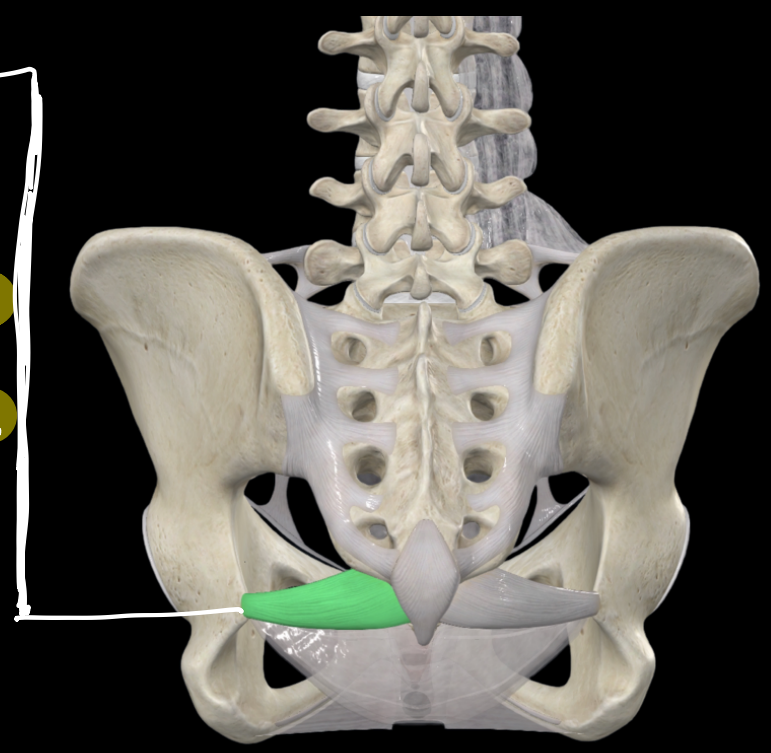


from the inferior aspect of L5 transverse process to the lateral part of the ala of sacrum

③ sacro spinous

ligament :-

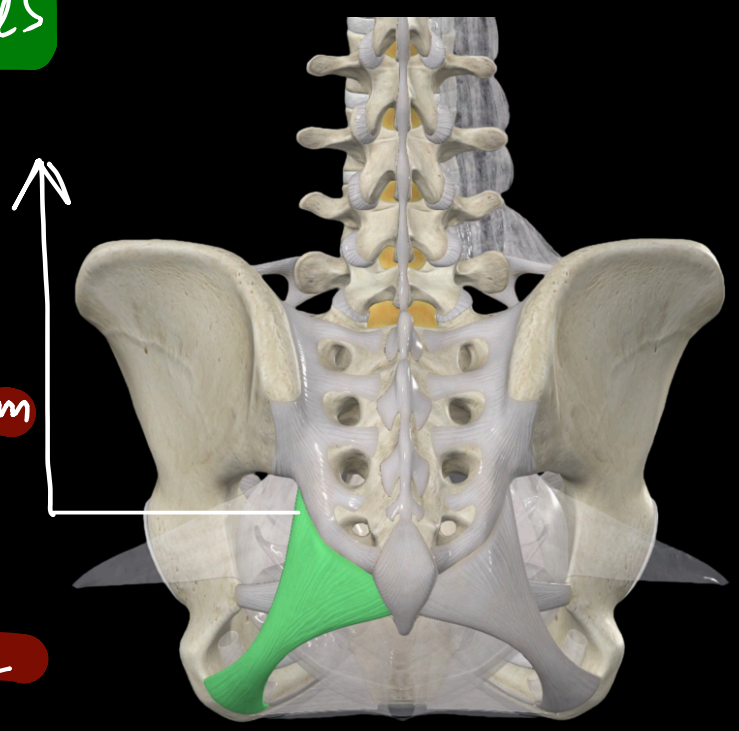
from ischial spine
to the lateral margins
of sacrum and
coccyx

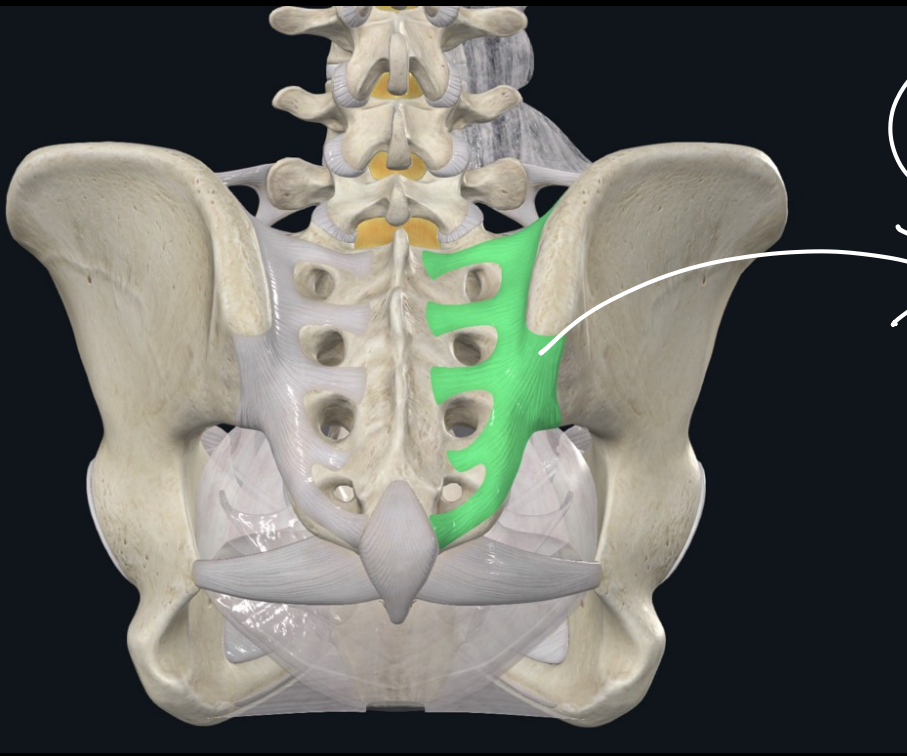


④ sacro tuberosus

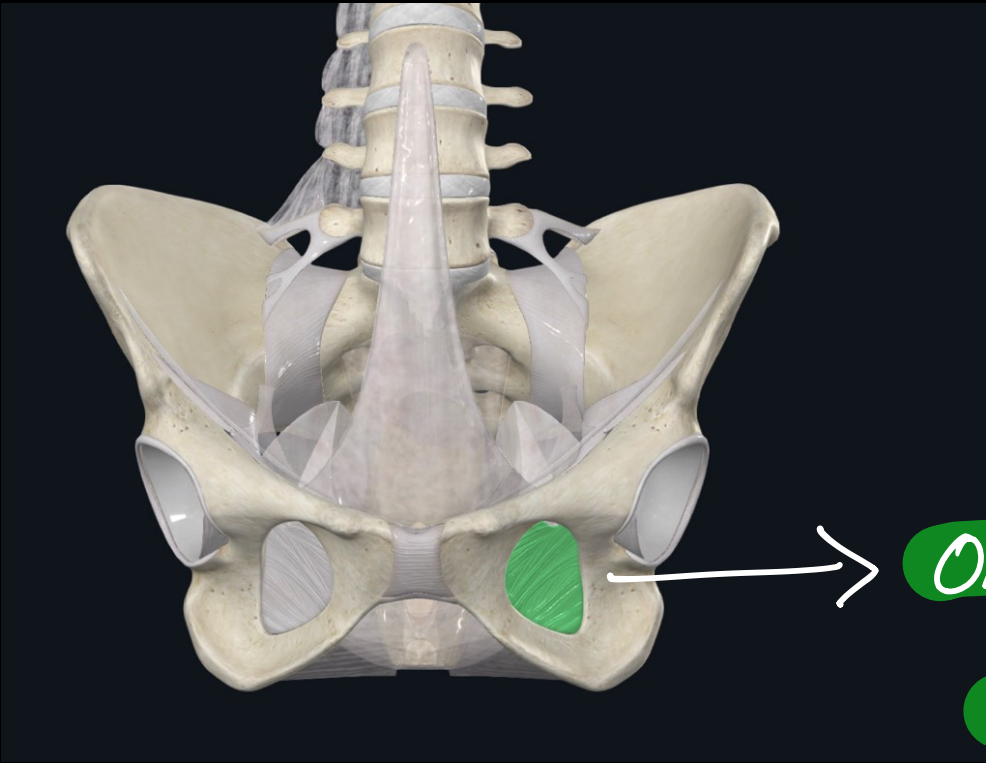
ligament :-

posterior iliac spine,
lower part of the sacrum
and coccyx and
ischial tuberosity



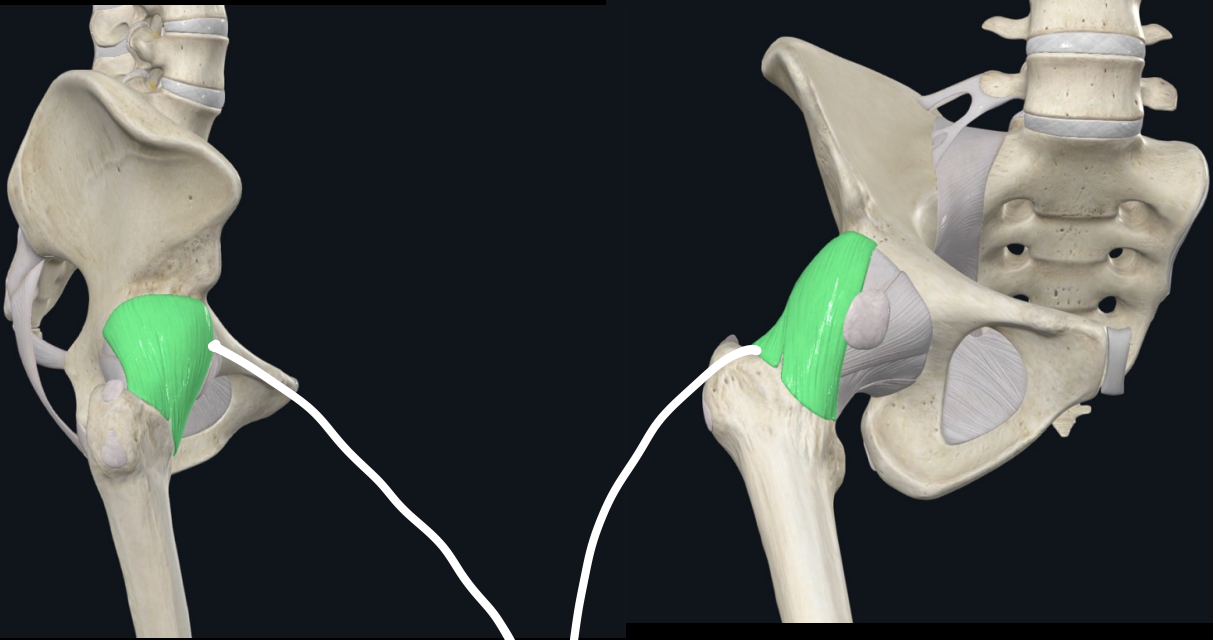


⑤ Sacrospinous
ligaments
(Interosseous)

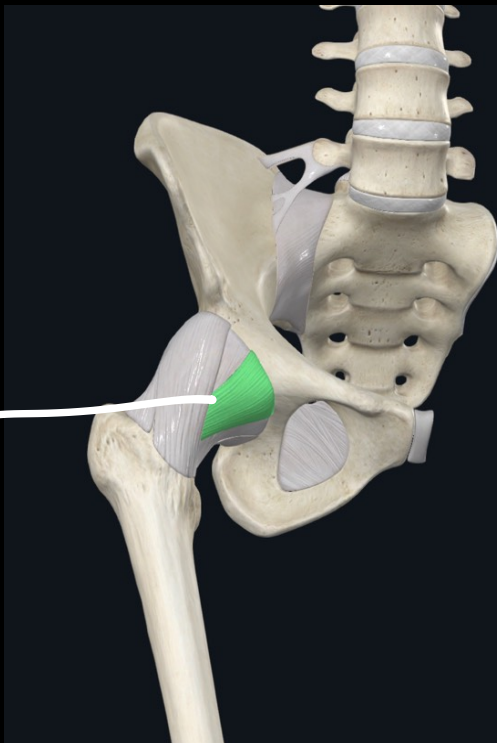


obturator-foramen
membrane

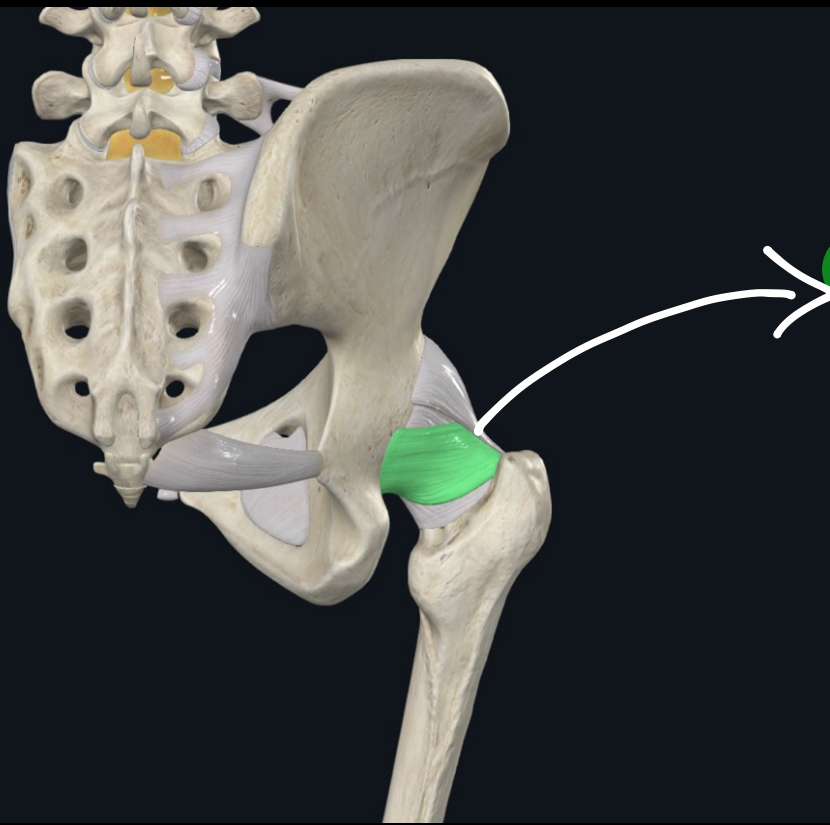
Hip joint ligaments



1 Iliofemoral ligament

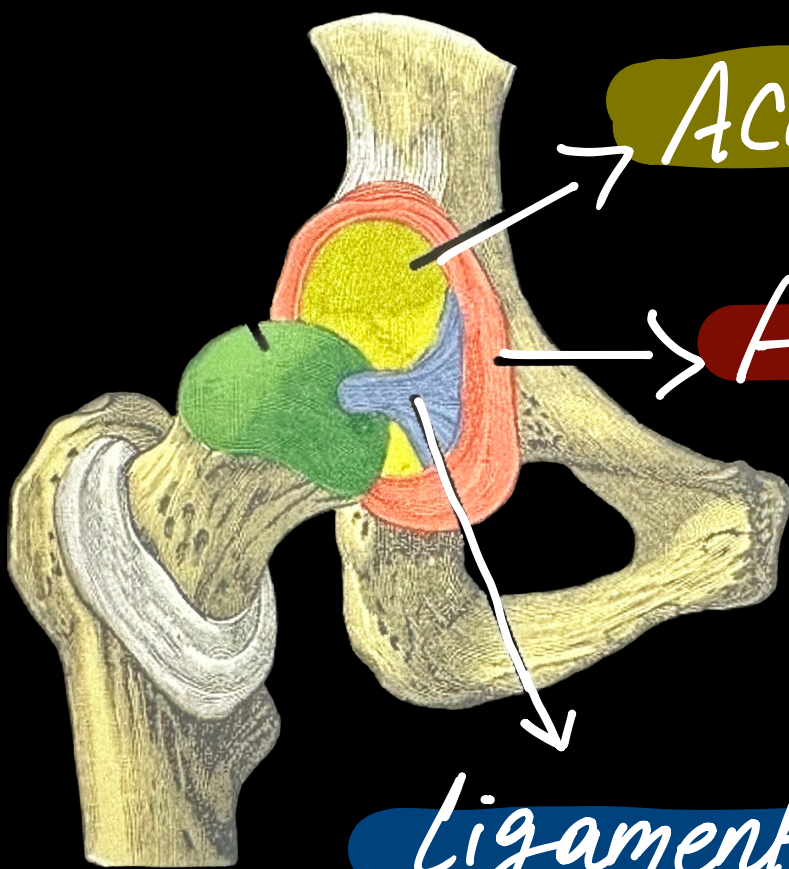


2 pubofemoral ligament



(3)

Ischiofemoral
ligament



Acetabulum

Acetabular
labrum

(4)

Ligament of the
head of the femur

