

The University Of Jordan
Faculty Of Medicine
Anatomy Department

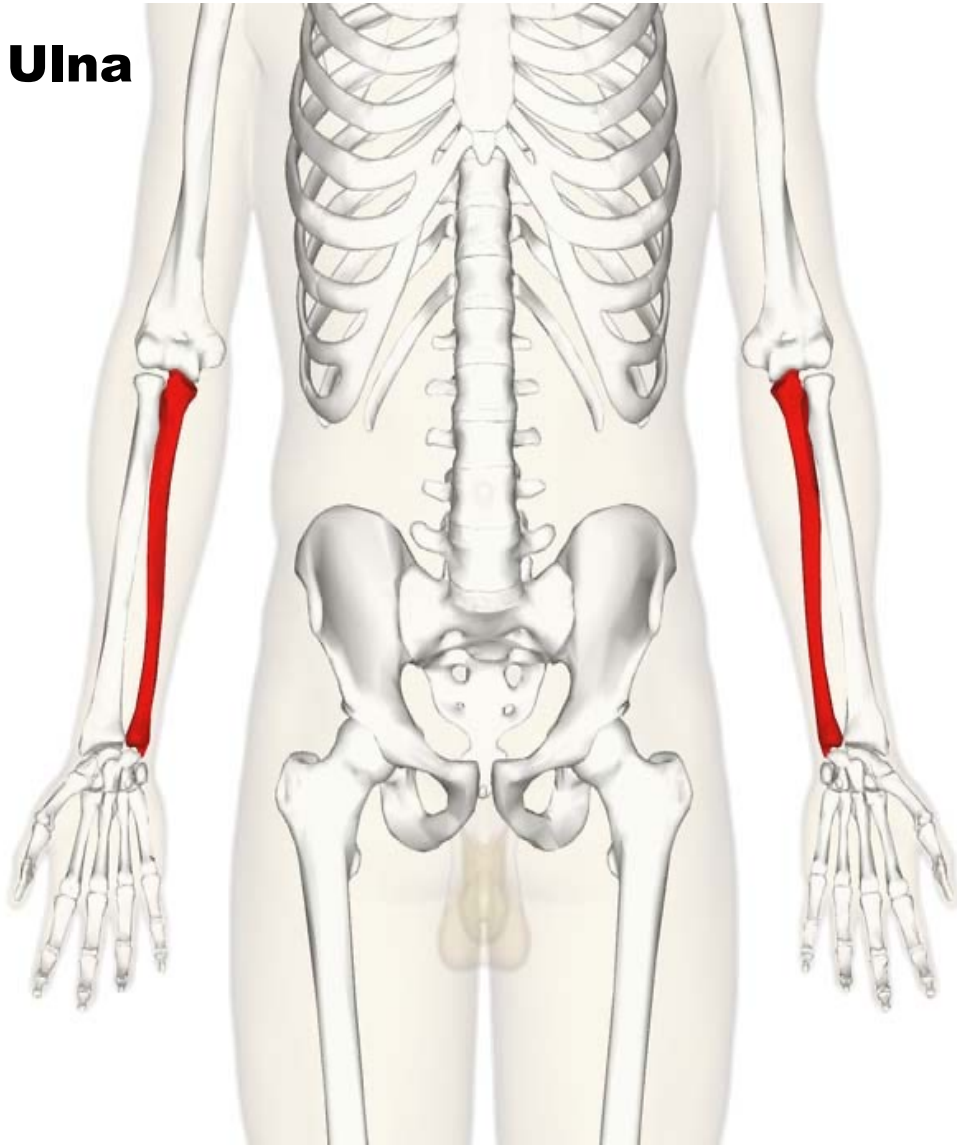


Ulna ,Radius and bones of the hand

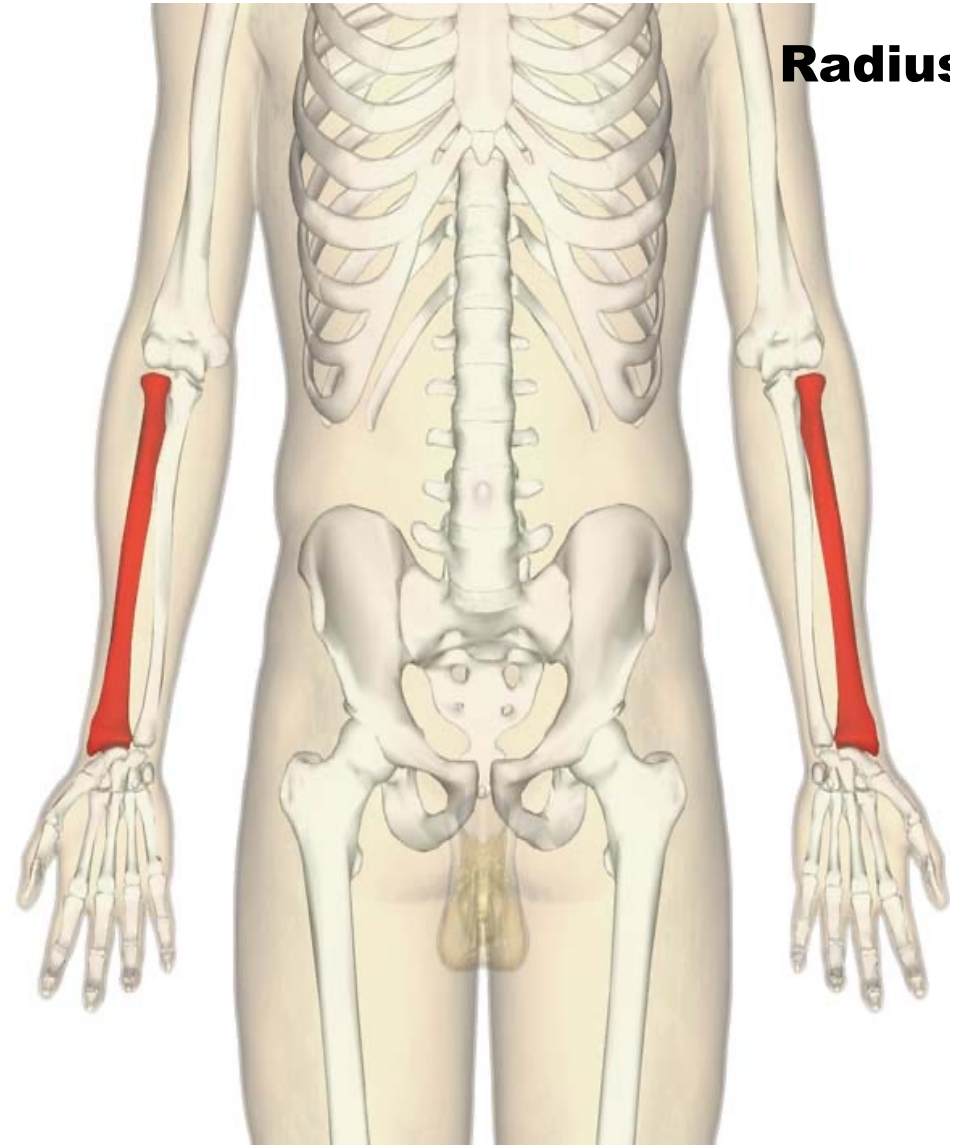
Dr.Ahmed Salman

Associate Prof. of Anatomy. The University Of Jordan

Ulna



Radius



Ulna:

★ It is a long bone forming the medial bone of forearm ,it has:

I) Upper end: consists of

A.2 processes (olecranon & coronoid.)

B. Trochlear fossa

C. Ulnar tuberosity

D. Radial notch .

II) Shaft: has

A. Three surfaces (anterior, posterior & medial surfaces)

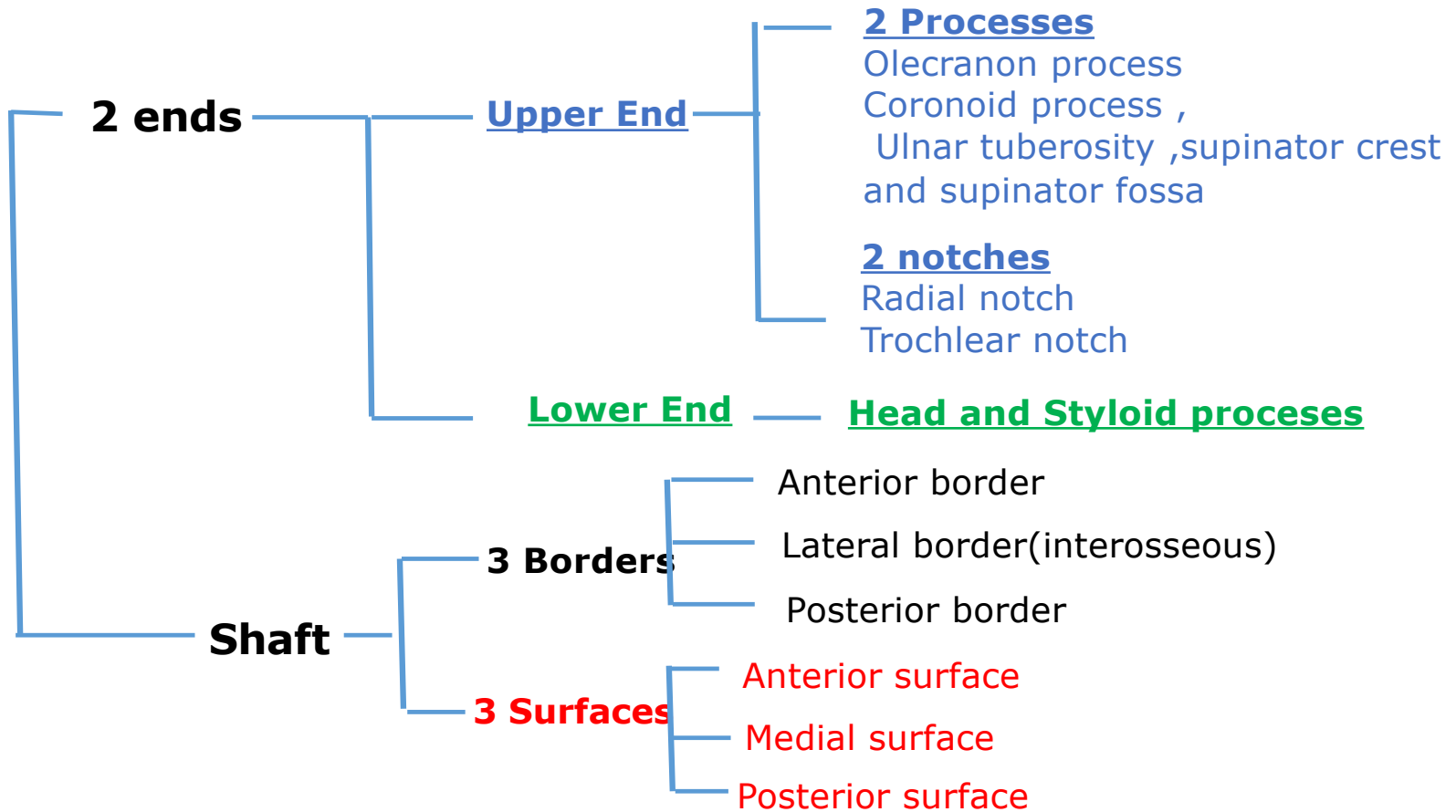
B. Three borders (anterior , posterior & lateral or interosseous borders)

III) Lower end: consists of

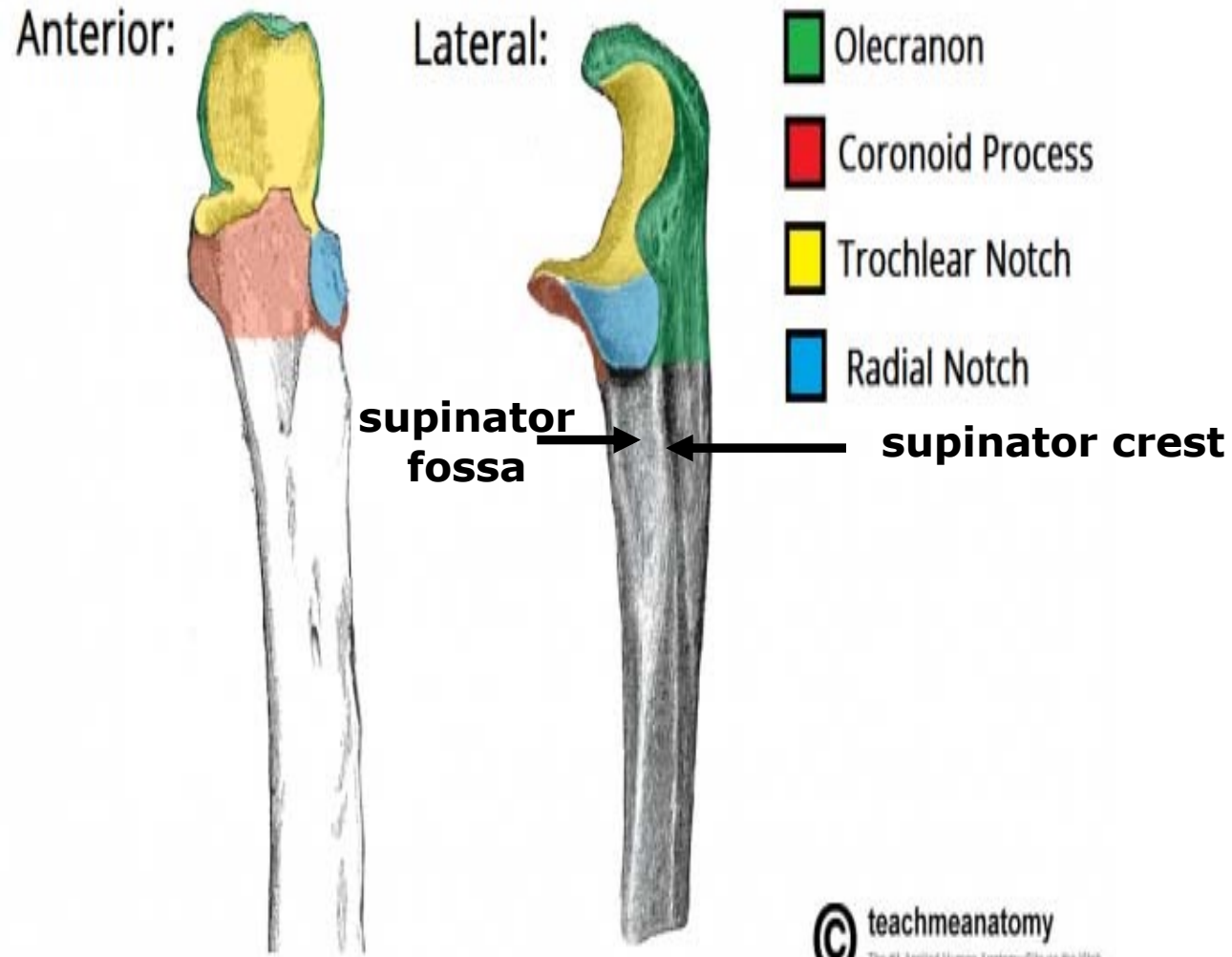
A. Head

B. Styloid process (which is shorter than styloid process of radius).

Ulna



Ulna



Radius:

★ It is a **long bone** forming the **lateral bone of forearm** ,it has:

I) Upper end: Consists of

A. Head , which has 2 **articular surfaces** (upper surface & its circumference)

B. Neck

C. Radial tuberosity

II) Shaft: it has

A. Three borders (anterior, posterior & medial borders or interosseous)

B. Three surfaces (anterior, posterior & lateral)

III) Lower end: It has **5 surfaces**

A. Anterior (smooth) rough

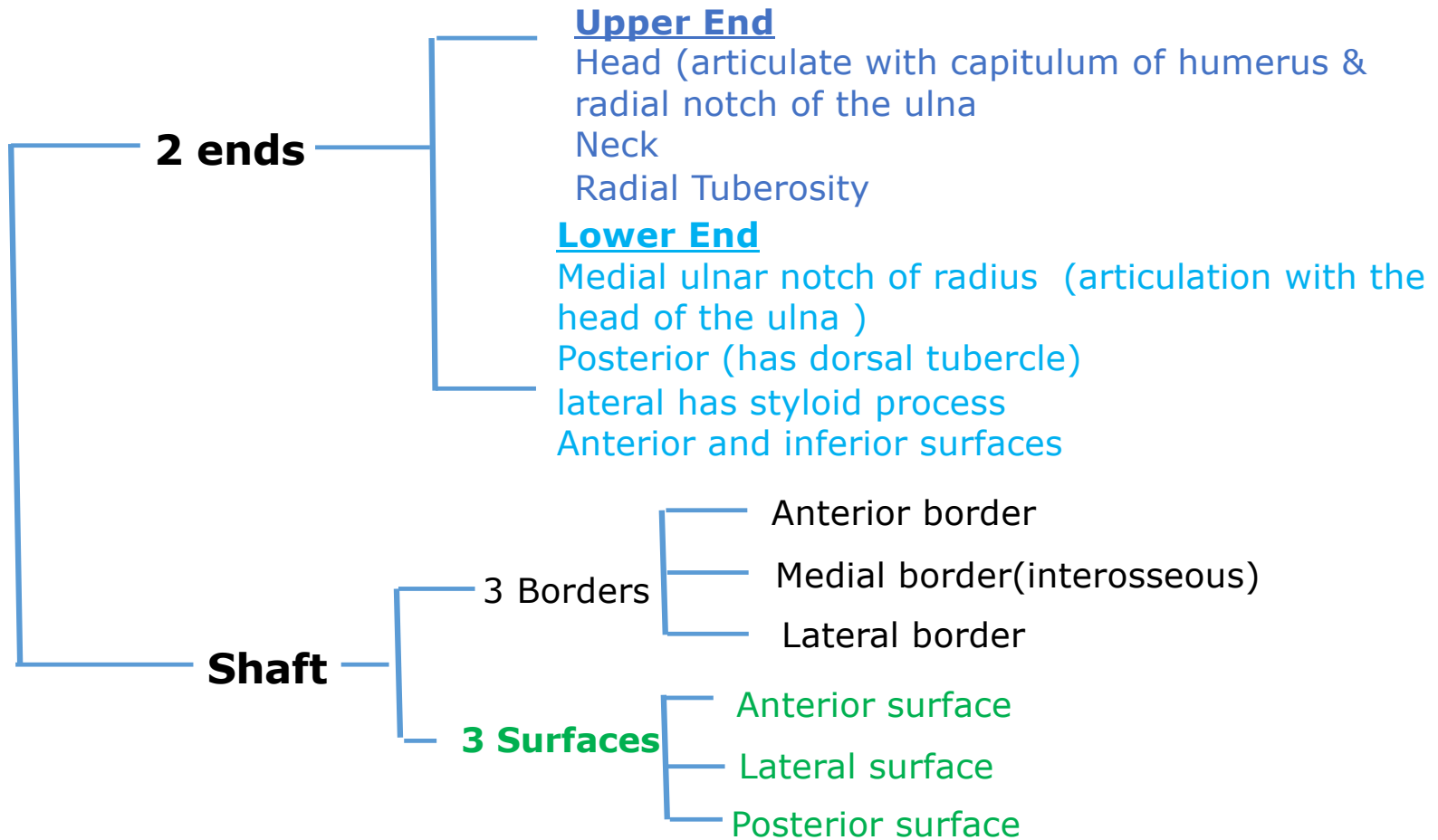
B. Posterior ,it has **dorsal tubercle**

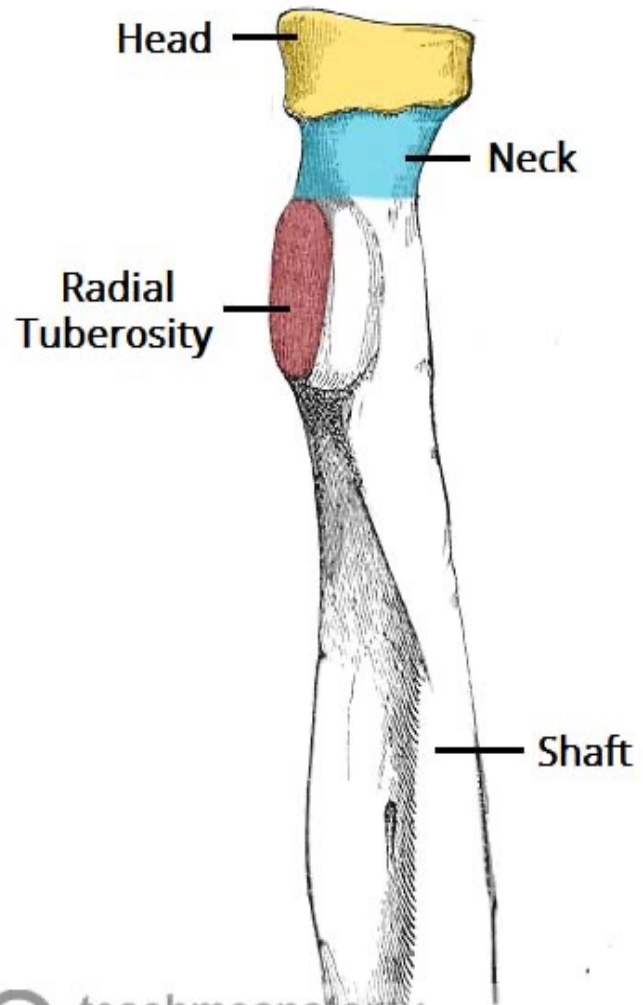
C. Lateral shows **styloid process**

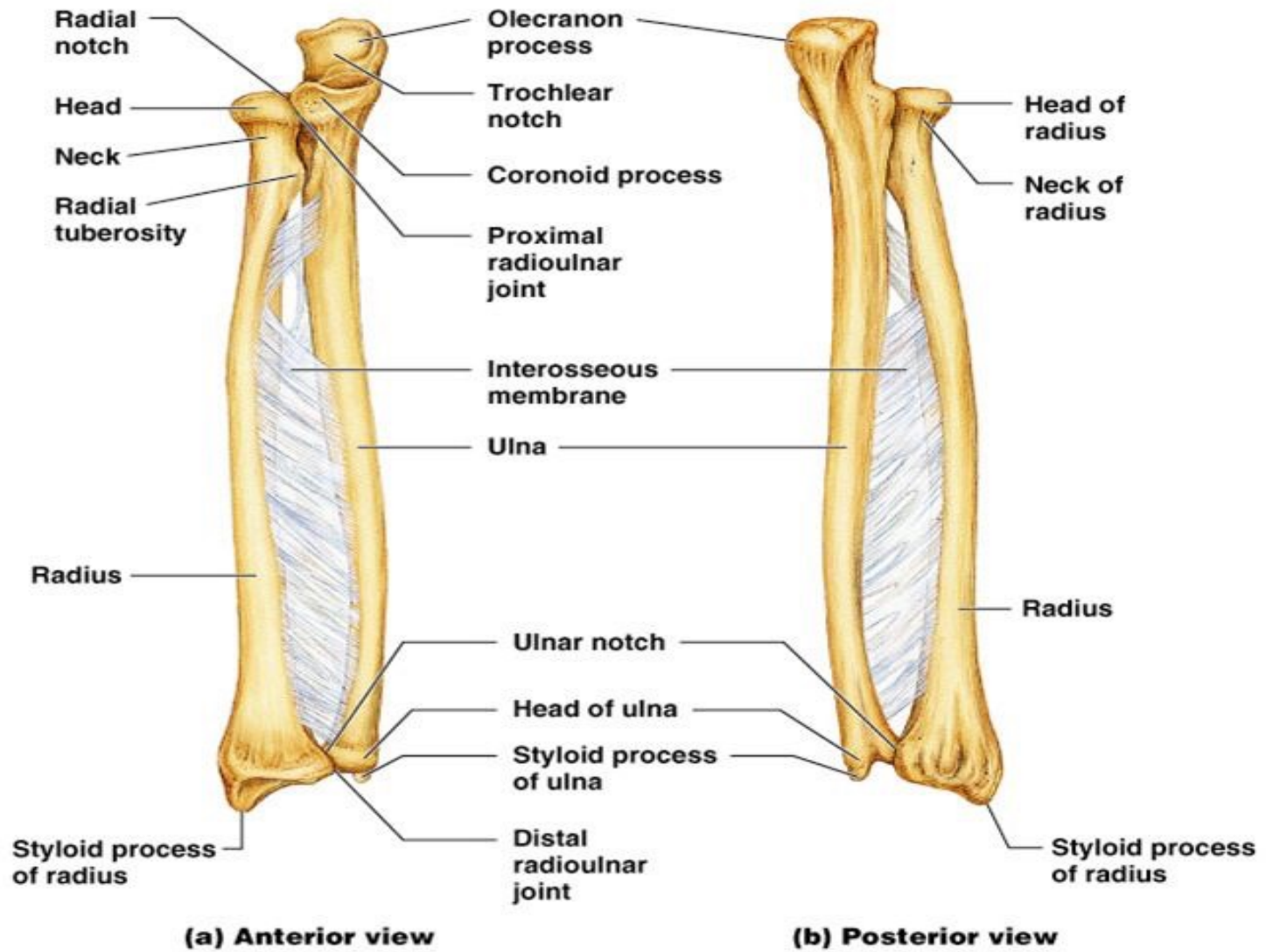
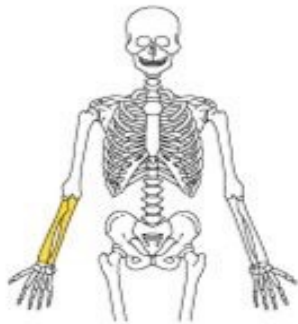
D. Medial surface form **ulnar notch** of radius

E. Inferior smooth **articular surfaces (articulates with carpal bones)** .

Radius







Joints of radius and ulna

1- Proximal radioulnar joint

Articulating bones :

Head of the radius ,radial notch of the ulna and annular ligament

2- Distal radioulnar joint

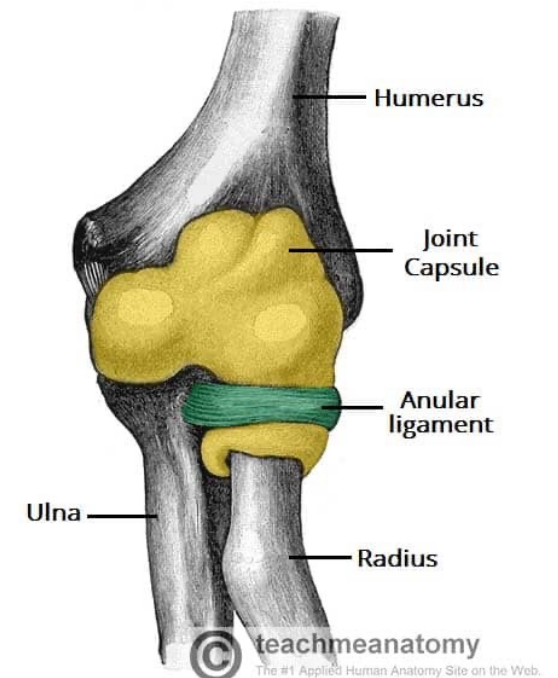
Articulating bones :

Head of the ulna ,ulnar notch of the radius

Type : Pivot synovial

Movement of both joints

Pronation and supination



Proximal radioulnar joint

3- Wrist joint

Articulating bones :

Above : Inferior surface of radius and articular disc Distal radioulnar joint

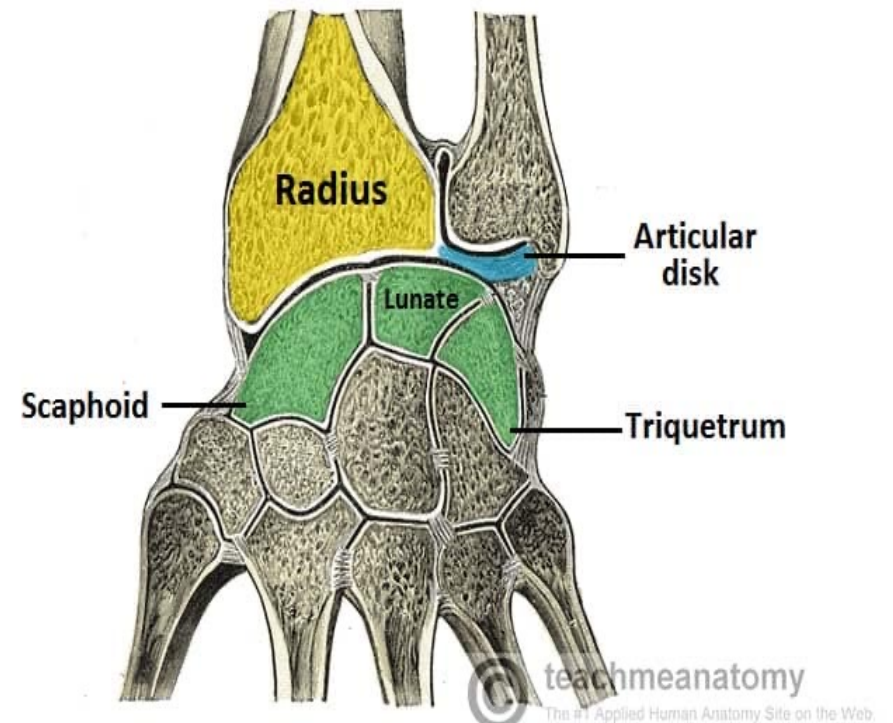
Below : Scaphoid - lunate - triquetrum

Type : Synovial Condyloid joint

Movement :

Flexion and extension

Abduction and adduction



Bones of the hand

A. Carpal bones

The **proximal row** is formed of 4 bones from lateral to medial:

Scaphoid - lunate - triquetrum - pisiform.

The **distal row** is formed of 4 bones from lateral to medial:

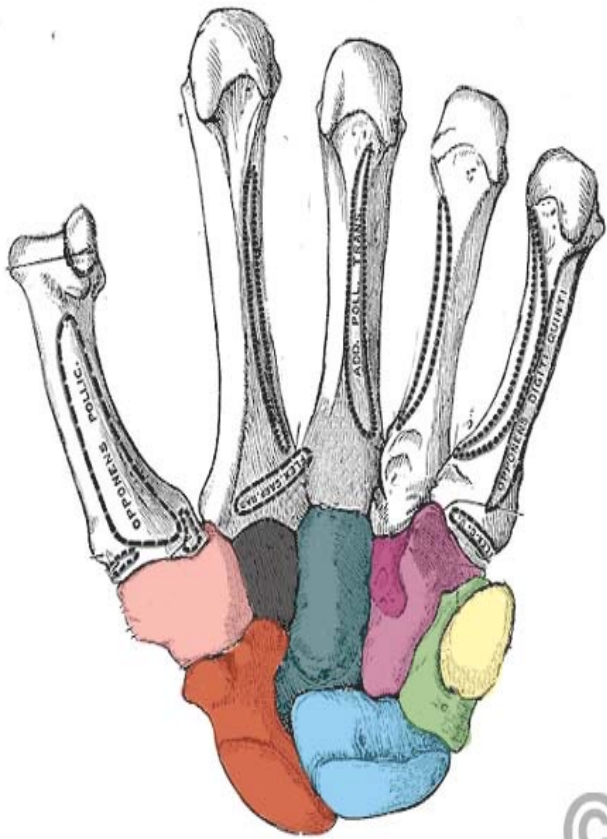
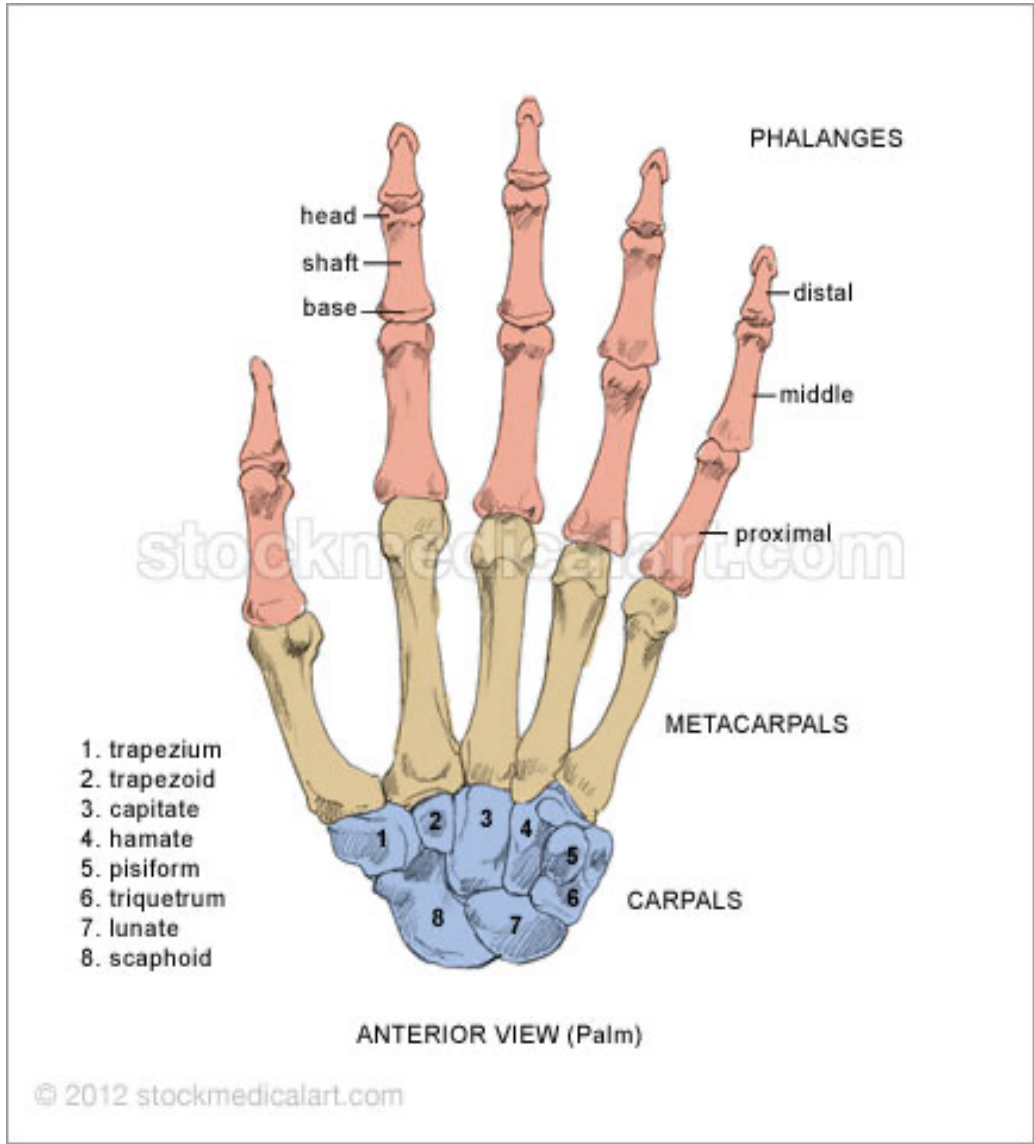
Trapezium - trapezoid - capitate - hamate

B. Five Metacarpal Named one to five from lateral to medial

C. Fourteen Phalanges

Each finger has 3 phalanges except thumb has only two

They are named Proximal, middle and distal phalanges



Joints of Hand

1- Intercarpal joint

Articulating bones :

Between carpal bones

Type : plane synovial

Movement

Gliding movement

2- Carpometacarpal joint (Medial four fingers)

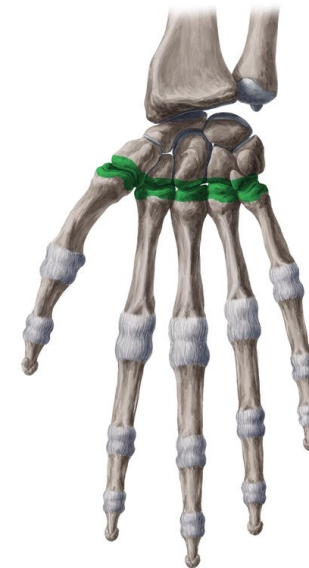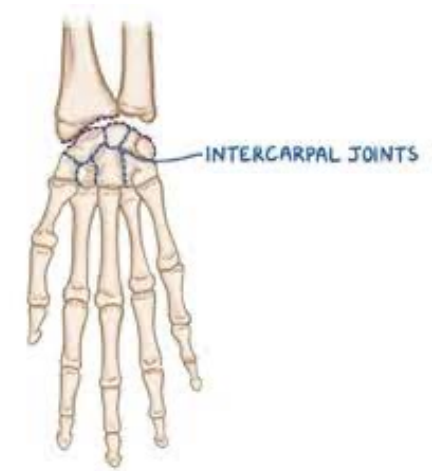
Articulating bones :

Carpal and medial four metacarpal bones

Type : plane synovial

Movement

Gliding movement



3- Carpometacarpal joint (Thumb)

Articulating bones :

Trapezium and 1st metacarpal bone

Type : Saddle shaped synovial

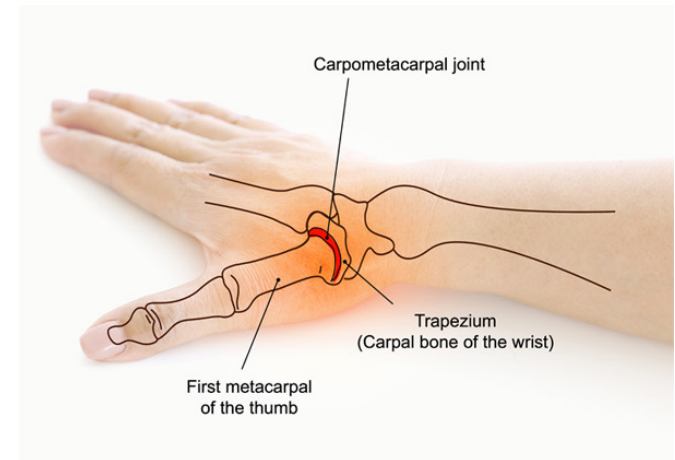
Movement

Flexion

Extension

Adduction

Abduction



Flexion



Extension



Abduction



Adduction



Opposition

4- Metacarpophalangeal joint

Articulating bones :

Head of Metacarpal bones and base of proximal phalanges

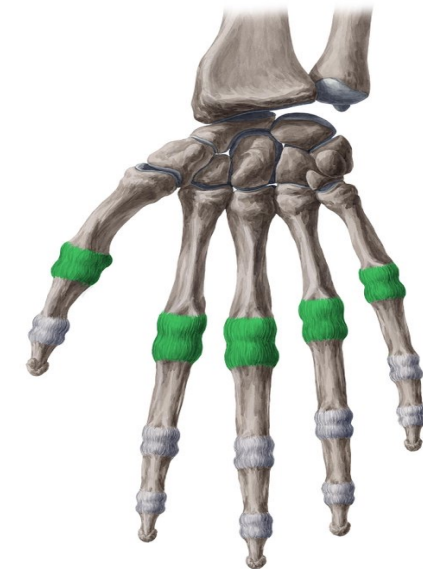
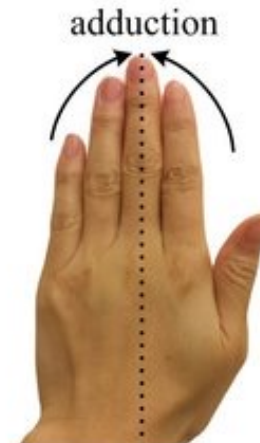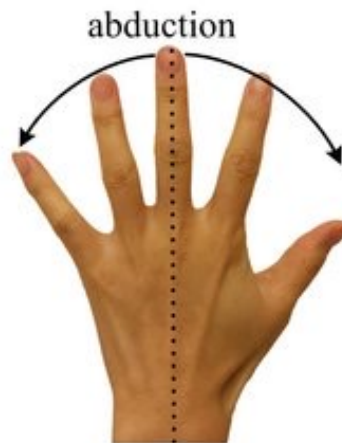
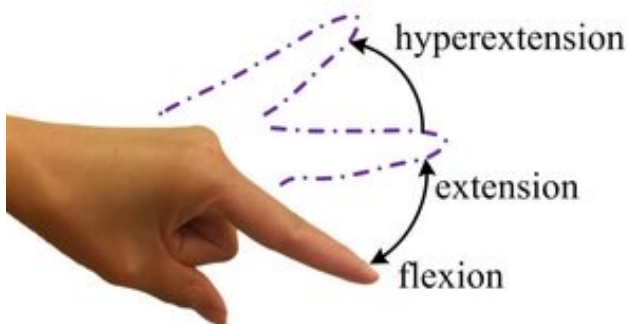
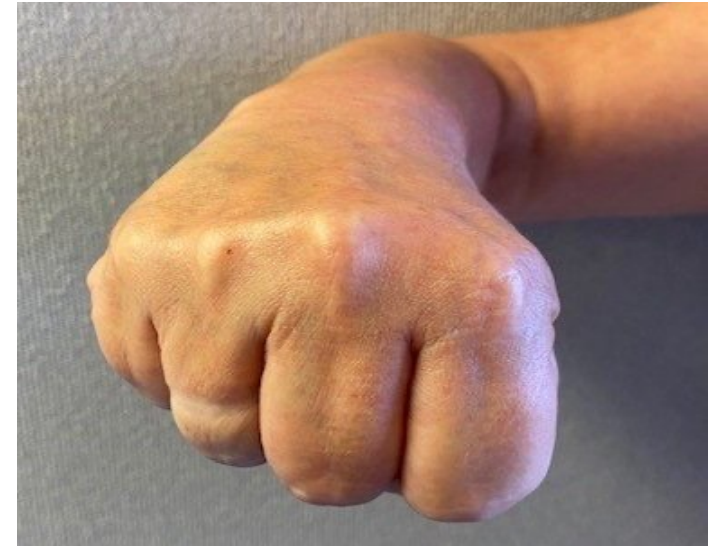Type : Synovial Condyloid joint

Movement

Flexion

Extension

Adduction



5- Proximal Interphalangeal joints

Articulating bones :

Proximal and middle phalanges

Type :Hinge synovial

Movement

Flexion

Extension

6 - Distal Interphalangeal joints

Articulating bones :

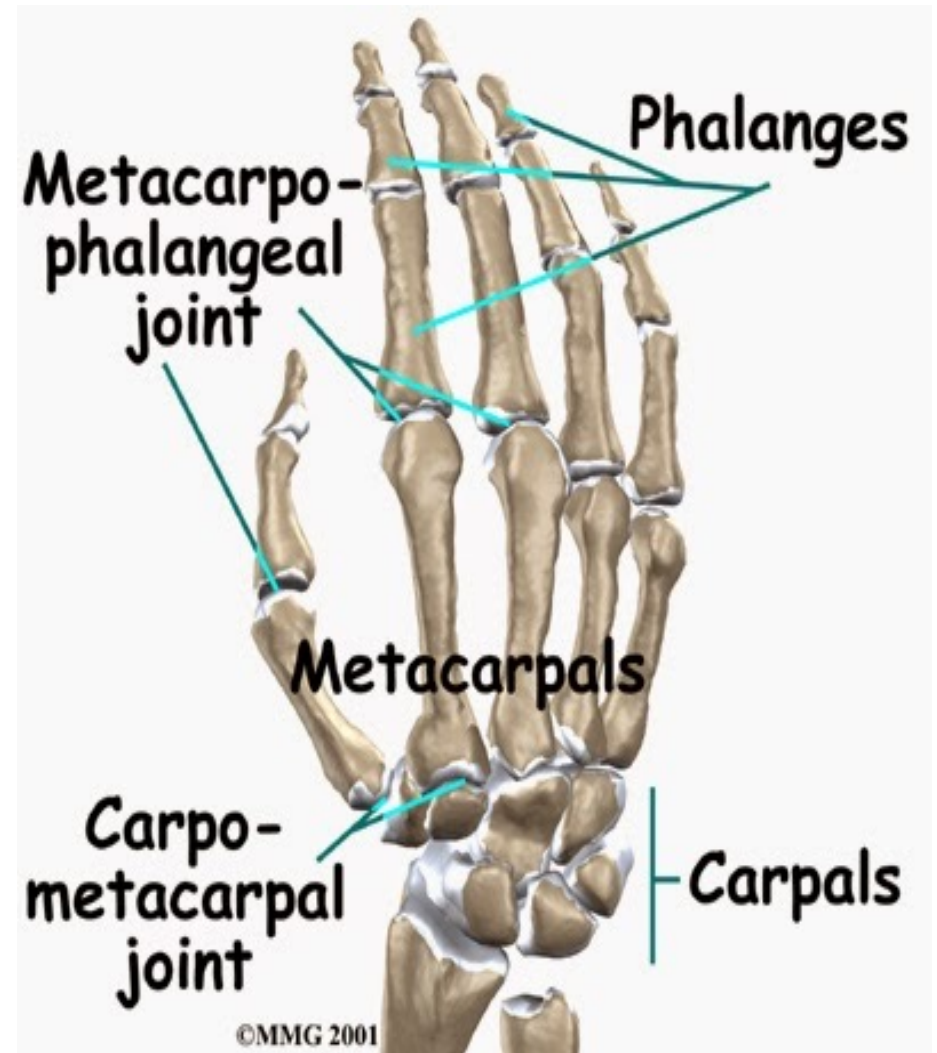
Middle and distal phalanges

Type :Hinge synovial

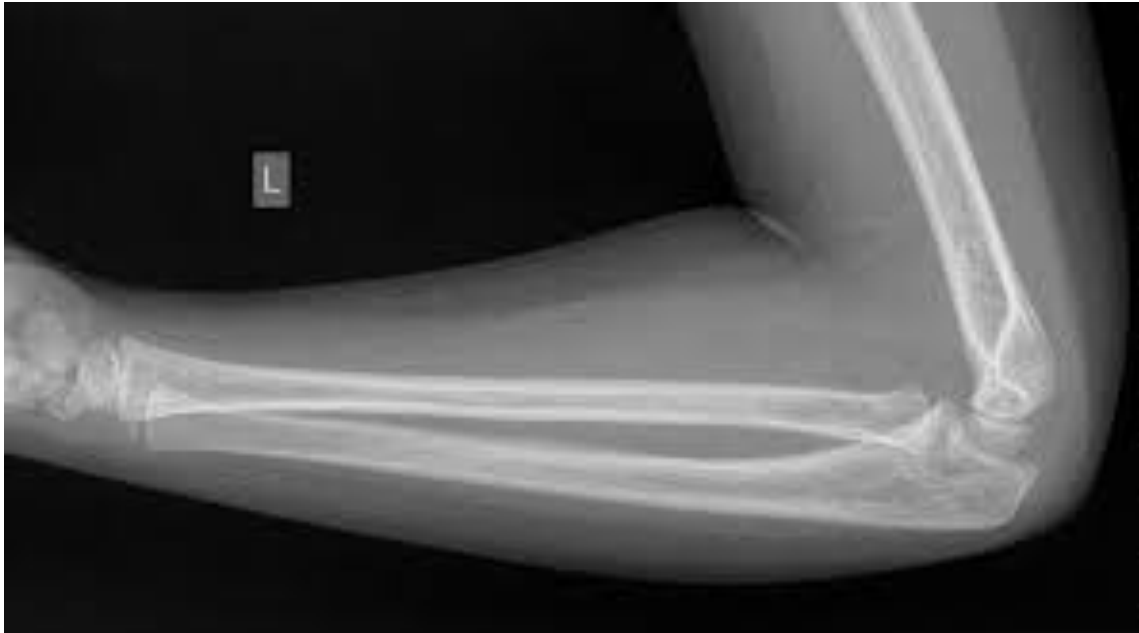Movement

Flexion

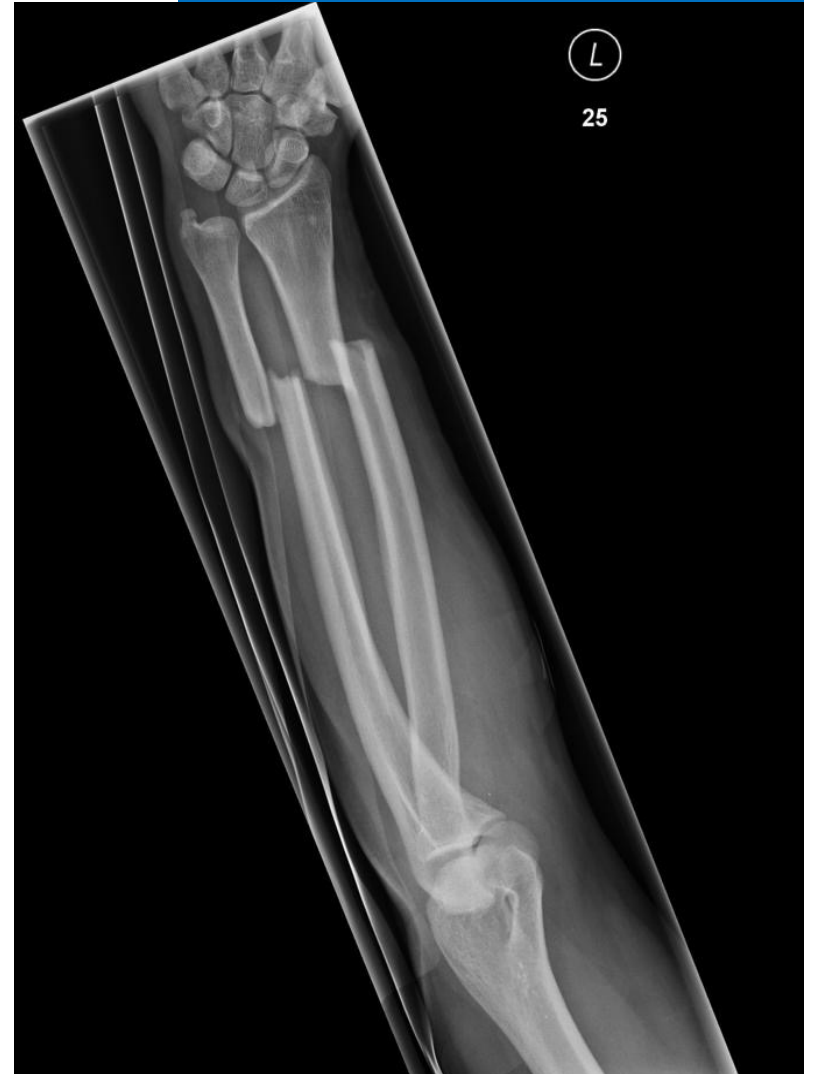Extension



X ray Normal



X ray Fracture





THANK YOU