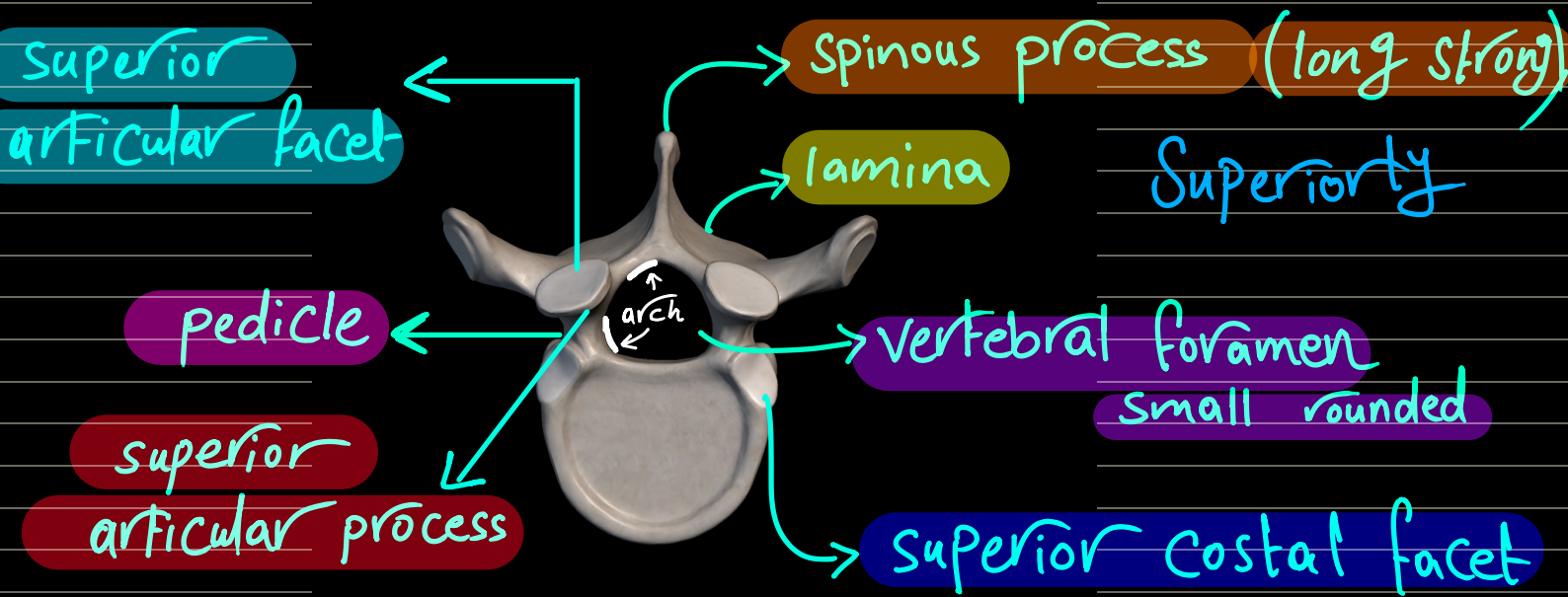
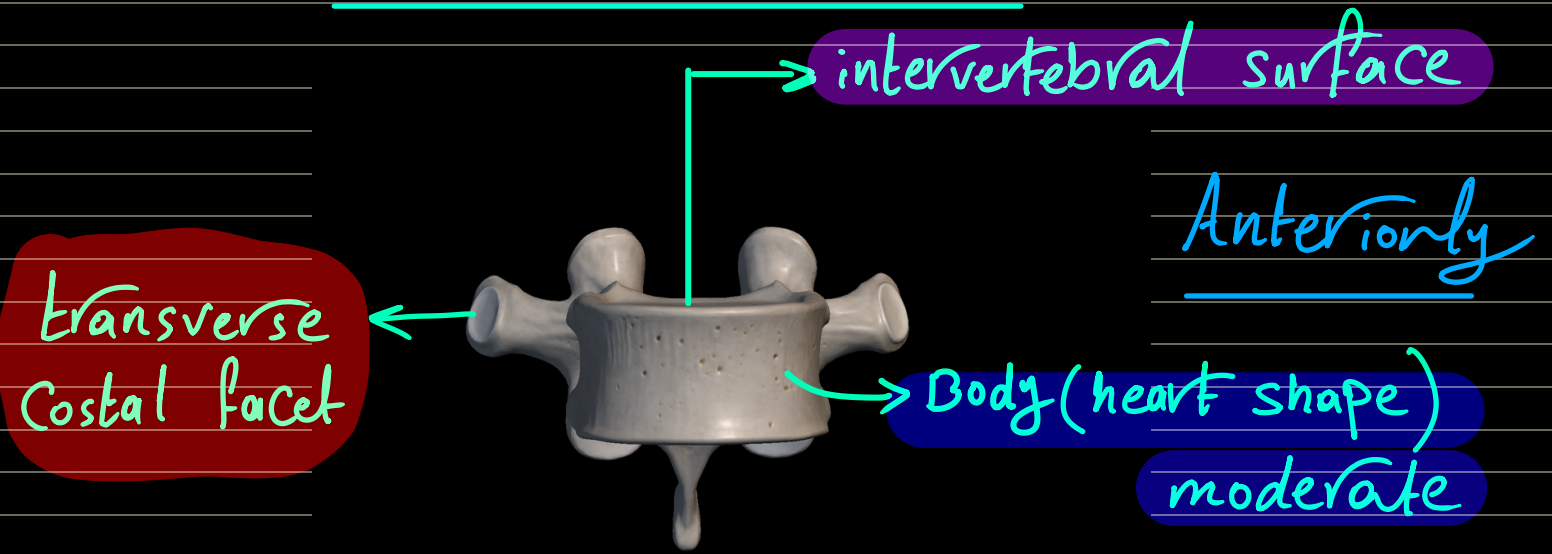
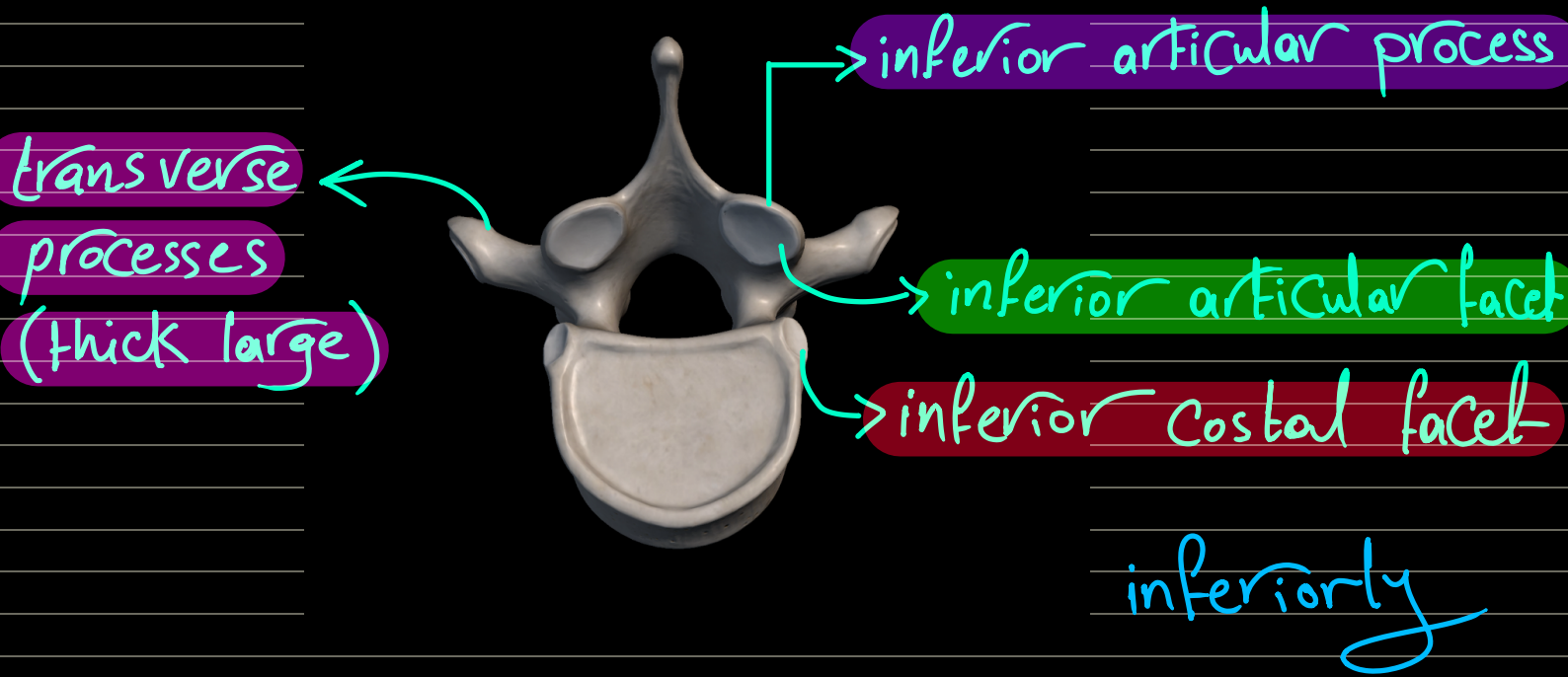


vertebral column

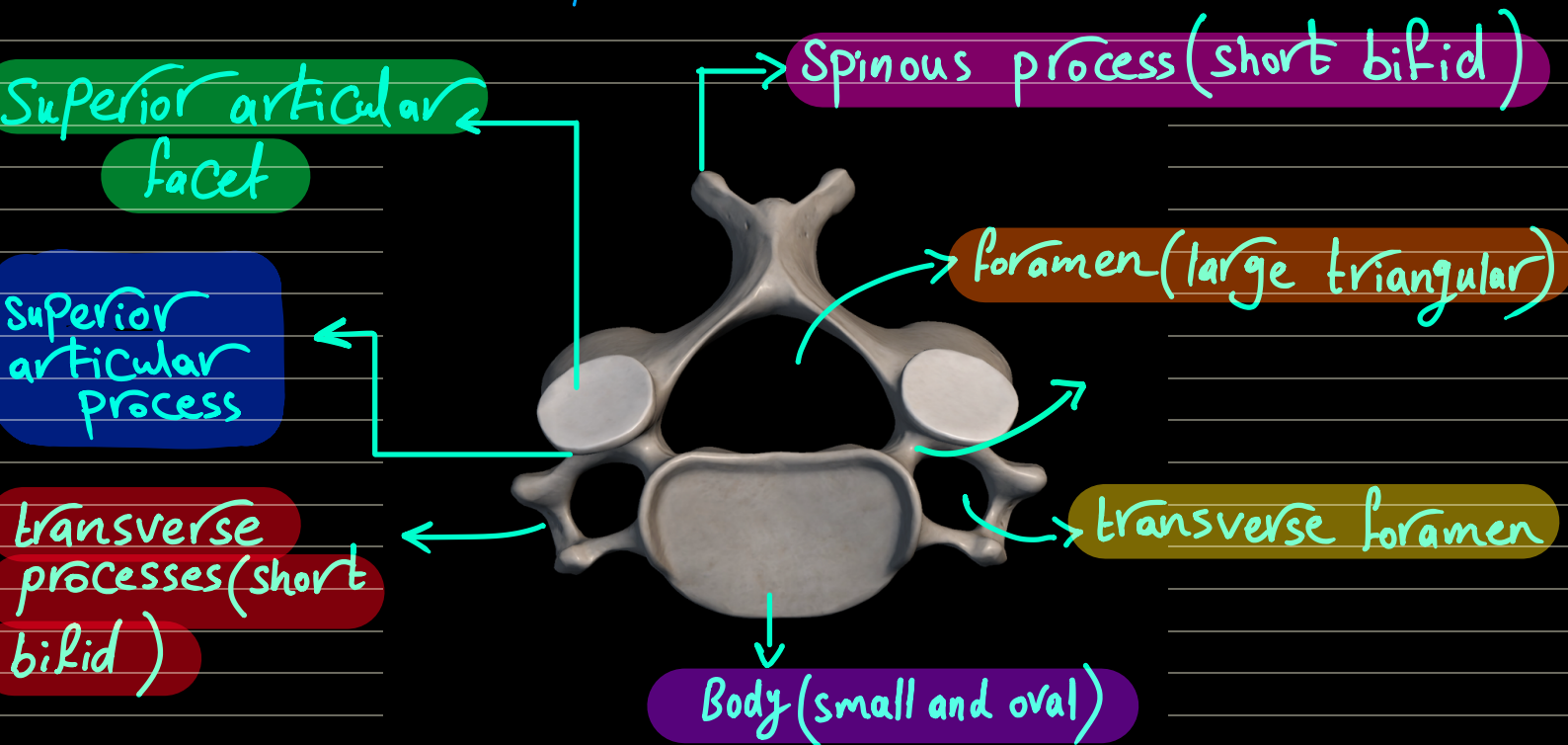
Thoracic vertebra



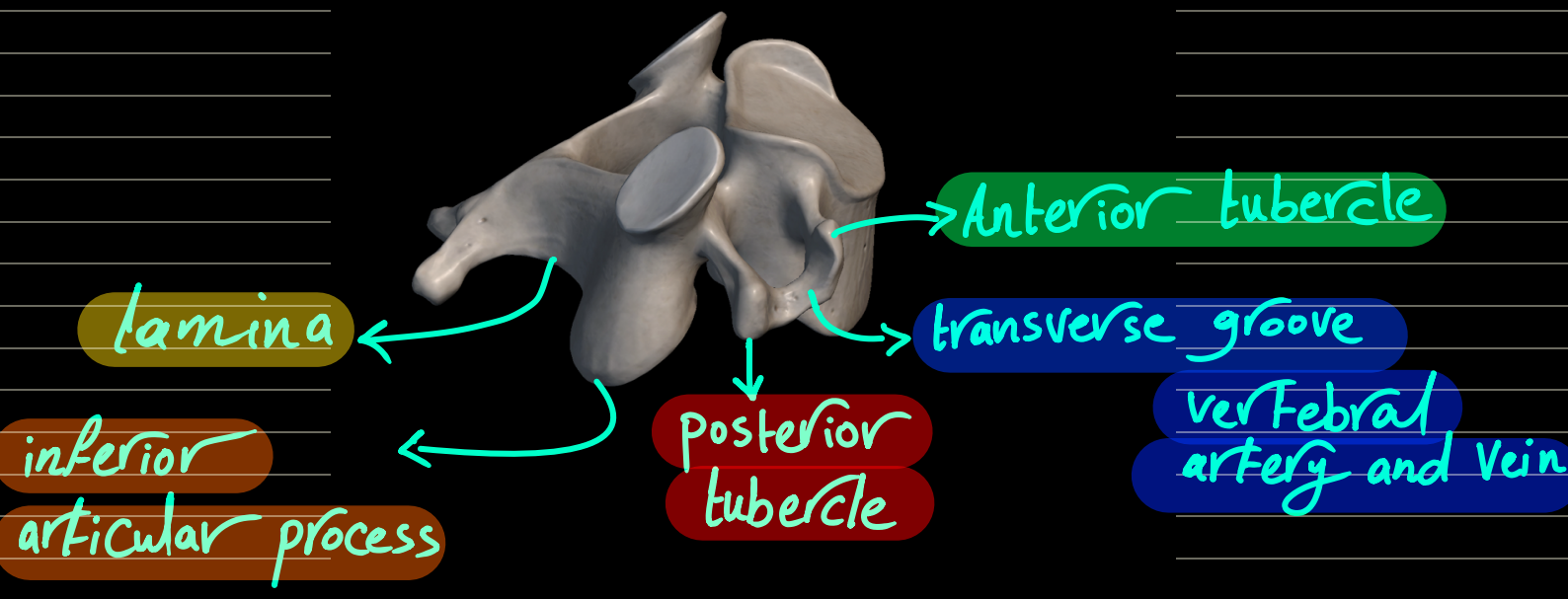


Cervical vertebra

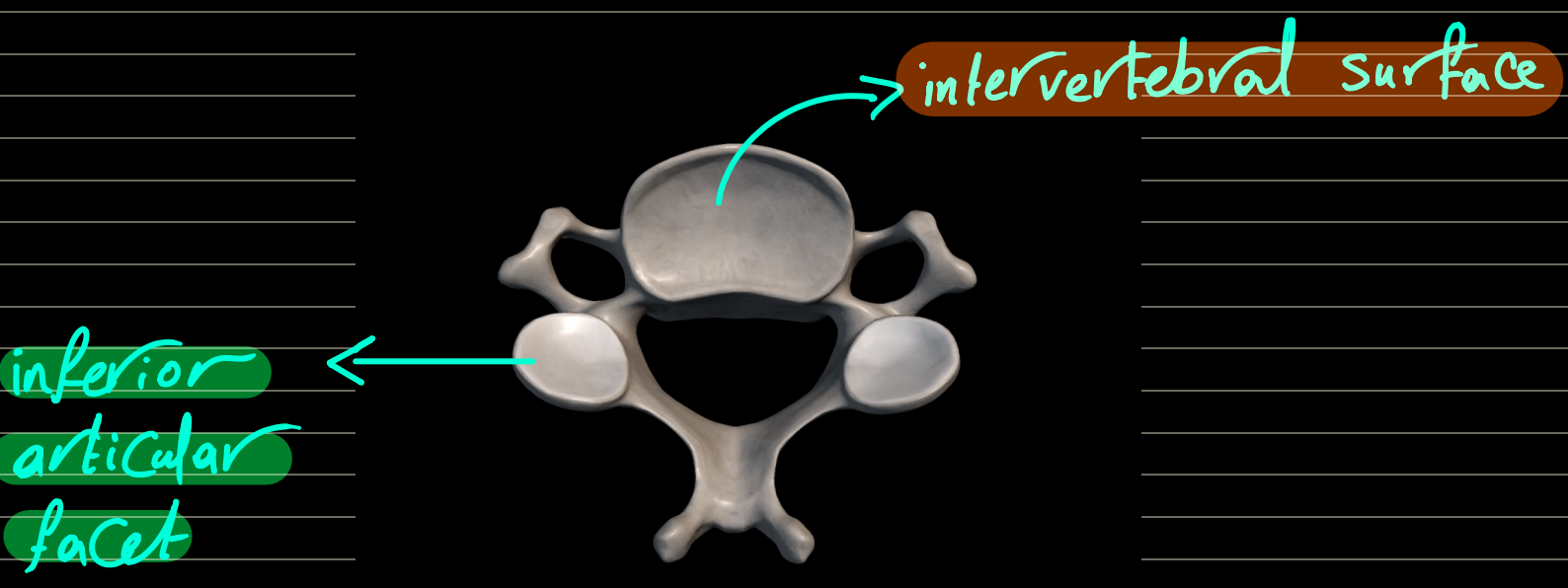
superiorly



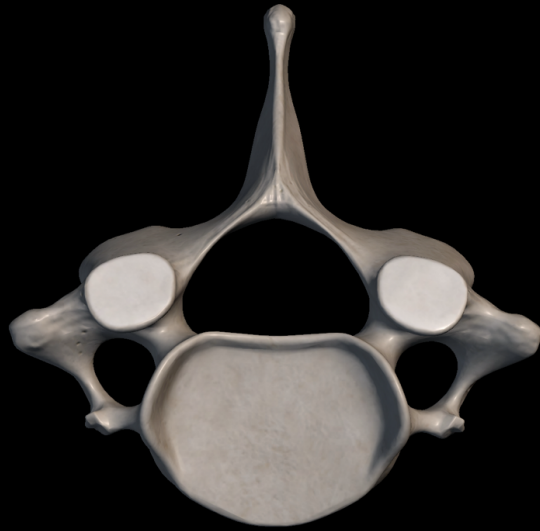left side



inferiorly

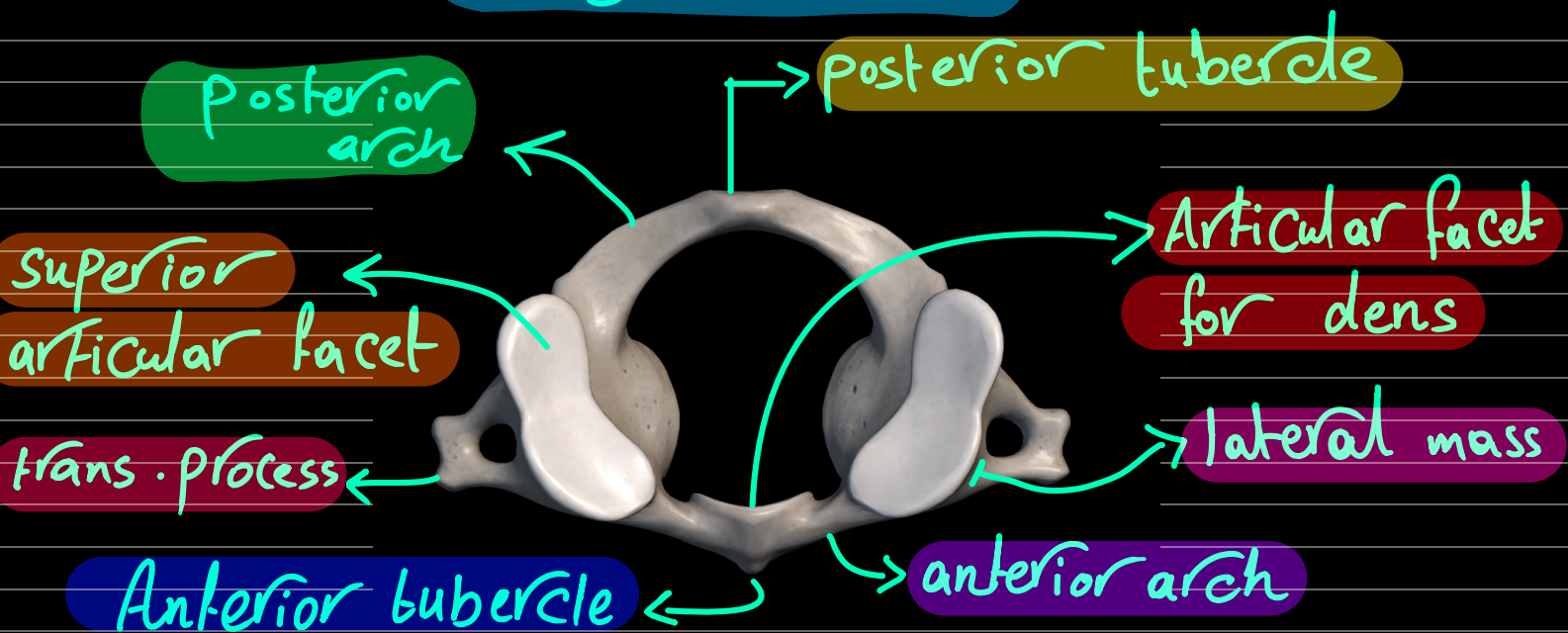


Exception C7 (vertebra prominens)
has the longest not bifid spinous process



Atlas (1st cervical vertebra)

Ring shaped

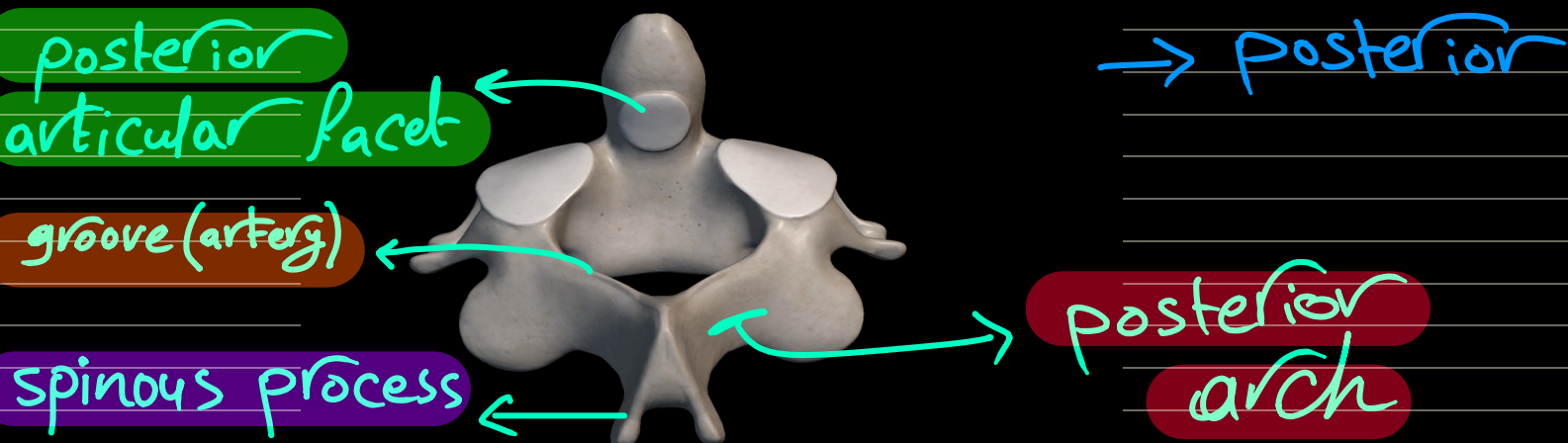
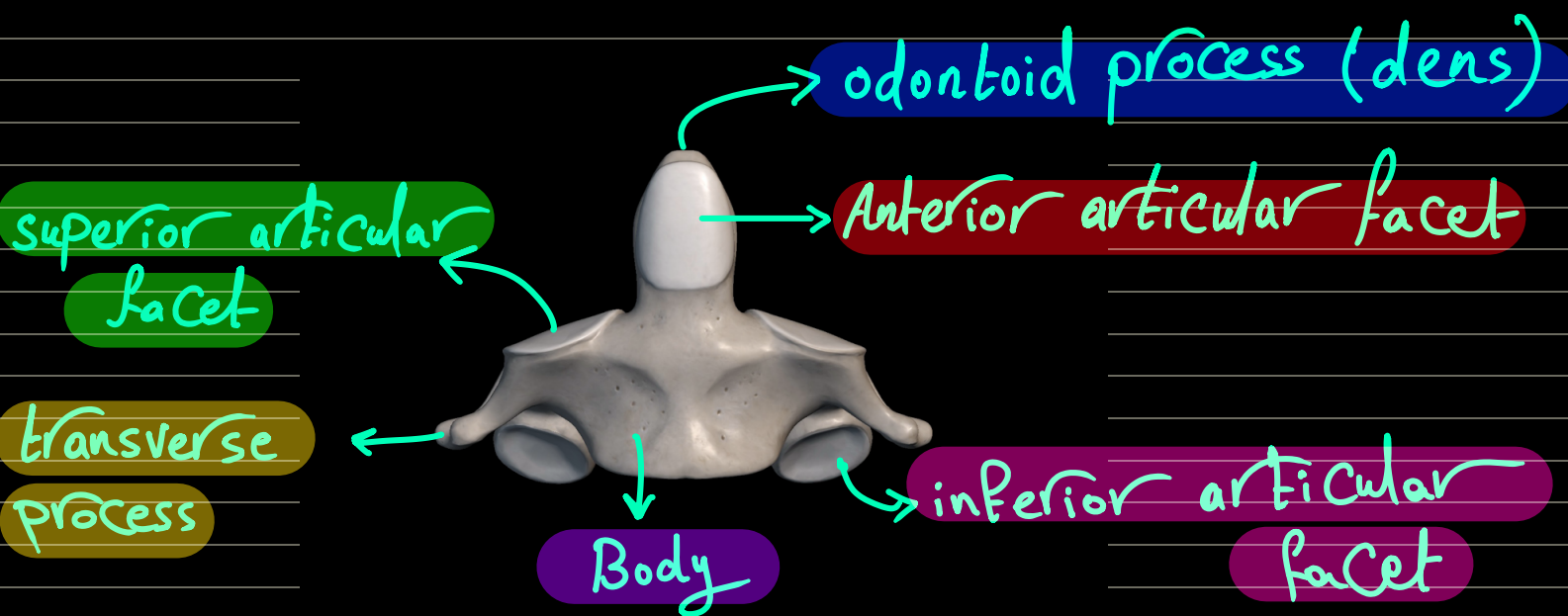


Lateral mass articulates :-

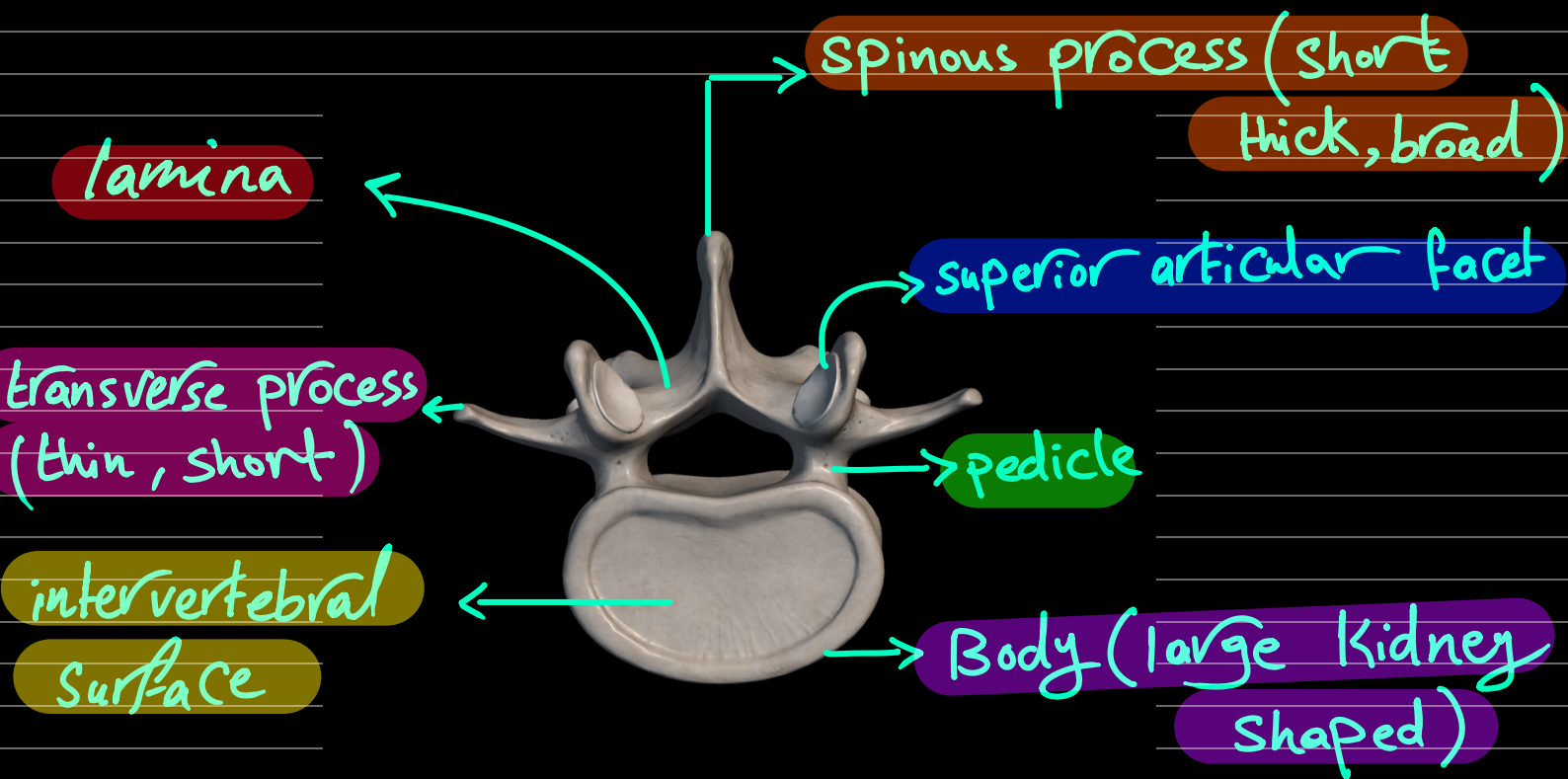
Above : occipital condyle (skull)

Below : Superior articular surface (axis)

Axis (2nd cervical vertebra)

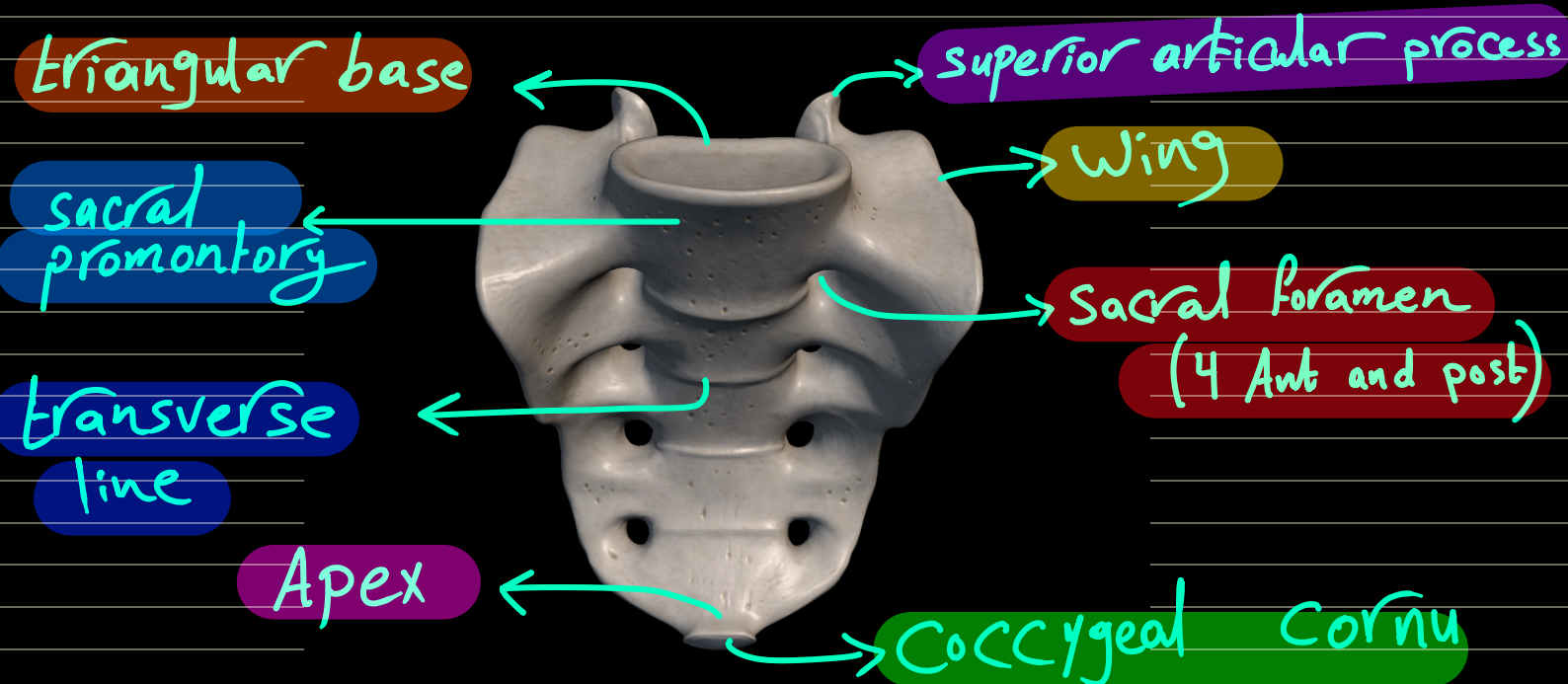


Lumbar Vertebra

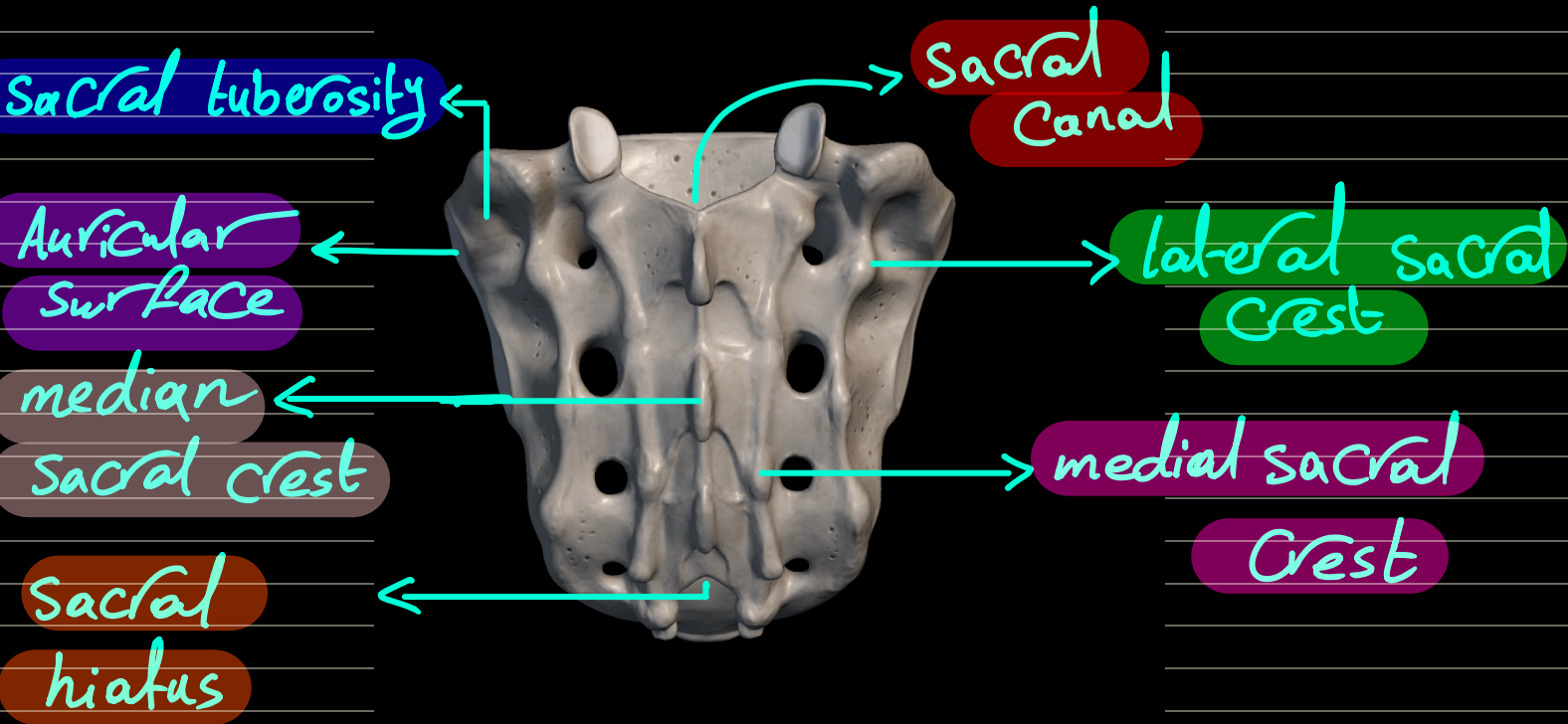


Sacrum

5 sacral vertebrae



posterior



Coccyx (4 coccygeal segments)

