



Done By Noor MarZooq 

The Deep Cervical Fascia

5 LAYERS

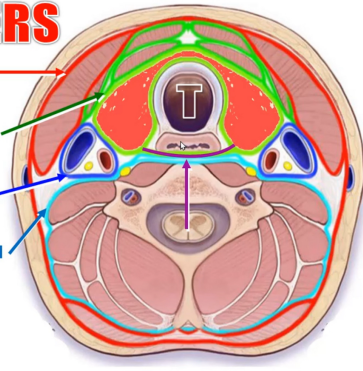
1. Investing Layer

2. Pretracheal Fascia

3. Carotid Sheath

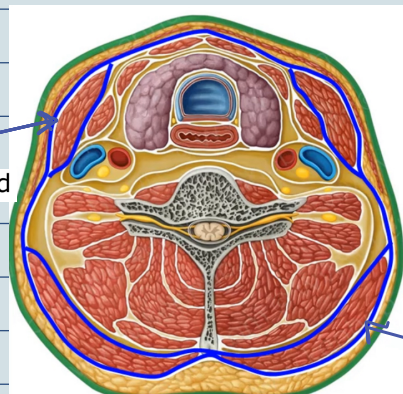
4. Prevertebral Fascia

5. Pharyngeal Fascia



A. Investing layer (fascia coll):

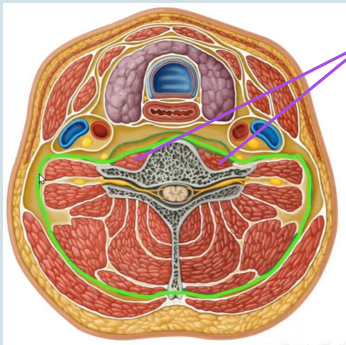
sternocleidomastoid



Trapezius

B. Prevertebral fascia:

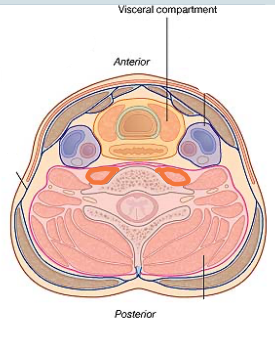
prevertebral muscles



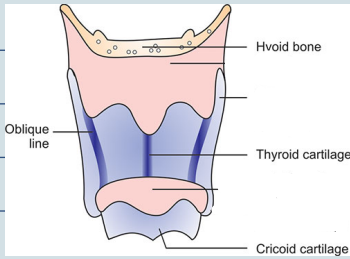
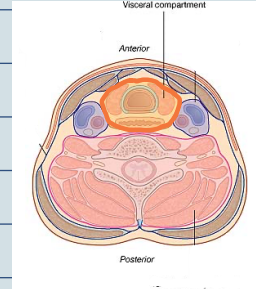
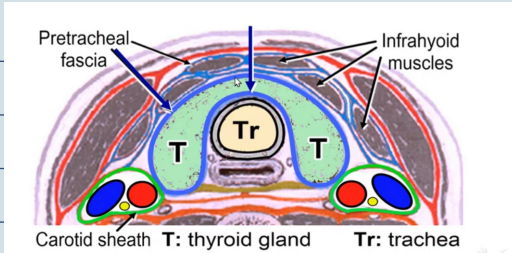
Visceral compartment

Anterior

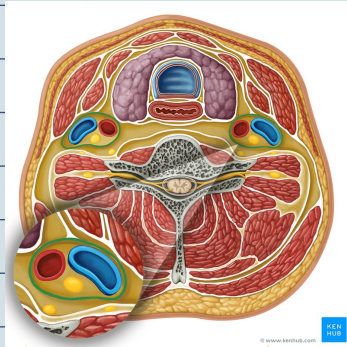
Posterior



C. Pretracheal fascia:



D. Carotid sheath



Scalene Muscles

Scalenus anterior

phrenic nerve

Roots of brachial plexus

Trunks of brachial plexus

3rd part

1st part

subclavian artery

internal jugular vein

Subclavian vein

