

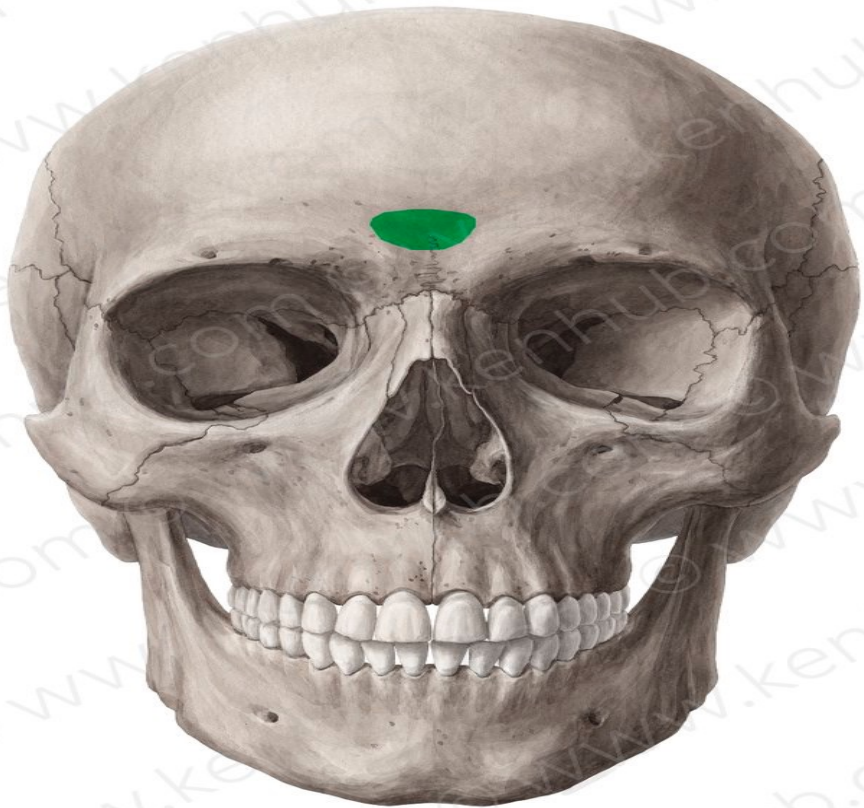


Skull

DR. AHMED SALMAN

Associate professor of anatomy

- ❑ The skull is formed of separate bones (6 single and 8 paired).
- ❑ Many of these bones articulate with one another by **sutures**.



❑ The skull is studied in six views, each is called norma :

- ✓ From in front : Norma frontalis
- ✓ From above : Norma verticalis.
- ✓ From behind : Norma occipitalis.
- ✓ From the side : Norma lateralis.
- ✓ From below: Norma basalis externa.
- ✓ From inside : Norma basalis interna.

Norma Frontalis

Norma Frontalis:

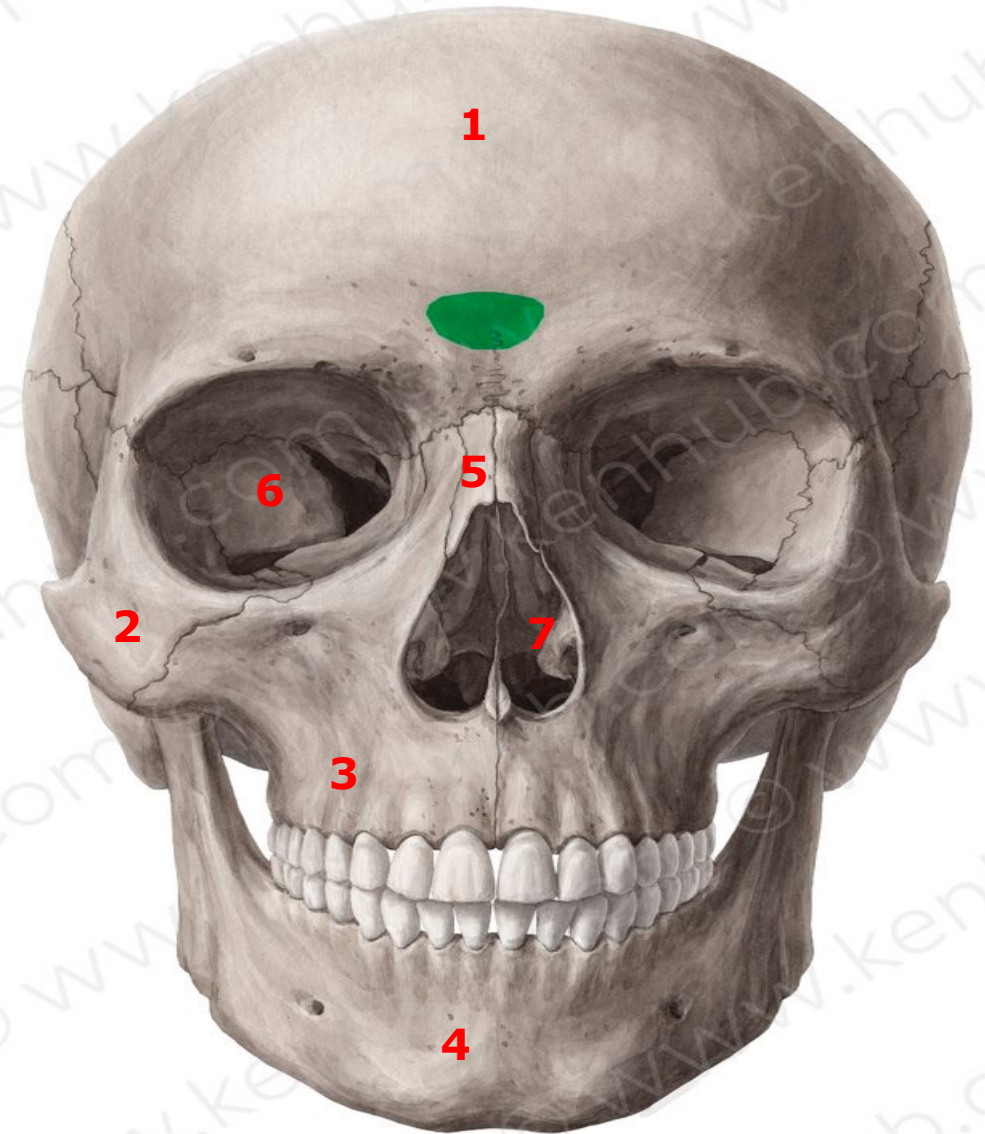
➤ Boons :

1. The frontal bone with its maxillary and zygomatic processes.
2. The two nasal bones.
3. The zygomatic bone with its maxillary and frontal processes.
4. The maxilla with its zygomatic, frontal and alveolar processes.

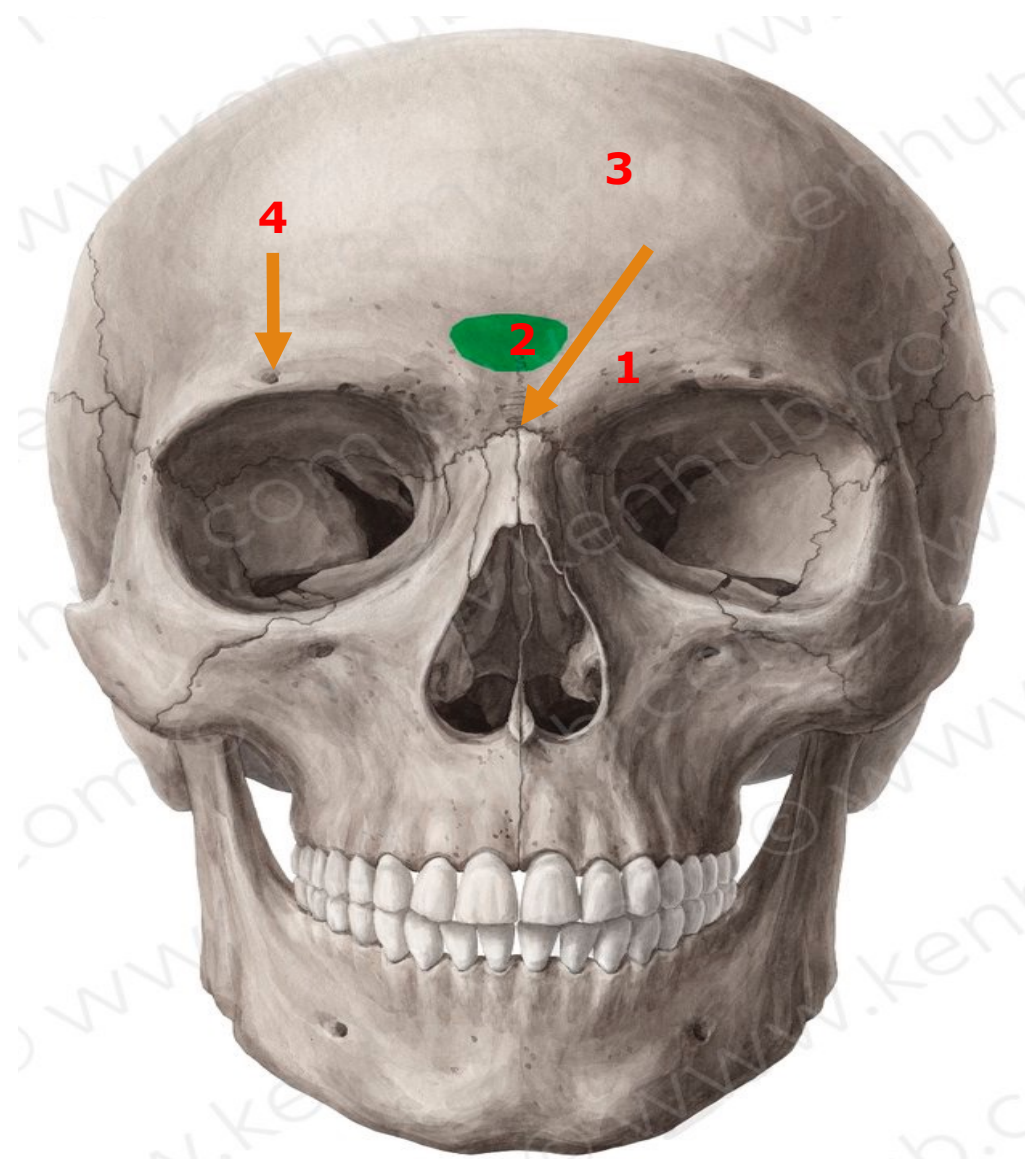
➤ Apertures :

1. Two orbital apertures.
2. The anterior nasal aperture.

1. Frontal bone
2. Zygomatic bone
3. Maxilla
4. Mandible
5. Nasal bone
6. Orbital apertures.
7. Anterior nasal aperture



1. The supraciliary arch
2. The glabella (is a median elevation between the two superciliary arches)
3. The nasion (The nasion : is the meeting point between the frontal bone and the two nasal bones)
4. The supraorbital foramen





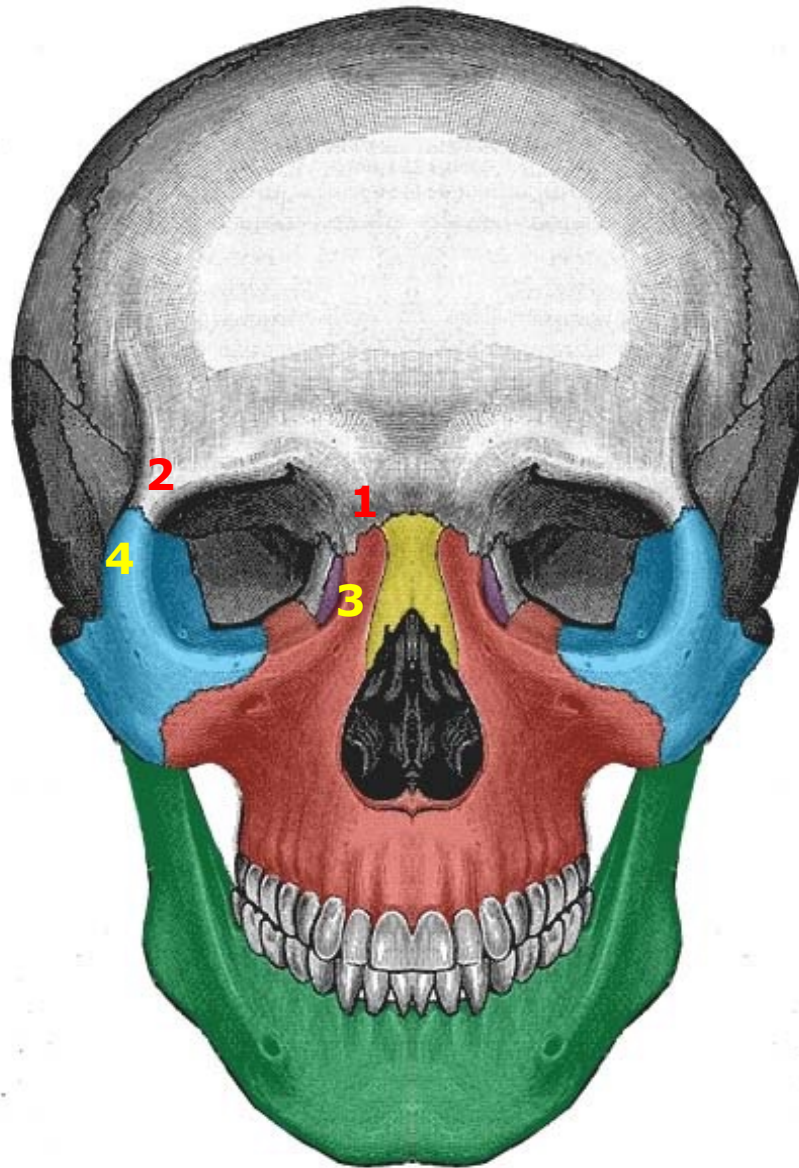
Frontal

Maxillary process of frontal bone

Maxilla

Frontal process of Maxilla

1. Maxillary process of frontal bone
2. Zygomatic process of frontal bone
3. Frontal process of Maxilla
4. Frontal process of Zygomatic



-  Zygomatic
-  Maxilla
-  Nasal
-  Lacrimal
-  Mandible

Maxilla Bone

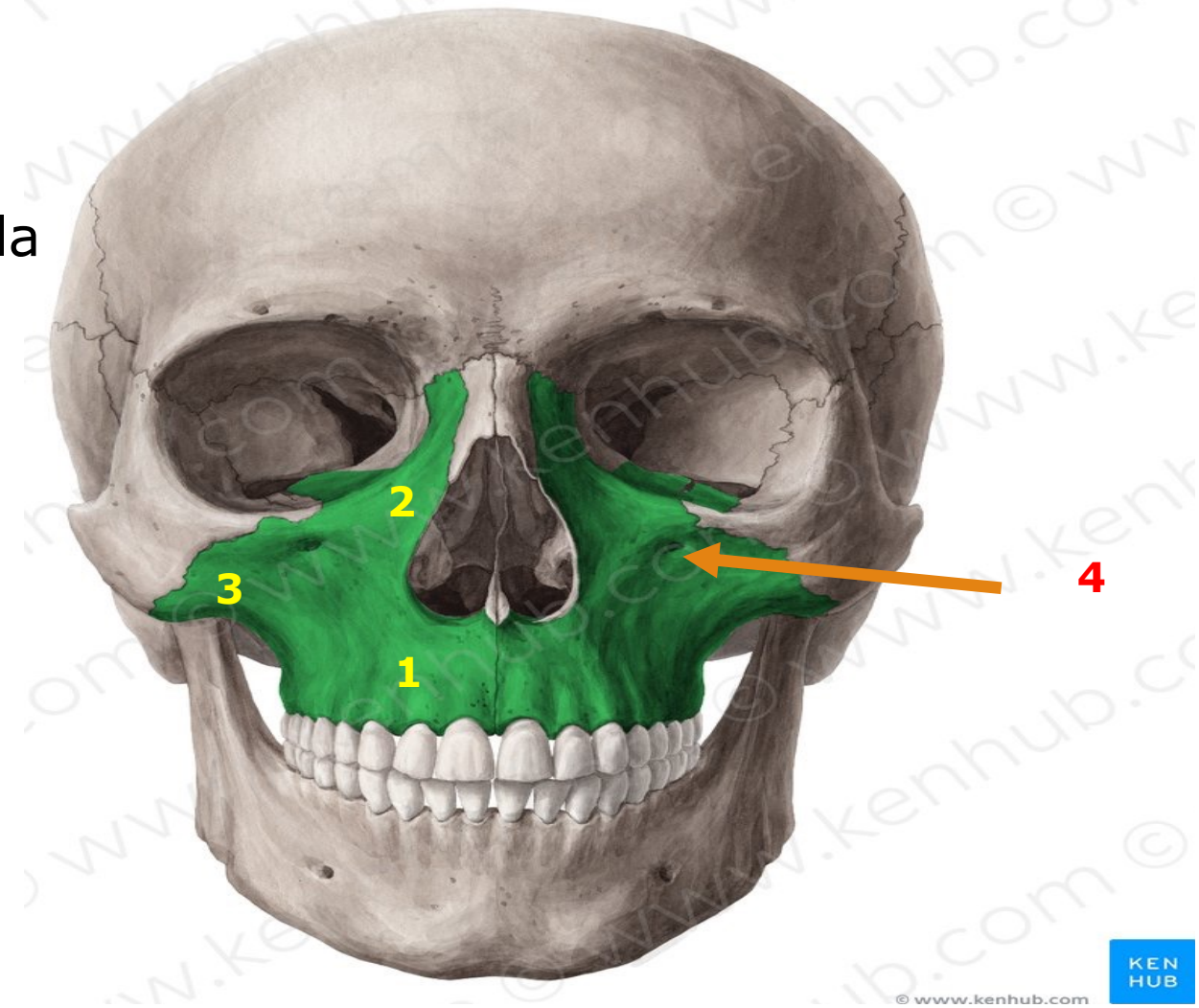
1. Alveolar process of Maxilla

(The two alveolar processes unite to form the alveolar arch (upper jaw)).

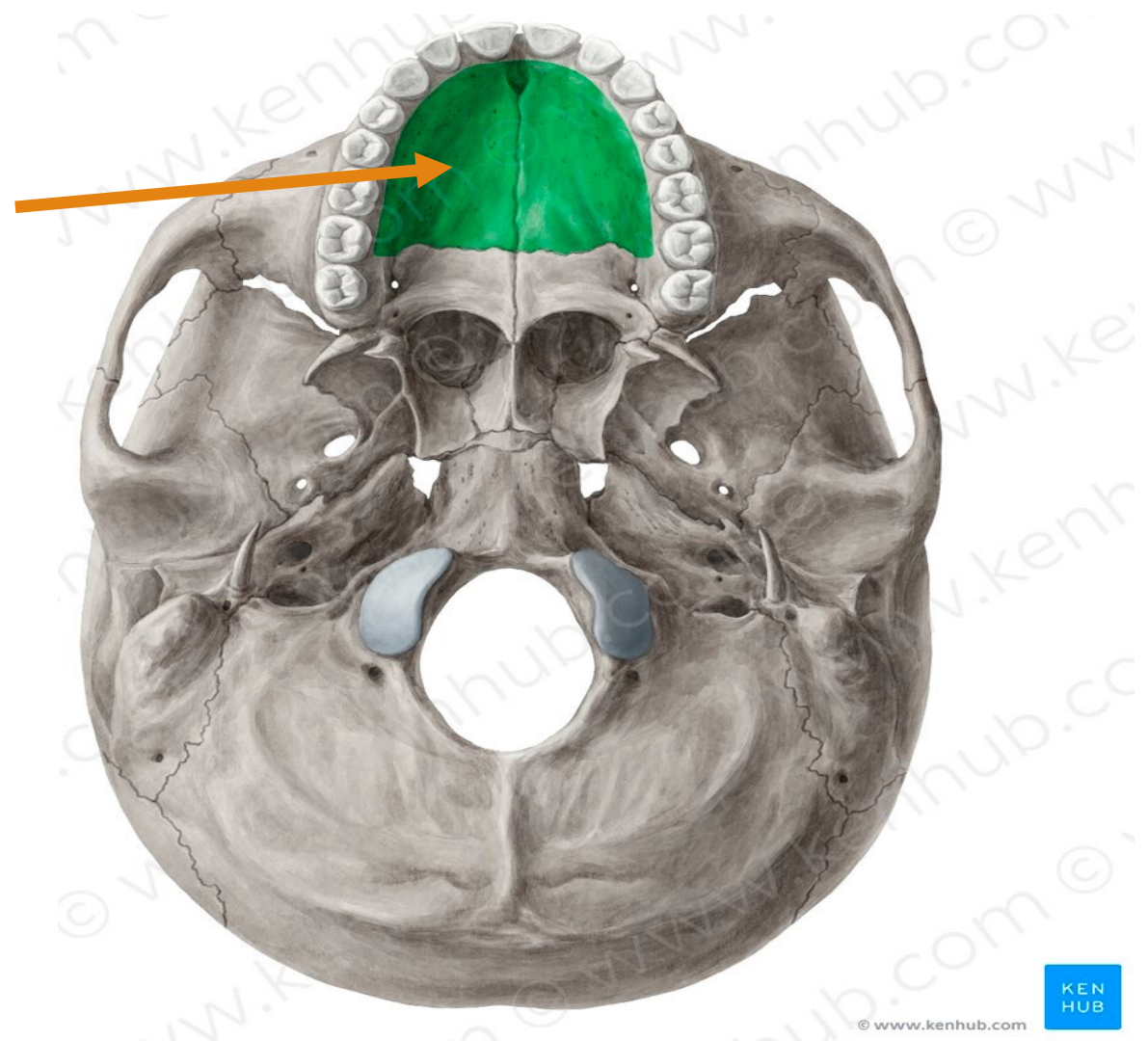
2. Frontal process of Maxilla

3. Zygomatic process of Maxilla

4. Infraorbital foramen

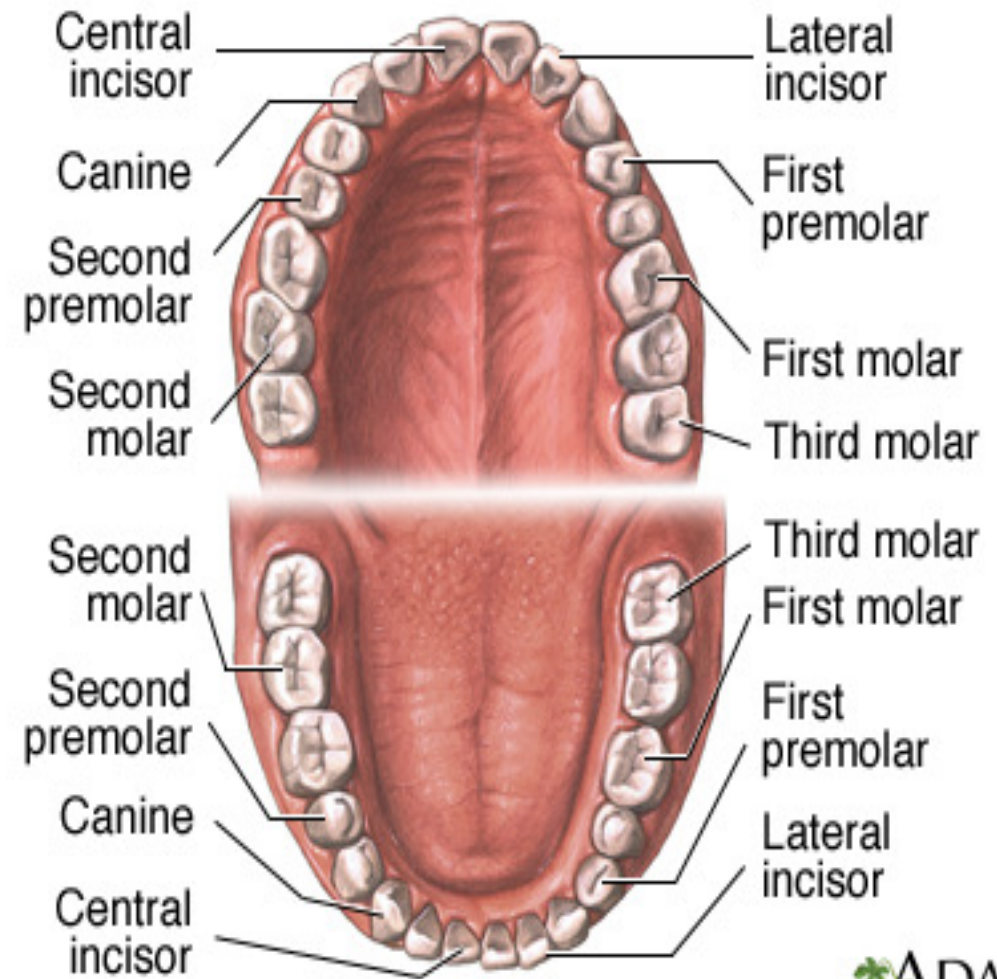


5- Palatine process of maxilla



Number of teeth is 32 in both jaws

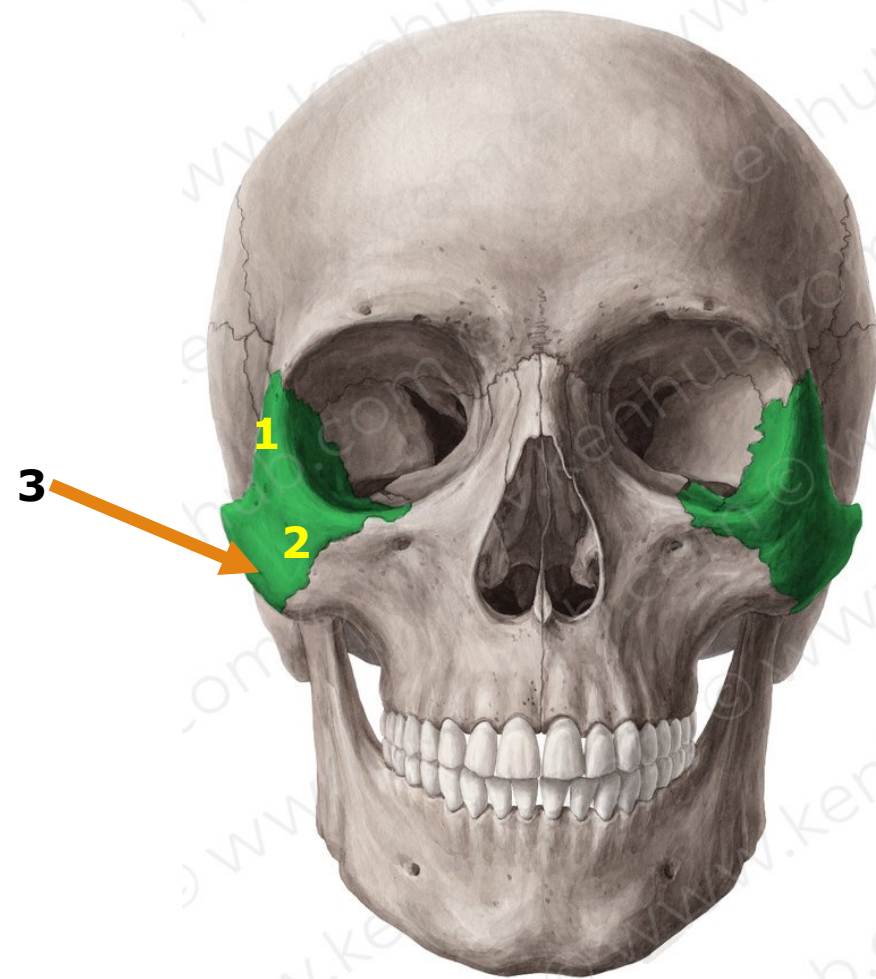
Incisors : 8
Canines : 4
Premolars : 8
Molars : 8
Third molars : 4



ADAM.

Zygomatic Bone

1. Frontal process of Zygomatic bone
2. Maxillary process of Zygomatic bone
3. zygomatico-facial foramen



Norma verticalis

Norma Verticalis :

This view presents :

➤ **4 bones**

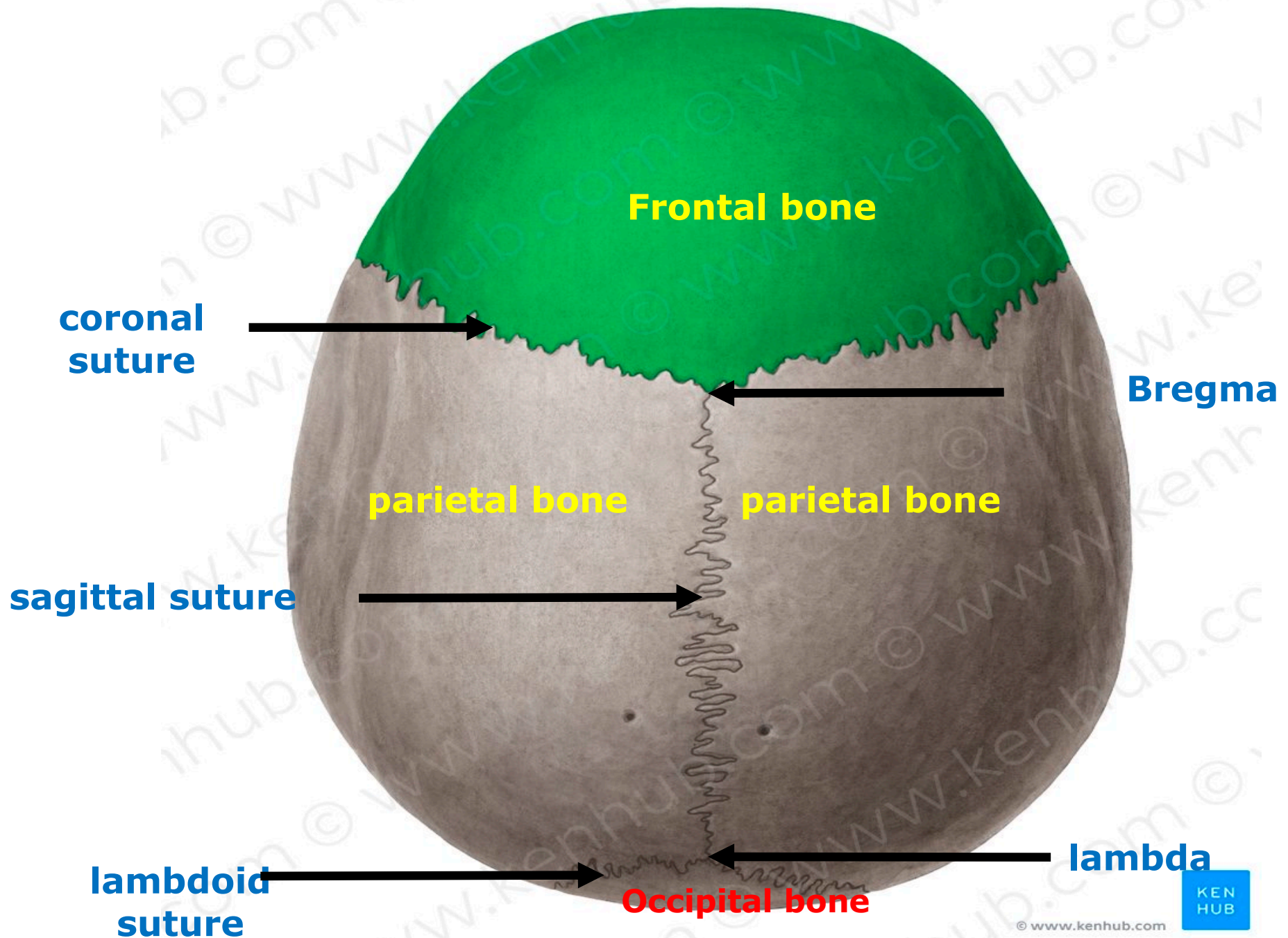
- Anteriorly : The frontal bone
- Laterally : The two parietal bones
- Posteriorly : The occipital bone

➤ **3 sutures :**

The coronal suture : between the frontal bone and the two parietal bones.

The sagittal suture : between the two parietal bones.

The lambdoid suture : between the occipital bone and the two parietal bones.



➤ 2 meeting points :

The bregma :

- ❑ Is the meeting of the coronal and sagittal sutures.
- ❑ It is the site of the anterior fontanelle

The lambda :

- ❑ Is the meeting of the lambdoid and sagittal sutures.
- ❑ It is the site of the posterior fontanelle .

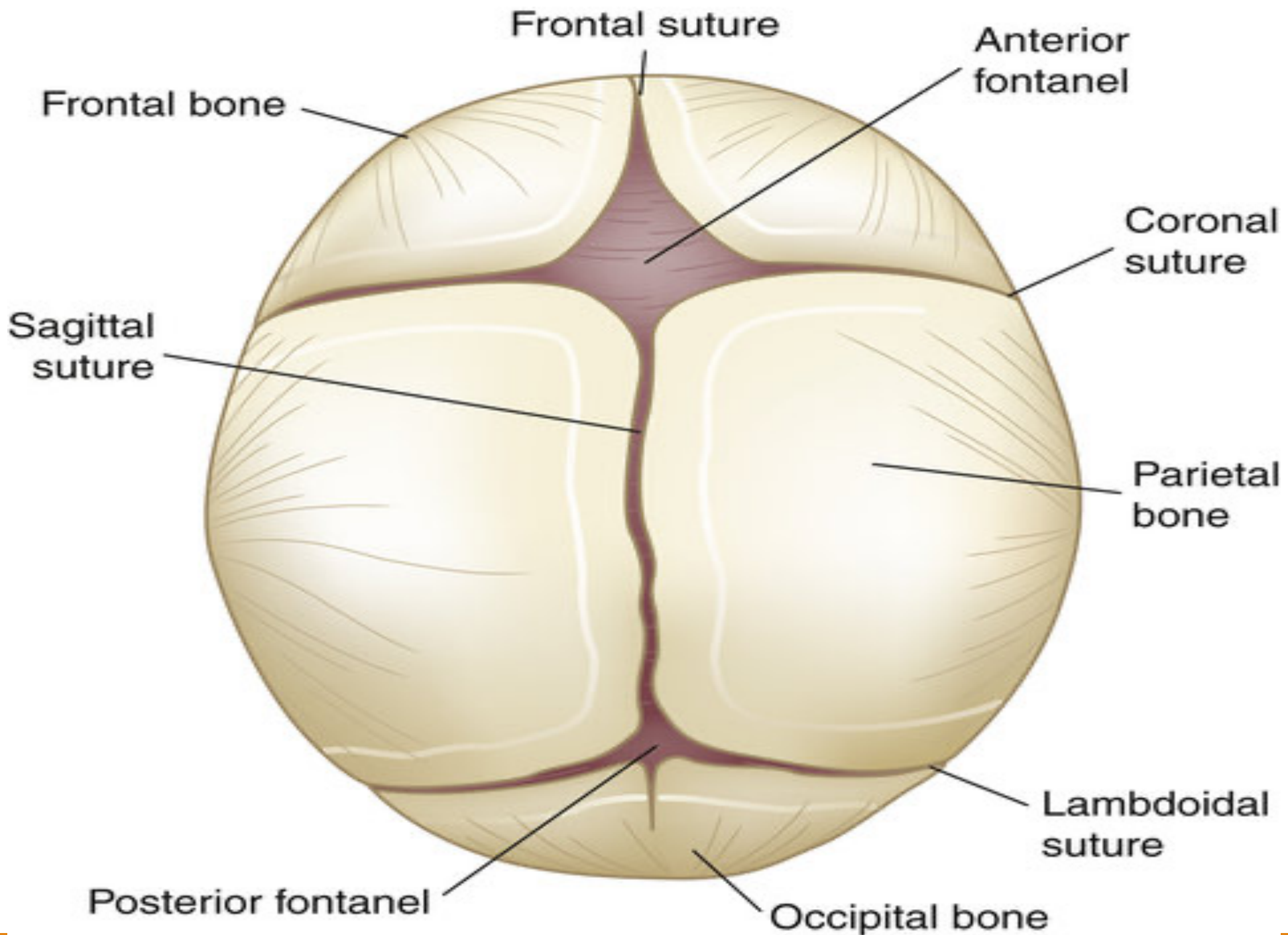
➤ 2 Fontanelle :

Anterior fontanelle

- ❑ It is a membrane-filled rhomboidal area.
- ❑ It usually closes 1.5-2 years after birth.
- ❑ It is the site of the bregma

Posterior fontanelle

- ❑ It is a membrane-filled triangular area
- ❑ It usually closes 3-6 months after birth
- ❑ It is the site of the lambda.



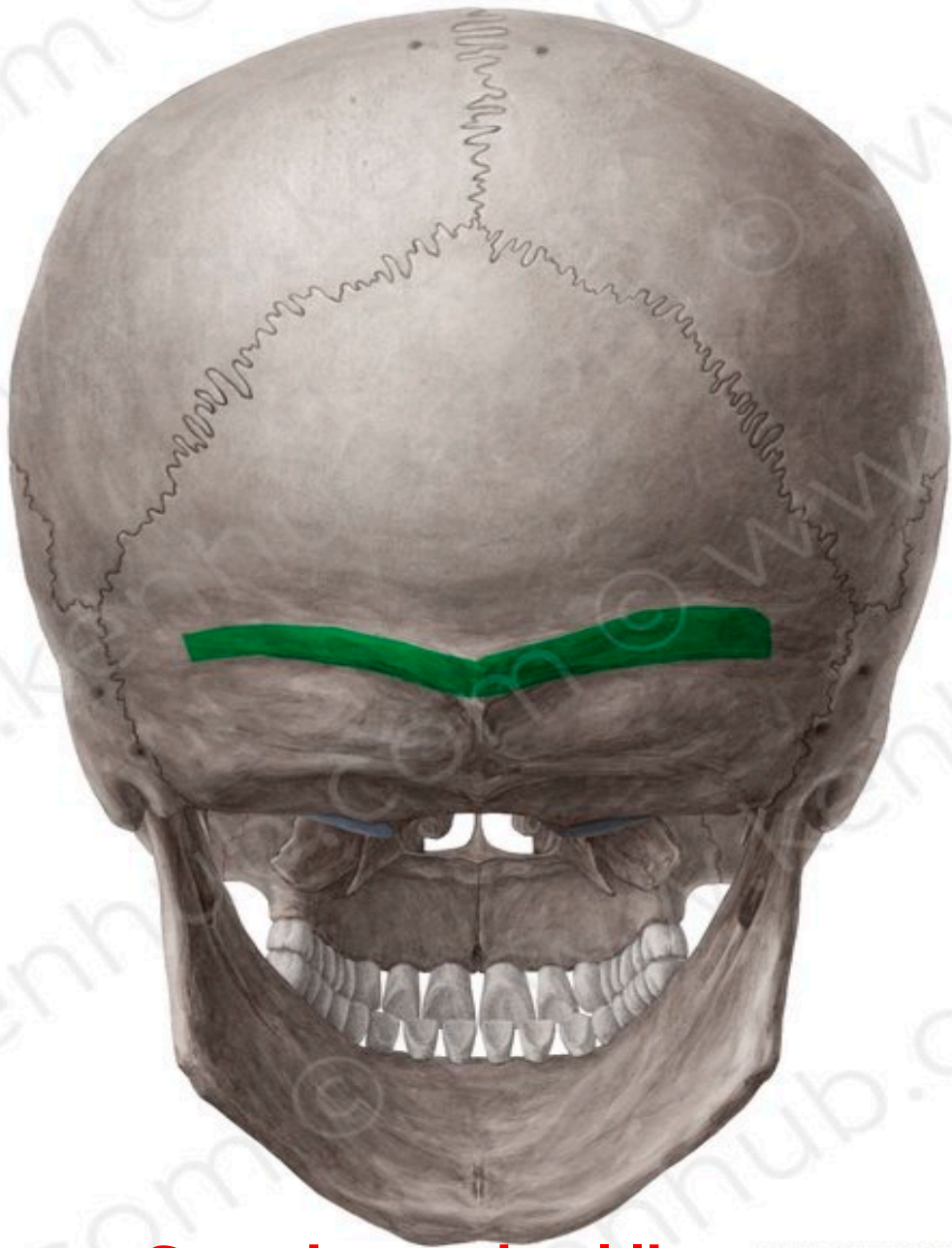Norma Occipitalis



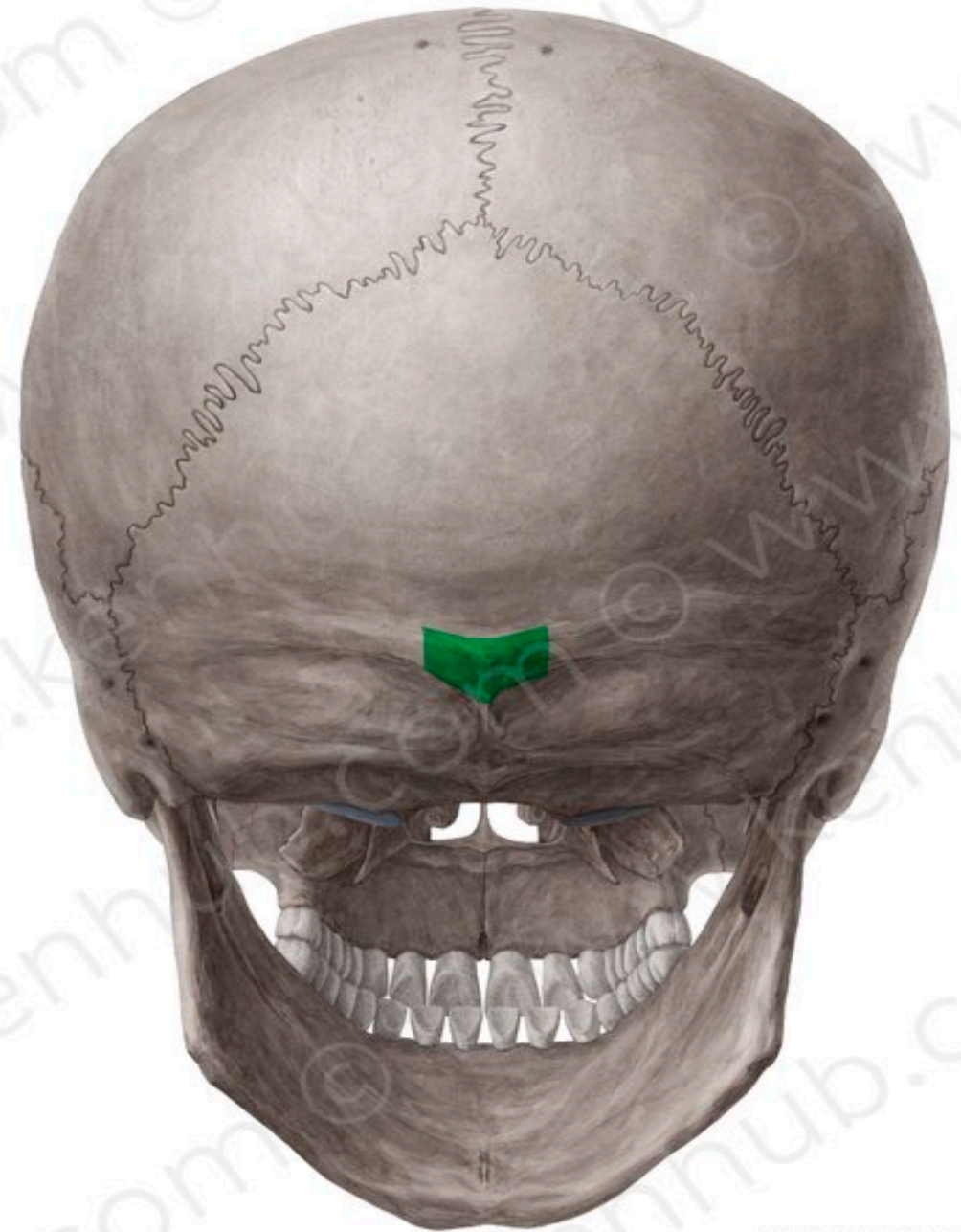Norma Occipitalis:

Special Features :

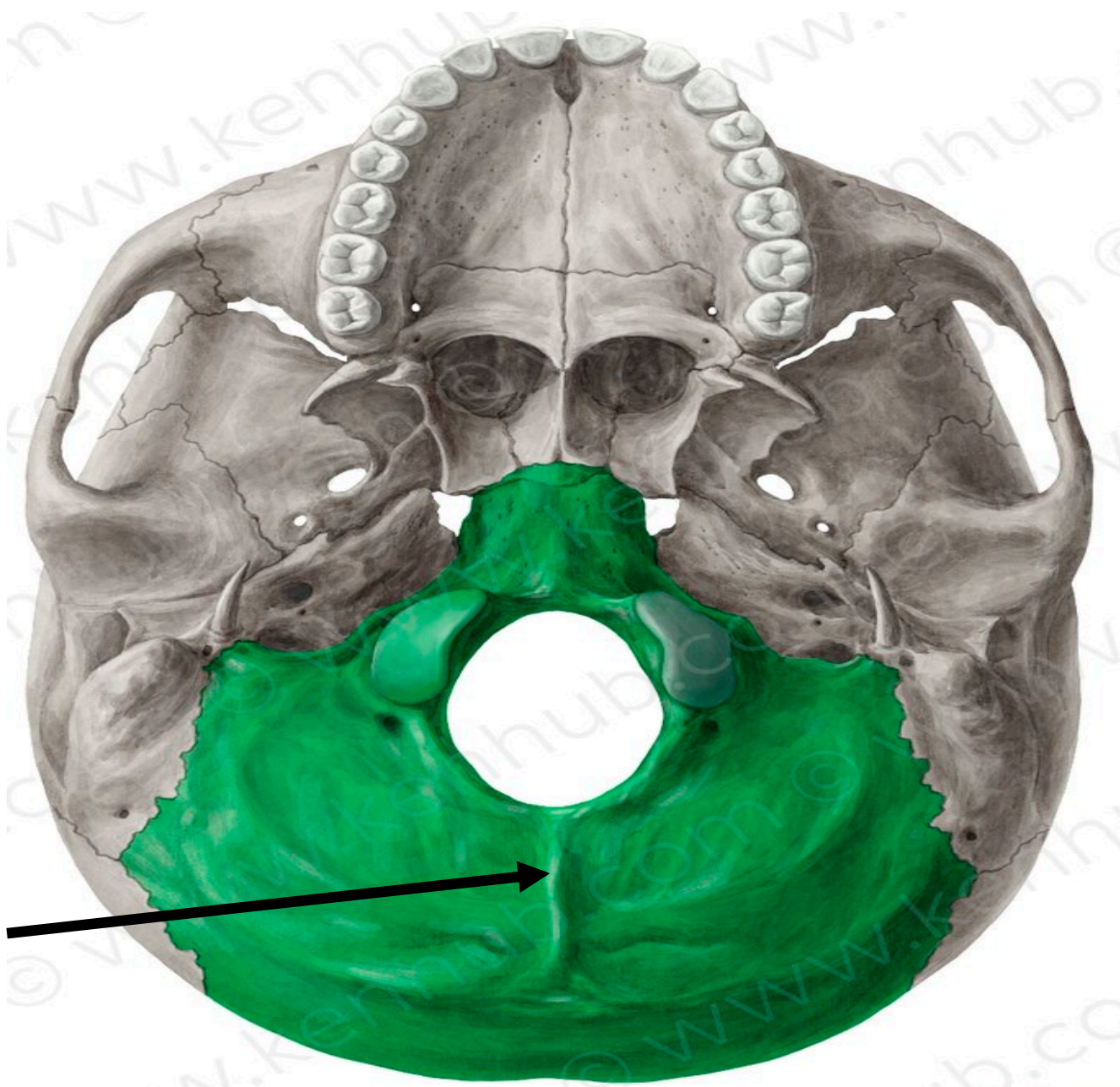
- External occipital protuberance: is a median elevation on the occipital bone.
- External occipital crest: extends from the protuberance to the foramen magnum.
- The superior nuchal lines : extend laterally from the protuberance.



Superior nuchal lines

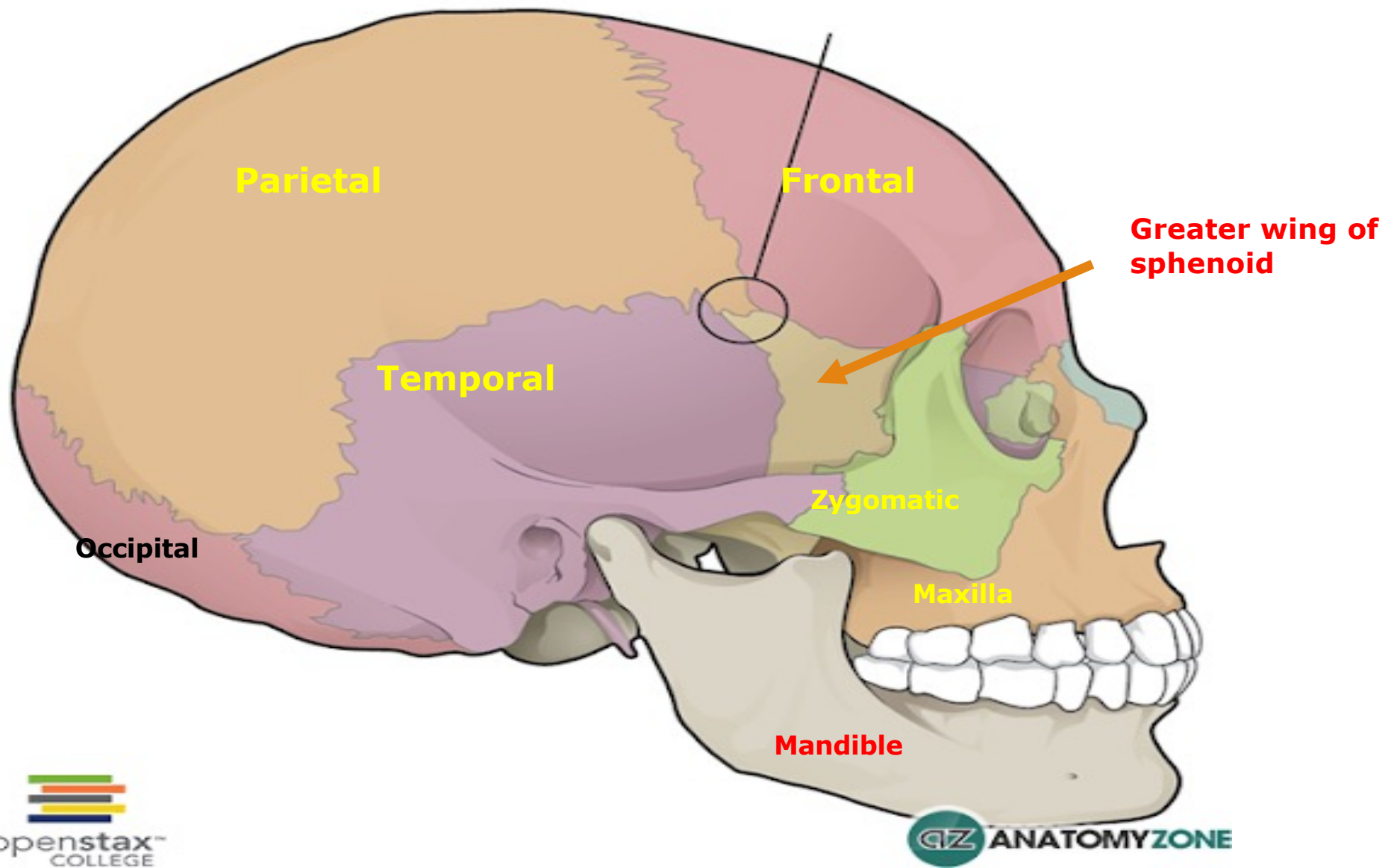


External occipital protuberance

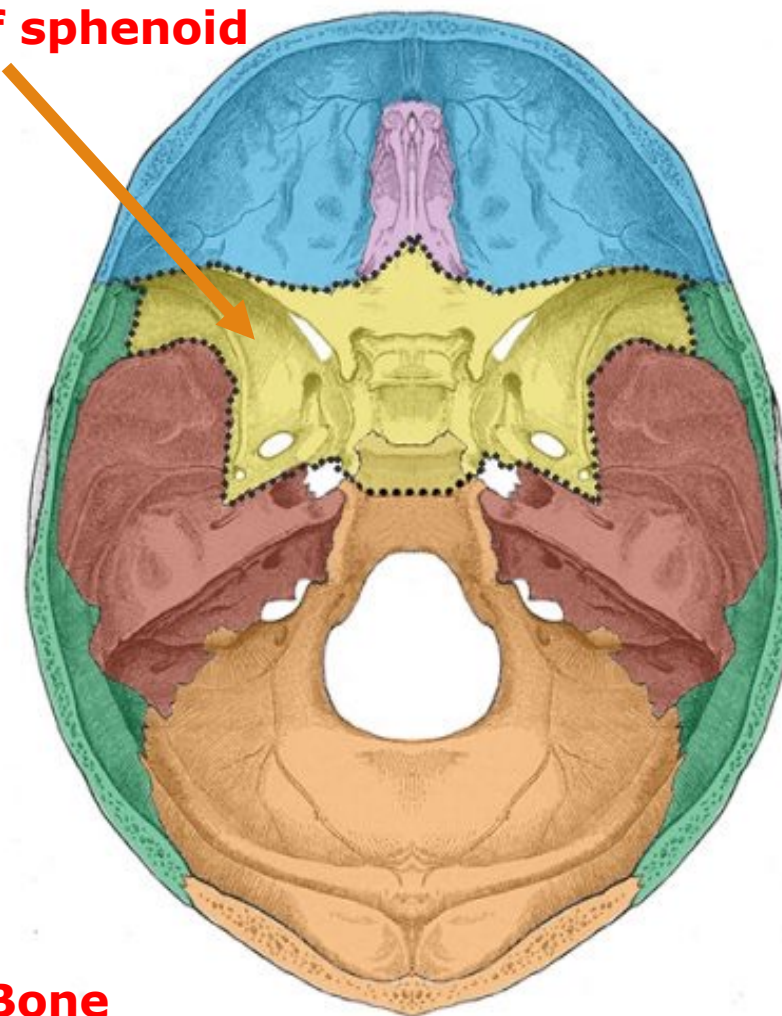
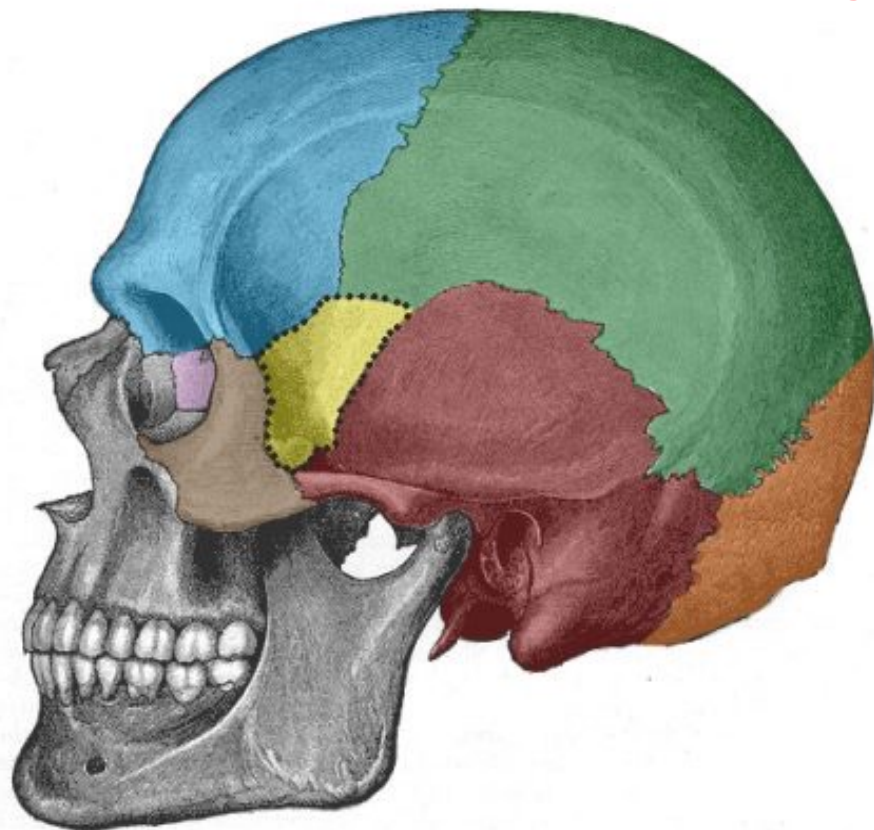


External
occipital crest

Norma Lateralis



Greater wing of sphenoid



- Frontal
- Ethmoid
- Sphenoid
- Temporal
- Parietal
- Occipital
- Zygomatic

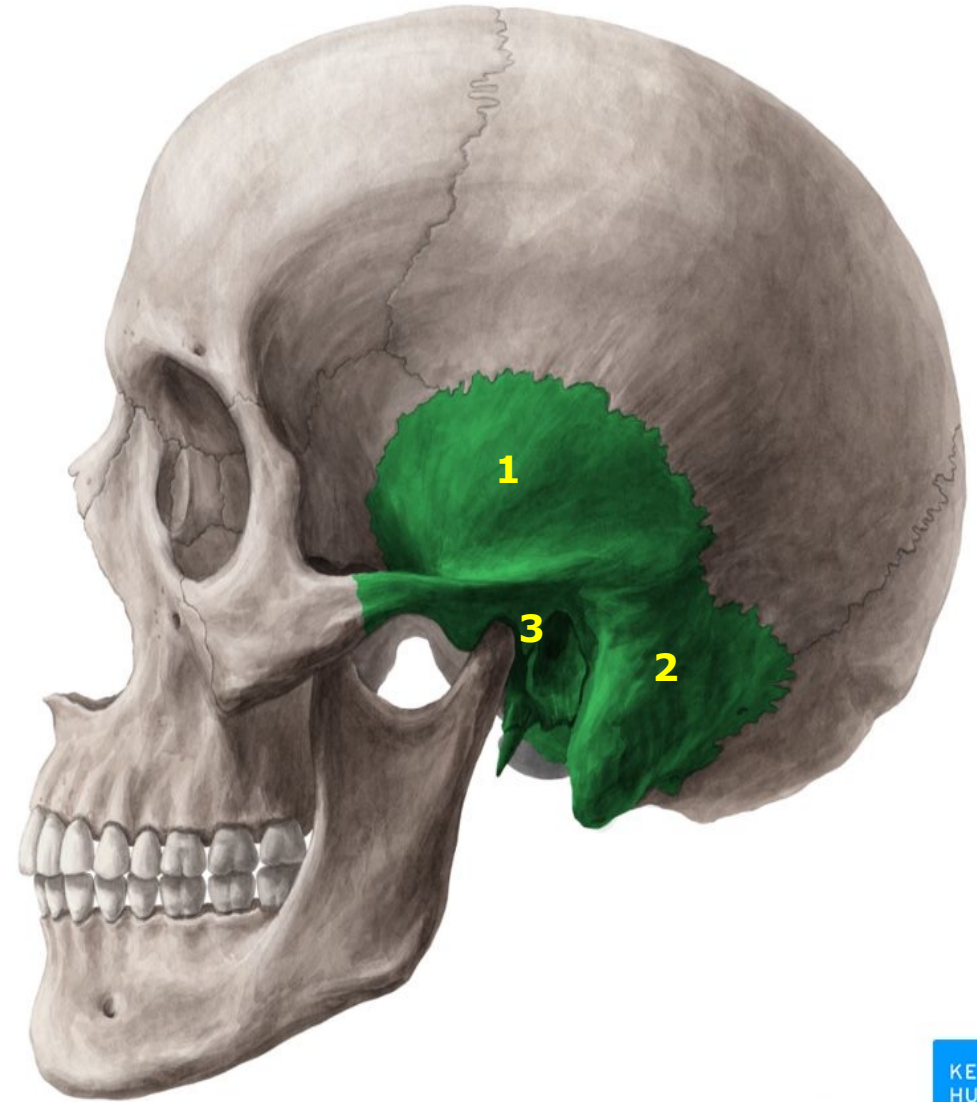
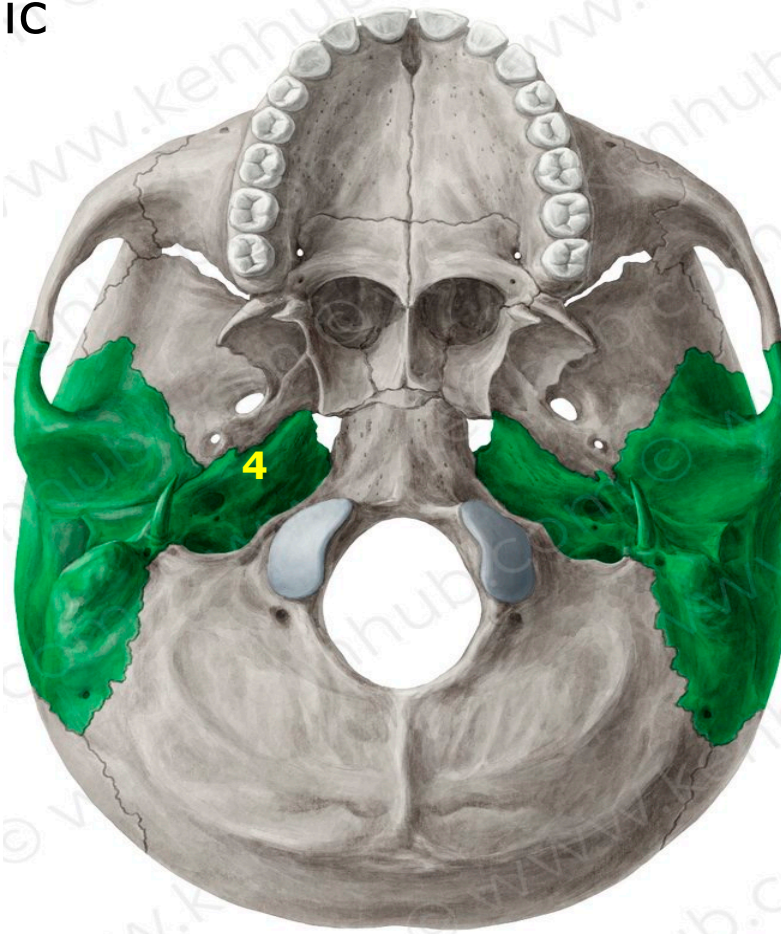
Sphenoid Bone

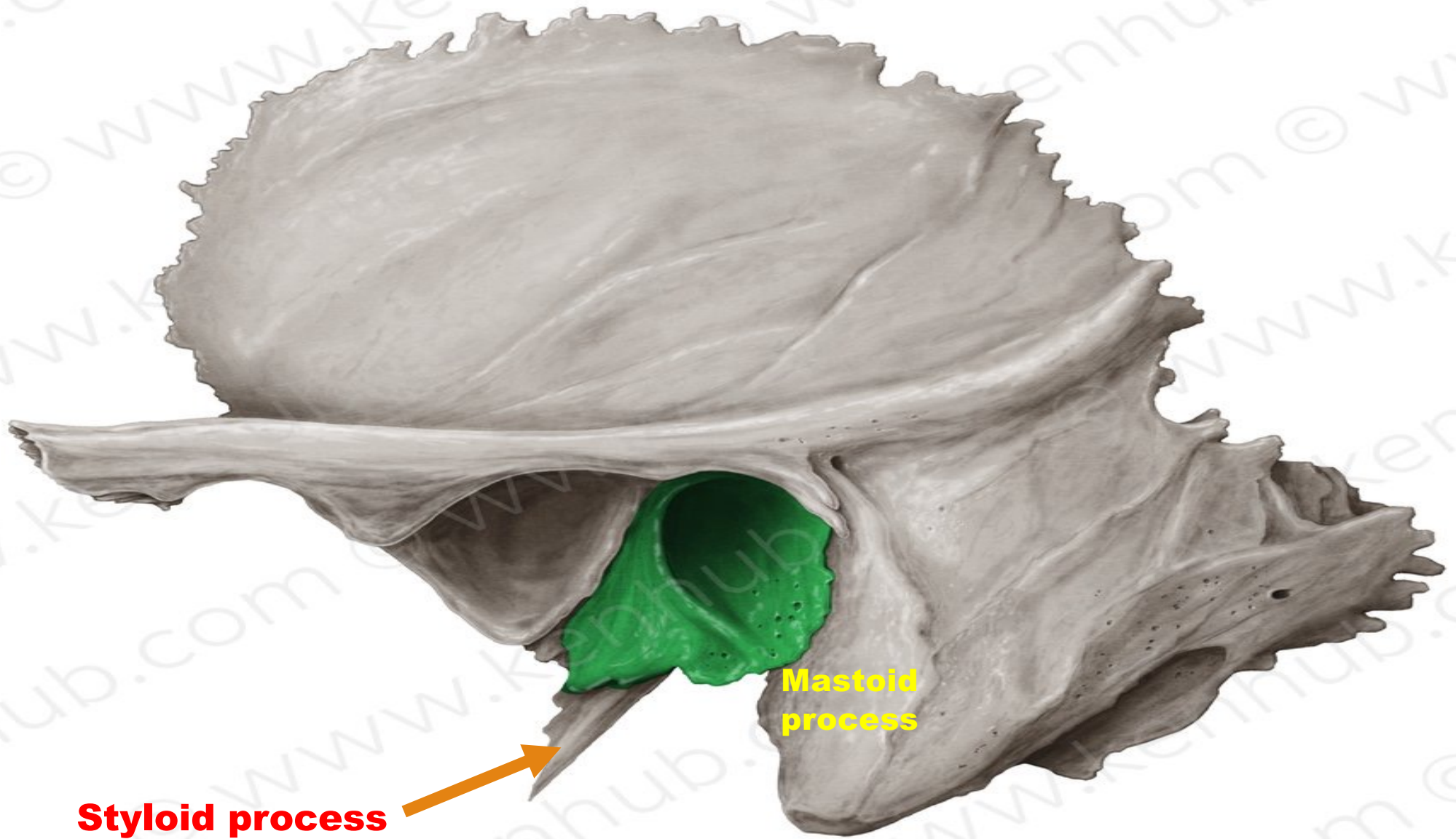
© TeachMeAnatomy_{inc}

Temporal bone

Is composed of 4 parts

1. Squamous
2. Mastoid
3. Tympanic
4. Petrous





Styloid process

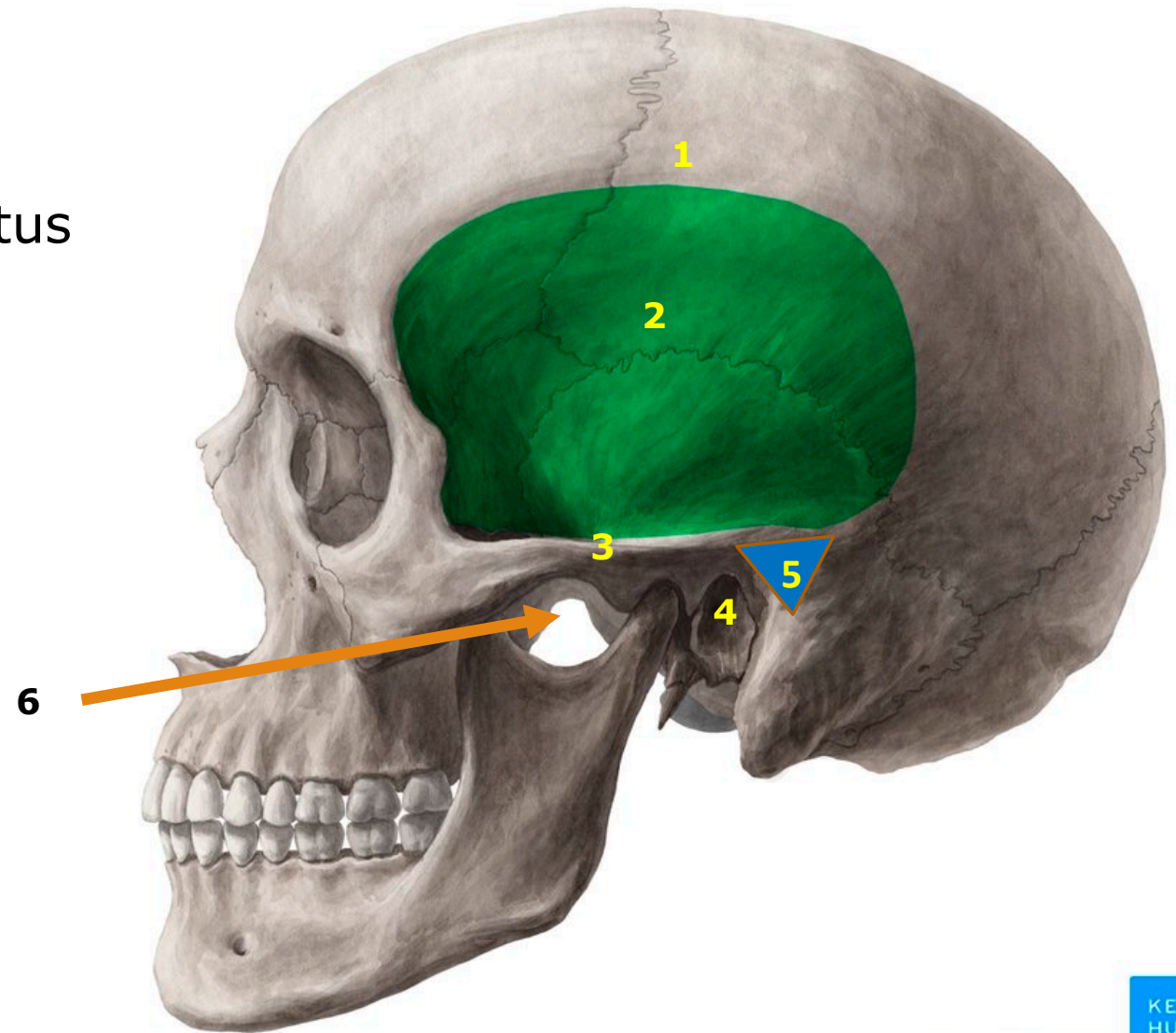
Mastoid process

Green area is Tympanic part of temporal bone

© www.kenhub.com

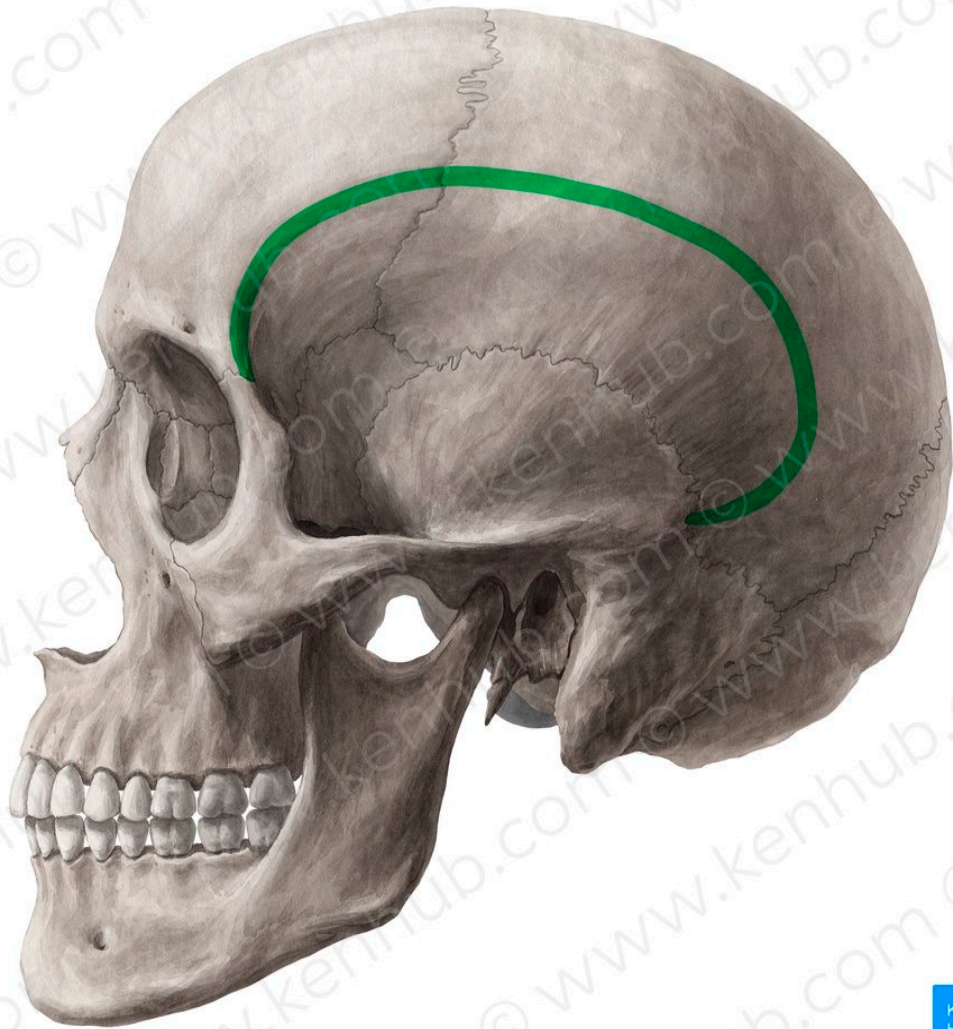

1. Temporal lines (superior and inferior)
2. Temporal fossa
3. Zygomatic arch
4. The External Auditory Meatus
5. Suprameatal triangle
6. Infratemporal fossa



© www.kenhub.com

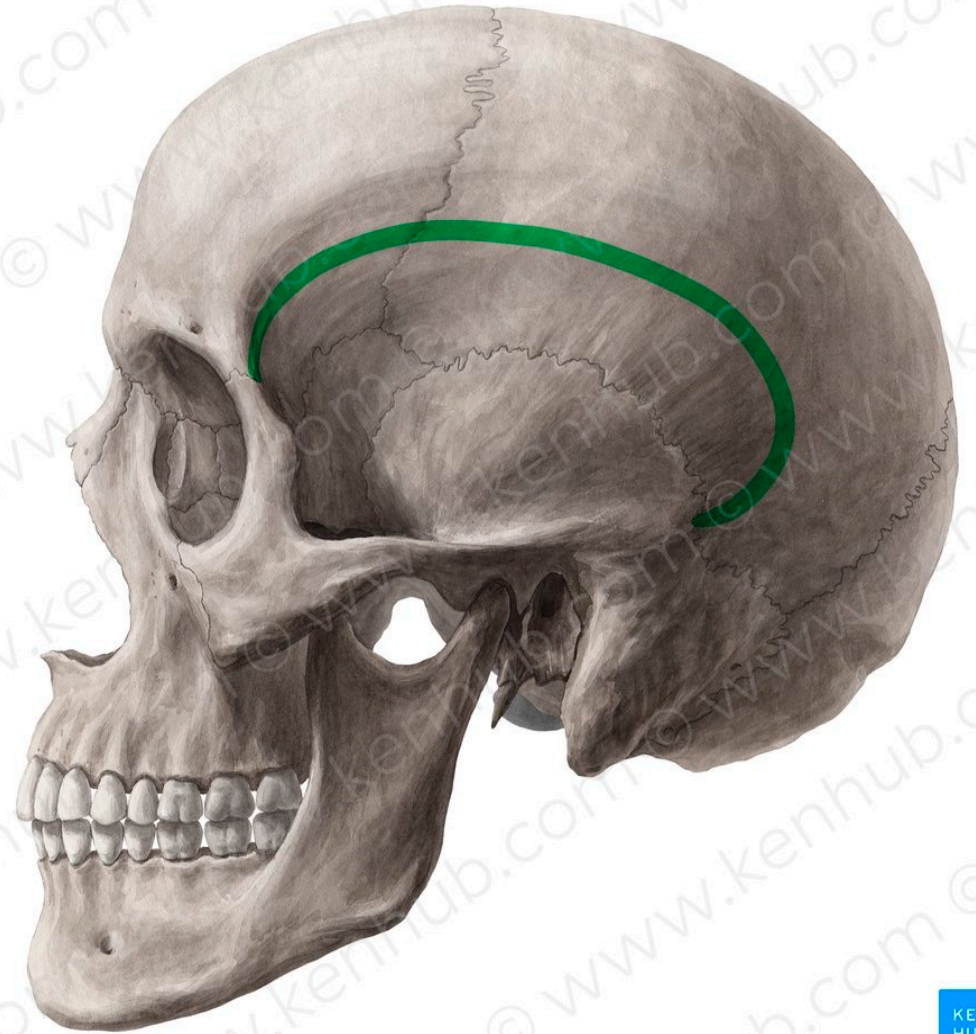




KEN
HUB

© www.kenhub.com

Superior temporal line



KEN
HUB

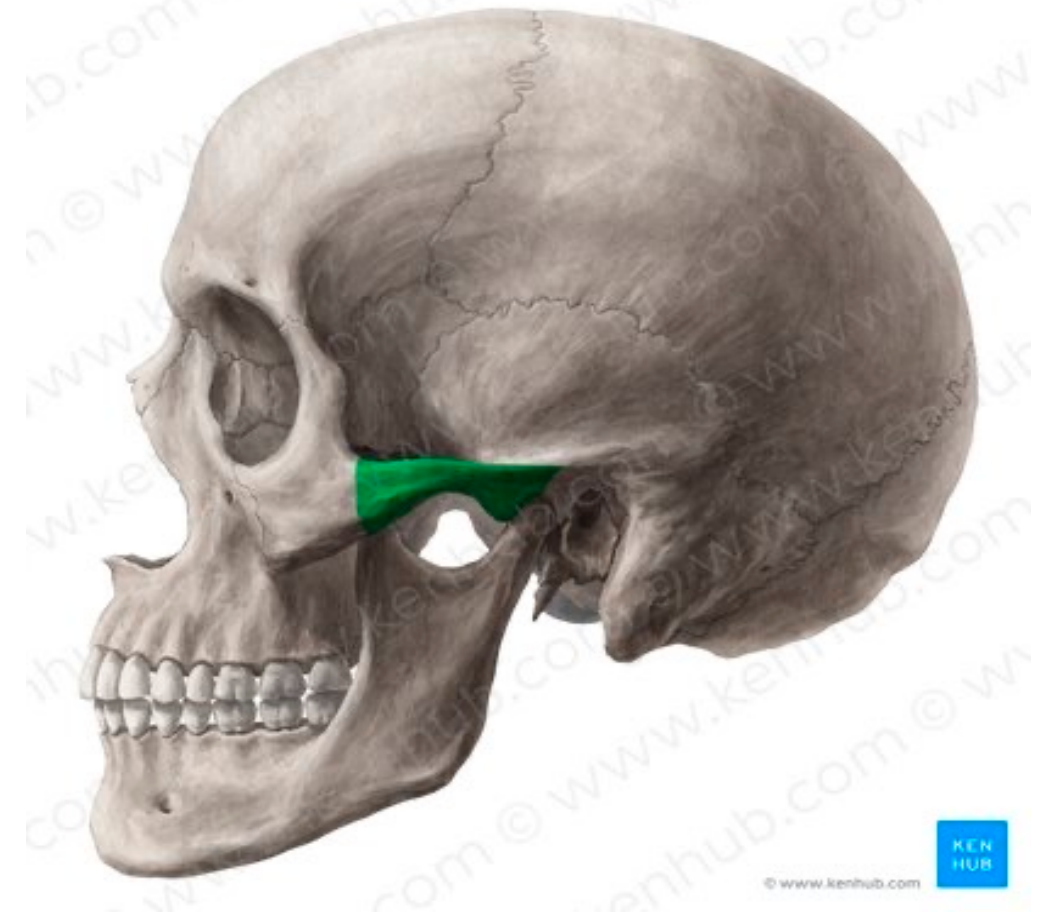© www.kenhub.com

Inferior temporal line

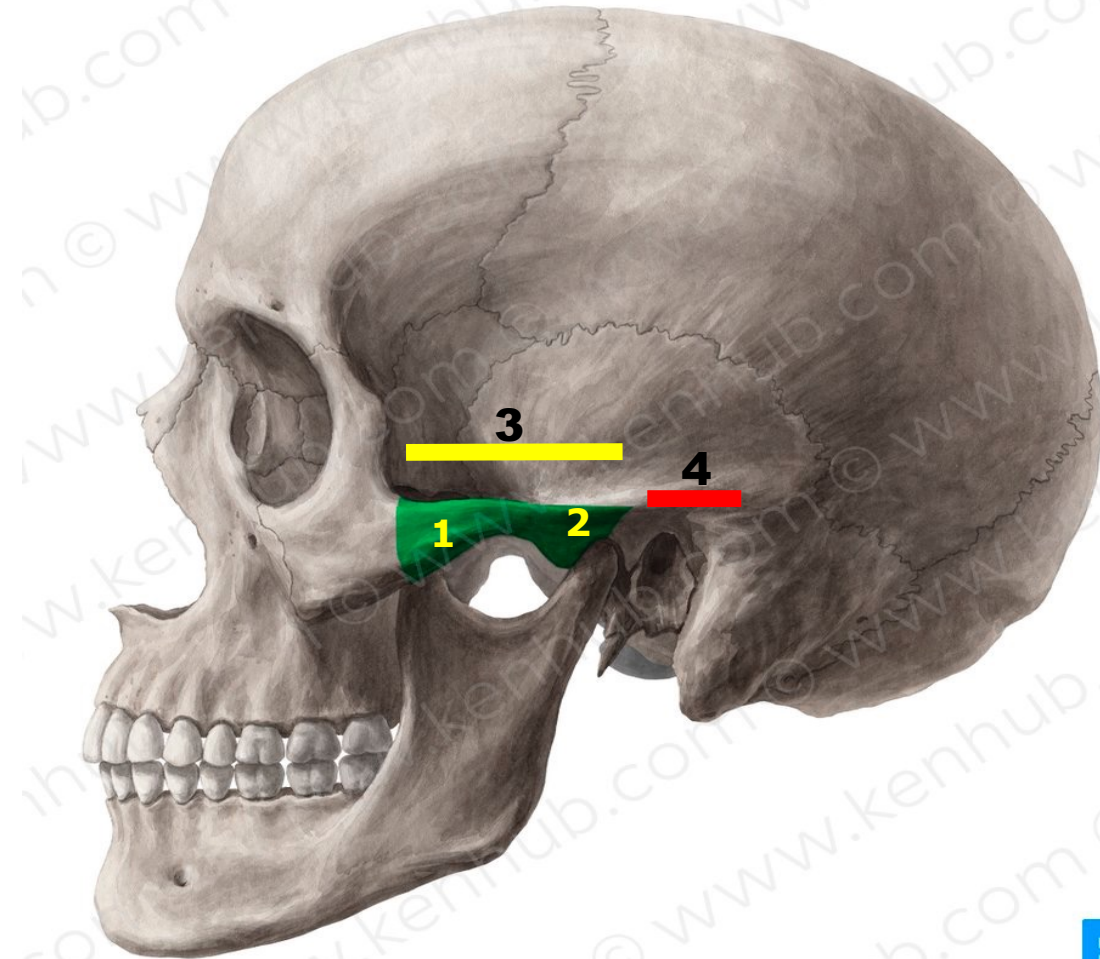
The Zygomatic Arch (Zygoma):

- It is formed by the temporal process of the zygomatic bone and the zygomatic process of temporal bone.

Its posterior root passes above the external auditory meatus and joins the supramastoid crest.



1. Temporal process of Zygomatic bone
2. Zygomatic process of temporal bone
3. Zygomatic arch
4. Supramastoid crest

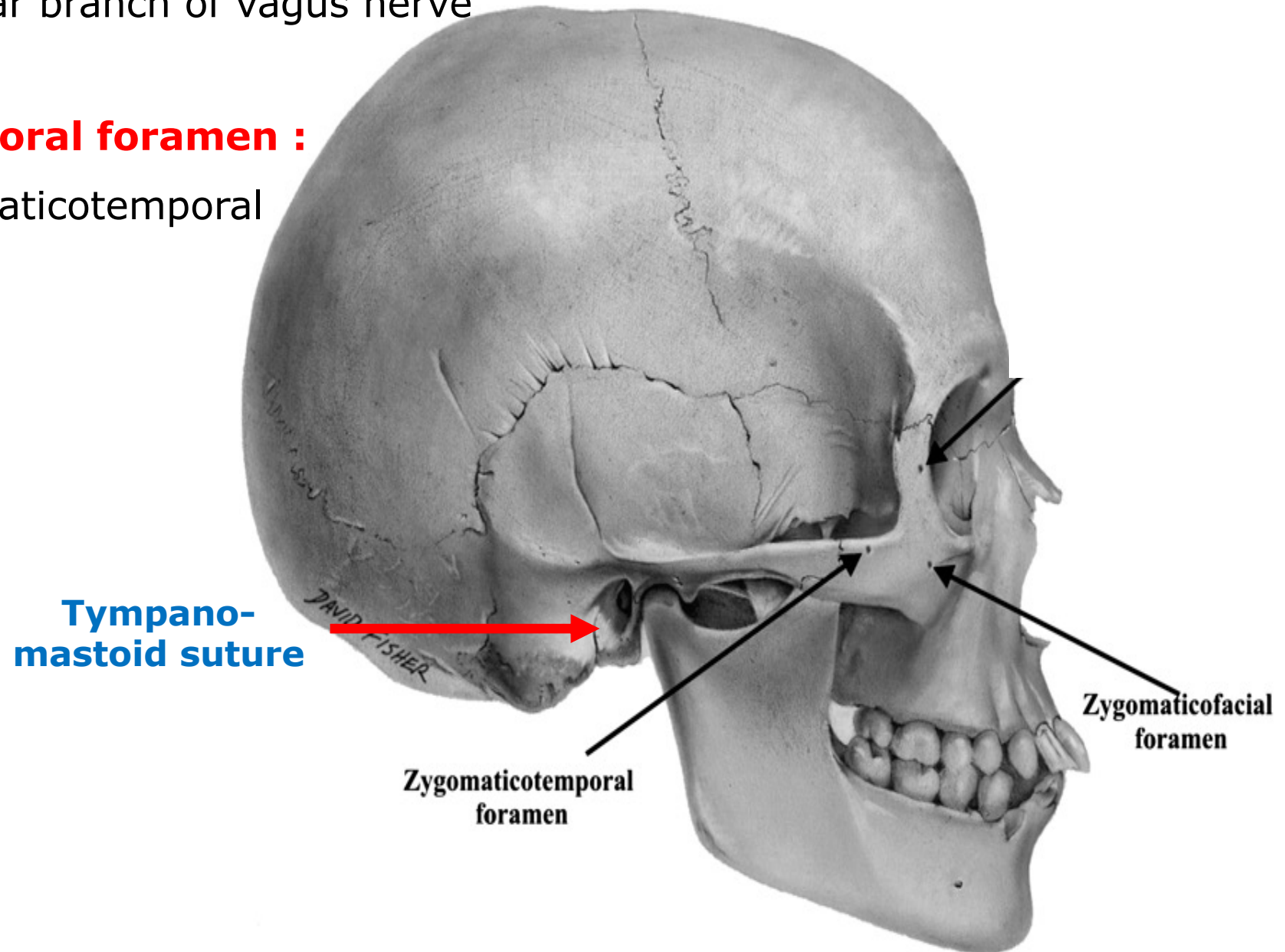


Tympano- mastoid suture :

It transmit auricular branch of vagus nerve

Zygomaticotemporal foramen :

It transmit zygomaticotemporal nerve



Suprameatal triangle or Macewen's triangle

Boundaries :

❖ **Superiorly:** Supramastoid crest.

❖ **Anterior-inferiorly:**

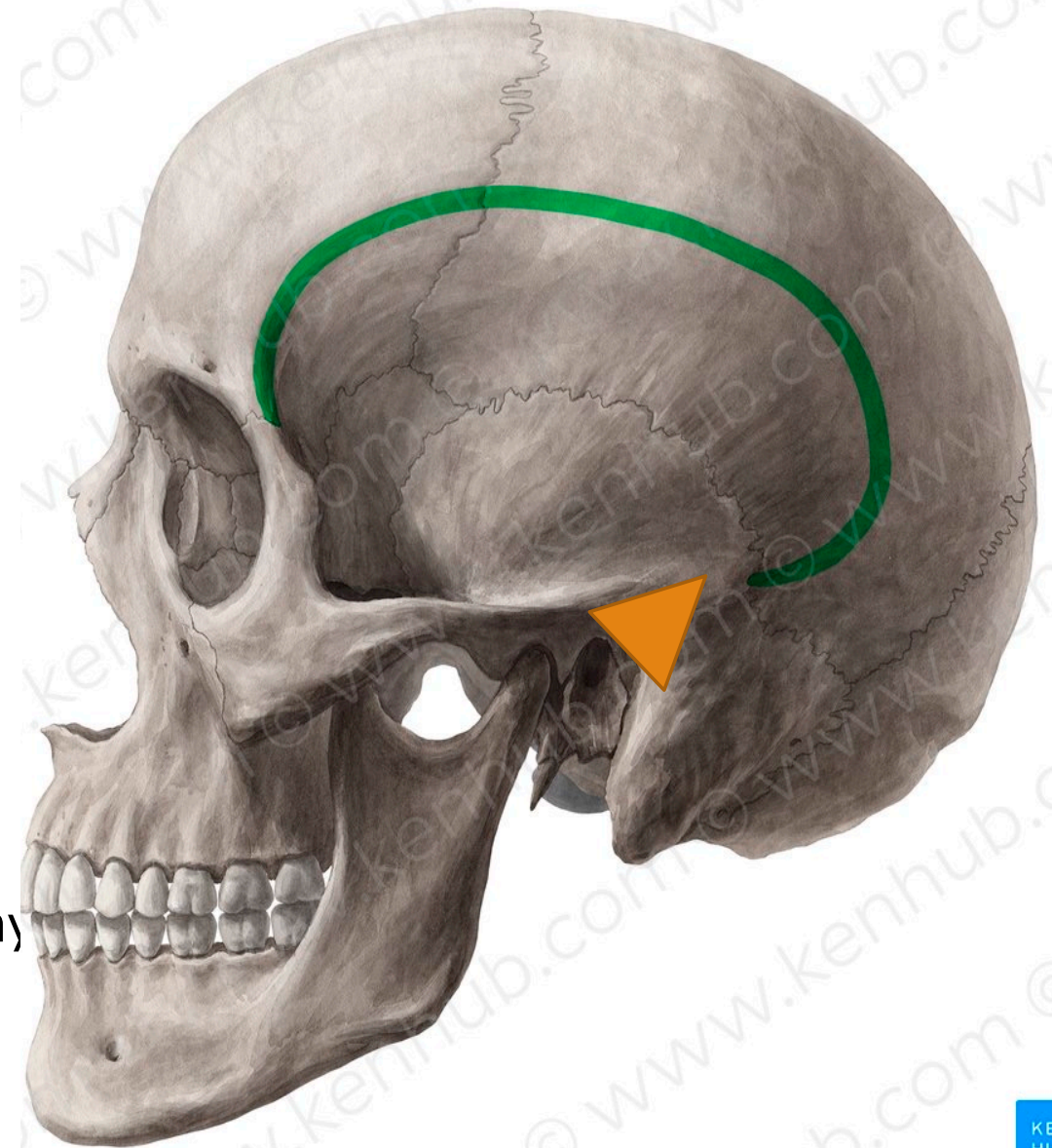
Posterior margin of external auditory meatus.

❖ **Posteriorly:**

A tangential line from the Posterior margin of external auditory meatus to the suprameatal crest.

Function :

This is an important landmark
For performing a cortical mastoidectomy

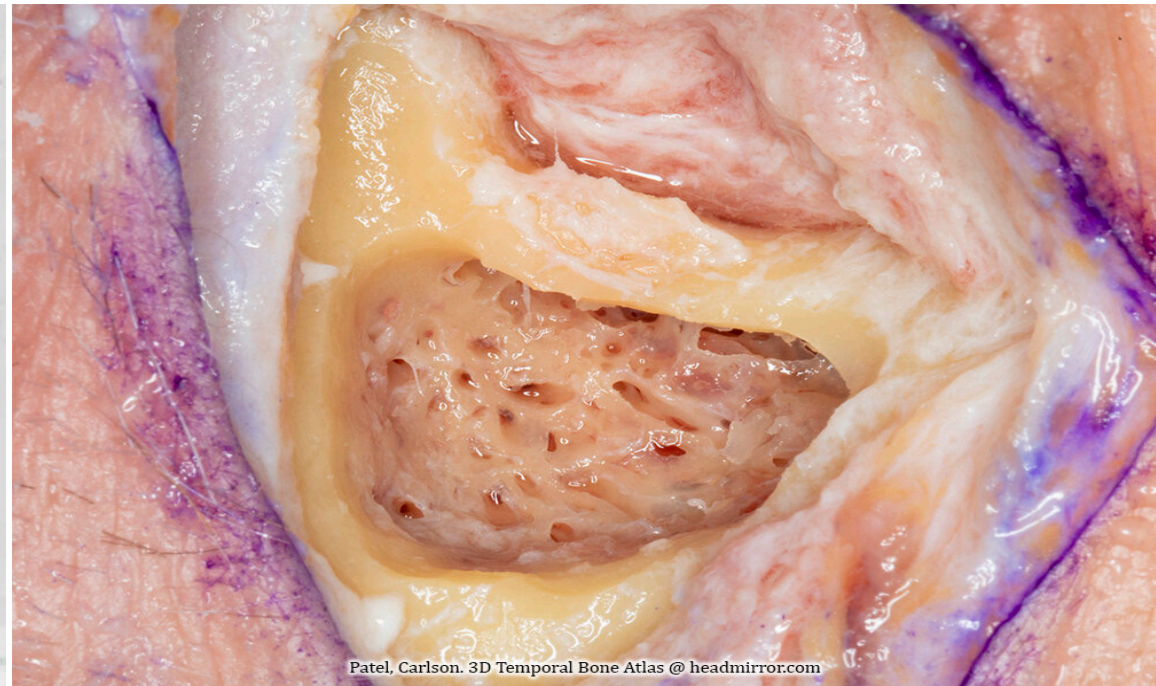
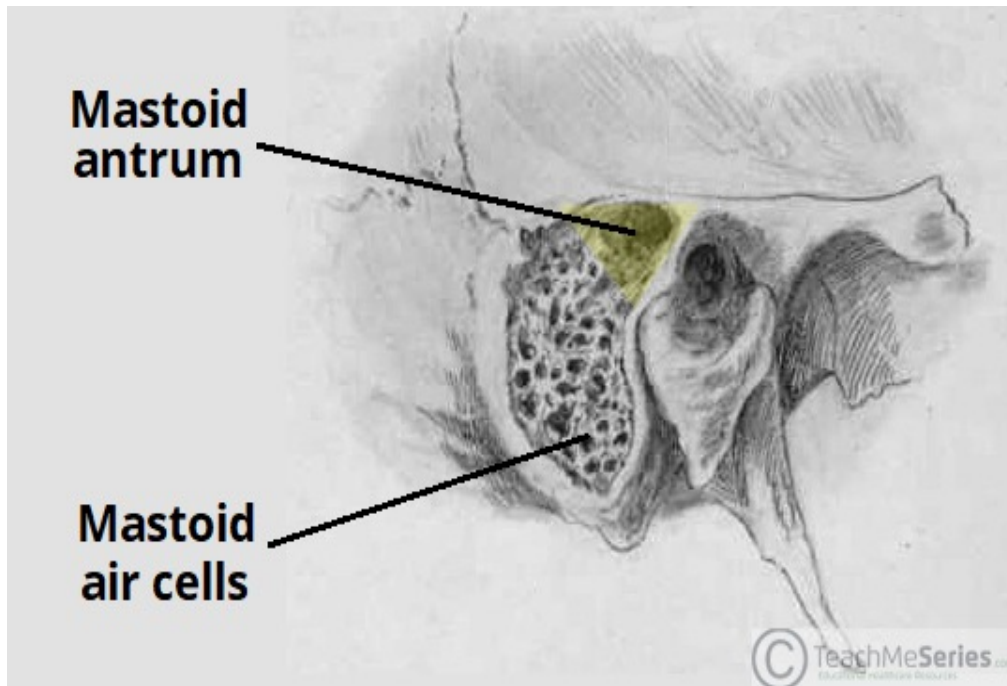


Mastoid antrum

is an air space in the petrous portion of the temporal bone, lying posterior to the middle ear and connected to it .

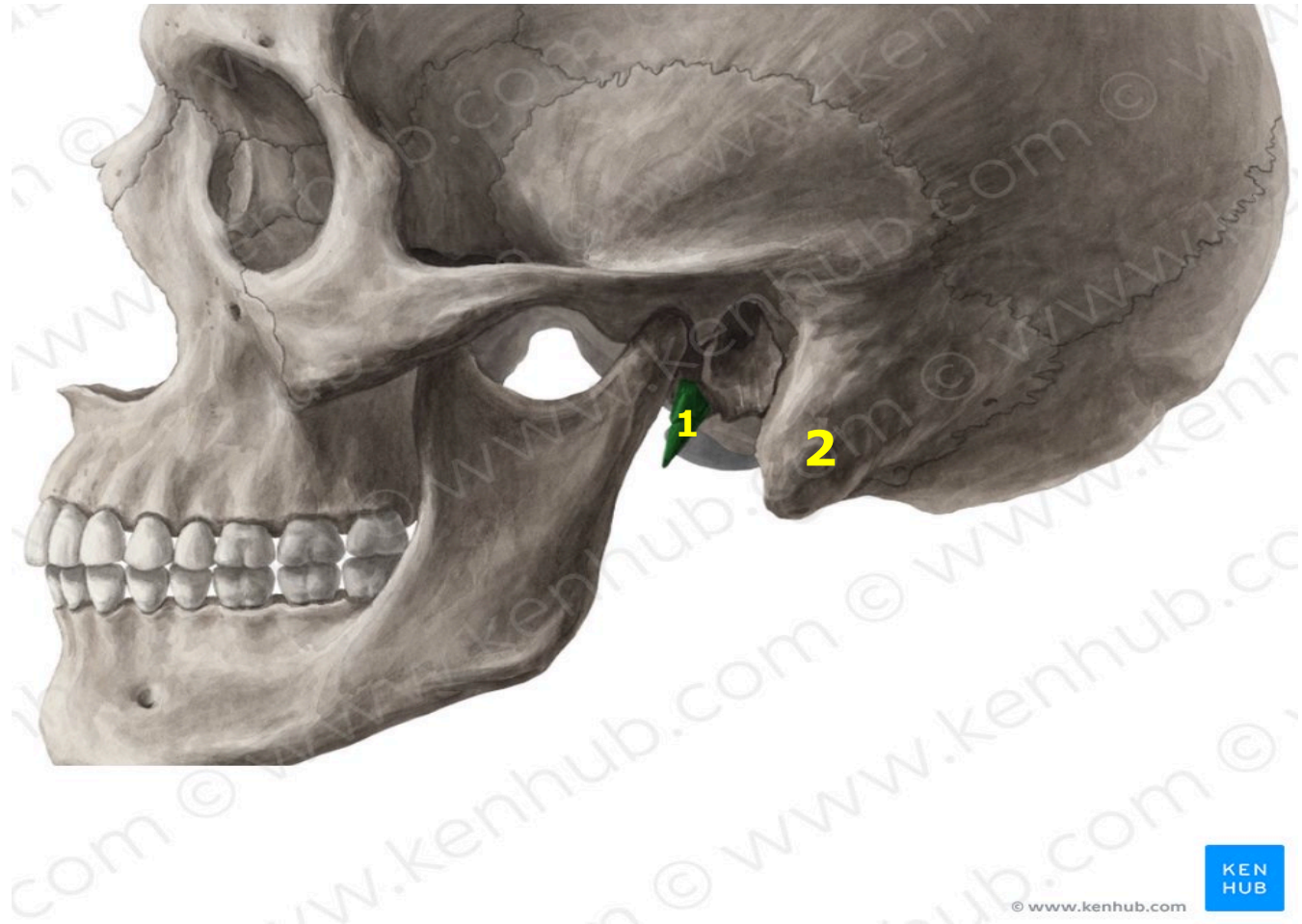
Function

voice resonance, acoustic insulation and reduce the mass of the cranium.



1- Styloid process

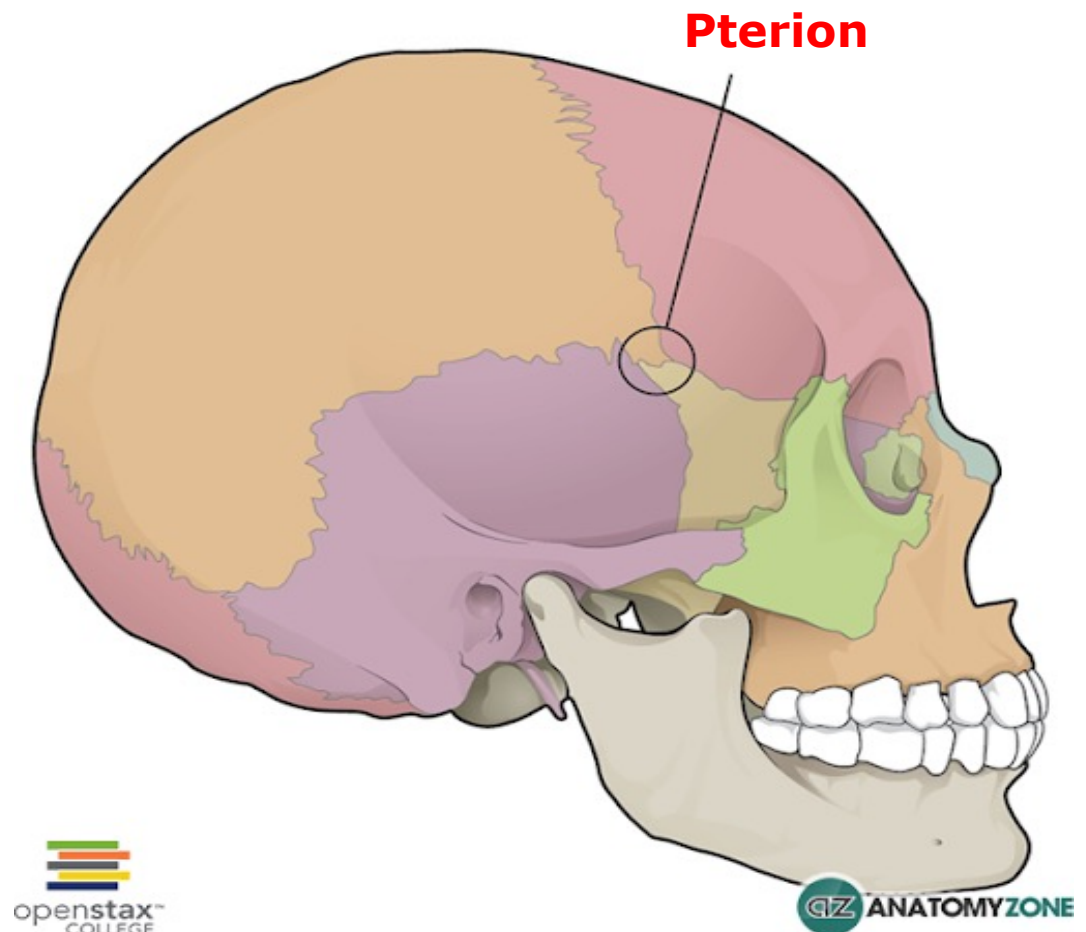
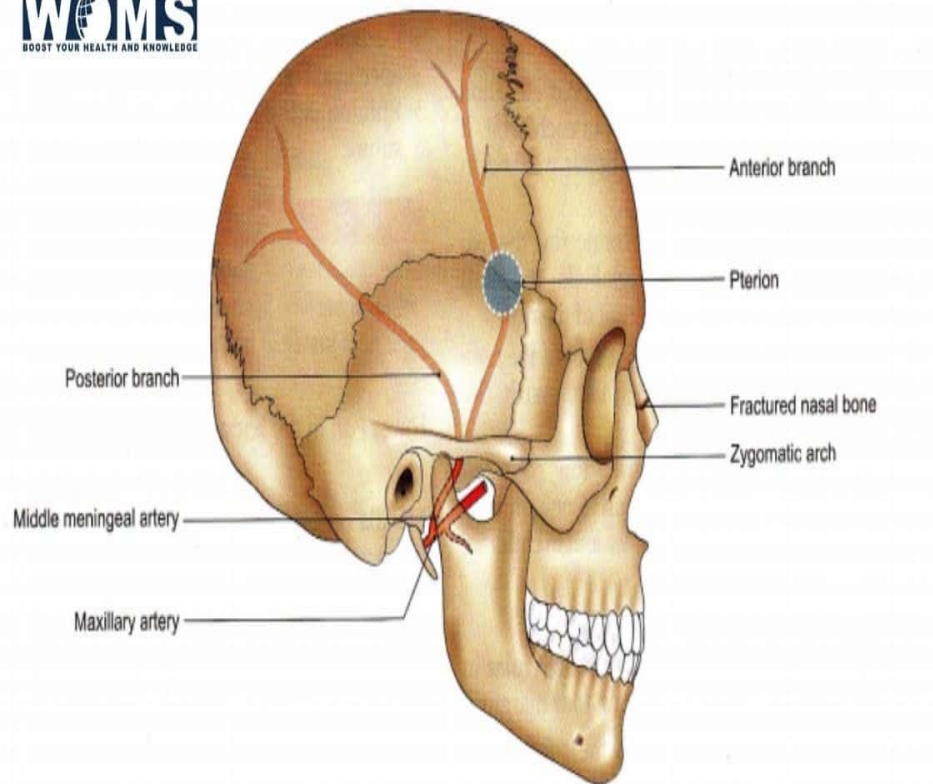
2- Mastoid process



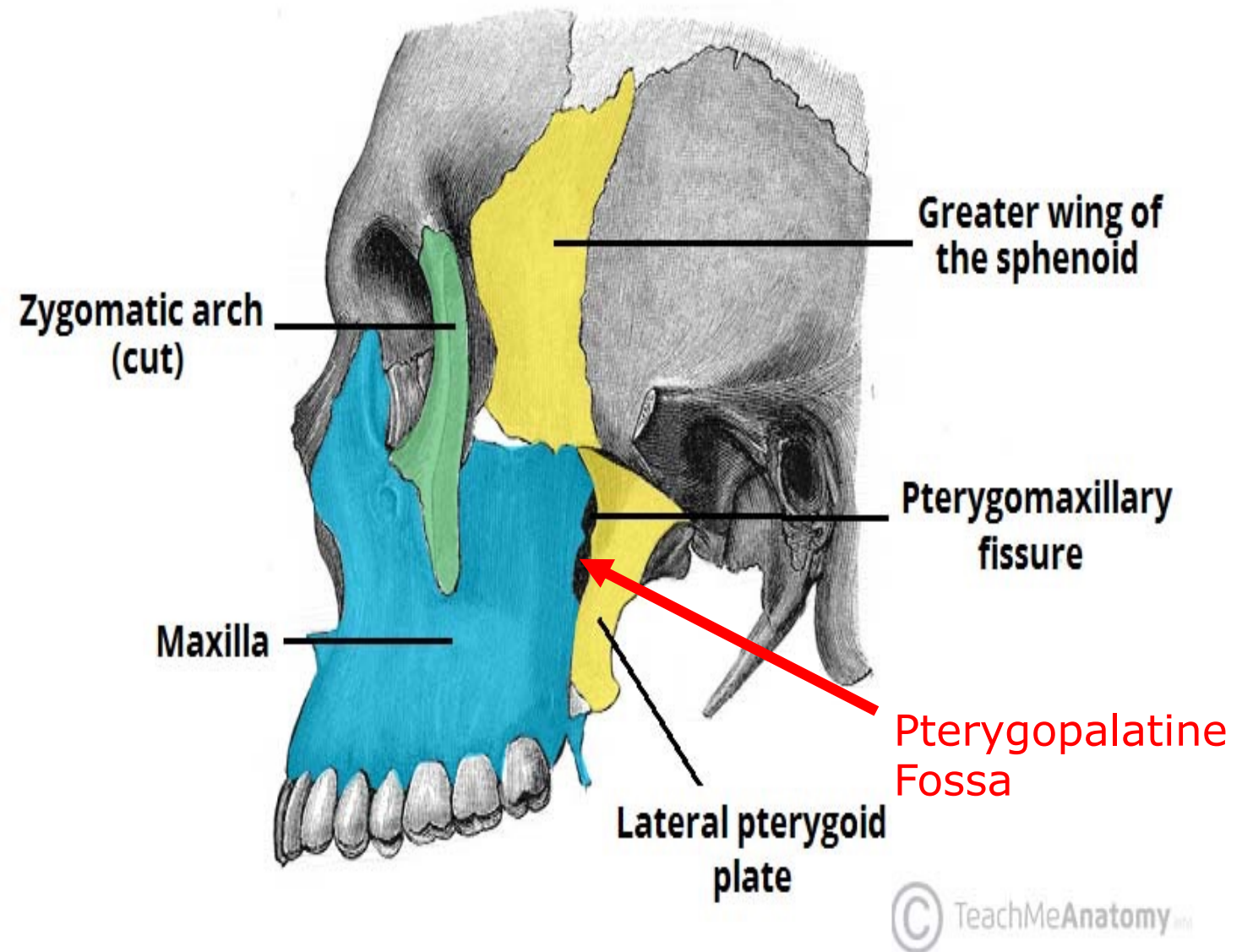
Pterion

It is H-shaped suture represent the meeting of frontal, parietal, squamous temporal and the greater wing of the sphenoid bones

It overlies the intracranial course of the frontal branch of the middle meningeal Artery



Pterygomaxillary fissure : It connects infratemporal fossa with Pterygopalatine Fossa



THANK YOU