

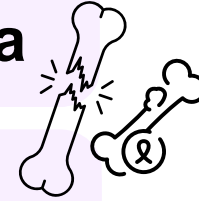
بِسْمِ اللَّهِ الرَّحْمَنِ الرَّحِيمِ

MID | Lecture 3

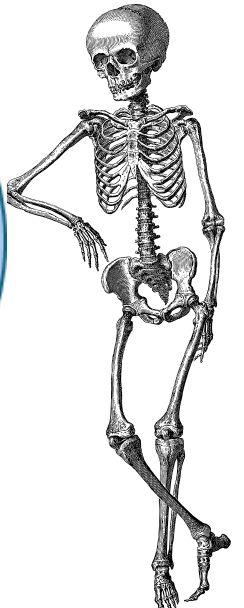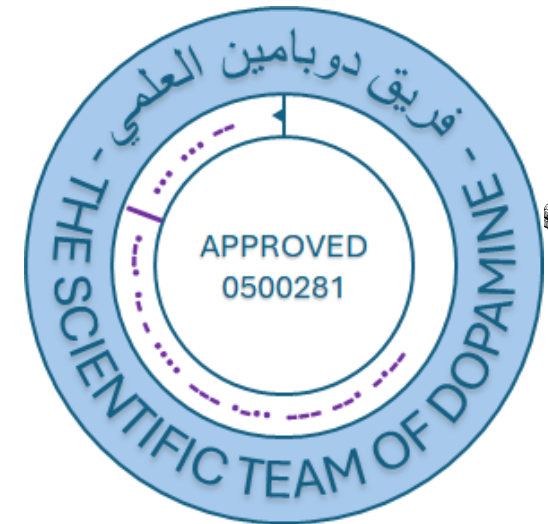# MSS & Skin Tumors (pt.3)

Written by: Ahmad Darwish  
Abd Al Rahman Musa

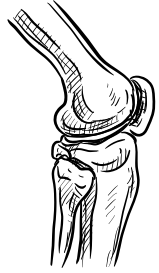Reviewed by: Mahmoud Aljunaidi



وَإِن تَتَوَلَّوْا يَسْتَبَدِلْ قَوْمًا غَيْرَكُمْ ثُمَّ لَا يَكُونُوا أَمْثَلَكُمْ  
اللهم استعملنا ولا تستبدلنا



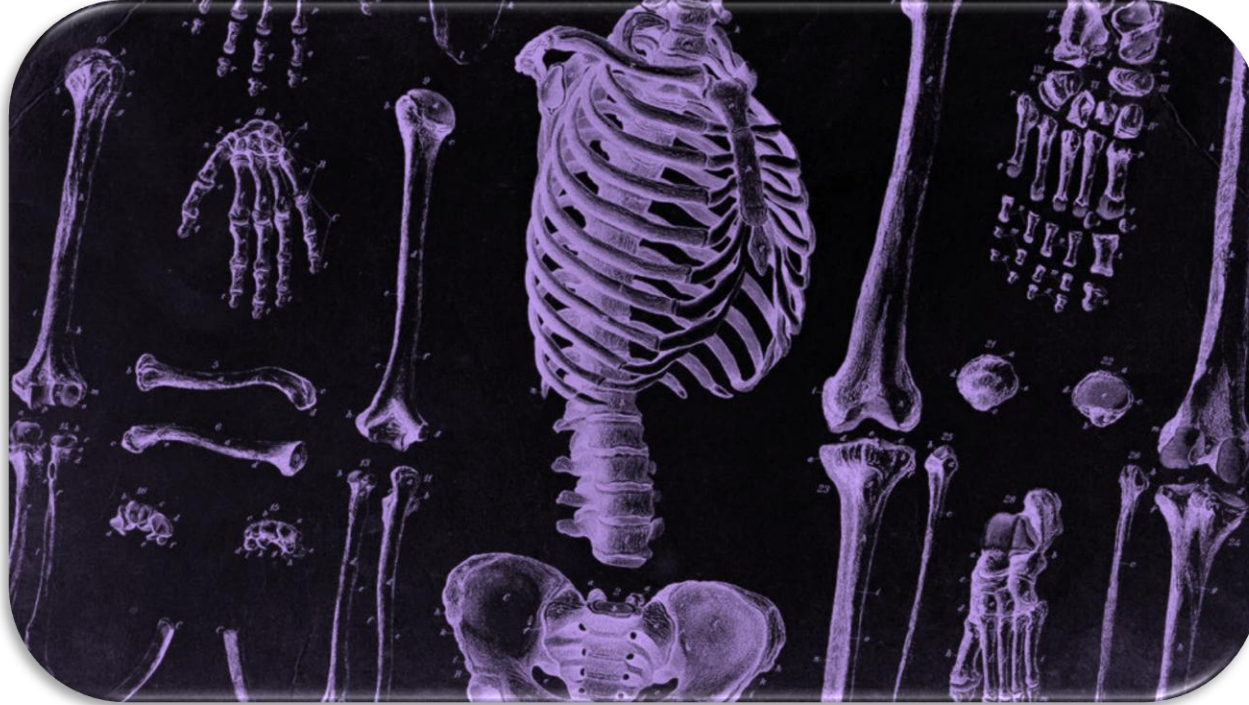رَمَضَانَ مُبَارَكٌ



PATHOLOGY



# Quiz on the previous lecture

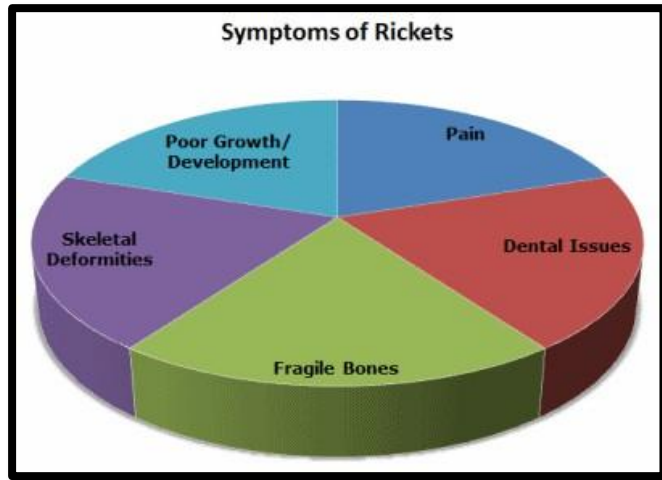


السلام عليكم ورحمة الله وبركاته يعطيكم العافية جميعاً، من باب تغيير الجو، وضعنا لعبة مخفية بالملف، في كلمة مكونة من عدد من الأحرف لازم تسلموها.  
طريقة اللعب: اكتشفوها بأنفسكم.

لضمان إنه ما حد يسحب عالمحاضرة، بعض الخطوات لا تُحل إلا إذا كنت فاهم المحاضرة، لتسليم الإجابة: اكبس على ملك الغابة ( يفضل تكبس عليه قبل ما تبدأ ) .

# Continuation of the metabolic disorders of the bone from lecture 2:

## RICKETS OSTEOMALACIA



- **Vitamin D deficiency or abnormal metabolism of vitamin D.**
- **Children: Rickets**
- **Adults: osteomalacia**
- **Decreased mineralization of bone, unmineralized matrix.**
- **Increase risk of fractures.**

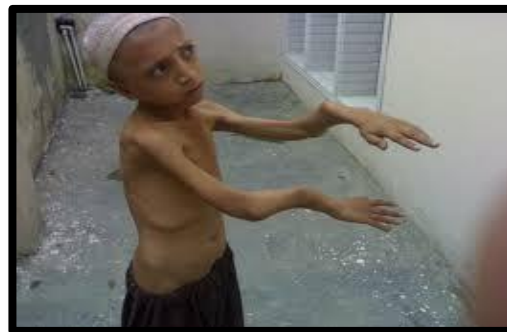Rickets and osteomalacia share the same primary cause but differ in terms of the affected population. Rickets affects children, while osteomalacia affects adults.

# Rickets & Osteomalacia:

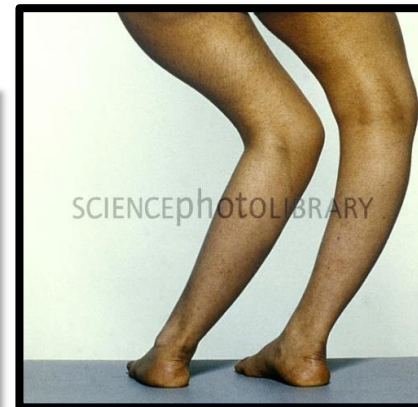- Rickets and Osteomalacia are both rare disorders that occur due to deficiency of vitamin D, that is either caused by:
  1. Insufficient intake of vitamin D.

OR

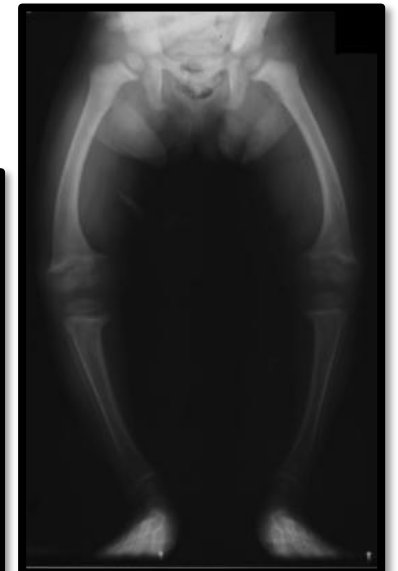  2. Abnormal metabolism of vitamin D.
- Vitamin D deficiency causes **decreased** mineralization of bone and an accumulation of unmineralized matrix, leading to the symptoms of rickets and osteomalacia, such as:
  1. Increased risk of fractures (fragile bone).
  2. Weakness of the bones which causes bowed bones in the legs (1) and arms (2).
- The prevalence of Rickets and osteomalacia has become very low recently, due to the availability of vitamin D supplements.



(2)



(1)



# HYPERPARATHYROIDISM (HPT) (Common metabolic disorder)

## Hyperparathyroidism classification

*Different causes and features of hyperparathyroidism - raised parathormone (PTH).*

The pathogenesis of tertiary HPT is complicated, the Dr said just memorize the features...

Types of HPT:	primary	secondary	tertiary
<b>pathology</b>	Hyperfunction of parathyroid cells due to hyperplasia, adenoma or carcinoma. (1)	Physiological stimulation of parathyroid in response to hypocalcaemia. (3)	Following long term physiological stimulation leading to hyperplasia.
<b>associations</b>	May be associated with multiple endocrine neoplasia.	Usually due to chronic renal failure or other causes of Vitamin D deficiency.	Seen in chronic renal failure.
<b>serum calcium</b>	high	low / normal	high
<b>serum phosphate</b>	low / normal	high	high
<b>management</b>	Usually surgery if symptomatic. Cinacalcet can be considered in those not fit for surgery. (2)	Treatment of underlying cause.	Usually cinacalcet or surgery in those that don't respond.

NICE have issued guidance for the use of cinacalcet in what they call refractory secondary hyperparathyroidism which is classified as tertiary hyperparathyroidism in this table. <http://www.nice.org.uk/TA117>

- Cinacalcet is a drug that lowers PTH levels.

tblable.com

The points labeled with numbers are further explained in the next slide.....

# HYPERPARATHYROIDISM (HPT)

## Primary HPT (most common type of HPT):

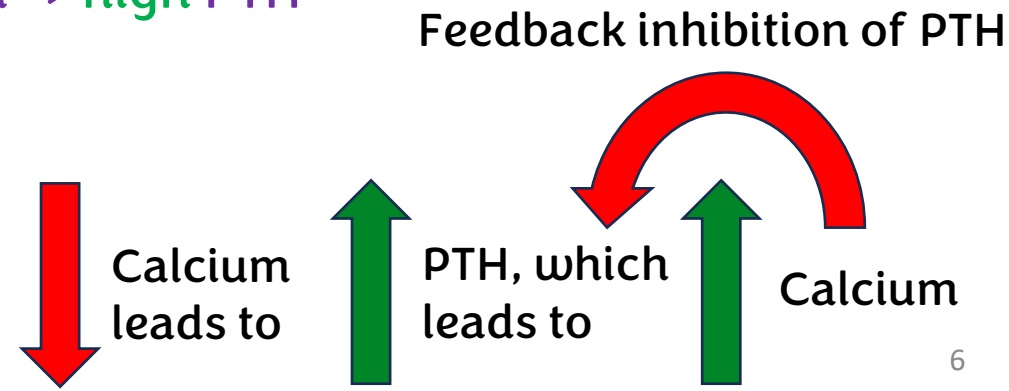
- 1) Hyperplasia, adenoma or carcinoma of parathyroid cells leads to hyperfunction and over secretion of parathyroid hormone, leading to **high** Calcium and **low/normal** phosphorus levels. Also, the altered parathyroid cells **stop** responding to the feedback inhibition response of the parathyroid hormone caused by **hypercalcemia**.
  - In normal conditions, hypercalcemia **decreases** parathyroid hormone release.
- 2) By surgery we mean surgical removal of overactive parathyroid glands.

## Secondary HPT:

- 3) Secondary HPT is due to **chronic** hypocalcemia, which can be caused by:
    1. Chronic renal failure (over excretion of calcium in the urine).
    2. Vit.D deficiency.
- Remember, **high** calcium -> **low** PTH/ **low** calcium -> **high** PTH

*A patient presents with **high PTH** and **high serum calcium**. Despite treatment of the underlying cause, PTH remains persistently elevated, and serum phosphate is also elevated. Based on the classification in the table, what is the most likely final stage of the disease progression?*

You will need the answer :)



# HPT clinically

Clinically, Patients with HPT can present with:

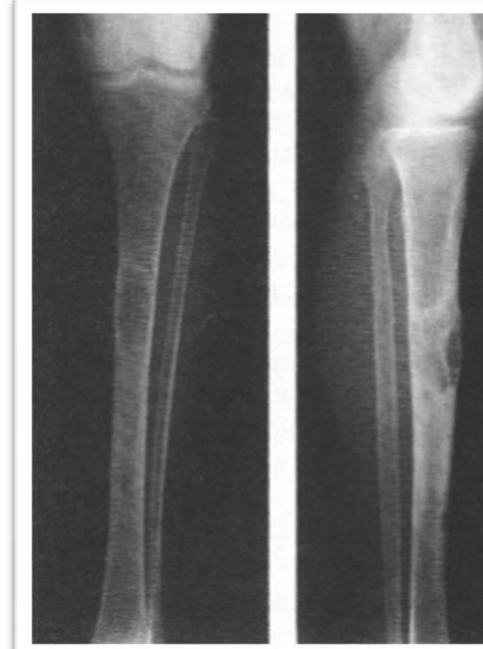1- Osteoporosis causing the weakening of the bone.

2- Brown tumors, due to osteoporosis, which can cause fractures and bleeding. This bleeding becomes contained in a localized area known as a brown tumor.

- A brown tumor is not a true tumor; it is a collection of hematomas (closed wounds where blood collects) and cystic spaces (abnormal fluid-filled sacs) – see picture.

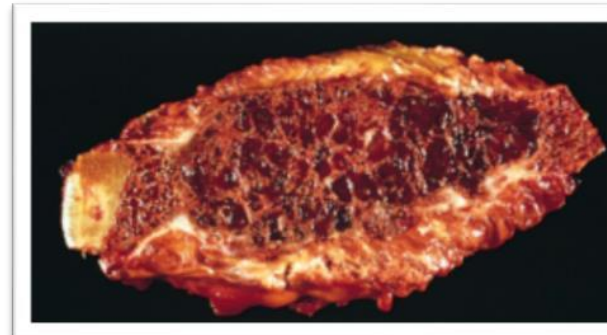
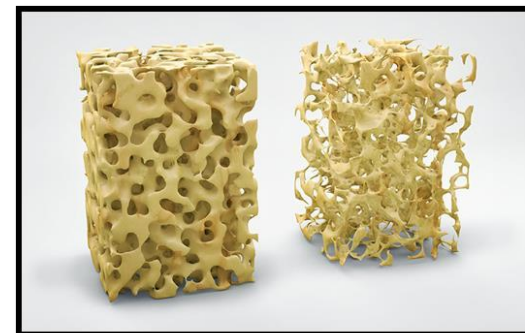
3- In *severe* cases of HPT, OSTEITIS FIBROSA CYSTICA can occur either locally or generally. This rare clinical presentation is characterized by severe osteoporosis and microcystic structures on bones.

## OSTEITIS FIBROSA CYSTICA



Abbreviated OFC, also known as osteitis fibrosa, osteodystrophia fibrosa, and von Recklinghausen's disease of bone (not to be confused with von Recklinghausen's disease, neurofibromatosis type I) – *not an -itis*.

## OSTEOPOROSIS



## BROWN TUMOR



## Summary

### Metabolic Disorders of Bone

- **Osteopenia** and **osteoporosis** represent histologically normal bone that is decreased in quantity. In osteoporosis the bone loss is sufficiently severe to significantly increase the risk of fracture. The disease is very common, with marked morbidity and mortality from fractures. Multiple factors including peak bone mass, age, activity, genetics, nutrition, and hormonal influences contribute to its pathogenesis.
- **Osteomalacia** is characterized by bone that is insufficiently mineralized. In the developing skeleton, the manifestations are characterized by a condition known as **rickets**.
- **Hyperparathyroidism** arises from either autonomous or compensatory hypersecretion of PTH and can lead to **osteoporosis**, **brown tumors**, and **osteitis fibrosa cystica**. However, in developed countries, where early diagnosis is the norm, these manifestations are rarely seen.

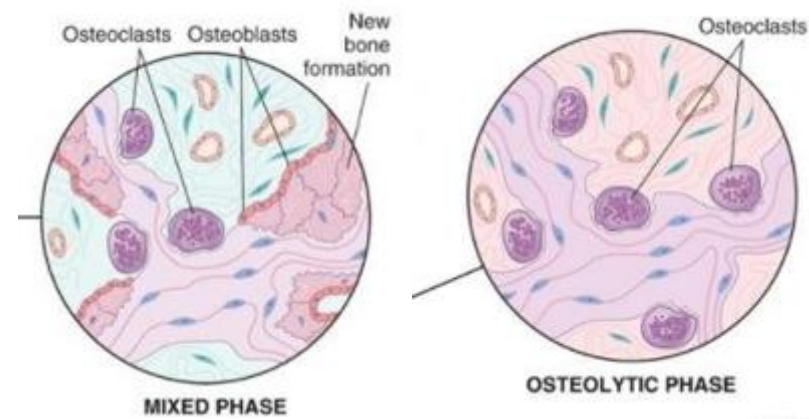
At slide 11 you should  
find something you  
need .

# Lecture 3

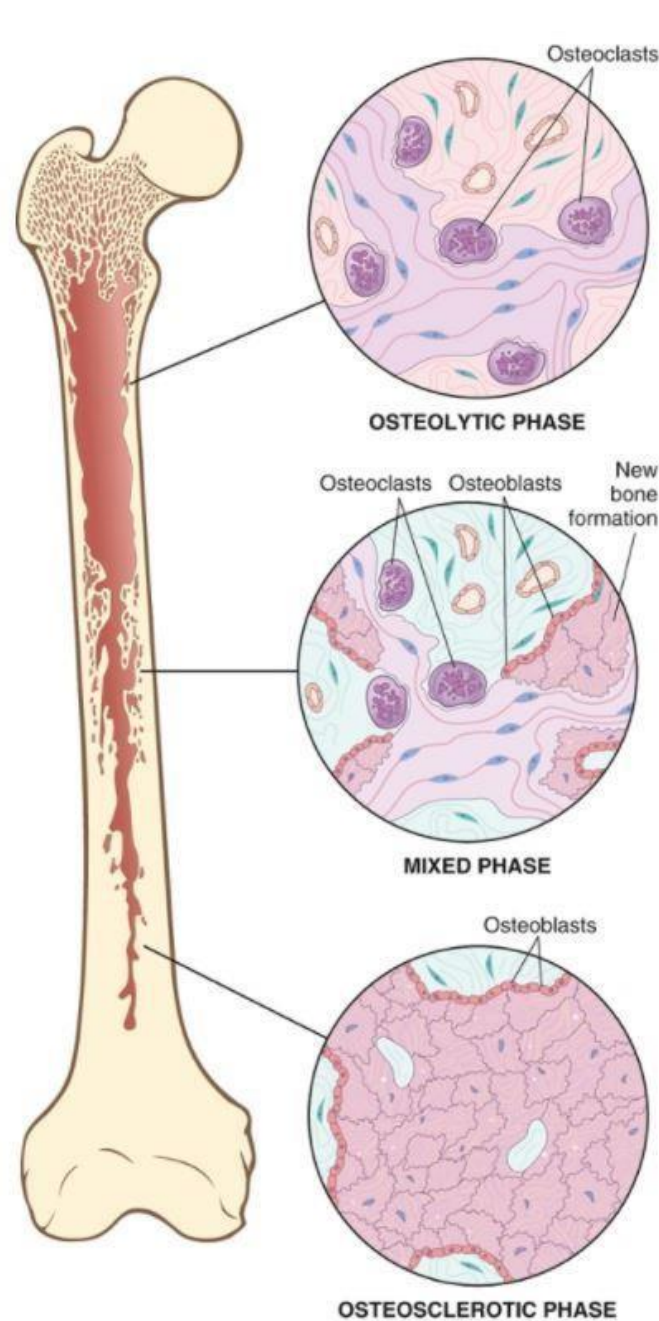
Spanish footballer – plays at real betis –  
wears the number 22  
*hint : only first letter needed*

# PAGET DISEASE OF BONE (OSTEITIS DEFORMANS)

- In Paget disease, abnormalities in both osteoblast and osteoclast function, along with a lack of coordination between them, lead to disturbances in bone formation and resorption, resulting in **Increased badly formed bone structure**.
- In paget disease there are 3 phases (lytic, mixed, sclerotic), these phases take place in random order.
  - If osteoblast activity > osteoclast activity = sclerotic (bone formation) phase.
  - If osteoblast activity < osteoclast activity = lytic phase.
  - If osteoblast activity = osteoclast activity = mixed phase.
- **1% in USA; geographic variations in prevalence have been observed between countries.**
- **Unknown etiology.** (Nobel prize awaits ☺)
- **Genetic and environmental factors play an important role.**
- **50% of familial Paget and 10% of sporadic have SQSTM1 gene mutations, which are believed to stimulate the RANKs and inhibit the OPGs (osteoprotegerin), (+RANKs -OPG)**
- **Viruses (measles and RNA viruses)??**
  - + Stimulate.
  - Inhibit.



Under the microscope, Paget disease appears as abnormal bone formation in the form of a mosaic pattern. This pattern is typically associated with the osteosclerotic phase.

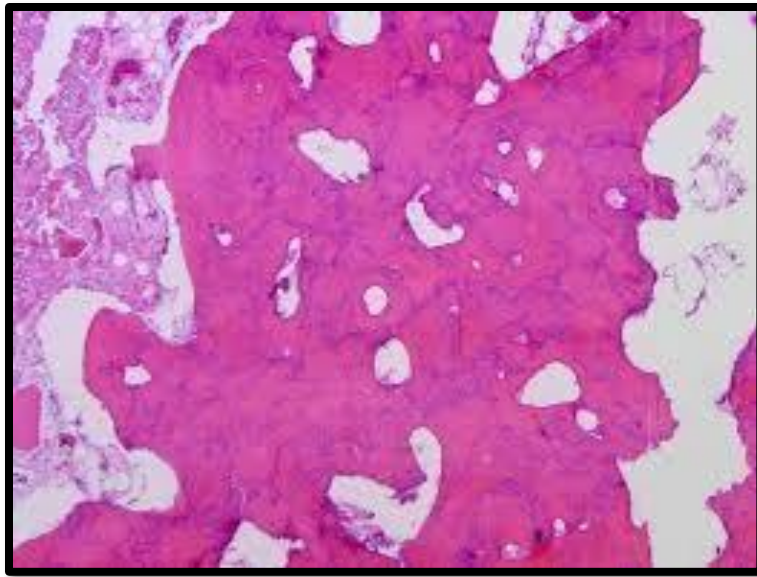


Increased activity of osteoclasts → more lytic lesions → decreased bone opacity in the **osteolytic phase**.

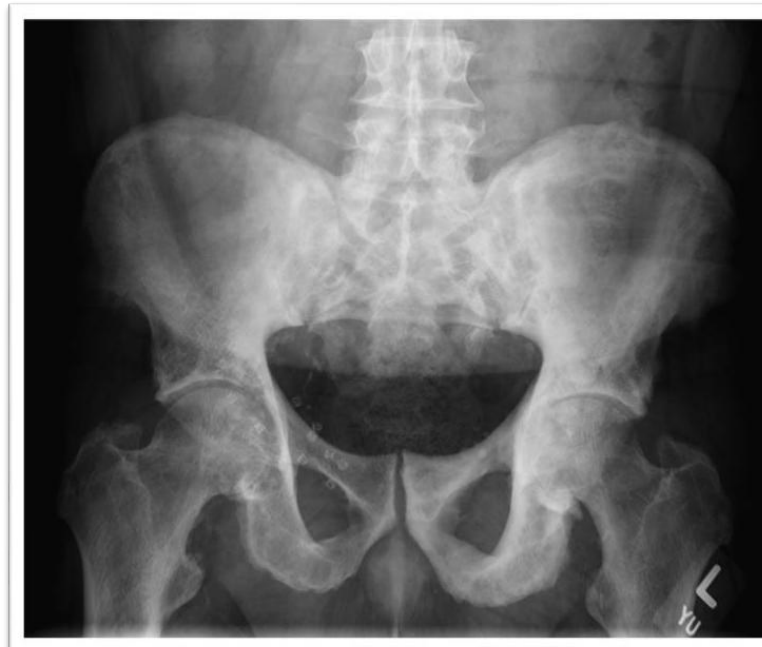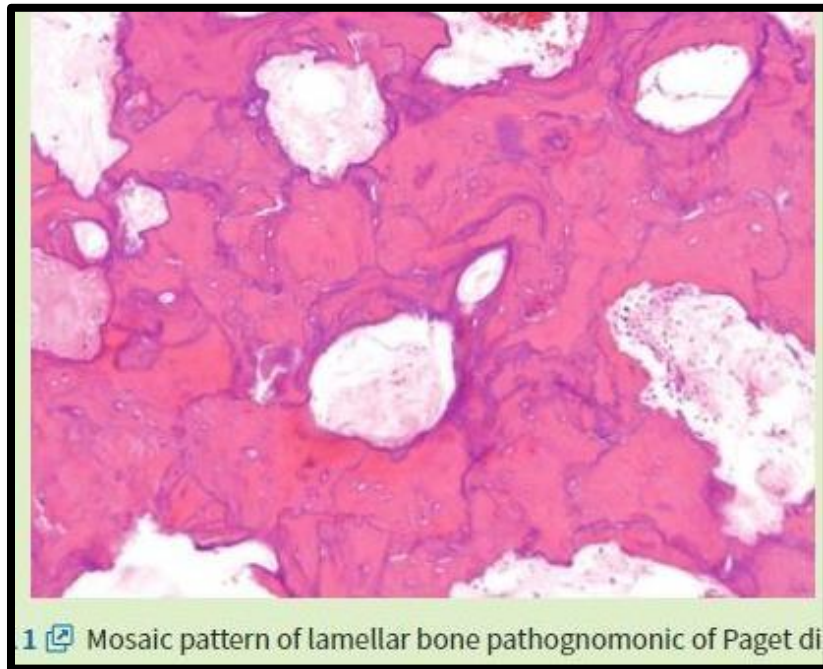
More activity of osteoblast → **osteosclerotic phase**

FIG. 21.10 Diagrammatic representation of Paget disease of bone demonstrating the t...

Some pathologic fractures can be treated by ORIF (open reduction internal fixation) – see slide 19.



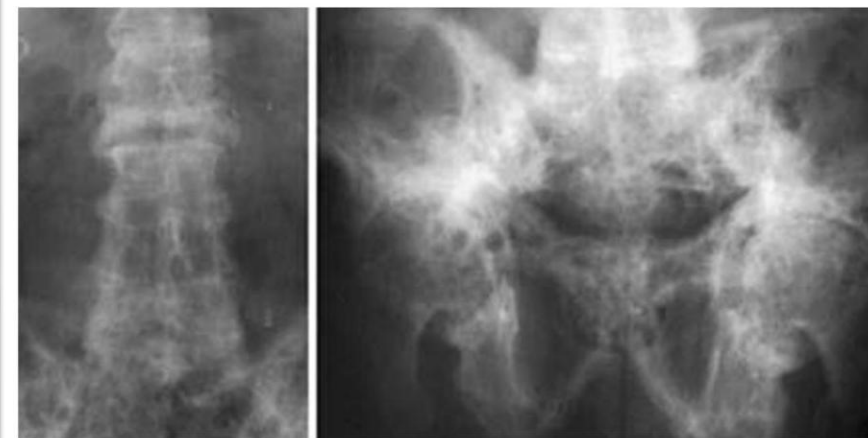
Mosaic  
Abnormal  
bone  
formation



X-ray of a pelvic bone affected by Paget disease.

More common in the vertebral column and the proximal axial skeleton.



The area which has whiter views on the x-ray has more osteoblastic activity (osteosclerotic), while lesser white indicates more osteoclastic activity (osteolytic).



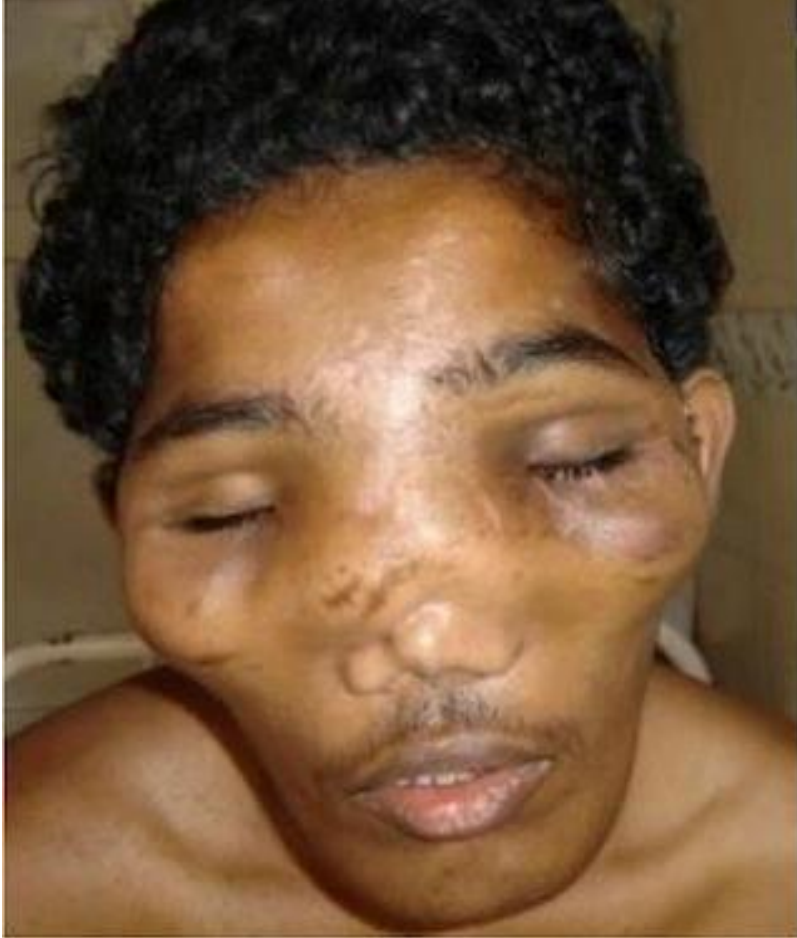Didn't get it?  
See lecture...  
[13:30-16:23](#)

Most of the time, a biopsy is done to rule out other causes.

# PAGET CLINICALLY:

- 85% polystotic  (more than one bone) or 15% monostotic.
- Axial skeleton more affected (prox. Femur) and is rarely found at distal bones.
- Most are mild and asymptomatic - no symptoms ( if there are symptoms, **pain** is the major one).
- Causes of Pain;
  1. Microfractures (an excessive number of microfractures can progress to <sup>2</sup>. nerve compression).
  2. Nerve compression (Similar to a vertebral disc, where a slipped disc compresses nerves, causing intense pain).
- The intensity of pain depends on the location and severity of the underlying cause.
- Leontiasis ossea (lion face), severe paget disease of the skull; platybasia (invagination of skull base); secondary osteoarthritis; fractures; osteosarcoma (1%)
- DX: x-ray;  serum Alk P, because of the commotion that occurs in the bone between osteoclasts and osteoblasts, Normal Ca and PO4 → so you **exclude** the vitamin D deficiency and **hyperparathyroidism**.

# Leontiasis ossea (**lion** face); platybasia



((وَقَلِيلٌ مِّنْ عِبَادِيَ الشَّكُورُ))  
الحمد لله الذي عافانا مما ابتلى  
غيرنا به

# FRACTURES #:

- Loss of bone integrity from mechanical injury (trauma) &/or diminished bone strength.
- Most common pathology of bone.
- Fractures are classified into multiple variants, as each type indicates how it occurred and determines the appropriate treatment:
  1. Simple #: the overlying skin is intact, the fractured bone doesn't penetrate the skin, there's no communication with the skin.
  2. Compound #: communicates with overlying skin.
  3. Displaced #: ends are not aligned (تزحلّقوا عن بعض)
  4. Stress #: repetitive slowly progressive (often occurs in Paget disease / osteoporosis)
  5. Greenstick #: soft bone fracture (mostly in children) - ( analogy from the Dr: مثل لما تطعج اعواد الملوخية)
  6. Pathologic #: bone abnormal (tumor), occurs when there are abnormal bones, such as: in Paget, osteoporosis, or metastatic cancer.

*Hint: some LETTERS need to be rearranged to give a correct word  
you need the full word*

# Types of Bone Fractures



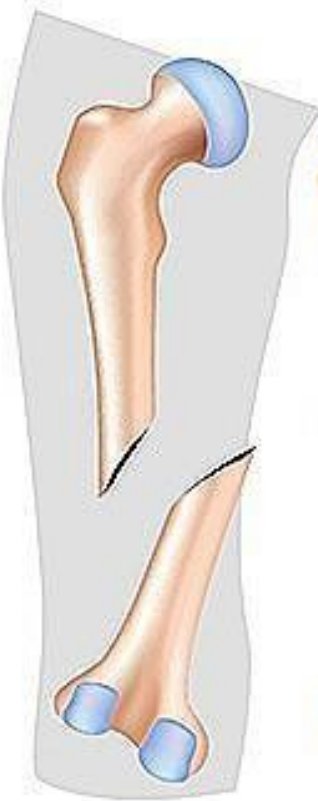Transverse




Linear



Nondisplaced



Displaced,  
Compound



Spiral



Greenstick



Comminuted

Try to analyze  
each case  
then look at  
the following  
slide

# Can a fracture be both, simple and nondisplaced?

- Simply, yes.

1.



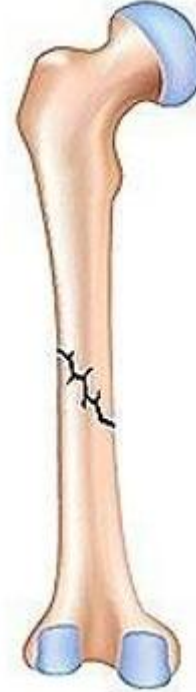**Transverse**  
–  
Horizontal

2.



**Linear**  
–  
Vertical

3.



**Oblique**  
–  
Diagonal

4.



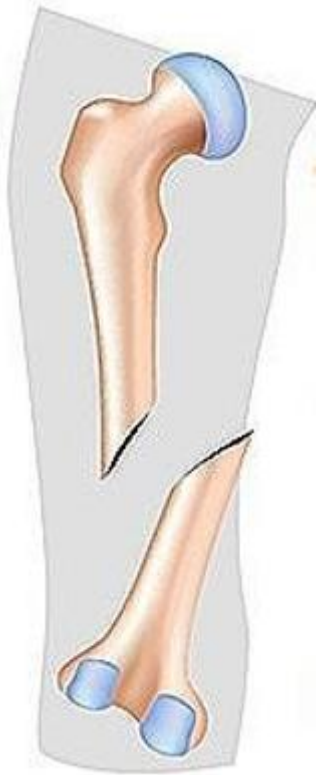**Spiral**

Can be caused by twisting.

**Treatment:** no need for reduction or surgery, only immobilization to aid in repair/ healing and localizing the bone. For spiral fractures, it depends.

# What about being both compound and displaced?

- Also, yes.



**Compound, displaced.**  
Penetrating the skin, it requires open reduction and surgery (internal fixation) and sometimes closed reduction.

## What if the bone is fractured into small pieces?



### **Comminuted**

More than 2 parts, it may be comminuted nondisplaced, comminuted displaced or comminuted compound (healing is more challenging and requires internal fixation - ORIF).

## What if the periosteum was dented, and the bone is still soft and not fractured?



### **Green stick**

- The bone is still soft, no fracture.
- Imp clinical advice: if greenstick fracture is suspected, it must be treated as a normal fracture and to be checked after 2-3 days as the hematoma appears to diagnose the case.

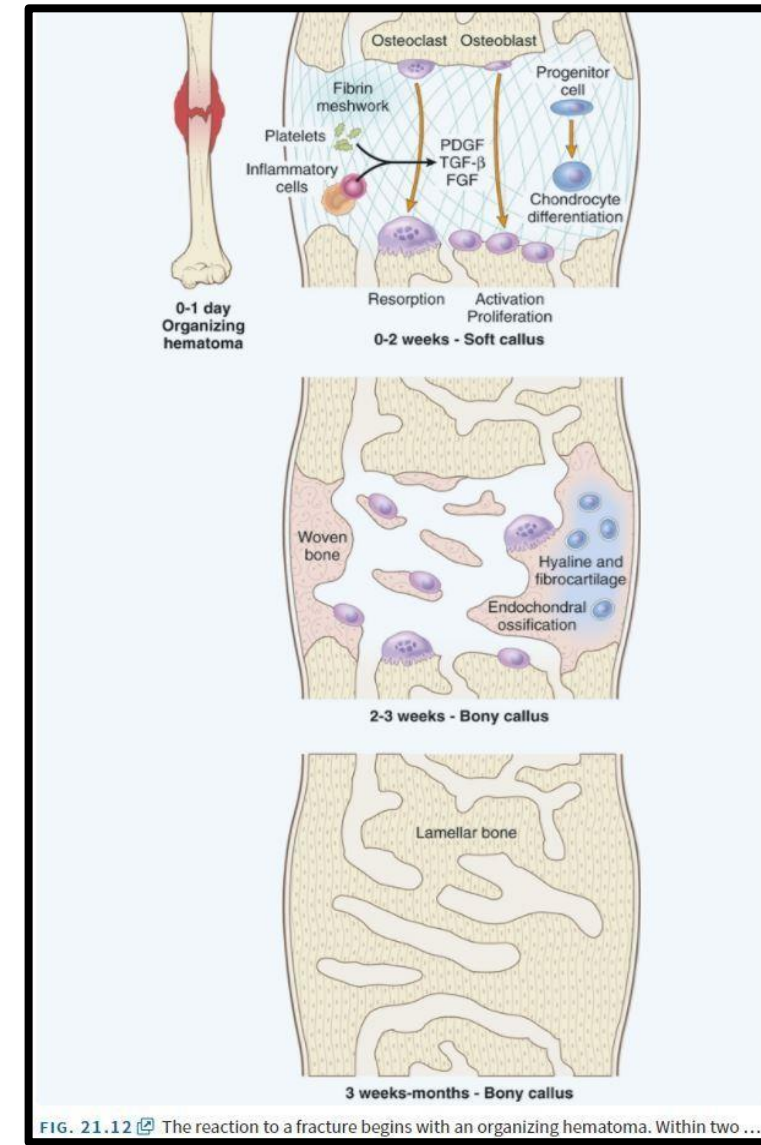
## EXTRA SLIDE – CLINICAL INFO.

- Simple + nondisplaced fractures are very easy to heal (2-3 weeks) after healing bone regain 90-99% of its original state.
- **Open Reduction & Internal Fixation (ORIF)** – Surgery is done to **realign the bone**, using screws, plates, or rods to stabilize it.
- **Closed Reduction** – If the bone can be **manually realigned** without surgery, a cast or brace is used for healing.

Skip if in a hurry, **DON'T** if you care about being an extraordinary physician.

# FACTORS IMPACTING PROPER HEALING:

- **Displaced and comminuted fractures**
- **Inadequate immobilization (delayed union or nonunion)**
- **Pseudoarthrosis** – joint takes place of the fracture site, affecting bones and movement.
- **Infection (open or compound fractures)**
- **Malnutrition.**
- **Steroids/AIDrugs.**
- ✓ Healing is faster for younger (2-3 weeks) than older (5-6) patients.



# OSTEONECROSIS (AVASCULAR NECROSIS)

Why named avascular? Because the main cause is the interruption of the blood supply.

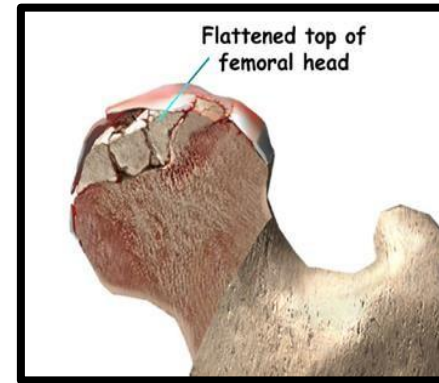
Infarction (ischemic necrosis) of bone and marrow

## ASSOCIATED CONDITIONS:

- **Vascular injury:** trauma, vasculitis
- **Drugs:** steroids
- **Systemic disease:** Sickle
- **Radiation**

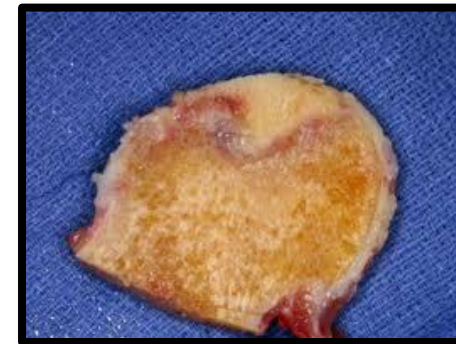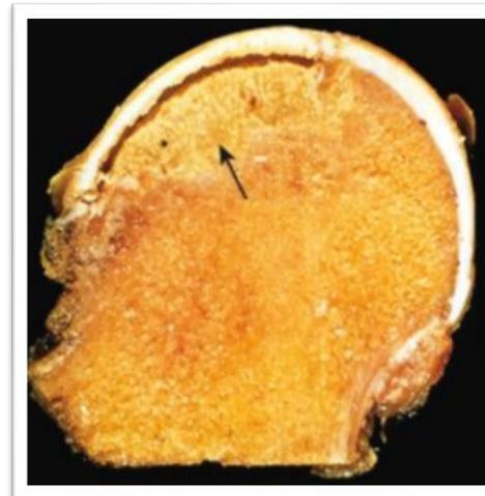## MECHANISM:

- **Mechanical disruption**
- **Thrombotic occlusion**
- **Extravascular compression**



- Most common bone affected by OSTEONECROSIS is the head of the femur.

Pyramidal shape necrosis, the base of the pyramid is in the articular joint.



# For any feedback, scan the code or click on it.



Corrections from previous versions:

Versions	Slide # and Place of Error	Before Correction	After Correction
V0 → V1	15	-	Added # (meaning fracture in medical terms)
	The whole file	-	General structural changes.
V1 → V2			

## Additional Resources:

## رسالة من الفريق العلمي:

قال عمر رضي الله عنه

نحن قوم أعزنا الله بالإسلام فمهما ابتغينا العزة في غيره أذلنا الله

كأننا رمالٌ بلا مرفأً \*\*\* تفرقت العربُ شيعاً  
وضعنا بأهواءٍ من يجرؤ \*\*\* جهالتنا أطفأت نورنا  
وعزُّ الفقيرِ كظلِّ المساءِ \*\*\* حروبٌ تطولُ بلا غايةٍ  
حقوقُ البؤساءِ ولا الضعفاءِ \*\*\* نهبنا الضعيفَ ولم نرعَ  
يذلهمُ الفرسُ والرومُ \*\*\* كثيرونَ لكنْ بلا قوَّةٍ

به شمسُ محمدَ كالْمِصباحِ \*\*\* ولكنَّ فجرَ الهدى أشرقت  
تسودُ بعلمٍ وبالإصلاحِ \*\*\* فضغنا بأحكامه أمةً  
بلادُ الجنوبِ أو الساحلِ \*\*\* عدلٌ، وأخوةٌ من كان من  
وعزُّ الفقيرِ كذي المنزلِ \*\*\* وسادَ الأمانُ، وزالَ الظلامُ  
من الذلِّ للمجدِ والعزةِ \*\*\* فدينُ الهدايةِ بدَّلنا  
ظلامِ القصورِ بلا رؤيةٍ \*\*\* وقمنا نُعلِّمُ من كان في

لا تنسوننا من صالح دعاءكم في هذه الأيام المباركة

### سُورَةُ الْبَقَرَةِ

بِسْمِ اللَّهِ الرَّحْمَنِ الرَّحِيمِ

شَهْرُ رَمَضَانَ الَّذِي أُنْزِلَ فِيهِ الْقُرْآنُ هُدًى لِّلنَّاسِ  
وَبَيِّنَاتٍ مِّنَ الْهُدَى وَالْفُرْقَانِ فَمَن شَهِدَ مِنْكُمُ  
الشَّهْرَ فَلْيَصُمْهُ وَمَن كَانَ مَرِيضًا أَوْ عَلَى سَفَرٍ فَعِدَّةٌ  
مِّنْ أَيَّامٍ أُخَرَ يُرِيدُ اللَّهُ بِكُمُ الْيُسْرَ وَلَا يُرِيدُ بِكُمُ  
الْعُسْرَ وَلِتُكْمِلُوا الْعِدَّةَ وَلِتُكَبِّرُوا اللَّهَ عَلَى مَا  
هَدَاكُمُ وَلَعَلَّكُمْ تَشْكُرُونَ