

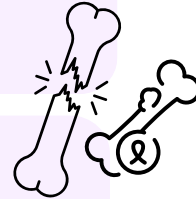
بِسْمِ اللَّهِ الرَّحْمَنِ الرَّحِيمِ

MID | Lecture 5

MSS & Skin Tumors (pt.5)

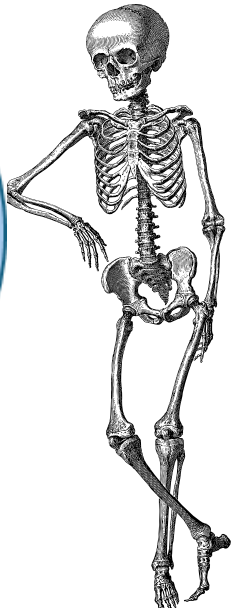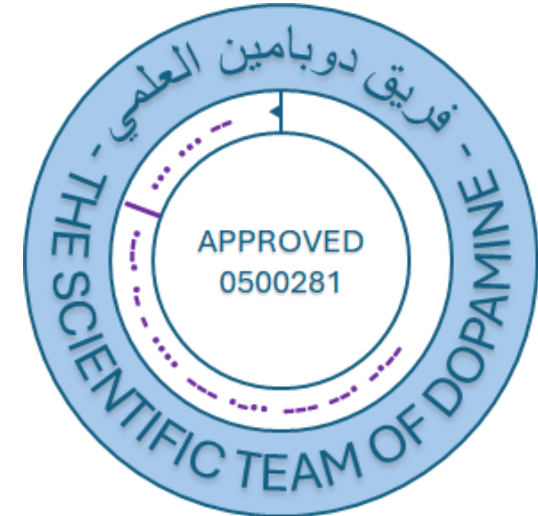Written by: Bashar Khraisat
Osama Hamdan

Reviewed by: Muthanna Khalil

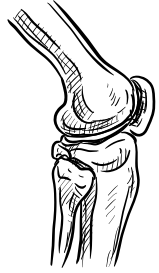

وَإِن تَتَوَلَّوْا يَسْتَبَدِلْ قَوْمًا غَيْرَكُمْ ثُمَّ لَا يَكُونُوا أَمْثَلَكُمْ

اللهم استعملنا ولا تستبدلنا



رَمَضَانَ مُبَارَكٌ



PATHOLOGY



QUIZ!

REMEMBER FROM GENERAL PATHOLOGY

- Grading vs staging

- Grading: grading of a cancer is based on the degree of differentiation of the tumor cells, tumor grading is typically classified into four grades:
 1. Grade 1 (low grade/ well differentiated) => cells look like normal cells.
 2. Grade 2 (moderate grade / moderately differentiated) => cells appear slightly abnormal.
 3. Grade 3 (high grade / poorly differentiated) => cells look very abnormal and grow rapidly.
 4. Grade 4 (highest grade / undifferentiated) => cells are extremely abnormal and grow aggressively.
- Staging: the staging of a cancer is based on:
 1. The size of the primary lesion (T) => (T1 – T4 , To => in situ)
 2. The extent of spread to regional lymph node (N) => (N1– N3 , No => no lymph node involvement)
 3. The presence or absence of bloodborne metastases (M) => (Mo => no distant metastases, M1 or sometimes M2 indicates distant metastases)

BONE TUMORS AND TUMOR-LIKE CONDITIONS:

1. **Primary bone tumors are rare:** That is, secondary bone tumors arising from metastasis are much more common than those originating primarily from the bone.
2. **Benign >>>> malignant tumors.** (Primary bone tumors are less likely to be malignant compared to other types)
3. **Most primary tumors in the First 3 decades are benign; adults more to be malignant**
4. **Trx: aims to optimize survival while maintaining function.**
(Treatment is less aggressive nowadays – limb salvage resection – which aims to remove a tumor from a limb without removing the whole limb)

BONE TUMORS AND TUMOR-LIKE CONDITIONS:

5. Age & location help narrow ddx

- Patient history is crucial; tumors show age-specific prevalence

6. S&S: asymptomatic, pain, pathological fractures (#)

- Most of these cases are asymptomatic because the lesions are usually benign (people live with them and die with them).
- However, symptoms like localized pain or pathological fractures can occur if the lesion is large and located in a highly active area.

Table 21.1 Classification of Selected Primary Bone Tumors

Memorize the TABLE!

Category	Behavior	Tumor Type	Common Locations	Age (yr)	Morphology
Cartilage forming	Benign	Osteochondroma	Metaphysis of long bones	10–30	Bony excrescence with cartilage cap
—	—	Chondroma	Small bones of hands and feet	30–50	Circumscribed hyaline cartilage nodule in medulla
—	Malignant	Chondrosarcoma (conventional)	Pelvis, shoulder	40–60	Extends from medulla through cortex into soft tissue, chondrocytes with increased cellularity and atypia
Bone forming	Benign	Osteoid osteoma	Metaphysis of long bones	10–20	Cortical, interlacing microtrabeculae of woven bone
—	—	Osteoblastoma	Vertebral column	10–20	Posterior elements of vertebra, histology similar to osteoid osteoma
—	Malignant	Osteosarcoma	Metaphysis of distal femur, proximal tibia	10–20	Extends from medulla to lift periosteum, malignant cells producing woven bone
Unknown origin	Benign	Giant cell tumor	Epiphysis of long bones	20–40	Destroys medulla and cortex, sheets of osteoclasts
—	—	Aneurysmal bone cyst (ABC)	Proximal tibia, distal femur, vertebra	10–20	Vertebral body, hemorrhagic spaces separated by cellular, fibrous septae
—	Malignant	Ewing sarcoma	Diaphysis of long bones	10–20	Sheets of primitive small round cells

Lecture 5

From now and till the end of the lecture,
more details about each of the 9 types listed in the table will be discussed.
Actually, only 7 of the 9 will be discussed 😊.

BONE-FORMING TUMORS

OSTEOID OSTEOMA

more common

- < 2cm
- Young men
- Femur & tibia; nidus with surrounding bone reaction
- It presents with severe nocturnal pain (mediated by PGE2), which is **relieved by aspirin** and non-steroidal anti-inflammatory drugs (NSAIDs).
- Treated by: radiofrequency ablation or surgery

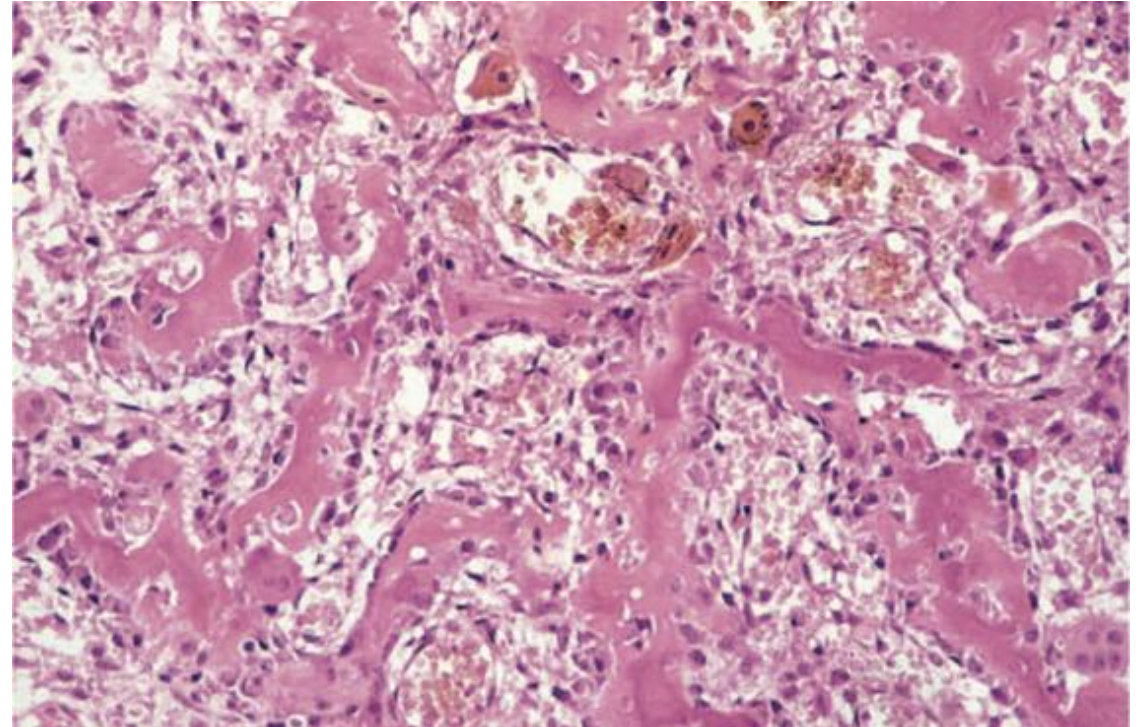
OSTEOBLASTOMA

- > 2 cm
- Posterior vertebrae; **no** rim of bone reaction like the one in osteoid-osteoma
- **Pain unresponsive to aspirin and NSAIDS**
- Treated by curetting (surgical)

Nocturnal pain refers to pain that occurs predominantly at night, often disrupting sleep

BONE-FORMING TUMORS NOTES:

- Osteoid osteoma and osteoblastoma are benign bone producing tumors that have similar histologic features, so It's difficult to differentiate between them under microscope but differ clinically and radiographically.
- Both look like reactive bone with some hemorrhage and reactive giant cells, there is no evidence of atypia.



OSTEOSARCOMA

Also called osteogenic sarcoma

- Malignant osteogenic tumor
- Excluding hematopoietic malignancies **such as myelomas and lymphomas**; osteosarcoma is the most common primary malignant tumor of bone
- 75% adolescents; another peak in older (secondary osteosarcoma)
- Males > females (1.6:1.0)
- Metaphysis of long bones **particularly around the knee joint** (distal femur & proximal tibia).

OSTEOSARCOMA NOTES:

- Osteosarcoma has a bimodal age distribution. Approximately 75% of cases occur in adolescents (ages 10–20), while a smaller second peak occurs in older patients (ages 55–65).
- Older patients often have predisposing conditions such as Paget's disease, bone tuberculosis, or a history of radiation exposure. These cases are referred to as secondary osteosarcomas.

OSTEOSARCOMA

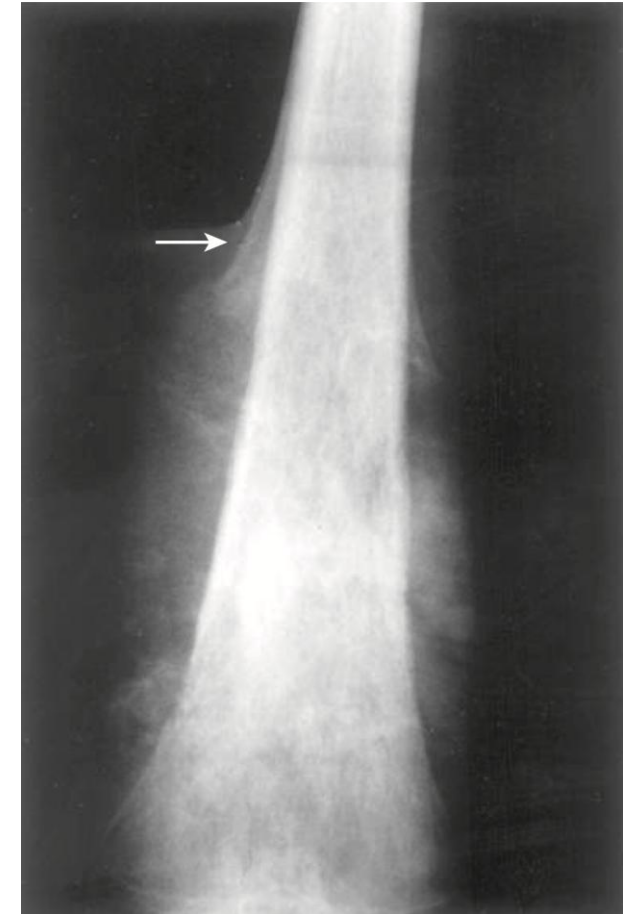
- Presents to care because of Progressive pain or Fractures
- Imaging: large, destructive and infiltrative lesions with Codman triangle
- The tumor typically originates in the bone, extending deep into the medulla and outward through the periosteum. It infiltrates the periosteum and surrounding soft tissues, elevating the periosteum and producing abnormal woven bone. This process creates a radiographically visible angle known as the **Codman triangle**. While the Codman triangle is characteristic of osteosarcoma, it is not pathognomonic, as it can also be seen in other infiltrative bone lesions.

OSTEOSARCOMA

- **Genetic abnormalities: mutations in RB gene, TP53 gene, CDKN2A (p16 & p14), MDM2 & CDK2**
 - The tumor suppressor gene p53, probably the most common tumor suppressor gene involved in human malignancies, plays a significant role.
- The molecular genetic changes in osteosarcoma are complex and are not routinely used for diagnosis or prognosis. Histologic and imaging findings are usually sufficient for diagnosis, as the diagnosis is usually straightforward.

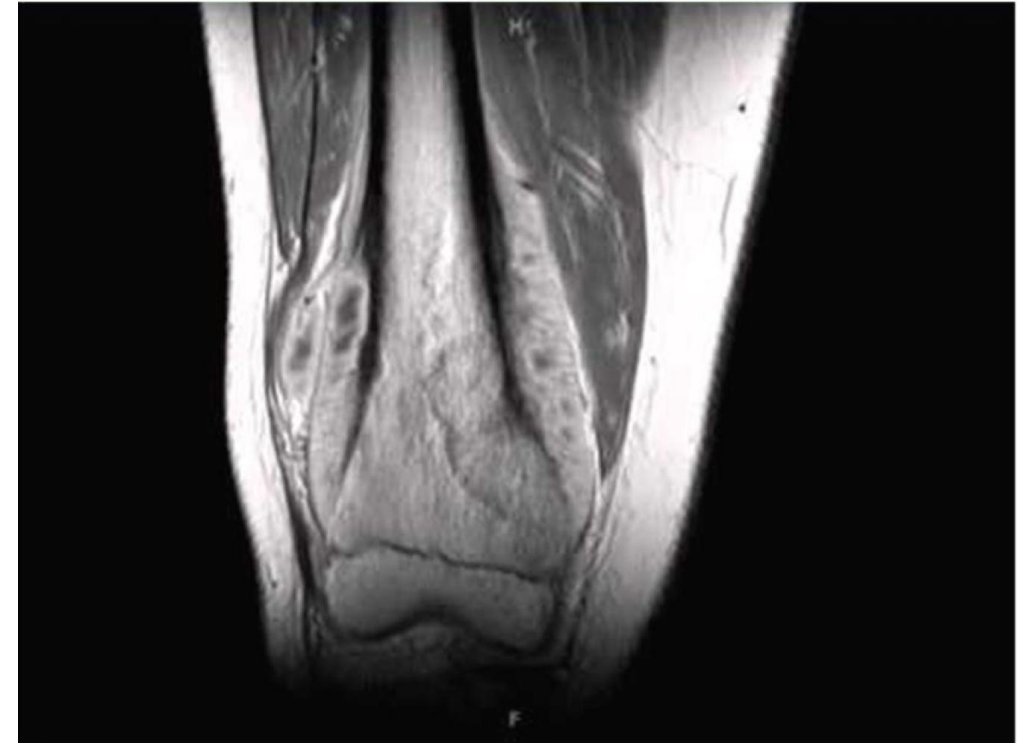
OSTEOSARCOMA FEATURES 1:

- On simple X-ray morphology, the distal femur shows a process originating in the medulla of the bone, infiltrating surrounding tissues, and elevating the periosteum. The angle formed between the actual bone and the elevated periosteum is called Codman's triangle.
- Distal femoral osteosarcoma with prominent bone formation extending into the soft tissues. The periosteum, which has been lifted, has laid down a triangular shell of reactive bone known as a Codman triangle (arrow).



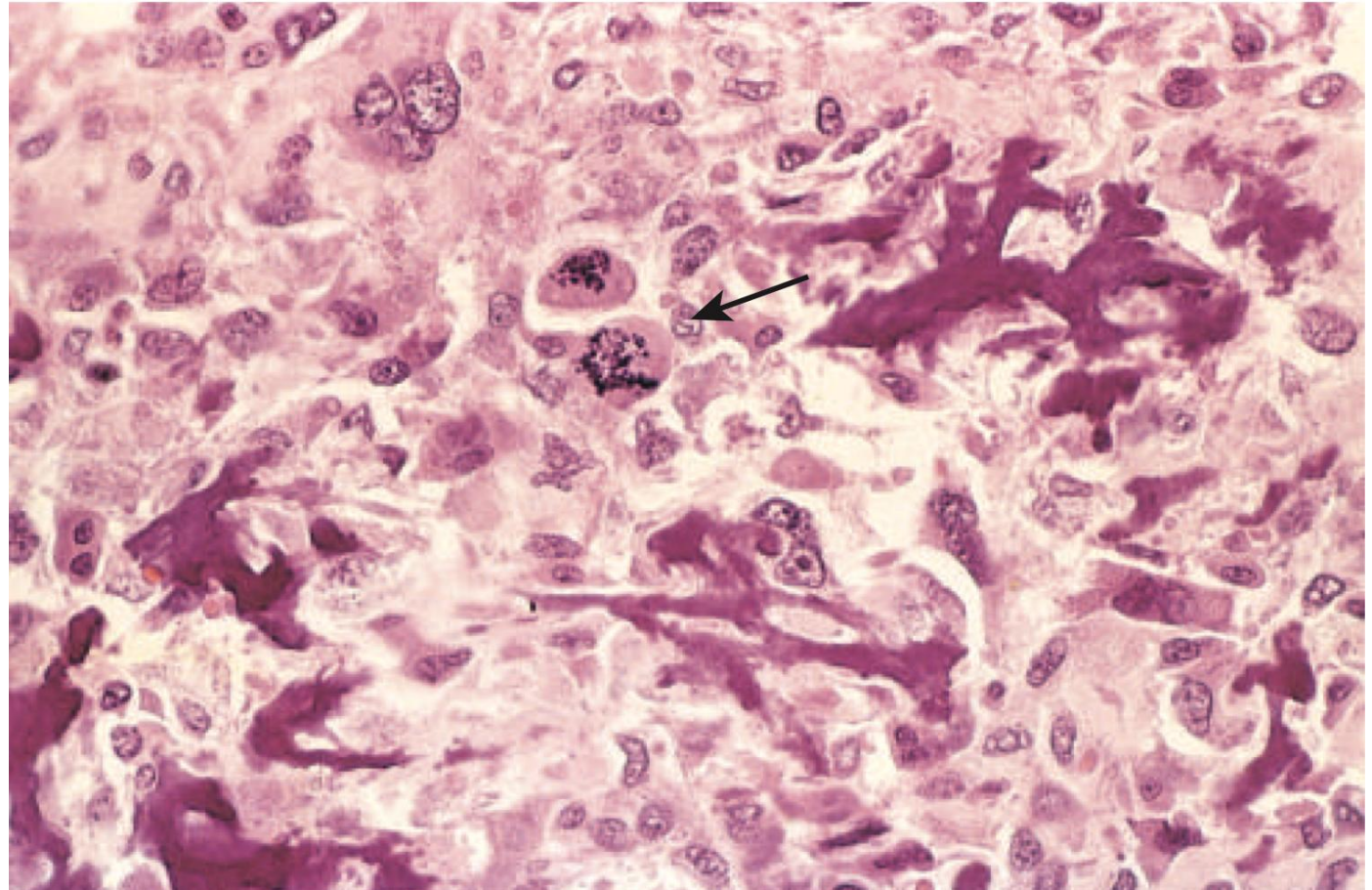
OSTEOSARCOMA FEATURES 2:

- MRI morphology reveals the tumor arising at the metaphysis and extending into the soft tissues, with skeletal muscle infiltration. Periosteal elevation caused by the tumor results in the formation of Codman's triangle.



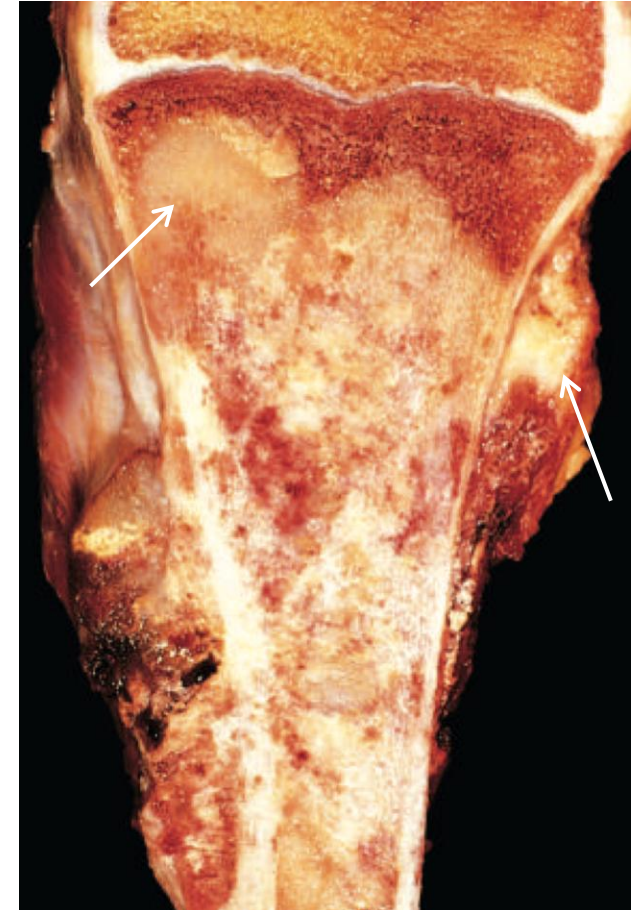
OSTEOSARCOMA FEATURES 3:

- The histological section shows osteoid produced by malignant osteoblasts, displaying haphazard patterns with frequent abnormal mitosis. The bone is entirely woven bone.
- Fine, lacelike pattern of neoplastic bone produced by anaplastic malignant tumor cells in an osteosarcoma. Note the abnormal mitotic figure (arrow).



OSTEOSARCOMA FEATURES 4:

- During gross examination of the specimen, a longitudinal cut through the distal head of the femur reveals excess articular cartilage extending from it.
- Osteosarcoma of the proximal tibia. The tan-white tumor fills most of the medullary cavity of the metaphysis and proximal diaphysis. It has infiltrated through the cortex, lifted the periosteum, and formed soft tissue masses on both sides of the bone.



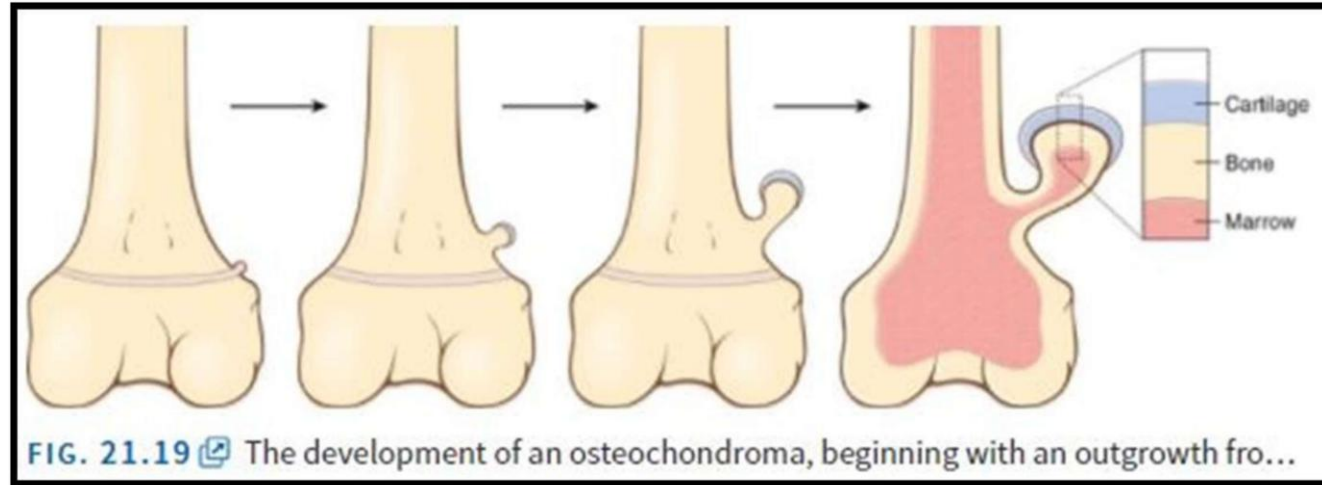
OSTEOSARCOMA TREATMENT:

- **Multimodality approach (MDTeam)**
- **1. Neoadjuvant chemotherapy 2. Surgery 3. Chemo and radiation therapy**
- Neoadjuvant chemotherapy is pre-surgical to shrink the tumor and improve outcomes
- The chemotherapy is given to prevent or kill any metastatic possibility, radiation locally to control the local disease, surgery to remove the tumor.
- **Hematogenous spread to lung**
- In general, sarcomas spread hematogenously to the lungs, not by lymphatics.
- **5-year survival reaches 60-70%** (5-year survival mean the percentage of people who are still alive after 5 years of diagnosis).
- **Presence of Mets at diagnosis is a bad prognostic factor and the 5 years survival rate will drop down.**

CARTILAGE-FORMING TUMORS:

Very common

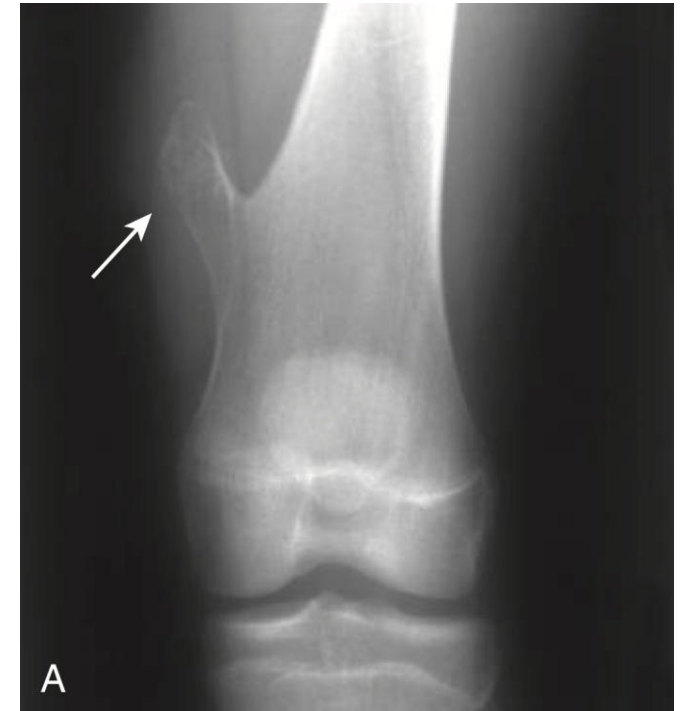
- **Osteochondroma (benign exostoses):**
- Osteochondroma is composed of benign bone covered by benign cartilage, and it is exophytic from the long bones.
- **Solitary (85%) but sometimes they can be multiple.**
- They are sometimes part of Multiple Hereditary Exostoses (MHE) which is characterized by EXT1, EXT2 gene mutations.
- Rare (<3-5%) transformation to chondrosarcoma (more common in MHE)
- If diagnose a patient with multiple hereditary exostoses, you must follow up to monitor the case because chondrosarcoma can originate from MHE.



- This bone and bone marrow extend outward and are then covered by benign cartilage.
- If you cut the extension, you will see normal cartilage, normal periosteum and normal bone marrow.
- Osteochondromas can occur in any bone, but the most common location is in the long bones around the cartilaginous plate.

OSTEOCHONDROMA

- Simple x-ray of the distal femur shows a very classic-appearing exophytic* pedunculated** mass with normal cartilaginous cap. We don't see destruction of the surrounding tissue, and we don't see infiltration or Codman's triangle.

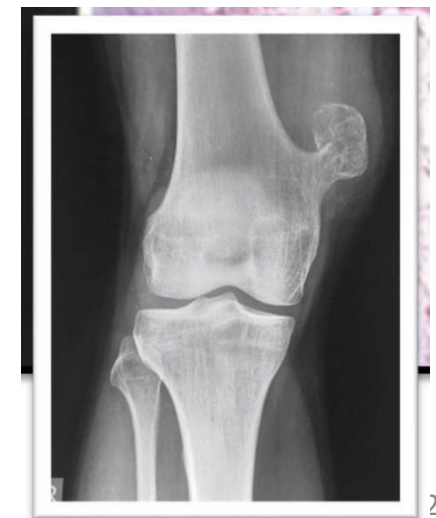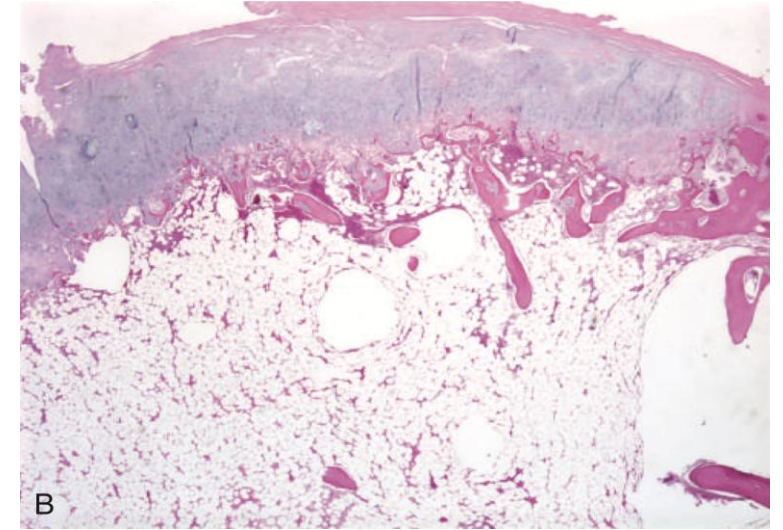


* tending to grow outward beyond the surface epithelium from which it originates.

** a structure that has a peduncle (a stalk or stem) or is attached to another structure by a peduncle

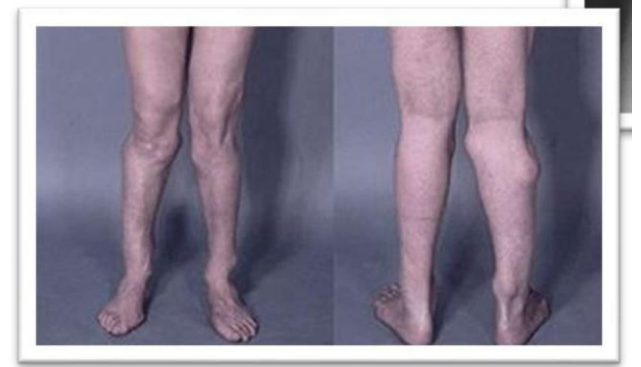OSTEOCHONDROMA

- Under the microscope, we see normal cartilage, normal subchondral bone and normal bone marrow, as if we are looking at a normal piece of articular bone.
- This is another example of osteochondroma.
- This is why they sometimes cause pain and, in some cases, they lead to pathological fractures.



OSTEOCHONDROMA

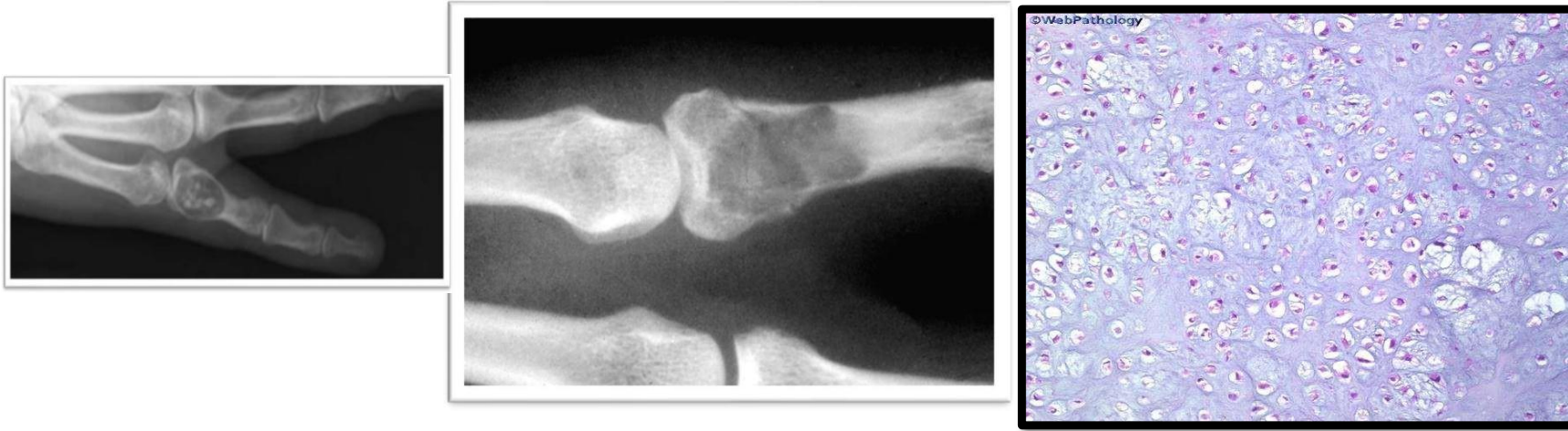- This is a case of multiple hereditary osteochondromas, you have to watch out on those cases because some of them may transform to chondrosarcoma.



CHONDROMA (ENCHONDROMA):

- Benign hyaline cartilage tumors in bones with endochondral origin; medullary enchondroma or cortical chondroma.
- Benign tumors in bones with endochondral origin in the medulla of long bones, they are most of the time solitary in the metaphysis of the long bones (the most common location is the bones of the hands and the feet).
- Solitary metaphyseal lesions; 20-50 years
- Multiple enchondroma: Ollier disease
- Mafucci syndrome: multiple enchondroma + skin hemangiomatosis
- IDH1 & IDH2 gene mutations

CHONDROMA (ENCHONDROMA):



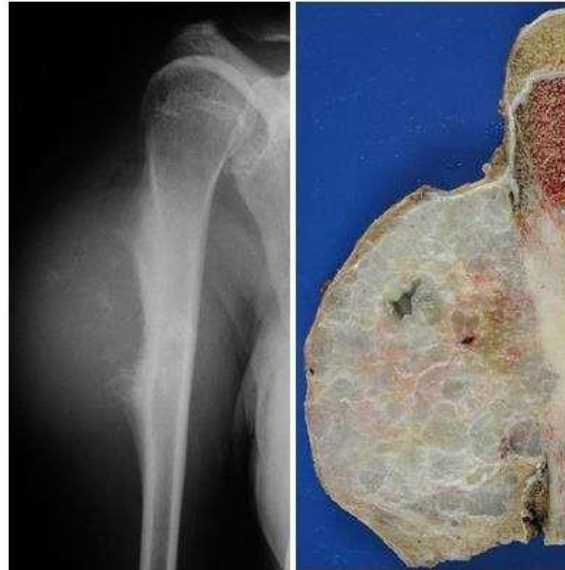- This is a good example of enchondroma, radiologically the radiologist will tell the surgeon and the pathologist that this is enchondroma.
- It has the cartilaginous appearance on x-ray, there is no destruction no elevation in the periosteum and it's in the medulla.
- Histologically, it looks like benign cartilage with no atypia.

CHONDROSARCOMA:

- Malignant tumors producing cartilage
- Incidence of chondrosarcomas is 50% the incidence of osteosarcoma
- 40-50 years of age; Male:Female (2:1)
- Large **big destructive** masses; shoulder, pelvis, ribs
- Genes: EXT, IDH1, IDH2, COL2A1, CDKN2A
- Px: depends on grade (grade 1 excellent px)
- Trx: surgical +/- chemotherapy

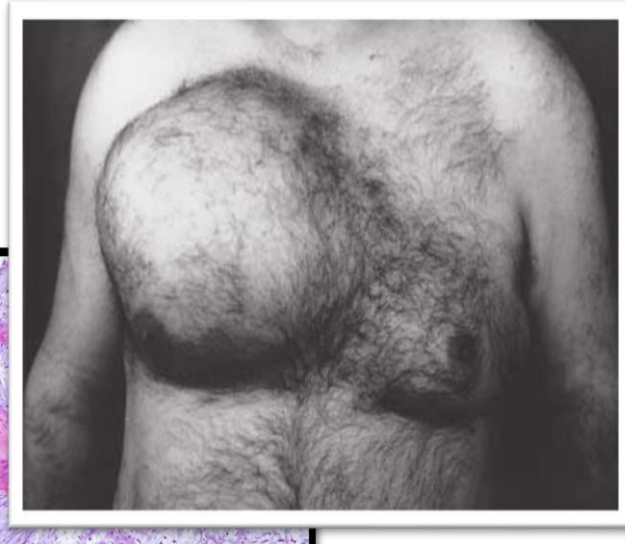
CHONDROSARCOMA FEATURES:

- This is a huge chondrosarcoma in the diaphysis of the humerus bone, there is Codman's triangle, and the tumor is infiltrating the bone marrow as well as extending outward into the surrounding tissue, elevating the periosteum and causing Codman's triangle.

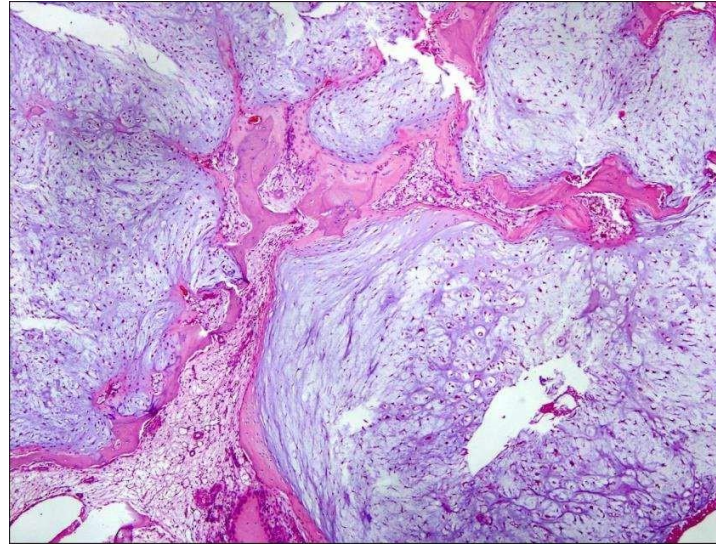


- This is the gross specimen that was removed, showing a large cartilaginous tumor infiltrating the soft tissue as well as the medulla of the bone.

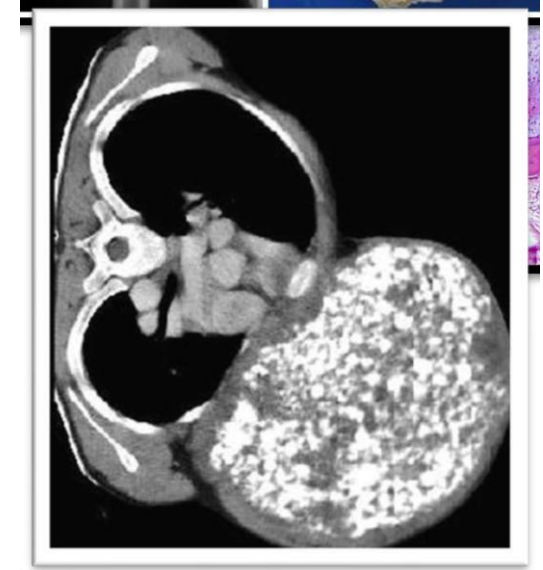CHONDROSARCOMA FEATURES:



- This is a large chondrosarcoma of the ribs.



- Histologically it's malignant lobulated cartilage, this is probably grade 1 or 2 because we can still see that the cartilage differentiation is very obvious.



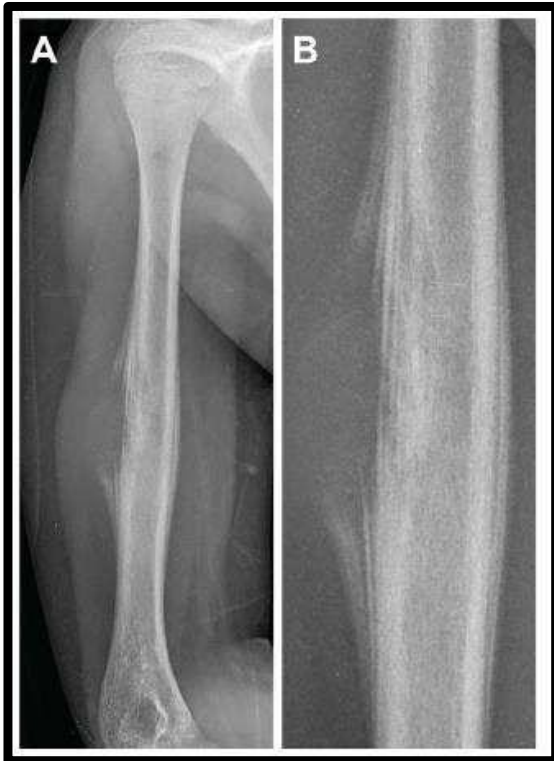
- This is a CT scan of the chondrosarcoma of the ribs.
- This is called bubble soap appearance, when the radiologist or the pathologist see this, they will identify it as chondrosarcoma until proven otherwise.

EWING SARCOMA:

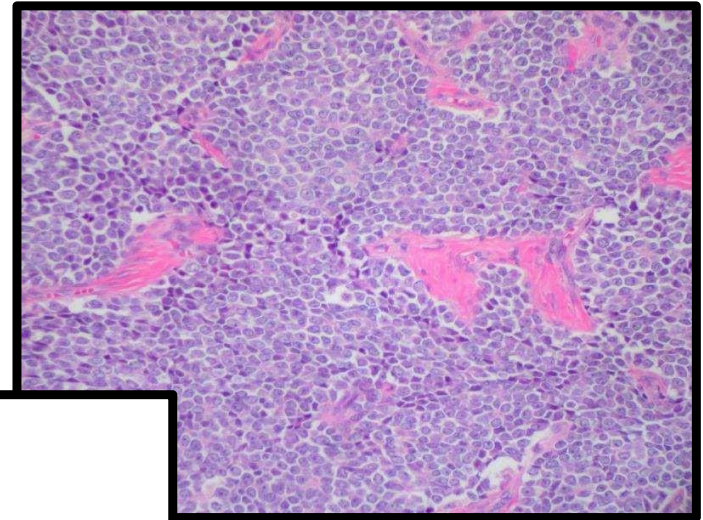
This slide (and the one after it) was not explained by the Dr. in the recorded lecture. Please study the slide content prophylactically.

- **Dr. James Ewing (1866-1943). Described this tumor 1920**
- **Small blue cell tumor (PNET)**
- **2nd most common sarcoma of bone after osteosarcoma**
- **< 20 years, diaphysis**
- **The most common translocation, present in about 90% of Ewing sarcoma cases, is $t(11;22)(q24;q12)$, which generates an aberrant transcription factor through fusion of the EWSR1 gene with the FLI1 gene.**
- **Trx: neoadjuvant CT followed by surgery; long term survival now reaches 75%**





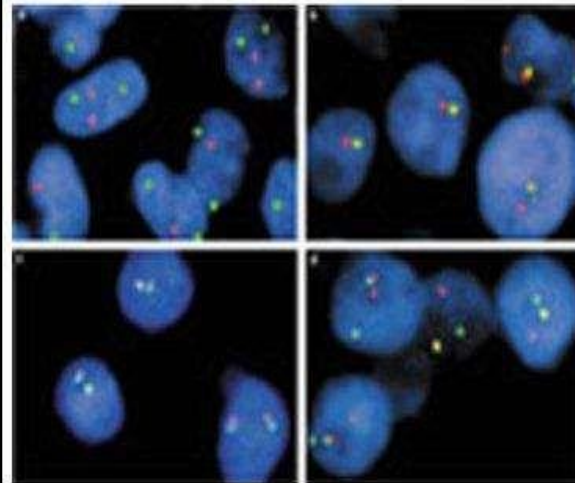
ES Features



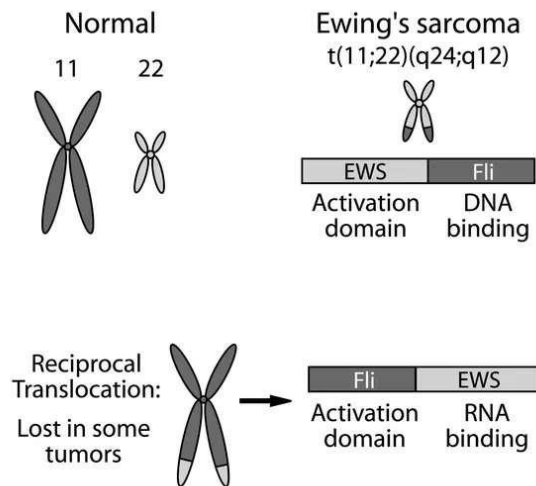
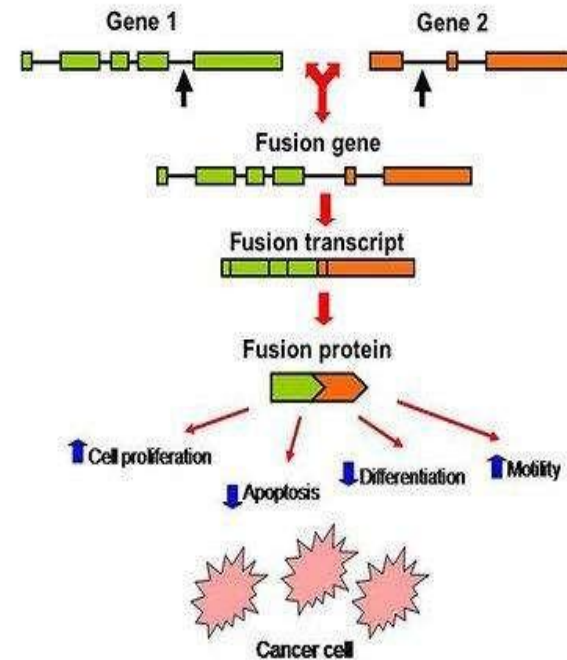
Positive translocation of EWS gene:

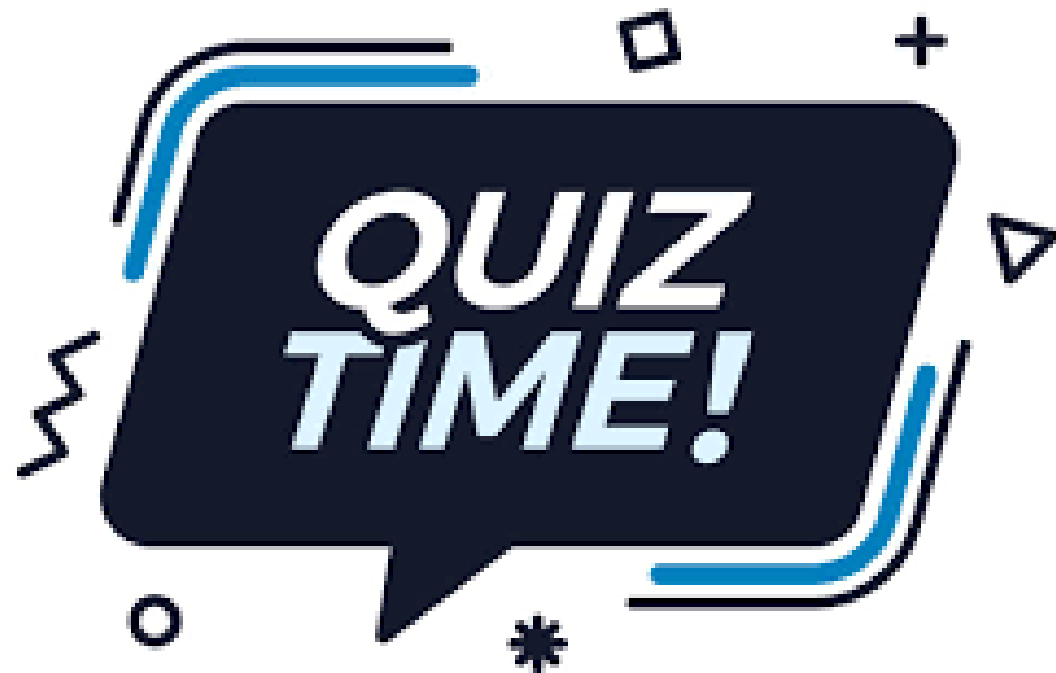
EWS FLI1 t(11;22)(q24;q12)

EWS FLI2 t(21;22)(q22;q12)



Pozit. EWS/FLI1 - FISH





For any feedback, scan the code or click on it.



Corrections from previous versions:

Versions	Slide # and Place of Error	Before Correction	After Correction
V0 → V1			
V1 → V2			

Additional Resources:

رسالة من الفريق العلمي:

Reference Used:
(numbered in order as cited in the text)

1. Robbins Basic Pathology
11th edition, Chapter 19

