

A red L-shaped bracket in the top-left corner of the page.

NERVE SUPPLY OF THE SCALP

Mays Aljundi ✓

A red L-shaped bracket in the bottom-right corner of the page.

Nerve supply of the scalp

Anterior half of scalp *5 nerves*

Sensory :

(Branches of trigeminal nerve)

1. Supratrochlear N. → skin of the forehead.
2. Supraorbital N. → skin of the forehead up to the vertex of scalp.
3. Zygomaticotemporal → **hairless** area of the temple.
4. Auriculotemporal → **hairy** area of the *temple*.

Motor :

Temporal branch of facial N. (motor) → frontal belly of occipitofrontalis muscle.

Posterior half of scalp *5 nerves*

Sensory :

(Branches of cervical plexus)

1. Great auricular N. (C_{2,3}) → skin over mastoid process.
2. Lesser occipital N. (C₂) → scalp behind the auricle.
3. Greater occipital N. (C₂ **dorsal** ramus) supplies the occipital scalp up to the vertex.
4. Third occipital N. (C₃ **dorsal** ramus) supplies skin of the lower occipital region.

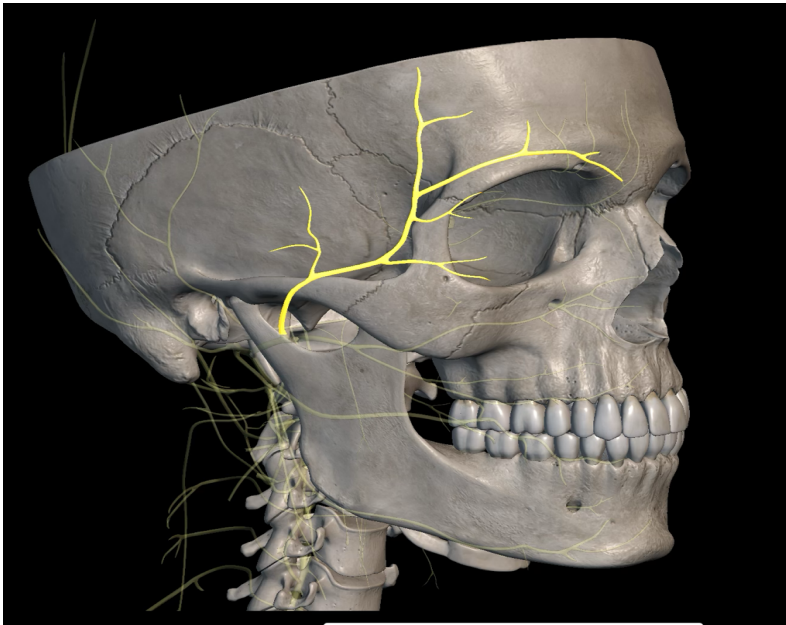
Motor :

Posterior auricular branch of facial N. , (motor) → occipital belly of occipitofrontalis.

Anterior :

Motor :

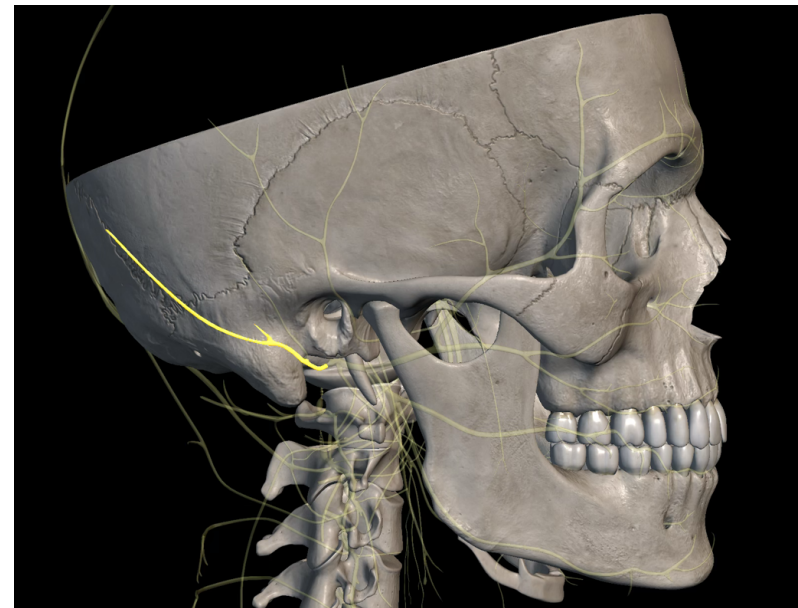
Temporal branch of facial N. (motor)
→ frontal belly of occipitofrontalis
muscle.



posterior :

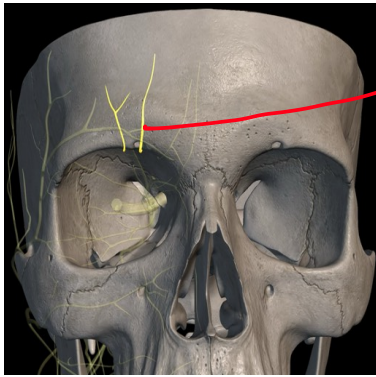
Motor :

Posterior auricular branch of facial N.
, (motor) → occipital belly of occipito-
frontalis.

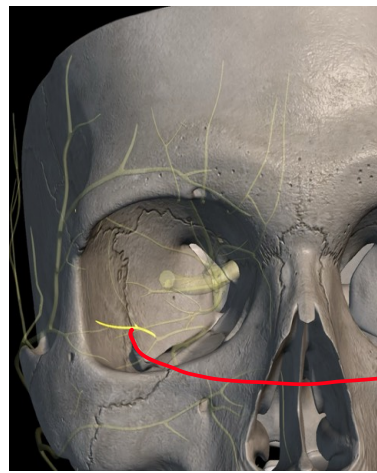


Anterior :)

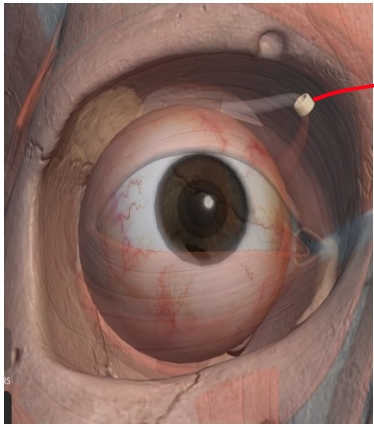
"Sensory nerves"



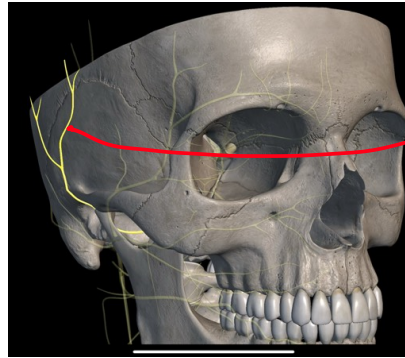
Supraorbital nerve



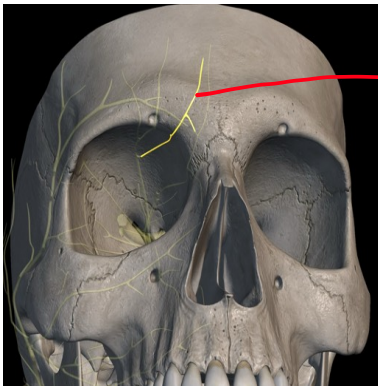
Zygomaticotemporal nerve



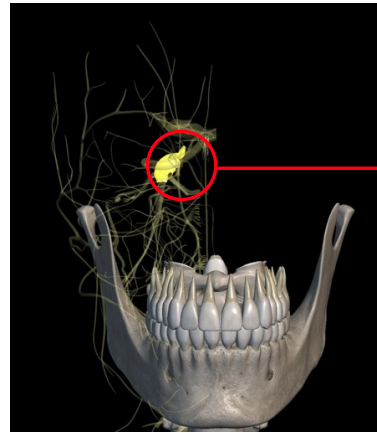
Trochlea



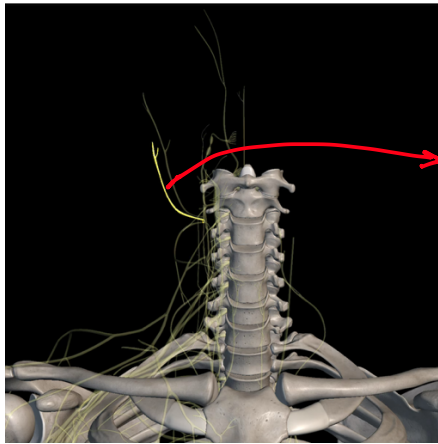
Auriculotemporal nerve



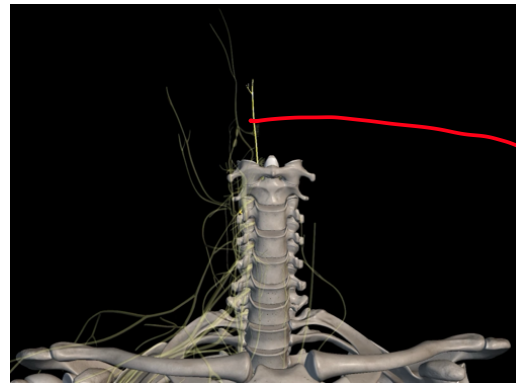
Supratrochlear nerve



Trigeminal nerve { nerves الی من خلاله بیتفرعوا باقی ال الی هون }

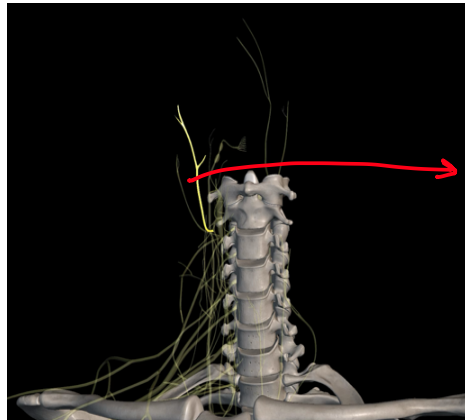


→ Great auricular nerve

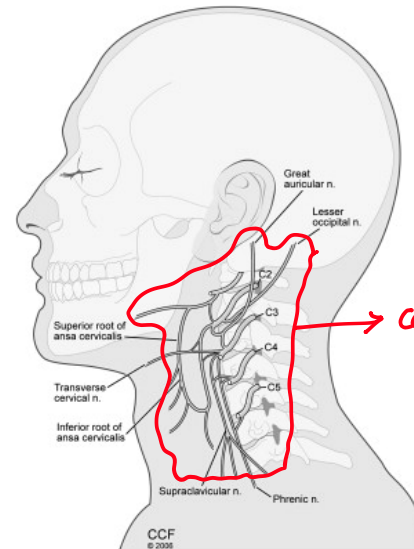


→ Third occipital nerve

posterior :)
"Sensory nerves"

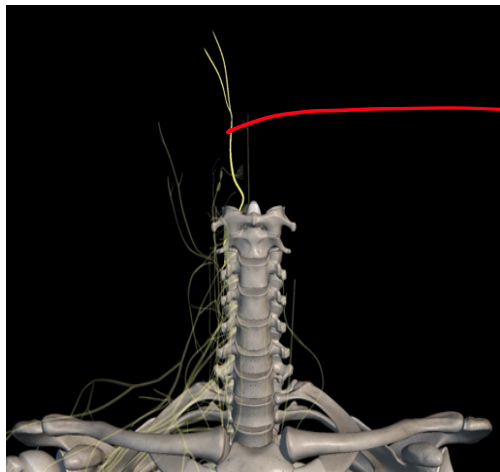


→ Lesser occipital nerve

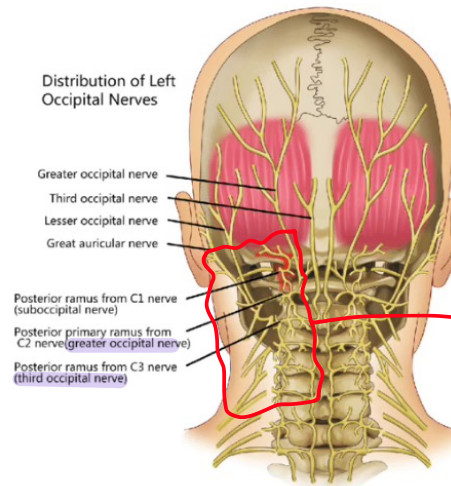


→ cervical plexus

الي من خلاله بيتفرعوا:
1/Greater auricular nerve
2/Lesser occipital nerve



→ Greater occipital nerve



→ Dorsal ramus

الي من خلاله بيتفرعوا:
1/Greater occipital nerve
2/Third occipital nerve