

The University of Jordan  
Faculty Of Medicine



# Skull Practical Part 1

**DR. AHMED SALMAN**

**Associate professor of anatomy & embryology**

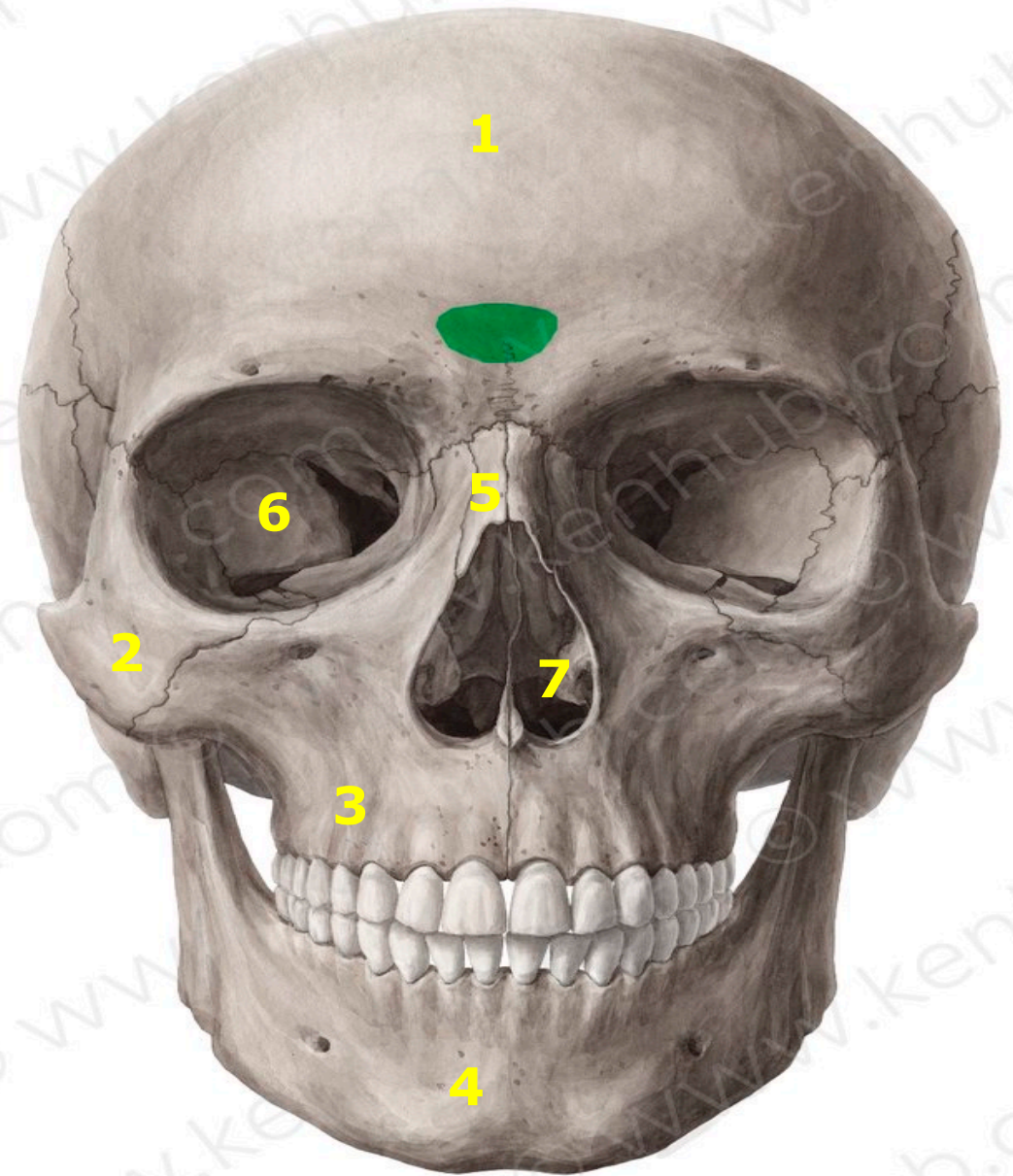


# **NORMA FRONTALIS**

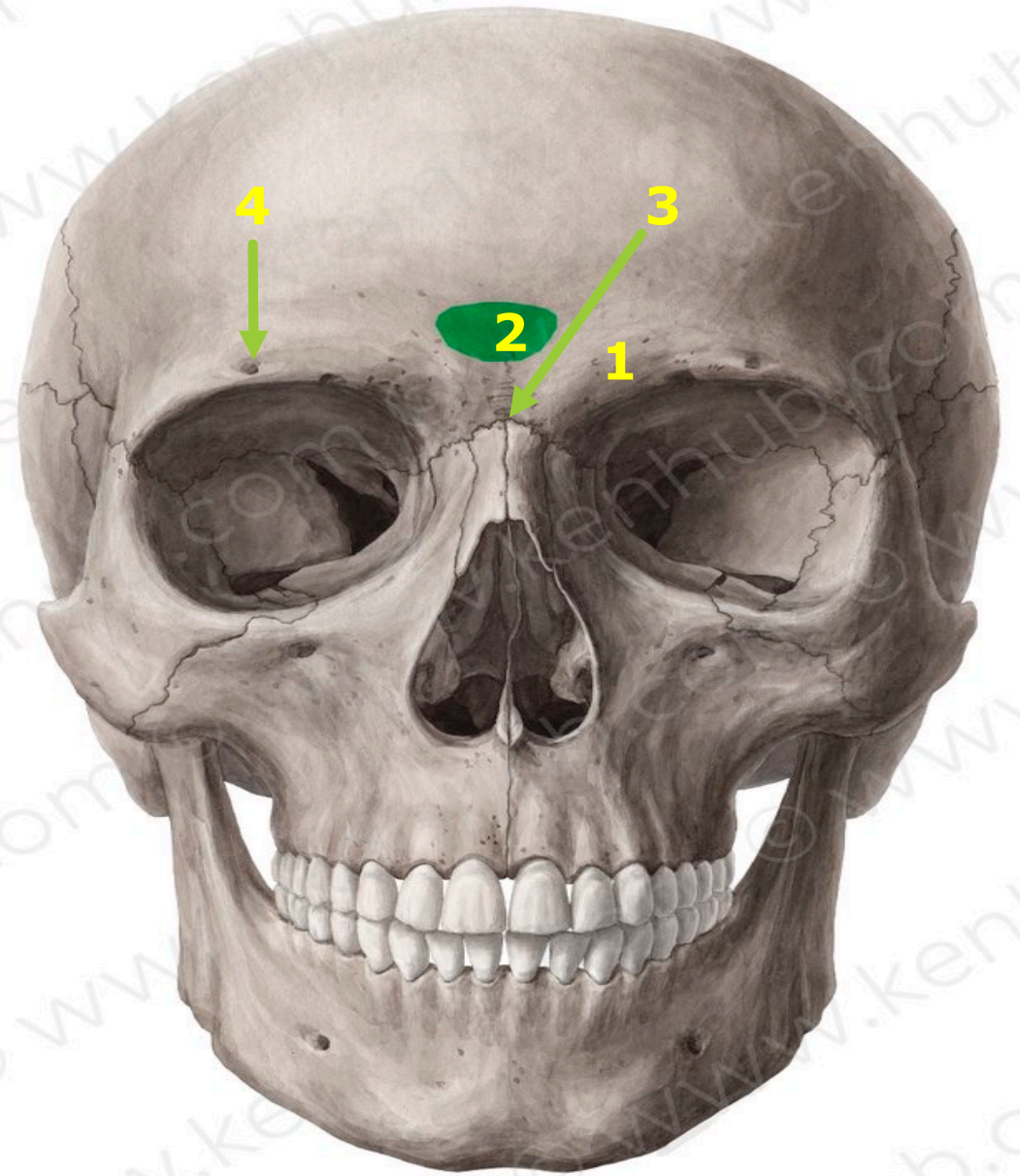
## Norma Frontalis Check list

1. Frontal bone
2. Zygomatic bone
3. Maxilla
4. Mandible
5. Nasal bone
6. Orbital apertures.
7. Anterior nasal aperture
8. The supraciliary arch
9. The glabella
10. The nasion
11. The supraorbital foramen
12. Infraorbital foramen
13. Maxillary process of frontal bone
14. Zygomatic process of frontal bone
15. Frontal process of Maxilla
16. Frontal process of Zygomatic
17. Alveolar process of Maxilla
18. The two alveolar processes unite to form the alveolar arch
19. Zygomatic process of Maxilla
20. Maxillary process of Zygomatic
21. Zygomatico-facial foramen

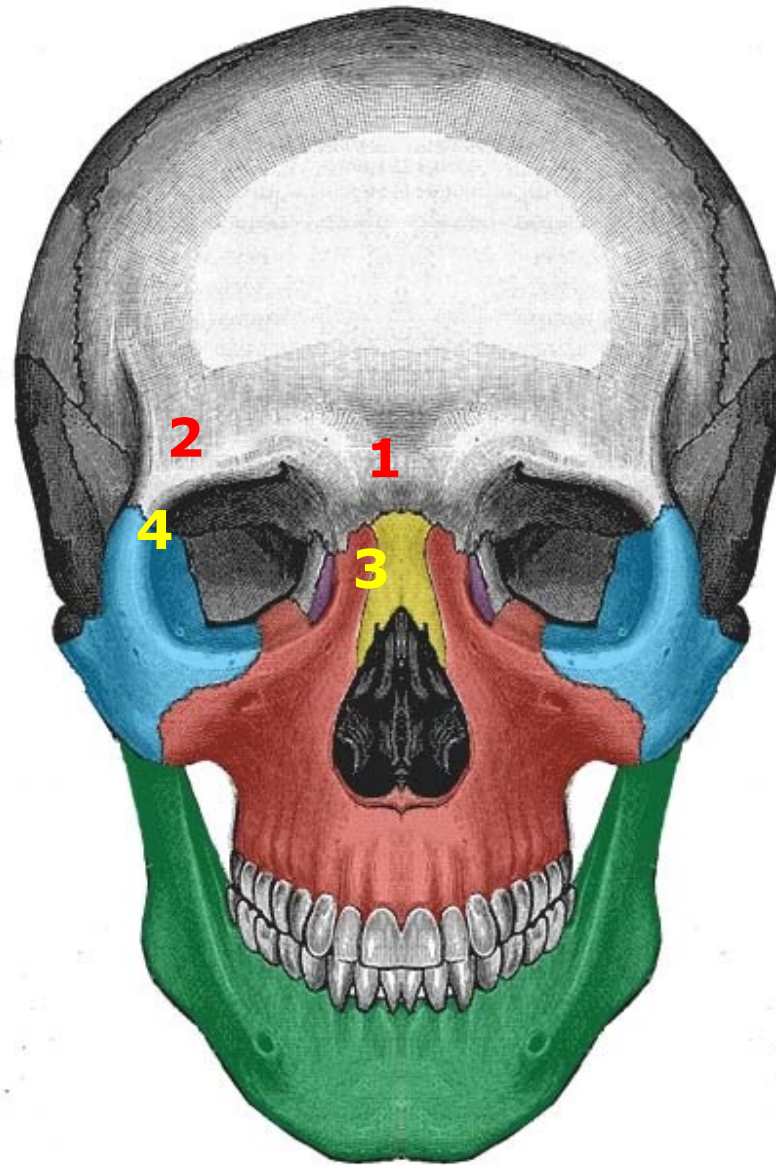
1. Frontal bone
2. Zygomatic bone
3. Maxilla
4. Mandible
5. Nasal bone
6. Orbital apertures.
7. Anterior nasal aperture



1. The superciliary arch
2. The glabella
3. The nasion
4. The supraorbital foramen



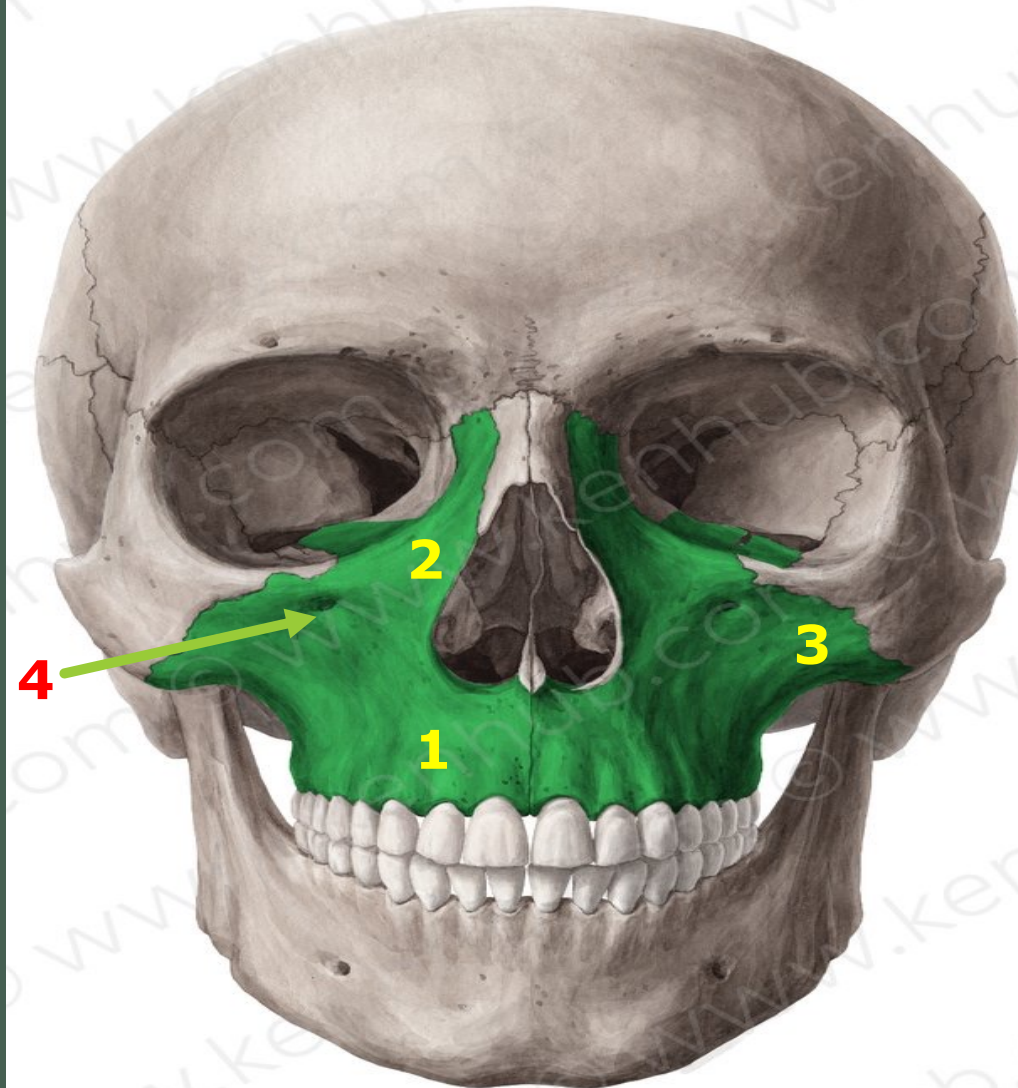
1. Maxillary process of frontal bone
2. Zygomatic process of frontal bone
3. Frontal process of Maxilla
4. Frontal process of Zygomatic



-  Zygomatic
-  Maxilla
-  Nasal
-  Lacrimal
-  Mandible

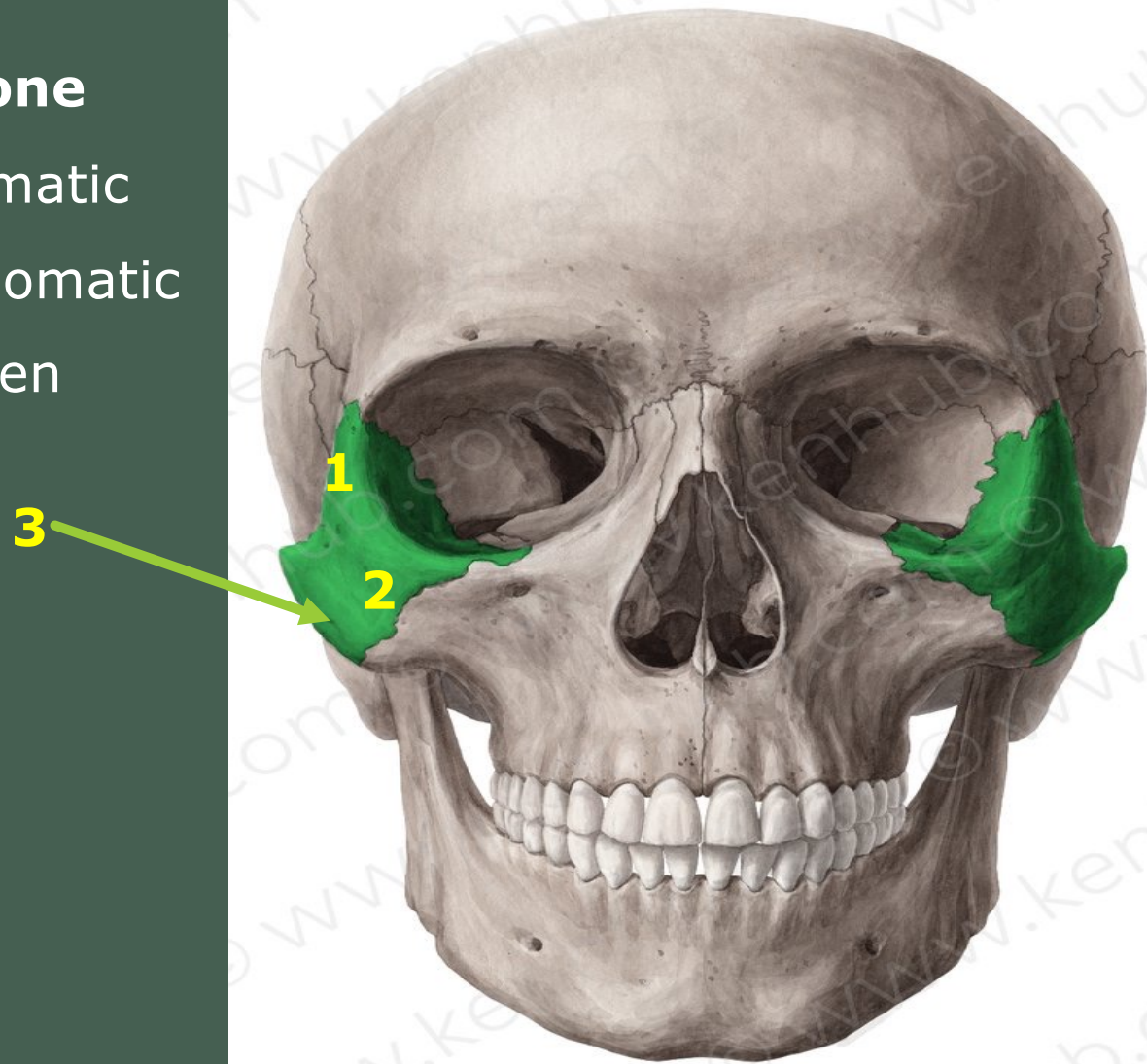
## Maxilla Bone

1. Alveolar process of Maxilla  
(The two alveolar processes unite to form the alveolar arch (= upper jaw)).
2. Frontal process of Maxilla
3. Zygomatic process of Maxilla
4. Infraorbital foramen



## Zygomatic Bone

1. Frontal process of Zygomatic
2. Maxillary process of Zygomatic
3. zygomatico-facial foramen

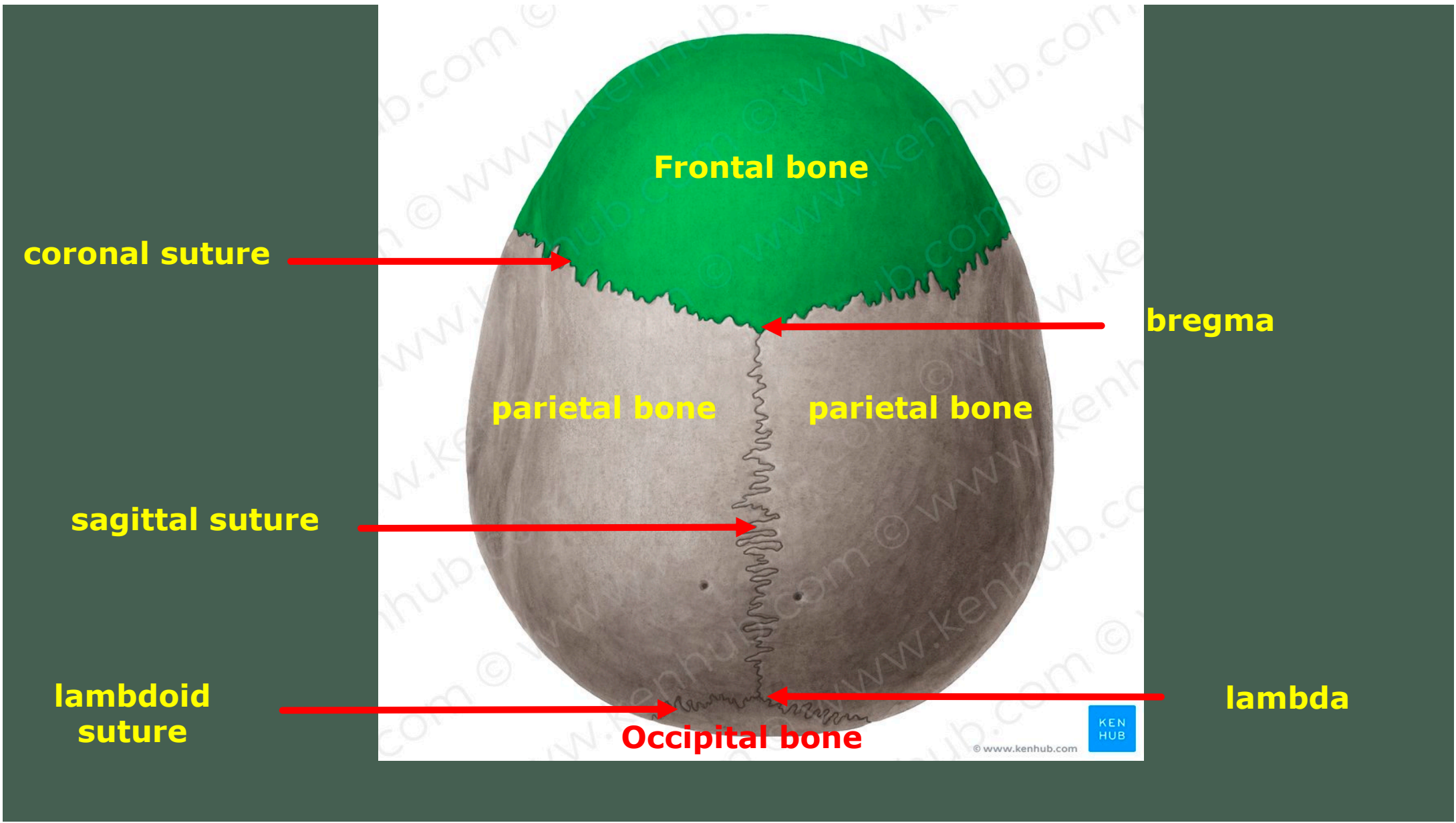




**NORMA VERTICALIS**

## **Norma Verticals Check list**

- 1- Frontal bone
- 2- Parietal bone
- 3- Occipital bone
- 4- Coronal suture
- 5- Sagittal suture
- 6- Lambdoid suture
- 7-Bregma
- 8-Lambda



**Frontal bone**

**coronal suture**

**bregma**

**parietal bone**

**parietal bone**

**sagittal suture**

**lambdoid suture**

**lambda**

**Occipital bone**

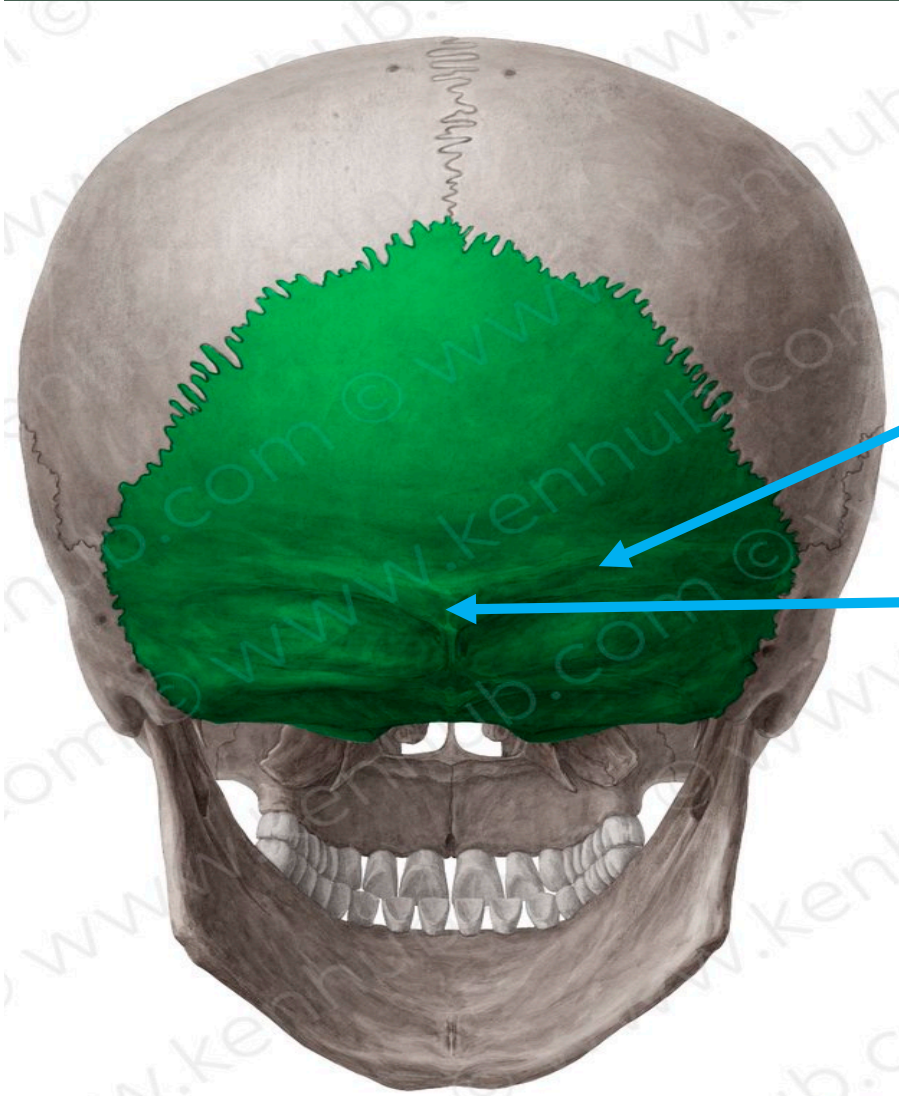


© www.kenhub.com

**NORMA OCCIPITALIS**

## **Norma Occipitalis Check list**

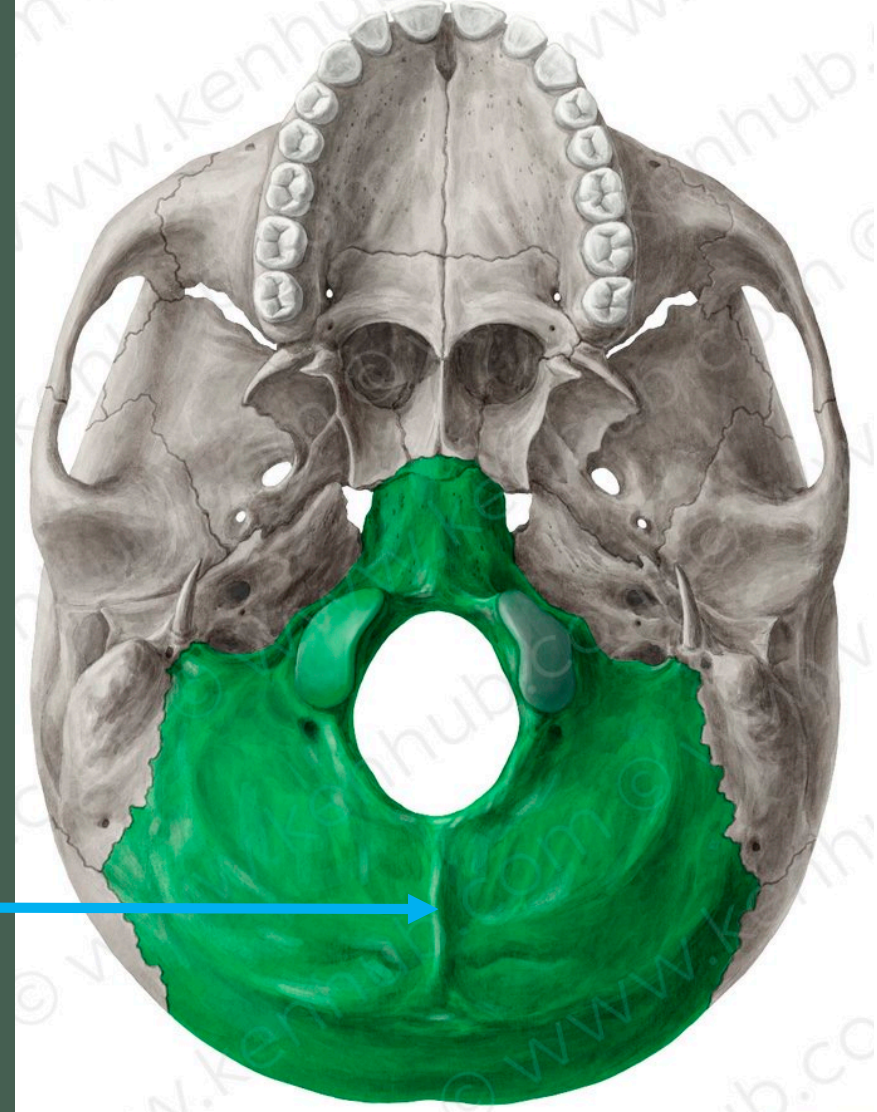
- 1- Superior nuchal lines
- 2-External occipital protuberance
- 3-External occipital crest
- 4-Squamous part of occipital bone



**Superior nuchal lines**

**External occipital protuberance**

**External occipital crest**

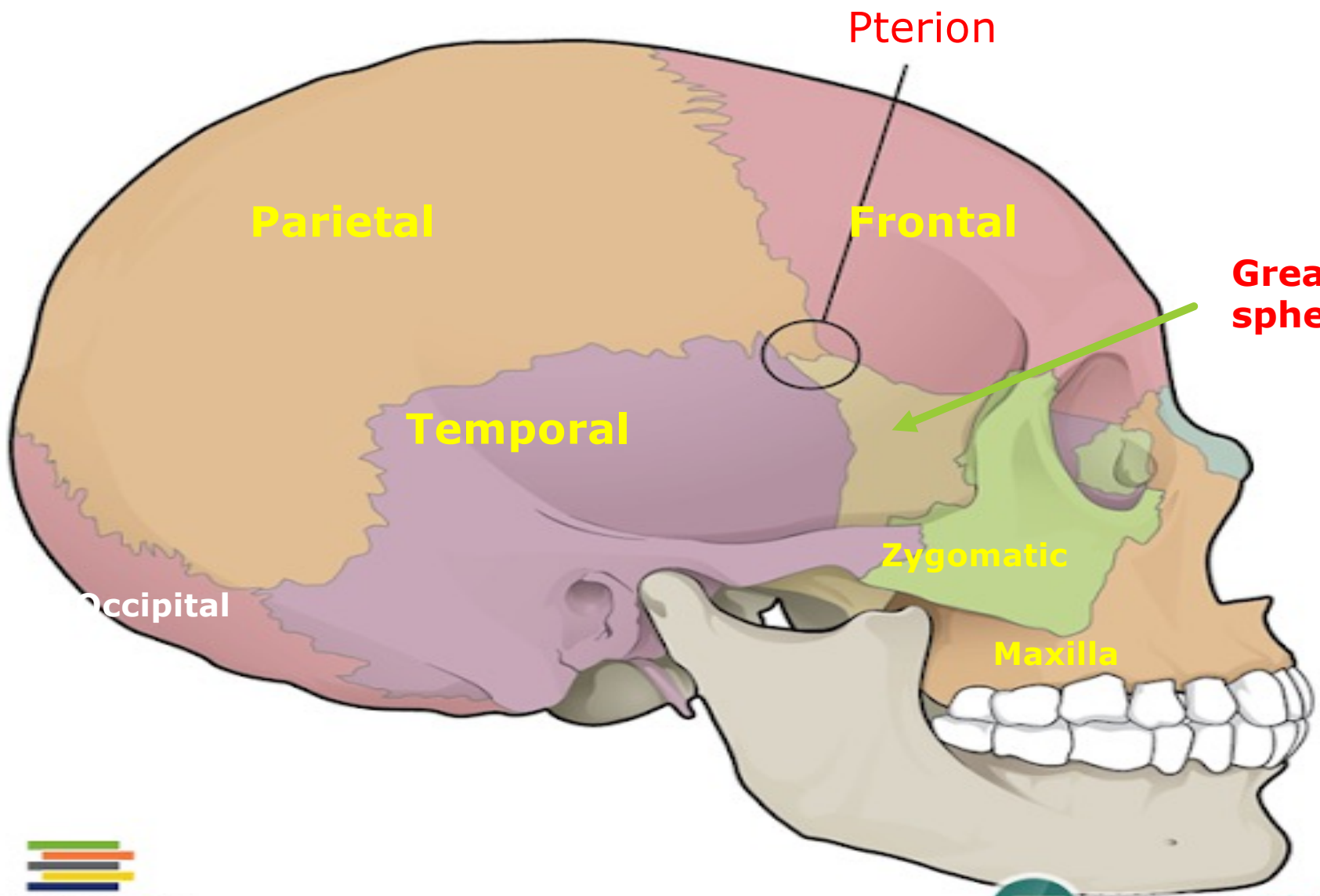


**NORMA LATERALIS**

## Check list

1. Pterion
1. Temporal lines (superior and inferior )
2. Temporal fossa
3. Zygomatic arch
4. The External Auditory Meatus
5. Suprameatal triangle
6. Infratemporal fossa
7. Temporal process of Zygoma
8. Zygomatic process of temporal bone
9. Zygomatic arch
10. Supramastoid crest
11. Mastoid process
12. Styloid process
13. Parts of Temporal bone
  - a) Squamous
  - b) Mastoid
  - c) Tympanic
  - d) Petrous





Pterion

Parietal

Frontal

Greater wing of sphenoid

Temporal

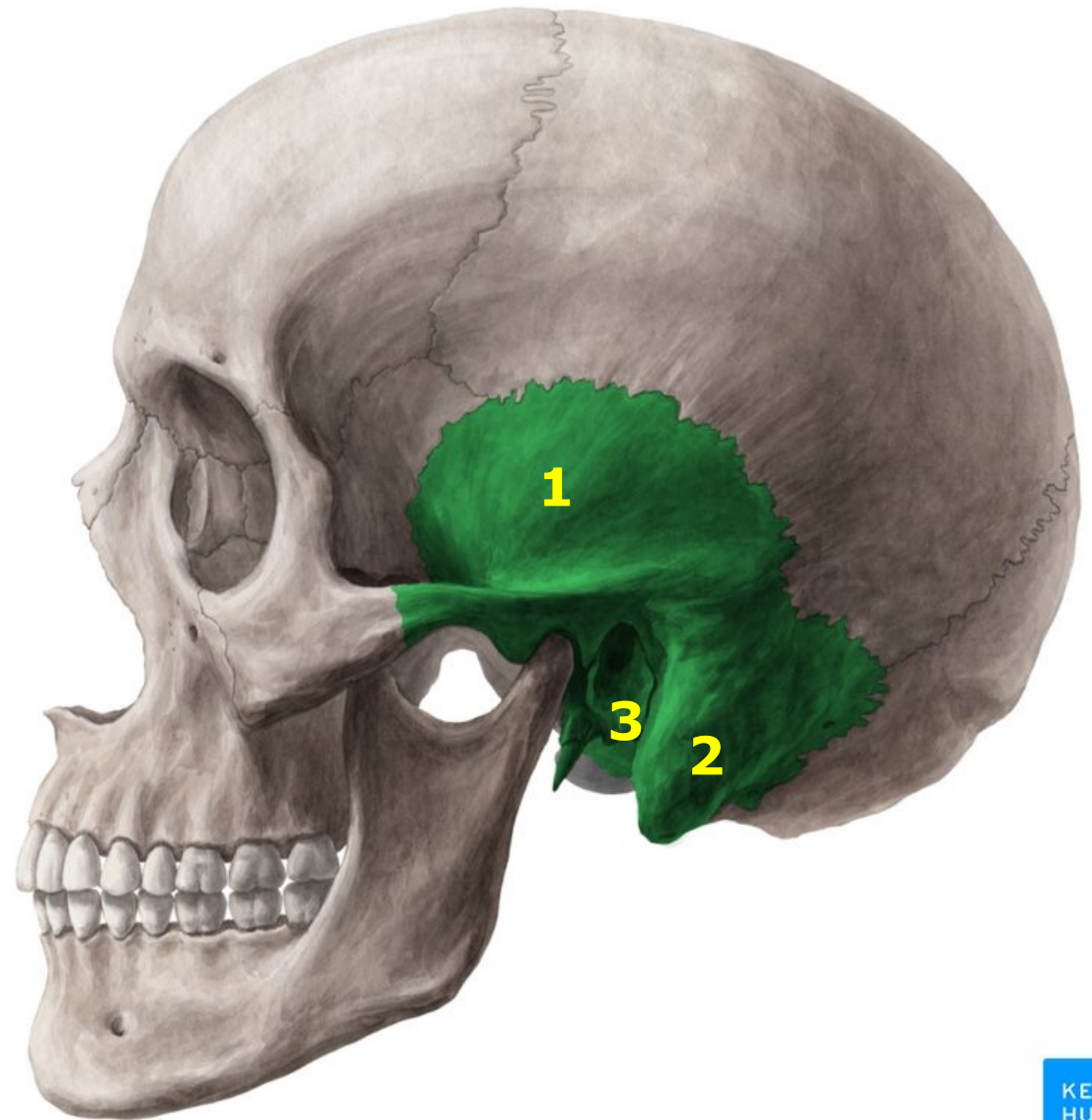
Zygomatic

Occipital

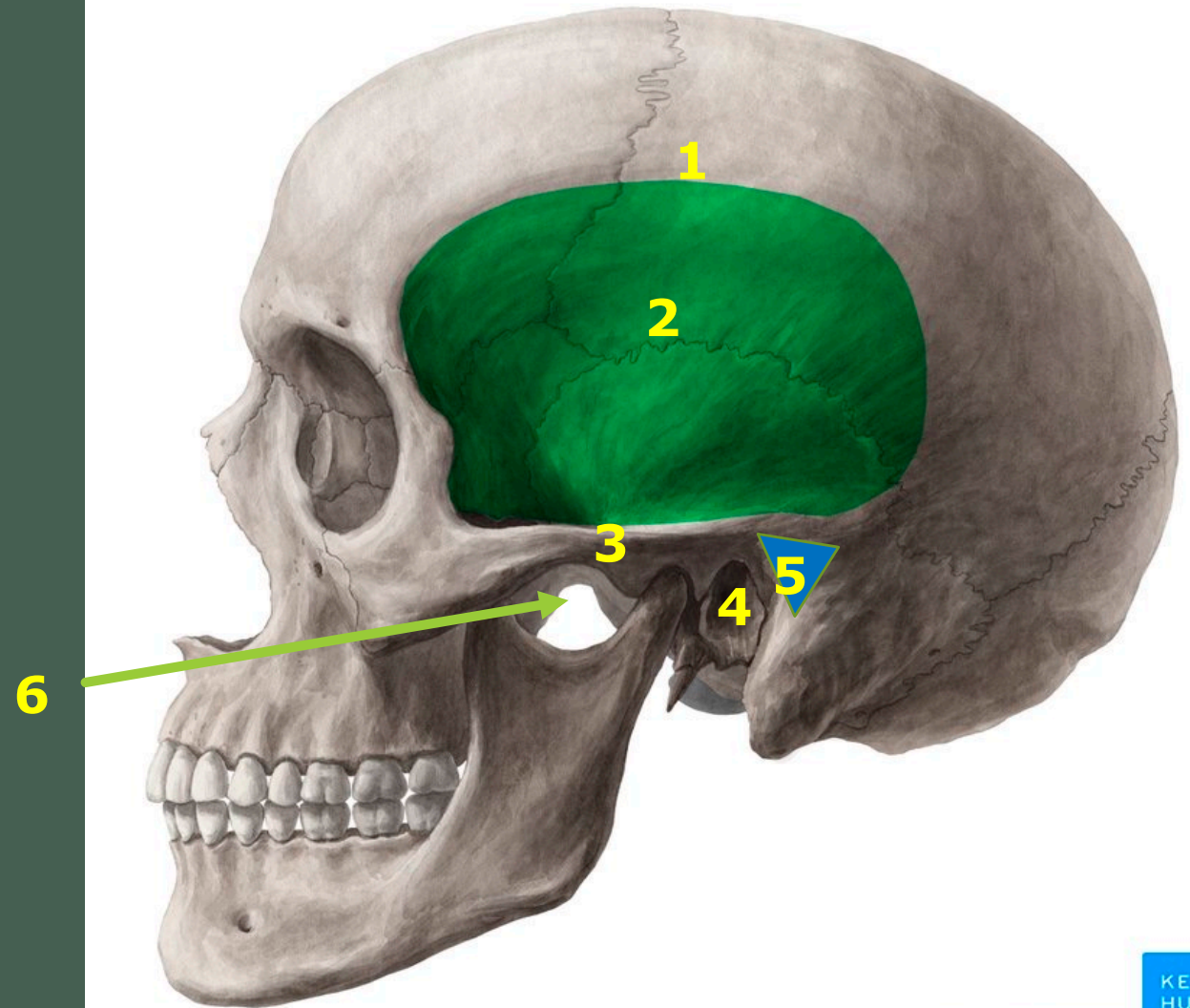
Maxilla

## Temporal bone

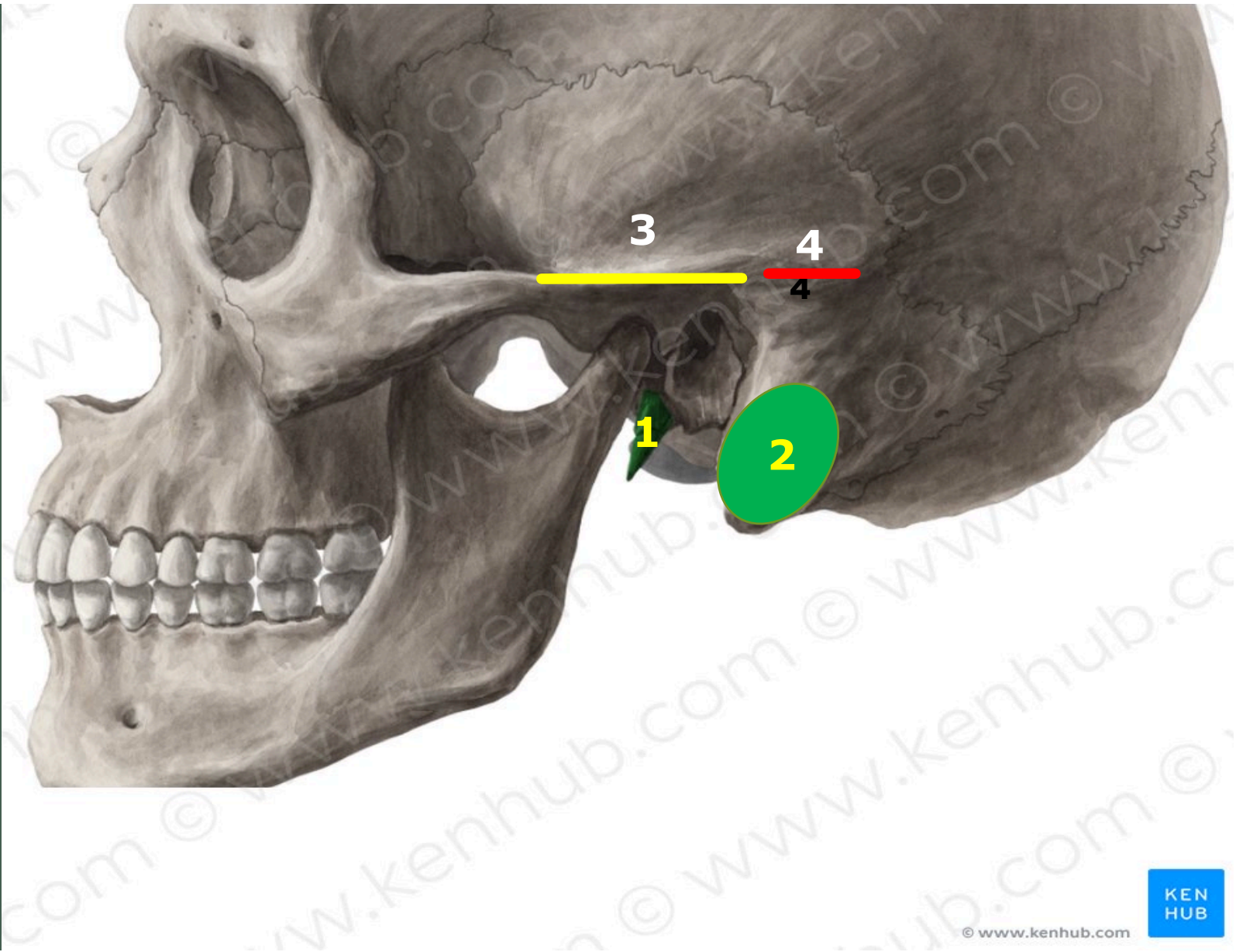
1. Squamous
2. Mastoid
3. Tympanic

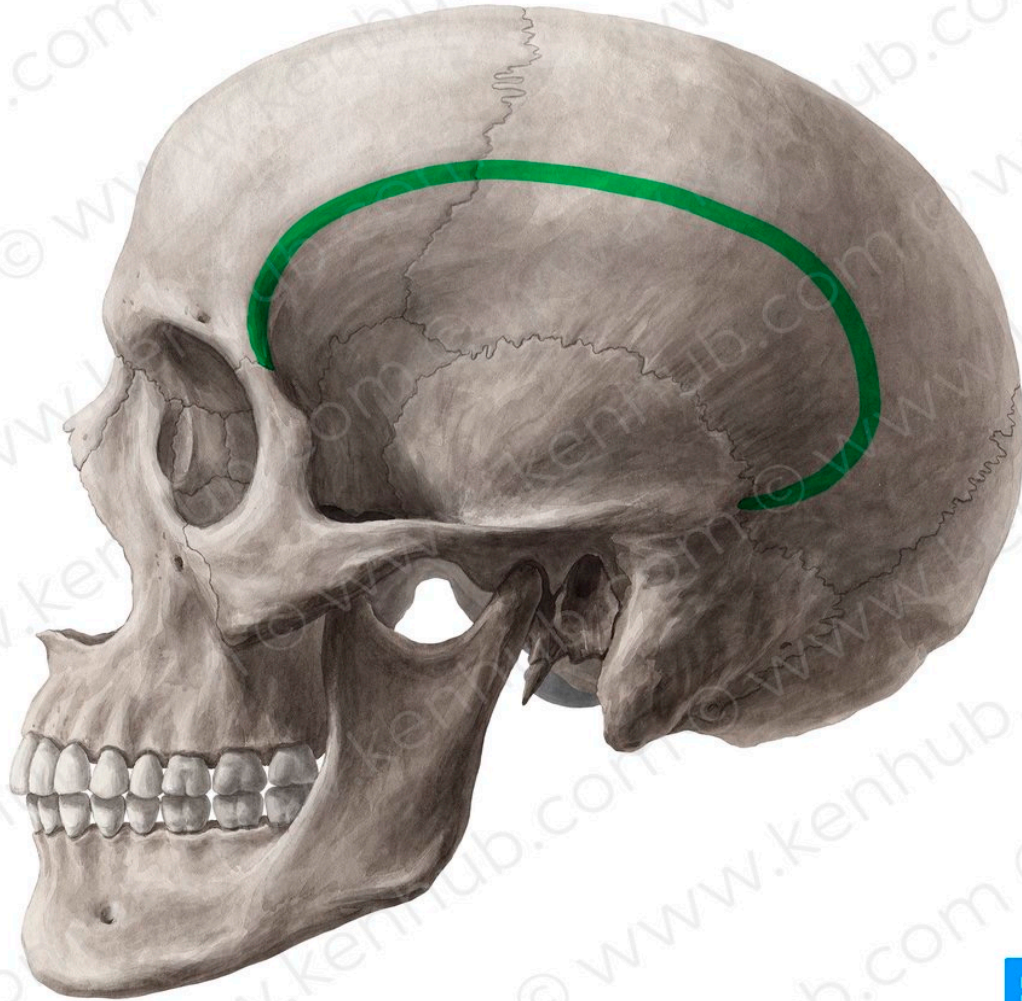


1. Temporal lines (superior and inferior )
2. Temporal fossa
3. Zygomatic arch
4. The External Auditory Meatus
5. Suprameatal triangle
6. Infratemporal fossa



- 1- Styloid process
- 2- Mastoid process
- 1. Zygomatic arch
- 2. Supramastoid crest

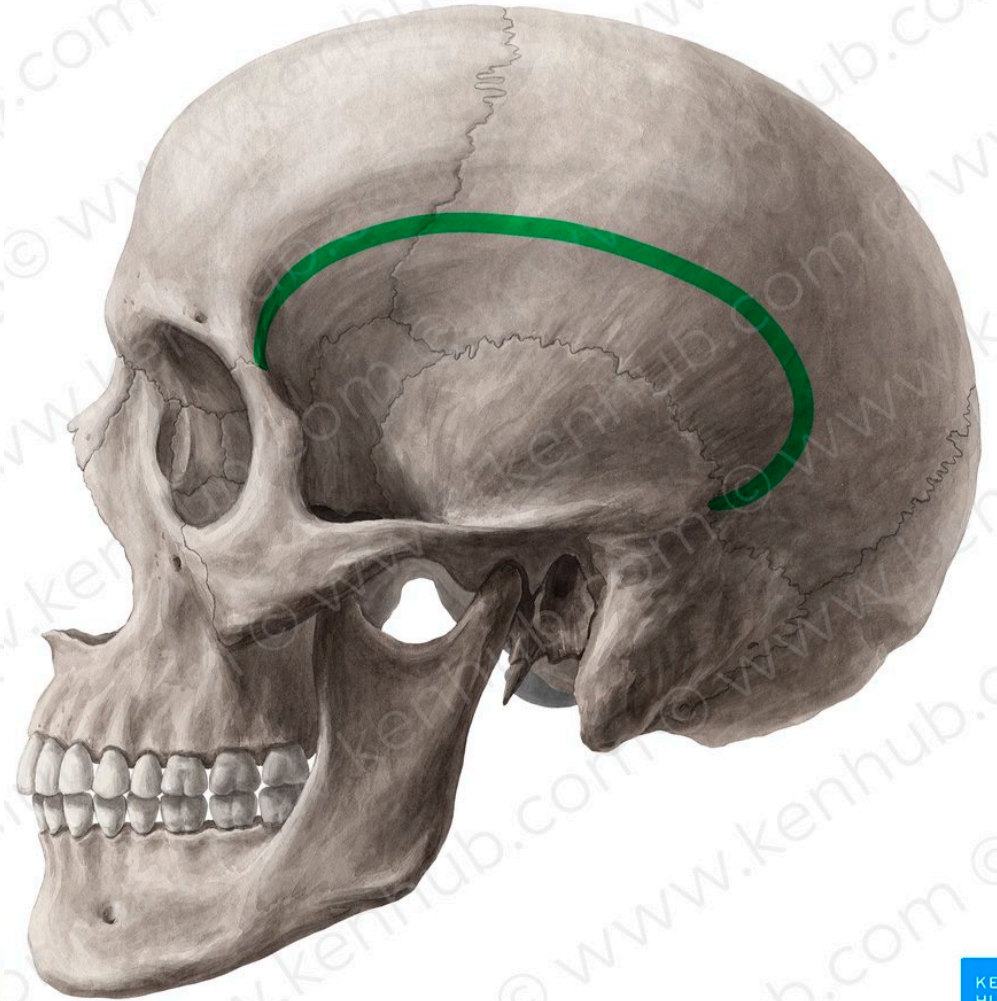




© www.kenhub.com



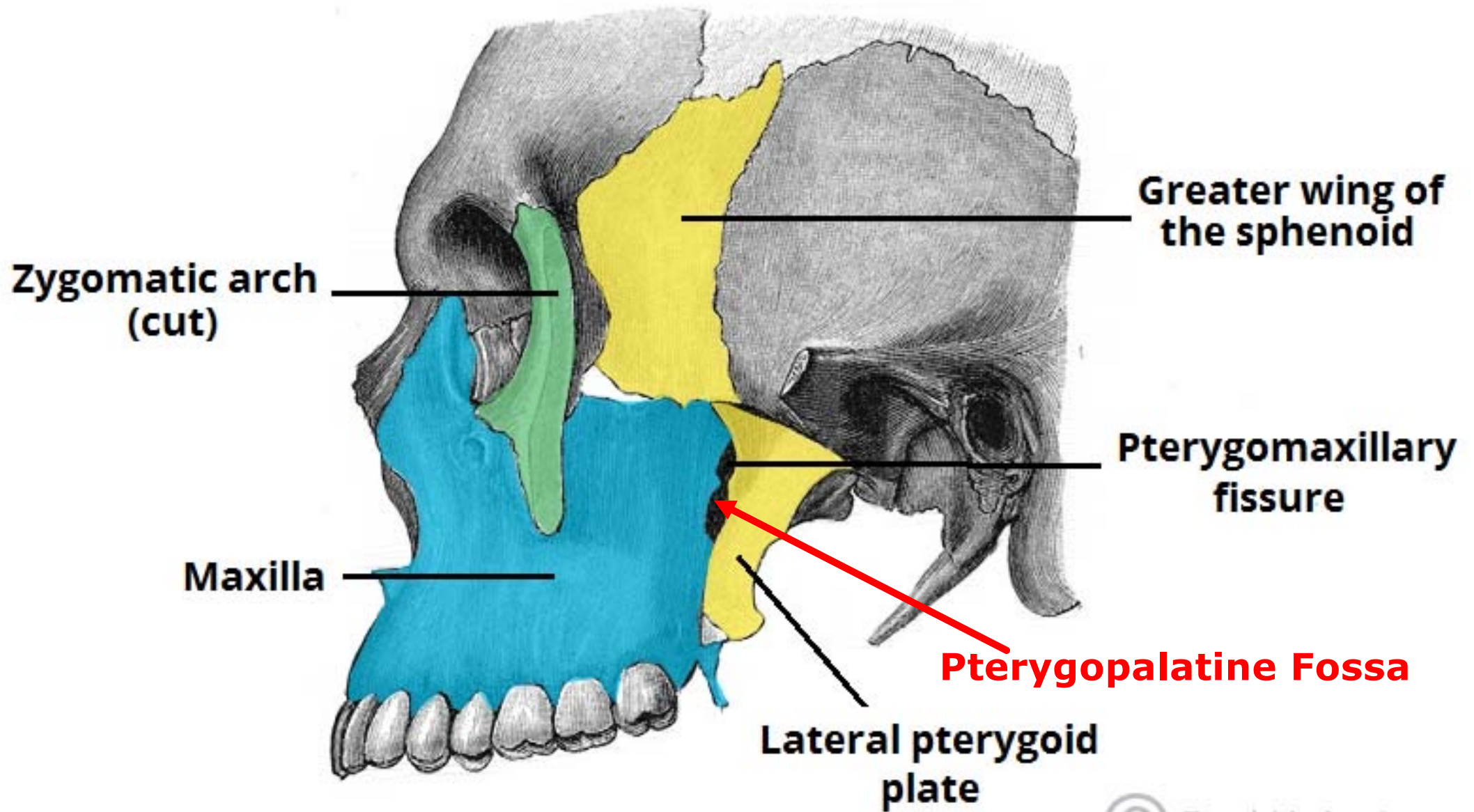
**Superior temporal line**



© www.kenhub.com



**Inferior temporal line**



Thank  
you

