# Anatomy of the Gastrointestinal Tract

Done by Joud Al zubaidi

هاد الملف تفريغ لكل كلام الدكتور محتسب بالمحاضرة سواء من السلايدات أو الكلام الخارجي و الصور يلي بيشرح عليها . ان شاء الله شامل كل شي ..
في صور إضافية من كتاب
Netters Atlas
ادعولي 💗

# * The Digestive System in the head and neck *

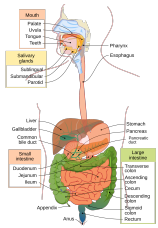


GI System جهاز

① Head and neck → mouth → tongue
→ Salivary gland
→ palate
→ pharynx

② Abdominal organs → Alimentary tract قناة هضمية [tube] Start in the Oral Cavity End in the anal Canal

Oral Cavity → Pharynx → Esophagus → Stomach → Small intestine → large intestine → Rectum and anal Canal

③ Association Organ → Salivary gland → liver → Gall bladder
→ Spleen
→ Pancreas

All of them open in the Alimentary tract

Function of GI ① Digestion of Food turning the Complicated material into Simple Absorbable material
Carbohydrate → Glucose
Fats → Fatty acid
protein → Amino acid

② Absorption of Absorbable material after Digestion
↳ وين بيروح ؟ portal vein → Through the portal Circulation to the Liver
- metabolism.
- produce the bile.
- Enzymes and hormones for Coagulation.
- Storage of Glycogen
- Detoxication

Deloxic material and Waste Product وين بيروح ؟ inferior Vena Cava to the Heart to be oxidised ...

Through what Vein? Hepatic Vein

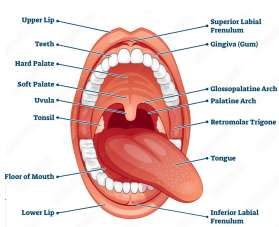


## Oral Cavity .. Mouth :

the alimentary tract begin at the mouth wich has 2 opening :

→ Anterior + Posterior

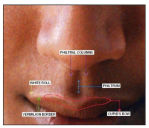

# Anterior opening lies between the upper and lower lip ...
→ between them there is the Oral opening.

The Lips Contain Circular Striated muscle act as Sphincter Called :

Orbicularis Oris Supplied by Facial Nerve

A Facial Nerve injury (palsy) result in :

# lips are important in articulation .
أحرف الشفة .

inability For Whistling.

inability to blow his cheeks .

Orbicularis Oris

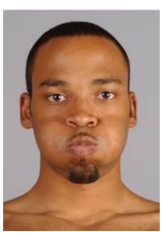

Buccinator

# When chewing there is a Drop of Saliva from the mouth .

→ the Upper lip Originate from the maxillary prominence and medial nasal prominence they Contact with each other in the lateral 2/3 and medial 1/3 ...

→ Failure of fusion will result in Cleft lip

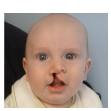

[Bilateral , Unilateral]

→ Philtrum Vertical Depression in midline → Efusion between Right and left medial nasal prominence

The lips have 3 Zones :

hair follicle ← Sweat gland → Sebaceous gland

1. Outer Zone (Skin) Stratified Squamous Keratinized Epithelium
2. inner Zone (Orally) Stratified Squamous Non Keratinized Epithelium

Contain Labial gland (mucos gland) in the internal mucosa.

3. Red Zone Transitional / Vermilion Zone Stratified Squamous Modified
   ↳ ↑↑ Blood Vesseles ↑↑↑ Nerve terminal → Sensetive

# Posterior Opening Oropharyngeal isthmus / Phasis :

Boundaries :

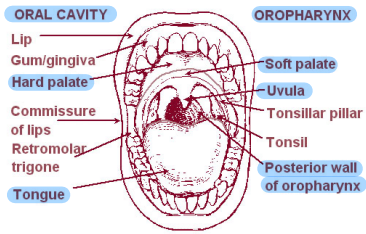


Roof : Soft palate + Uvula
floor : posterior 1/3 of the tongue (liguinal tonsil)
↳ lymphoid tissue

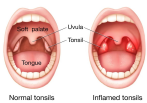


laterally: palatine tonsil in both Sides
↳ Filtration for the bacteria, Viruses and foreign bodies ...

→ in Children : Common Site for inflammation result in Tonsillitis

Palatine tonsils on the lateral Side of Oropharyngeal isthmus between 2 fold : 1) Anteriorly Plato glossal Contain The Palatoglossus muscle
2) Posterior Plato pharyngeal Contain The palatopharengues muscle

# The Oral Cavity is Divided into :

## ① Vestibule وين ما بخط مربشابة سلك و

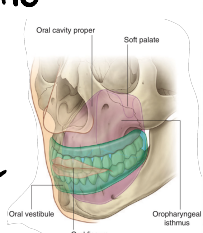


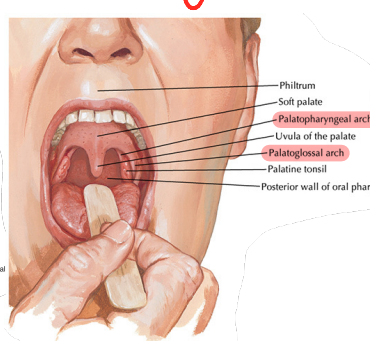


The Space between the teeth medially, the cheeks laterally, the lips Anterior.

→ function : The Duct of the parotid gland (Salivary gland) open in it at the level of upper Second molar teeth ..

The Secretion of the parotid go from the Vestibule to the mouth proper

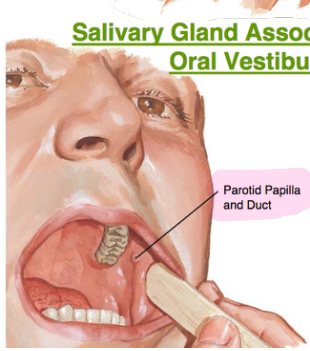

## ② The mouth proper : Cavity inside Closed teeth (upper and lower Jaw)

boundaries: Roof: Hard palate.
Floor: Anterior 2/3 Tongue
laterally: Closed teeth.

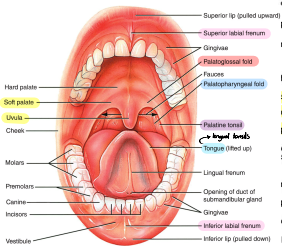


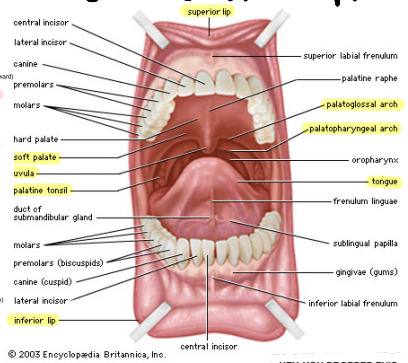

→ Mucous Membrane of the mouth is 2 Types:

1. Soft + elastic Connective tissue form the mucosa.
→ Under the tongue and floor of the mouth.

2. Dense Connective tissue
Cover the Hard palate, gums and teeth

## Sensory Innervation of The mouth :

→ Hard palate.

# Remember :

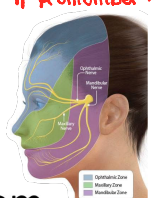


- **Roof:** The greater palatine and nasopalatine nerves from the maxillary division of the trigeminal nerve
  Touch, Tem., pain → General Sensation [common sensation]
- **Floor:** The lingual nerve [common sensation], a branch of the mandibular division of the trigeminal nerve.
  → Special Sensation
  [The taste fibers] travel in the chorda tympani nerve, a branch of the facial nerve.
  Come from the Dorsum of the tongue that Contain taste buds براعم ذوقية

Taste buds:

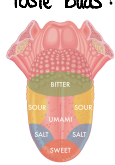


- **Cheek:** The buccal nerve, a branch of the mandibular division of the trigeminal nerve (the buccinator muscle is innervated by the buccal branch of the facial nerve)

Sensory ← motor →

# Blood Supply to the mouth: Branches from the Facial → + Lingual Artery ...

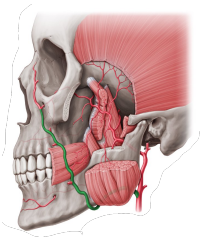

## The teeth:

Located in the Gum (Gingiva) اللثة, each teeth have a Socket embedded in it, around it there is D.C.T

- Deciduous teeth. لبنية
- permanent teeth. دائمة

### Deciduous Teeth

- There are 20 deciduous teeth: four incisors, two canines, and four molars in each jaw
- They begin to erupt about 6 months after birth and have all erupted by the end of 2 years.
- The teeth of the lower jaw usually appear before those of the upper jaw.

### Permanent Teeth

- There are 32 permanent teeth: four incisors, two canines, four premolars, and six molars in each jaw → Wisdom tooth.
- They begin to erupt at 6 years of age — الطفل يبلش يبدل أسنانه
- The last tooth to erupt is the third molar, which may happen between the ages of 17 and 30 يكتمل النمو على ١٧ سنة ماعدا الـ Wisdom
- The teeth of the lower jaw appear before those of the upper jaw.

## The tongue:

Muscular Organ

كل شي عصبي إلا على اليمين ← موجود على الشمال..

### Intrinsic

bundles of muscle fiber (longitudenal, transverse, Oblique)

### Extrinsic [Symmetrical]

muscle that Came from the Skull or the Surrounding bones to the tongue

Responsible: The Shape of tongue.

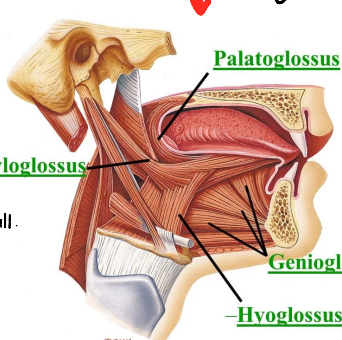


Palatoglossus → From the palate

Styloglossus → Styloid process of Skull.

Genioglossus → Superior genial Tubercle of Mandible

Hyoglossus → Hyoid bone

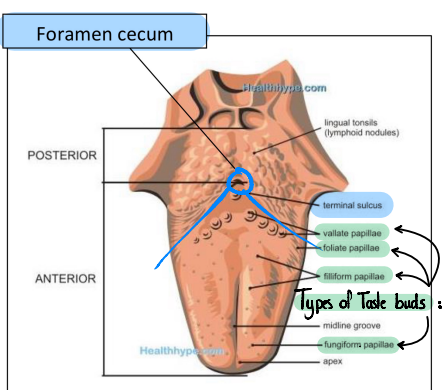


The tongue is divided

Anterior 2/3 | Posterior 1/3

By: 1. Foramen Cecum → V-Shaped
2. Sulcus Terminalis

Depending in the Development..

→ posterior 1/3 : Contain lymphoid tissue → Lingual tonsils

→ Anterior 2/3 : Contain Taste buds on the Dorsum Surface → for the taste Sensation

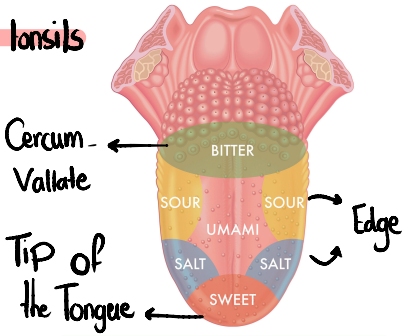


# Mucous Membrane of the tongue :

**Dorsal Surface (upper) :**

- Stratified Squamous
- Para - Keratinized .

**Ventral Surface (Lower) :**

- Stratified Squamous
- Non Keratinized .

with the Digestion and Secretion the Keratin will be injured .

* If filled with taste buds (papillae)

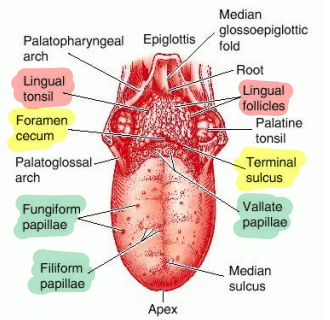


Glossopharyngeal posterior 1/3

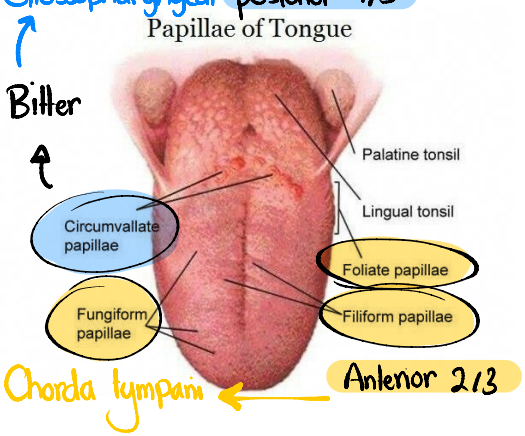


Bitter

Chorda tympani

Anterior 2/3

# Muscles

## Intrinsic

- The muscles of the tongue are divided into two types: intrinsic and extrinsic
- Intrinsic Muscles
- These muscles are confined to the tongue and are not attached to bone.
- They consist of longitudinal, transverse, and vertical fibers.
- Nerve supply: Hypoglossal nerve
- Action: Alter the shape of the tongue

## Extrinsic

- These muscles are attached to bones and the soft palate
- They are the genioglossus (Superior genial spine of mandible), Protrudes apex of tongue through mouth
- the hyoglossus (Body and greater cornu of hyoid bone), Depresses tongue
- the styloglossus (Styloid process of temporal bone), Draws tongue upward and backward
- and the palatoglossus (Palatine aponeurosis), Pulls roots of tongue upward and backward, narrows oropharyngeal isthmus
- Insertion : Blends with eachother, the palatoglossus inserts at Side of tongue
- Nerve supply: Hypoglossal nerve

# Genioglossus : is The only muscle that extend the tongue outside the mouth this is why it's inserted to the base and posterior to the mouth [Straight] the 2 Side work

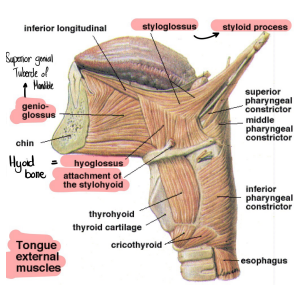

Doctor said to read the below two slides.

# Extrinsic Muscles

The **extrinsic muscles of the tongue** attach to bones or the soft palate and are responsible for the **position and gross movements of the tongue**. These muscles include:

## 1. Genioglossus

- **Origin**: Superior mental (genial) tubercle (spine) of the mandible
- **Insertion**: Base of the tongue, extending posteriorly
- **Action**: **Protrudes the apex of the tongue** through the mouth
- When the tongue is protruded in a **straight, midline position**, it indicates that **both genioglossus muscles are functioning symmetrically** on either side.
- The **genioglossus is clinically important** because it is innervated by the **hypoglossal nerve (cranial nerve XII)**. If the **right hypoglossal nerve is injured**, the **right genioglossus becomes paralyzed**, causing the tongue to **deviate toward the paralyzed side (right side)** when protruded.

## 2. Hyoglossus

- **Origin**: Body and greater cornu of the hyoid bone
- **Insertion**: Base of the tongue
- **Action**: **Depresses the tongue**

## 3. Styloglossus

- **Origin**: Styloid process of the temporal bone
- **Insertion**: Base of the tongue posteriorly
- **Action**: **Draws the tongue upward and backward**

## 4. Palatoglossus

- **Origin**: Palatine aponeurosis
- **Insertion**: Side of the tongue
- **Action**: Pulls roots of tongue upward and backward and narrows oropharyngeal isthmus

**Insertion Note:**

- These muscles' insertions **blend with each other**

- **Nerve Supply:**
  - All extrinsic muscles of the tongue are innervated by the **hypoglossal nerve (cranial nerve XII)**,
  - **Except for the palatoglossus**, which is supplied by the **cranial accessory of vagus nerve**.

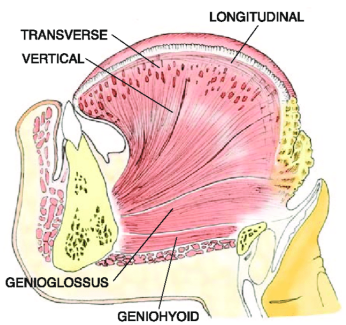


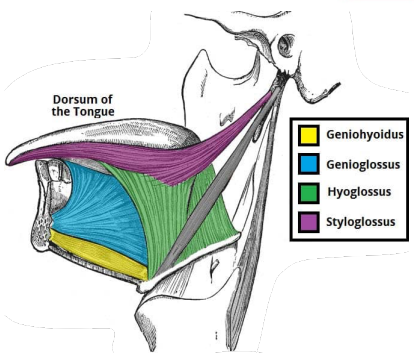


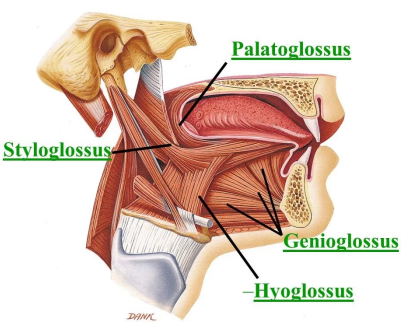


**Table 8.21** Muscles of the tongue

| Muscle | Origin | Insertion | Innervation | Function |
|---|---|---|---|---|
| Intrinsic | | | | |
| Superior longitudinal (just deep to surface of tongue) | Submucosal connective tissue at the back of the tongue and from the median septum of the tongue | Muscle fibers pass forward and obliquely to submucosal connective tissue and mucosa on margins of tongue | Hypoglossal nerve [XII] | Shortens tongue; curls apex and sides of tongue |
| Inferior longitudinal (between genioglossus and hyoglossus muscles) | Root of tongue (some fibers from hyoid) | Apex of tongue | Hypoglossal nerve [XII] | Shortens tongue; uncurls apex and turns it downward |
| Transverse | Median septum of the tongue | Submucosal connective tissue on lateral margins of tongue | Hypoglossal nerve [XII] | Narrows and elongates tongue |
| Vertical | Submucosal connective tissue on dorsum of tongue | Connective tissue in more ventral regions of tongue | Hypoglossal nerve [XII] | Flattens and widens tongue |
| Extrinsic | | | | |
| Genioglossus | Superior mental spines | Body of hyoid; entire length of tongue | Hypoglossal nerve [XII] | Protrudes tongue; depresses center of tongue |
| Hyoglossus | Greater horn and adjacent part of body of hyoid bone | Lateral surface of tongue | Hypoglossal nerve [XII] | Depresses tongue |
| Styloglossus | Styloid process (anterolateral surface) | Lateral surface of tongue | Hypoglossal nerve [XII] | Elevates and retracts tongue |
| Palatoglossus | Inferior surface of palatine aponeurosis | Lateral margin of tongue | Vagus nerve [X] (via pharyngeal branch to pharyngeal plexus) | Depresses palate; moves palatoglossal fold toward midline; elevates back of the tongue |

## Tongue tell the truth

**Lesion**

- Atrophy of ipsilateral tongue muscles
- Deviation of the tongue to the paralyzed side,

Why ????

The tongue being pushed by the genioglossus muscle of the normal side

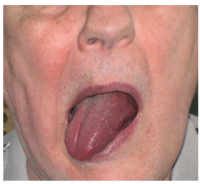

Right Hypoglossal Nerve palsy

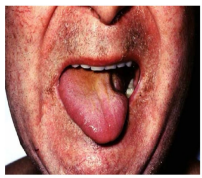

Left Hypoglossal Nerve palsy

This muscle is an important muscle, contraction of both muscles (right and left) protrudes the tongue straightly outside the mouth. While the rest of the muscles move it backwards, upwards, downwards.

So, Injury of the right hypoglossal nerve for example will cause paralysis of the right genioglossus muscle (and all muscles supplied by the right hypoglossal), resulting in right deviation of the tongue (the tongue will be deviated to the paralyzed side).

https://youtu.be/6eyp-TRFsDY?feature=shared

Explanation: when only the left side protrudes the tongue (because the right side is paralyzed) the tongue will be pushed towards the paralyzed side because it is not functioning and doing its job (no resistance on the right side).

# Sensory innervation of the Tongue :

General Special → taste

**Very Important**

Via the circumvallate papillae, although they are found in the anterior two thirds but they originated from the posterior third and follow its innervation.سؤال امتحان

- Sensory Innervation
  - Anterior two thirds: Lingual nerve branch of mandibular division of trigeminal nerve (general sensation) and chorda tympani branch of the facial nerve (taste)
  - Posterior third: Glossopharyngeal nerve (general sensation and taste)

Motor: Hypoglossal (XII), *except* Palatoglossus: Pharyngeal branch of Vagus (X)

**Posterior 1/3**

Sensory and Taste: Glossopharyngeal (IX)

Sensory: Lingual branch of V3 from Trigeminal (V)

Taste: Chorda tympani branch of Facial (VII), carried by lingual branch

**Anterior 2/3**

**Note:** Although the **posterior one-third of the tongue** is largely composed of **lymphoid tissue** (forming the **lingual tonsil**), **taste sensation** in this region is provided by the **circumvallate papillae**.

- Blood Supply
  - The lingual artery, the tonsillar branch of the facial artery, and the ascending pharyngeal artery supply the tongue, and all of those are branches from the external carotid artery.

- The veins drain into the internal jugular vein. Tributaries veins (opposite of arteries) drain into internal jugular vein.

- Lymph Drainage
- Tip: Submental lymph nodes
- Sides of the anterior two thirds: Submandibular and deep cervical lymph nodes
- Posterior third: Deep cervical lymph nodes

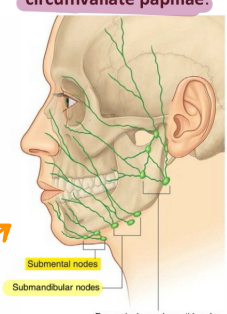


*Structures in the midline drain into the submental lymph nodes like the tip of the tongue , the philtrum , the mid of the lower lip and the tip of the nose

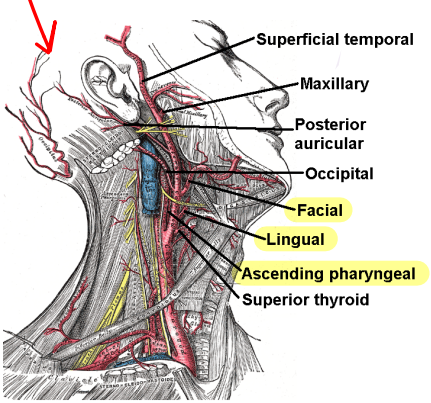


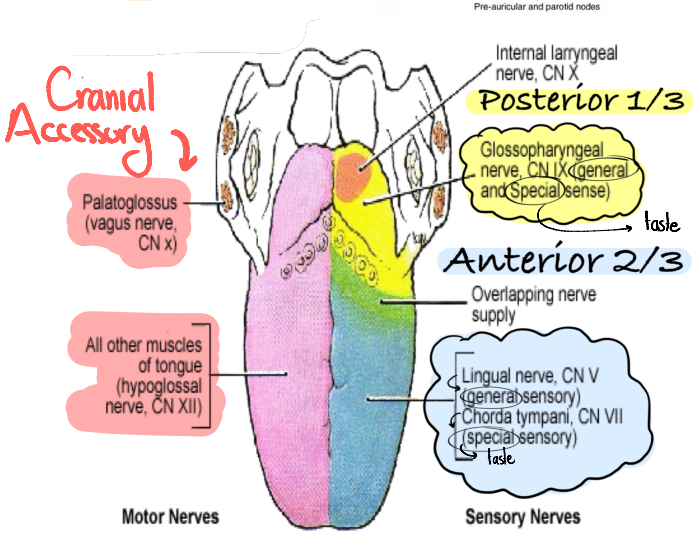

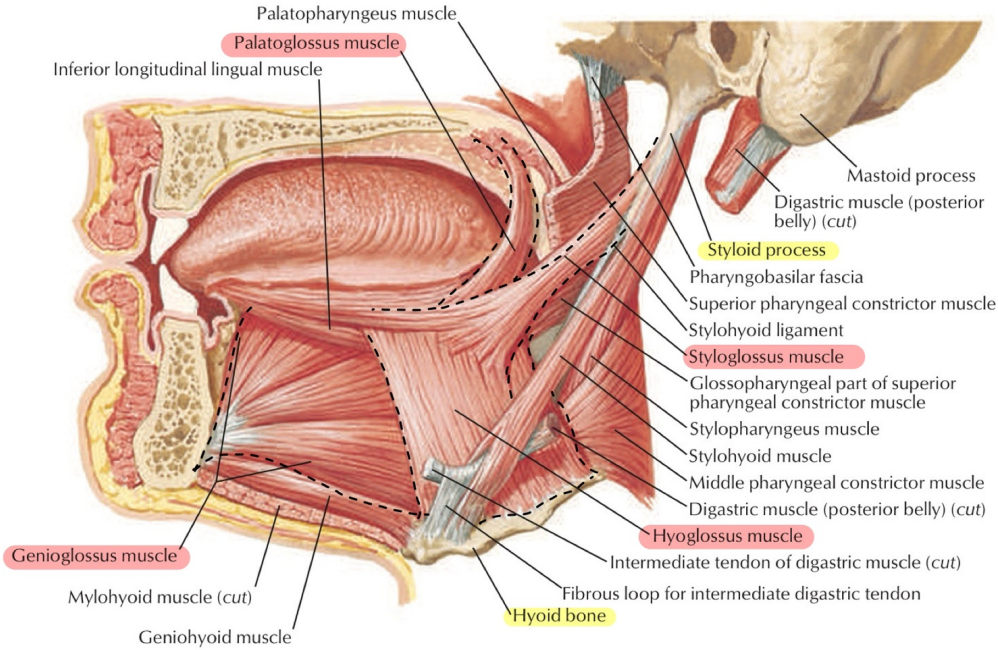
Palatopharyngeus muscle
Palatoglossus muscle
Inferior longitudinal lingual muscle
Mastoid process
Digastric muscle (posterior belly) (cut)
Styloid process
Pharyngobasilar fascia
Superior pharyngeal constrictor muscle
Stylohyoid ligament
Styloglossus muscle
Glossopharyngeal part of superior pharyngeal constrictor muscle
Stylopharyngeus muscle
Stylohyoid muscle
Middle pharyngeal constrictor muscle
Digastric muscle (posterior belly) (cut)
Hyoglossus muscle
Intermediate tendon of digastric muscle (cut)
Fibrous loop for intermediate digastric tendon
Hyoid bone
Genioglossus muscle
Mylohyoid muscle (cut)
Geniohyoid muscle

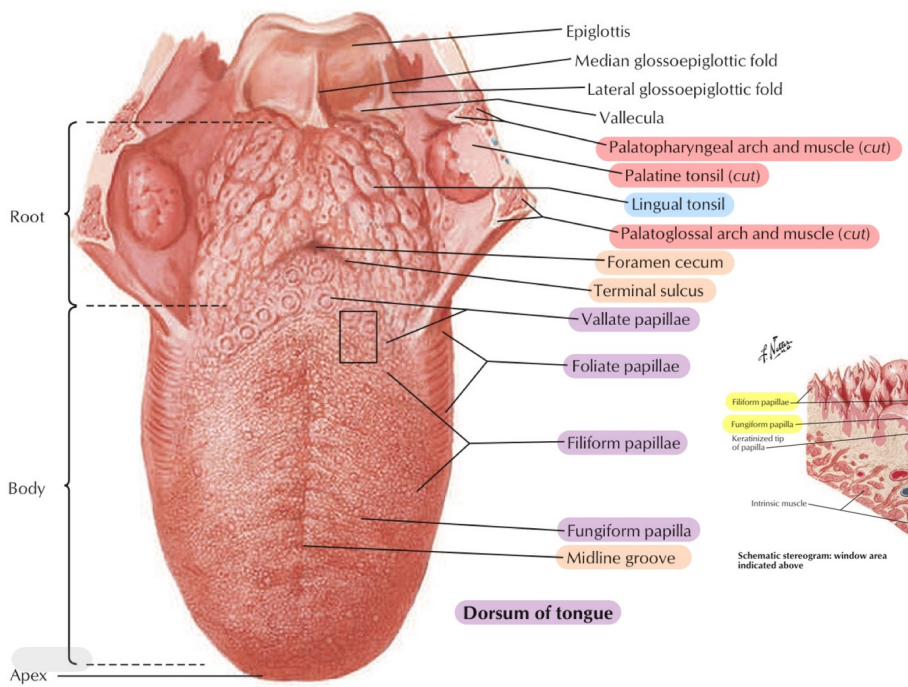
Epiglottis
Median glossoepiglottic fold
Lateral glossoepiglottic fold
Vallecula
Palatopharyngeal arch and muscle (cut)
Palatine tonsil (cut)
Lingual tonsil
Palatoglossal arch and muscle (cut)
Foramen cecum
Terminal sulcus
Vallate papillae
Foliate papillae
Filiform papillae
Fungiform papilla
Midline groove
Root
Body
Apex
Dorsum of tongue

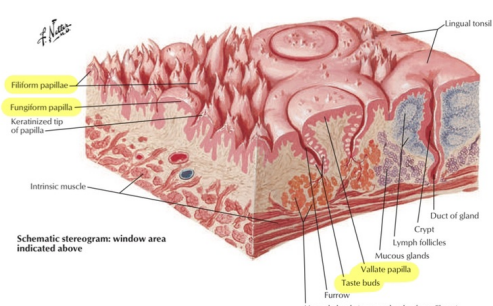
Lingual tonsil
Filiform papillae
Fungiform papilla
Keratinized tip of papilla
Intrinsic muscle
Duct of gland
Crypt
Lymph follicles
Mucous glands
Vallate papilla
Taste buds
Furrow
Lingual glands (serous glands of von Ebner)
Schematic stereogram: window area indicated above

- Salivary glands are classified into **two main types**:

1. **Minor Salivary Glands**
   - These are **numerous** and are **mostly mucous-secreting glands**.
   - They are **scattered throughout the oral cavity** and include:
     1. **Labial glands** (within the lips)
     2. **Lingual glands** (on the tongue)
     3. **Palatal glands** (in the hard and soft palate)
2. **Major Salivary Glands**
   - There are **three pairs** of large salivary glands:
     1. **Parotid glands**
     2. **Submandibular glands**
     3. **Sublingual glands**

For each of the **major salivary glands**, it is essential to know the following details:
- **Location (site)**
- **Presence and type of capsule**
- **Duct and gland contents**
- **Type of secretion** (serous, mucous, or mixed)
- **Anatomical relations**
- **Innervation** (both sympathetic and parasympathetic)

- All major salivary glands are **surrounded by a capsule**, but the **parotid gland** is unique in that it has **two capsules**.
- **Type of Secretion:**
  1. **Parotid gland**: Produces **serous secretion**
  2. **Submandibular gland**: Produces **mixed secretion** (mostly serous, some mucous)
  3. **Sublingual gland**: Produces **mostly mucous secretion**
- **Innervation of Salivary Glands:**
  - Each major salivary gland receives **three types of innervation**:
    1. **Sensory innervation**: for general sensation
    2. **Sympathetic innervation**: causes **vasoconstriction** o blood vessels
    3. **Parasympathetic innervation**: **stimulates glandular secretion** (secretomotor fibers)

❖ While **sympathetic** and **parasympathetic** systems often have opposite effects, their roles in salivary glands differ:
- **Parasympathetic** innervation has a **direct effect** by stimulating saliva production.
- **Sympathetic** innervation does **not directly inhibit secretion**, but it causes **vasoconstriction**, which may **indirectly reduce salivary output** by limiting blood flow to the gland.

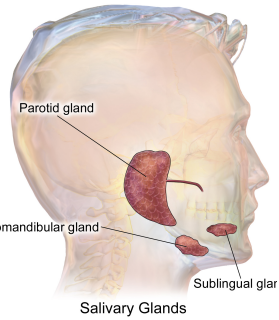


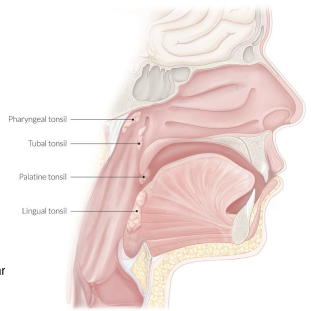


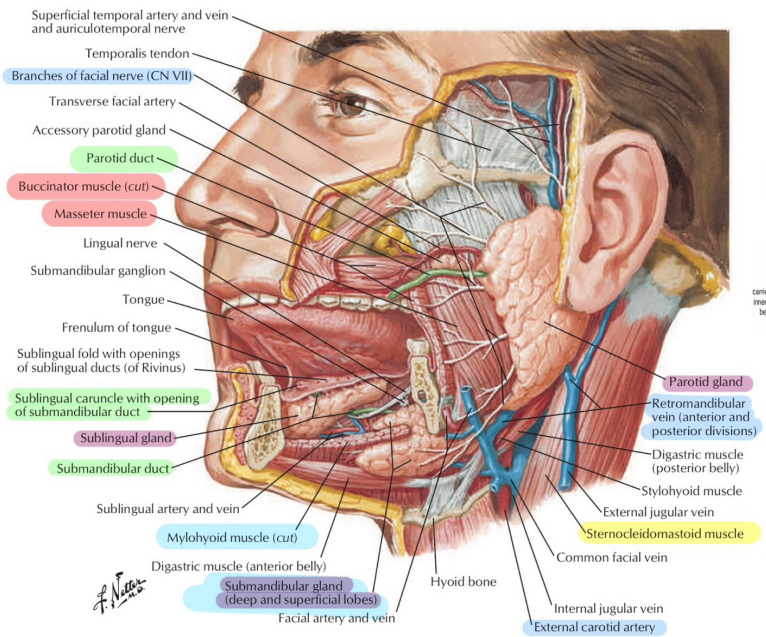


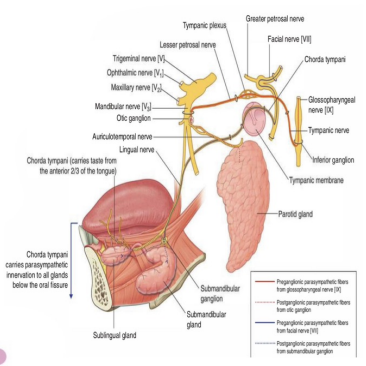


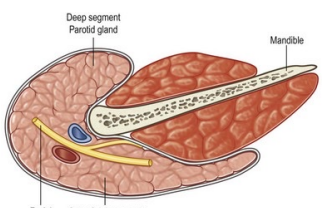


# The Salivary Glands

- **Parotid Gland**
- The parotid gland is **the largest salivary gland** and is composed mostly of **serous acini**
- lies in a deep hollow **below the external auditory meatus**, **behind the ramus of the mandible** and **in front of the sternocleidomastoid muscle**
- **The facial nerve divides the gland into superficial and deep lobes**
- **The parotid duct emerges from the anterior border of the gland** and passes forward over the lateral surface of the masseter.
- **It enters the vestibule of the mouth upon a small papilla opposite the upper second molar tooth**
- ✱ **Parasympathetic secretomotor supply arises from the glossopharyngeal nerve** → lesser Petrosal of temporal
- **The nerves reach the gland via the tympanic branch, the lesser petrosal nerve, the otic ganglion, and the auriculotemporal nerve.**

- The **preganglionic parasympathetic** fibers leave the tympanic cavity as the **lesser petrosal** nerve which leaves the petrous bone to passes through the **foramen ovale** to relay in the **otic ganglion**.
- **Postganglionic** fibers join the **auriculotemporal** nerve which carries them to the **parotid gland**.

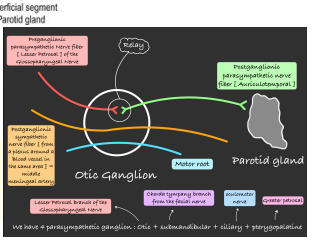


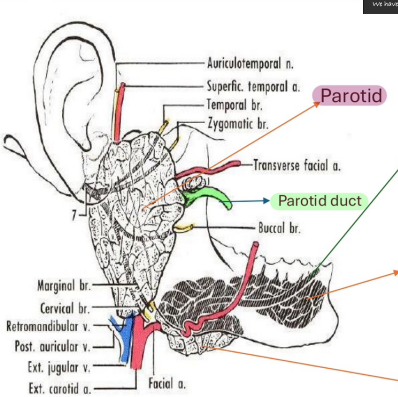


- Origin of Mylohyoid muscle.
- It separates the **superficial part of the submandibular gland** from its **deep part**.
- It also separates the **submandibular gland** from the **sublingual gland**

# Anatomical relations

- The **parotid gland** lies within the **parotid bed**, which is anatomically bounded by:
  1. **Posteriorly**: the **sternocleidomastoid muscle**
  2. **Anteriorly**: the **ramus of the mandible**
  3. **Superiorly**: the base of the trench is formed by the **external acoustic meatus** and the **posterior part of the zygomatic arch**

The **parotid duct** runs **anteriorly** over the external surface of the **masseter muscle**, then turns **medially**, **pierces the buccinator muscle**, and opens into the **oral cavity adjacent to the crown of the second upper molar tooth**.

- The **parotid gland** encloses three important structures:
  1. The **external carotid artery**
  2. The **retromandibular vein**
  3. The **extracranial part of the facial nerve (cranial nerve VII)**

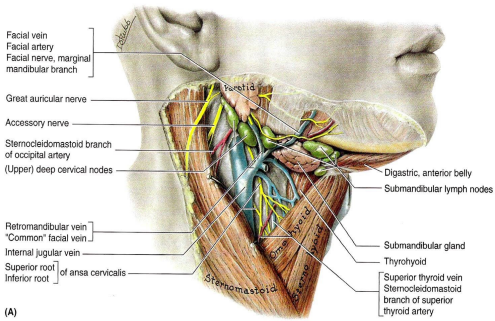


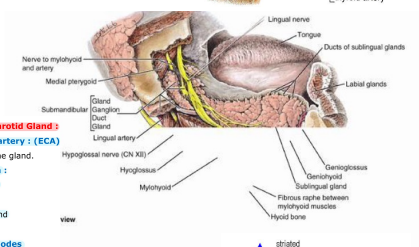


**Structures within the Parotid Gland :**

**1. The external carotid artery : (ECA)**
The deepest structure in the gland.

**2. Retromandibular vein :**
Is intermediate in position

**3. The facial nerve:**
lies superficial to E.C.A. and retromandibular V.

**4. Deep parotid lymph nodes**

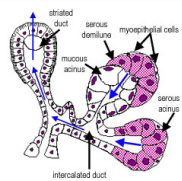


## Site of the Parotid Gland ①

- The **parotid gland** is located **anterior to the ear**, and it **overlies both the masseter muscle and the sternocleidomastoid muscle**.
- The **base** of the gland lies **just beneath the skin**, while the **apex** points **toward the pharynx**.
- **Parotid Bed**
  The **parotid bed** refers to the **structures upon which the gland rests**, including:
  - The **styloid process of the temporal bone**
  - **Muscles attached to the styloid process**: stylohyoid, etc.
  - The **posterior belly of the digastric muscle**
  - The **deep cervical fascia**
  - The **last four cranial nerves** (CN IX–XII)
- **Vascular Relations**
  The **parotid gland also overlies major blood vessels**, including:
  - The **internal jugular vein**
  - The **common carotid artery**, which bifurcates into the **external** and **internal carotid arteries** deep to or near the gland

③

Doctor said a lot of questions ask about the relations of the parotid gland:

- Most superficial → Facial nerve.
- Middle → Retromandibular vein.
- Deep → External carotid artery.

- The **retromandibular vein**, which lies **deep to the facial nerve**, is formed by the union of the **superficial temporal vein and the maxillary vein** within the **parotid gland**.
- The **deepest structure within the parotid gland** is the **external carotid artery**, along with its terminal branches—the **superficial temporal and maxillary arteries**. These vessels **run alongside their corresponding veins**.
- **Mumps**, a **viral infection**, leads to **inflammation and swelling** of the parotid gland. However, the gland's **tight fibrous capsule** limits expansion, causing **severe pain** due to **pressure buildup**.
- The **parotid gland contains intraglandular lymph nodes**, commonly referred to as the **parotid lymph nodes**.
- The gland is divided into **lobes and lobules by connective tissue septa**, which extend **inward from the inner capsule**.
- Each **lobule contains secretory acini**, which drain into "small" **interlobular ducts**. These eventually converge to form the **main parotid duct,** which opens into the **oral vestibule opposite the upper second molar tooth**.
- The **parotid duct** arises from the **anterior border** of the parotid gland, is approximately **4 cm long**, and has a surface anatomical landmark of **one fingerbreadth below the zygomatic arch**.
- The gland's **outer capsule** is formed by the parotid fascia, which is derived from the **deep cervical fascia.**

## Facial Nerve and the Parotid Gland ②

- The **most superficial structure within the parotid gland** is the **facial nerve (cranial nerve VII)** and its **five terminal branches**, which pass through the gland but **do not supply it functionally**.
- **Facial Nerve Branches in the Parotid:**
  These branches arise **within the parotid gland** and fan out to innervate the **muscles of facial expression**:
  1. **Temporal branch** → innervates the **orbicularis oculi**
  2. **Zygomatic branch**
  3. **Buccal branch**
  4. **Marginal mandibular branch** → innervates muscles near the **mandible**
  5. **Cervical branch** → innervates the **platysma**
- The **main trunk (stem) of the facial nerve** enters the parotid gland and **divides it into superficial and deep lobes**.
- **Clinical Relevance in Parotid Surgery:**
  - During **parotid gland surgery** (e.g. tumor removal), the **facial nerve is at risk of injury**. This is a **primary surgical concern**.
  - On the **first day after surgery**, the doctor typically assesses facial nerve function by asking the patient to perform actions involving facial muscles:
    - **Close the eyes** → tests the **temporal branch (orbicularis oculi)**
    - **Blow out the cheeks**
    - **Check for drooling of saliva**

④

- The parasympathetic innervation of the parotid gland originates from the **inferior salivatory nucleus** in the medulla oblongata. The **glossopharyngeal nerve (cranial nerve IX)** emerges from this nucleus and gives rise to the **tympanic nerve,** which branches into the lesser petrosal nerve at the tympanic membrane. The lesser petrosal nerve carries **preganglionic parasympathetic fibers** to the **otic ganglion,** located just below the **foramen ovale**. The **postganglionic parasympathetic fibers** then travel via the **auriculotemporal nerve** to reach and innervate the **parotid gland**. This nerve also provides **sensory innervation** to the gland.

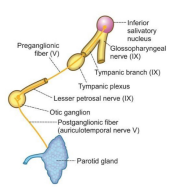


- **Preganglionic parasympathetic:** lesser petrosal nerve
- **Postganglionic parasympathetic and sensory:** auriculotemporal nerve
- **Postganglionic sympathetic:** fibers originate from the **superior cervical ganglion in the neck** and reach the gland via a **plexus around the external carotid artery**.

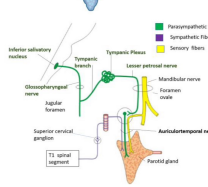


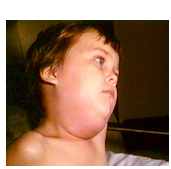

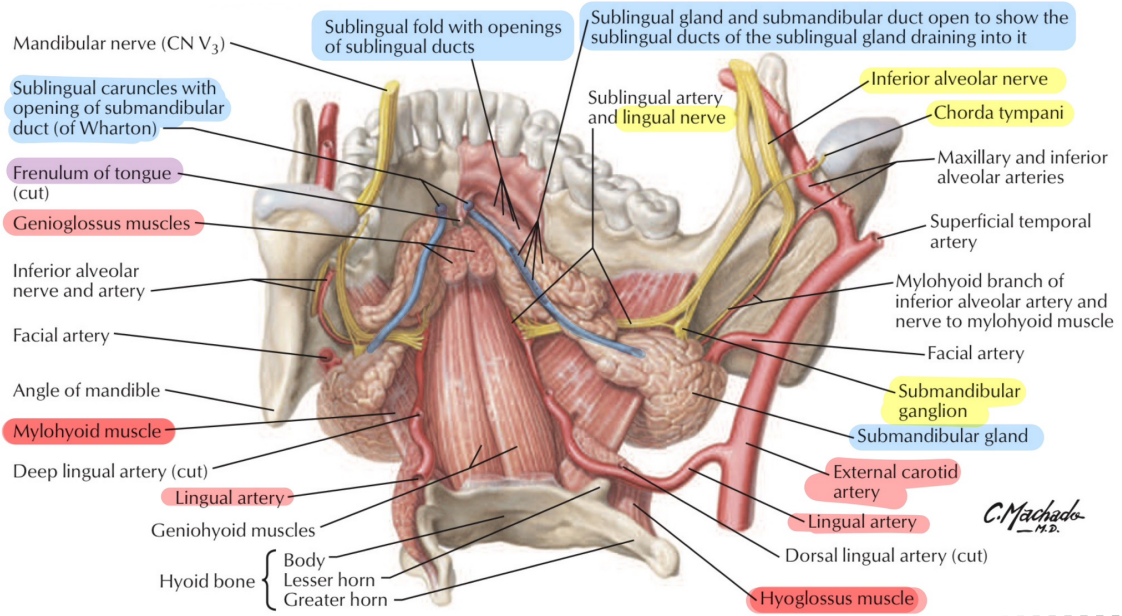


# Submandibular Gland

- The submandibular gland consists of a mixture of serous and mucous acini
- It lies beneath the lower border of the body of the mandible
- divided into superficial and deep parts by the mylohyoid muscle
- The deep part of the gland lies beneath the mucous membrane of the mouth on the side of the tongue.
- The submandibular duct emerges from the anterior end of the deep part of the gland and runs forward beneath the mucous membrane of the mouth.
- It opens into the mouth on a small papilla, which is situated at the side of the frenulum of the tongue

- Parasympathetic secretomotor supply is from the facial nerve via the chorda tympani, and the submandibular ganglion
- The postganglionic fibers pass directly to the gland.

The **submandibular gland** lies within the **submandibular (digastric) triangle**, located **between the anterior and posterior bellies of the digastric muscle.**

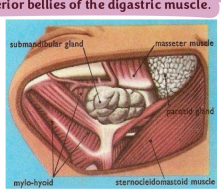


The **submandibular duct** opens at the base of the tongue, in the **floor of the mouth.** This opening is marked by a **small submandibular papilla beneath the tongue.**

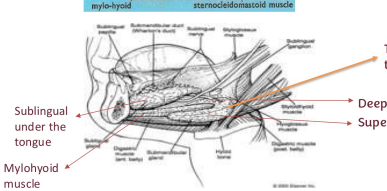


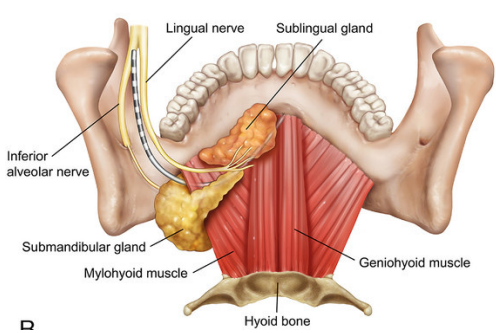

# Submandibular Gland

- The larger arm of the hook is directed forward in the horizontal plane below the mylohyoid muscle and is therefore outside the boundaries of the oral cavity-this larger superficial part of the gland is directly against a shallow impression on the medial side of the mandible (submandibular fossa) inferior to the mylohyoid line;
- The smaller arm of the hook (or deep part) of the gland loops around the posterior margin of the mylohyoid muscle to enter and lie within the floor of the oral cavity where it is lateral to the root of the tongue on the lateral surface of the hyoglossus muscle.

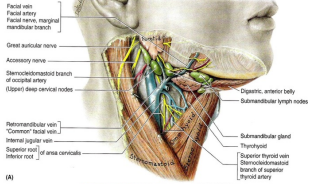


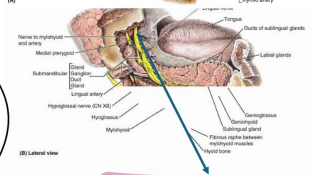


The lingual nerve loops under the submandibular duct, crossing first the lateral side and then the medial side of the duct, as the nerve descends anteromedially through the floor of the oral cavity and then ascends into the tongue.

- **Relations:**
  - There are **five key structures** located **between the mylohyoid and hyoglossus muscles:**
    1. **Three submandibular** structures:
    2. **Deep part of the submandibular gland**
    3. **Submandibular ganglion**
    4. **Submandibular duct (Wharton's duct)**
  - **Two nerves:**
    1. **Lingual nerve**
    2. **Hypoglossal nerve (cranial nerve XII)**

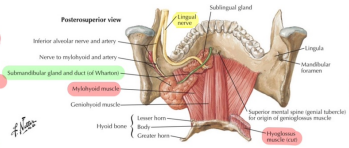


Notice how the chorda tympani, joins the lingual nerve and carries preganglionic parasympathetic fibers.

# Sublingual Gland

- The sublingual gland lies beneath the mucous membrane (sublingual fold) of the floor of the mouth, close to the frenulum of the tongue
- It has both serous and mucous acini, with the latter predominating.
- The sublingual ducts (8 to 20 in number) open into the mouth on the summit of the sublingual fold
- Parasympathetic secretomotor supply is from the facial nerve via the chorda tympani, and the submandibular ganglion. Postganglionic fibers pass directly to the gland.

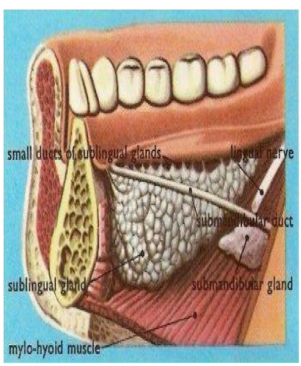


- The **sublingual gland** is located **beneath the tongue**, in the **floor of the mouth**. It is **enclosed in a thin mucosal capsule**. The gland has **8–20 minor ducts**, which **open directly into the oral cavity**. In some cases, these ducts **join the submandibular duct.**
- **Relations:**
  - Medially, the sublingual gland is related to the **lingual nerve**, the **submandibular duct**, and the **genioglossus muscle**.

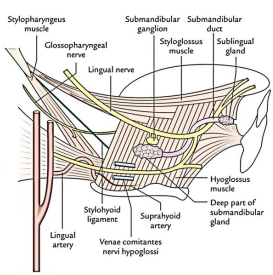


➢ **Innervation of the Submandibular and Sublingual Glands:**

- The **parasympathetic innervation** of the **submandibular and sublingual glands** originates from the **superior salivatory nucleus** in the **medulla oblongata and** is carried by the **facial nerve (cranial nerve VII)**. The **facial nerve** gives rise to the **chorda tympani nerve**, which carries **preganglionic parasympathetic fibers** as well as **taste fibers from the anterior two-thirds of the tongue**.
- The **chorda tympani** joins the **lingual nerve** (a branch of the mandibular division of the trigeminal nerve) in the **infratemporal fossa**. The parasympathetic fibers then synapse in the **submandibular ganglion,** which is located within the submandibular triangle, between the mylohyoid and the hyoglossus muscles.
- The **postganglionic parasympathetic fibers** either directly innervate the submandibular and sublingual glands or **re-enter the lingual nerve** to reach their target glands.

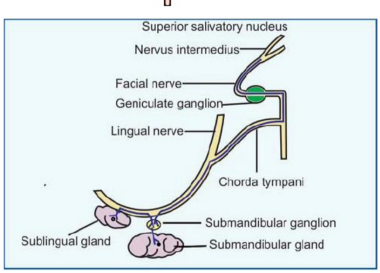


❖ *Note:* The **chorda tympani fibers travel with the lingual nerve** to reach the ganglion; they do not run independently. alone

- **Summary:**
  - **Preganglionic parasympathetic:** chorda tympani
  - **Sensory and taste fibers:** lingual nerve
  - **Postganglionic sympathetic fibers:** arise from the **superior cervical ganglion** and reach the glands via a **plexus around the lingual artery**

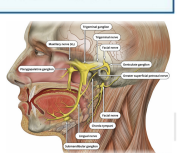

# Triple relation between Submandibular Duct and lingual Nerve = Start lateral → below → medial

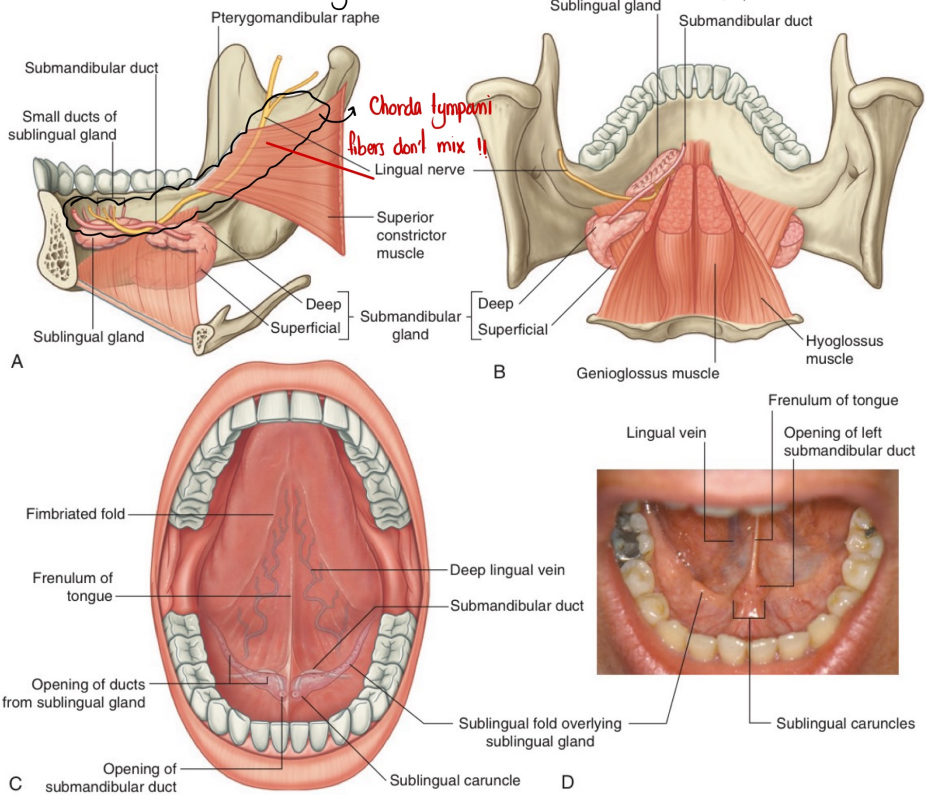

## Sublingual & Submandibular Glands Notes

- The **lingual nerve** has a triple relation to the **submandibular duct**: it passes **lateral**, then **inferior**, and finally **medial** to it.
- Although the **chorda tympani** joins the lingual nerve in the **infratemporal fossa**, their fibers remain distinct — the lingual nerve merely **carries** **parasympathetic and taste fibers** to the **submandibular ganglion and gland**, while still providing **general sensation**.
- In the **oral cavity**, there are **mucosal folds** known as **frenula**:
  - The **superior and inferior labial frenula** connect the **upper and lower lips** to the **gingiva**.
  - On the **underside of the tongue**, the **lingual frenulum** connects the **tongue to the floor of the mouth**.
- If you look in the mirror and lift your tongue, you'll notice **bluish veins** beneath the tongue — these are the **deep lingual veins**, visible through the thin mucosa of the **floor of the mouth**.
- The **lingual artery** and **lingual nerve** lie **deeper and more medially**, and are **not typically visible**, but they run in close relation to the vein beneath the mucosa.

The End

اللَّهُمَّ صَلِّ وَسَلِّمْ وَبَارِكْ على نَبِيِّنَا مُحَمَّد

# - The pharynx -

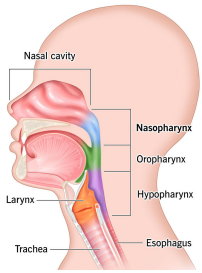


→ it extend from the base of the skull to the lower border of C6 Vertebra Continuo as Esophagus.

→ it's muscular tube but it's open Anteriorly (U shape Structure) it's Divided into:

1. Nasopharynx Anteriorly open in the nasal Cavity.
2. Oropharynx Anteriorly open in the Oral Cavity
3. Hypopharynx (laryngopharynx) Anteriorly bound by Esophagus and Larynx ↑ Epiglottis.

→ the wall of the pharynx is Musculomembranous wall Deficient (open) Anteriorly

→ The Lining Epithelium : Mucosa + Stratified Squamous Non Keratinized Epithelium + loose Areolar C.T + Muscular layer + Connective tissue. (Muscular layer between 2 C.T)

→ The pharynx mainly is formed by (3) Constrictor muscles responsible for Contraction and help in Peristaltic movement {middle, inferior, Superior} in descending Bolus, Their fiber are Circular, and the Stylopharyngess and Salpinopharyeus muscle their fibers are Obliquely in the Pharynx ... (internally in the wall of nasopharynx..)

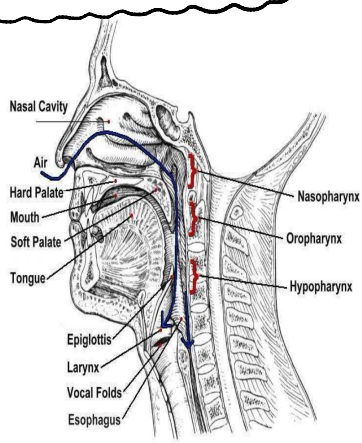


→ The pharynx Consist of (5) muscle in Total :

3 Constrictors, 2 Oblique

What is {Choana}? the posterior opening of the nose to the Nasopharynx

What we Call the opening of Oral Cavity? Oropharemeal {isthmus}.

# * Muscles of the pharynx :

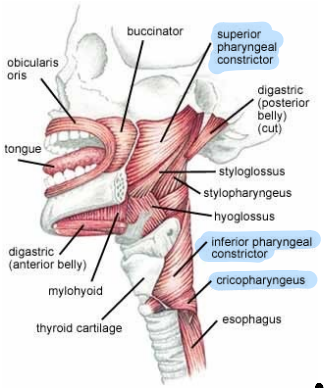


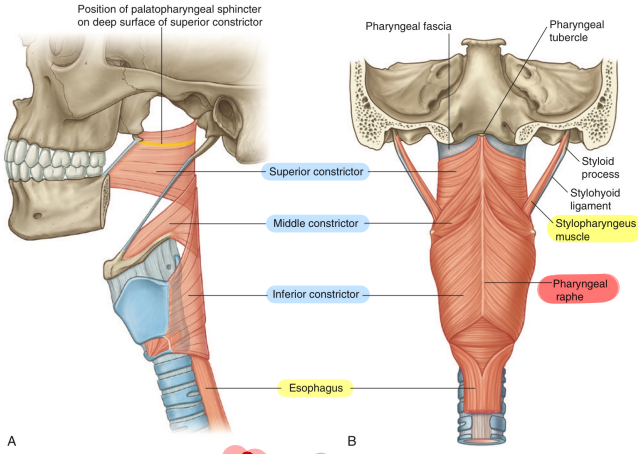


* There is a part from the inferior Constrictor Called : Cricopharyngeus → it's Origin From The Cricoid (Cartilage), insertion Pharynx. what it's important for ?? have a Circular fiber (Horizontally) it works as Sphincter → always Closed (Constricted) open only by Stimulation of Bolus : لقمة → حبة ليش بعمل هيك !! (go to the inlet of larynx) To prevent passage of Air.
(→ once it attached to the mucosa of Cricopharyngeus.)

* when it opens Some air will enter and go the Stomach Accumulate in the Fundus of Stomach (upper portion) → on X-Ray of Abdomen we will find black dots resembling Air.

* The 3 Constrictor muscle (Superior - middle - inferior) → Functions :
=> Propel the Bolus Downward to the Esophagus. They have Common insertion : fibrous line Descending in posterior mid line Start from the pharyngeal Tubercle → Pharyngeal Raphe

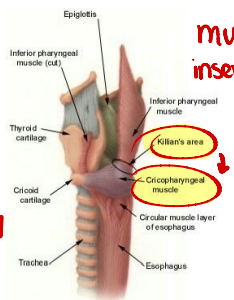


* All the Pharyngeal muscle inserted in it !!

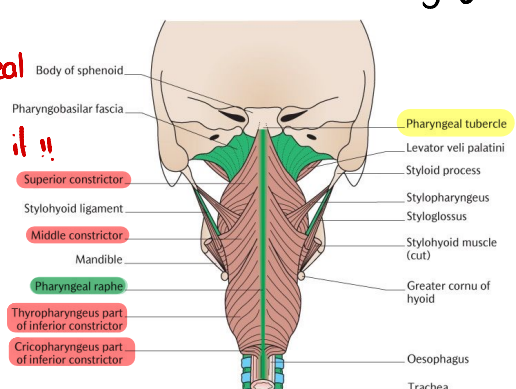

* **Killian's Dehiscence**: Small area it lies above the upper border of **Cricopharyngeus**. it's Very **Sensitive** → if it Stimulated → that will Cause Contraction that will lead to the **Vomiting** ...

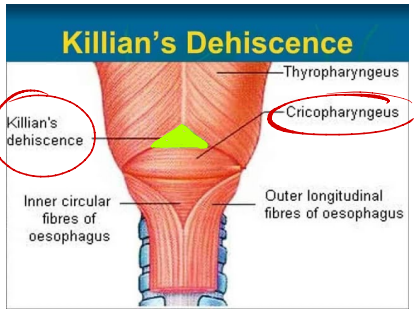


# Pharyngeal plexus: 3 nerves Vagus (X) + Accessory (XI) + Glosopharyneus (IX)

Located in the **posterior wall of pharynx** ...

- Superior constrictor
- O: Medial pterygoid plate, pterygoid hamulus, pterygomandibular ligament, mylohyoid line of mandible
- Ins: Pharyngeal tubercle of occipital bone, raphe in midline posteriorly
- Inerrv: Pharyngeal plexus

Aids soft palate in closing off nasal pharynx, propels bolus downward

- Middle constrictor
- Lower part of stylohyoid ligament, lesser and greater cornu of hyoid bone
- Pharyngeal raphe
- Pharyngeal plexus
- Propels bolus downward

**Thyropharyngeus**

- Inferior constrictor
- Lamina of thyroid cartilage, cricoid cartilage

**Cricopharyngeus**

- Pharyngeal raphe
- Pharyngeal plexus
- Propels bolus downward

- Cricopharyngeus
- Lowest fibers of inferior constrictor muscle
- Sphincter at lower end of pharynx

- Stylopharyngeus
- Styloid process of temporal bone
- Posterior border of thyroid cartilage
- Glossopharyngeal nerve
- Elevates larynx during swallowing

All the muscles are Supplied by the Pharyngeal Plexus Except.

- Salpingopharyngeus
- Auditory tube
- Blends with palatopharyngeus
- Pharyngeal plexus
- Elevates pharynx

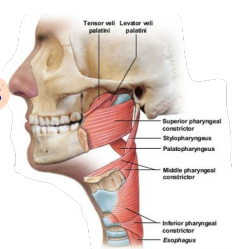


- Palatopharyngeus
- Palatine aponeurosis
- Posterior border of thyroid cartilage
- Pharyngeal plexus
- Elevates wall of pharynx, pulls palatopharyngeal arch medially

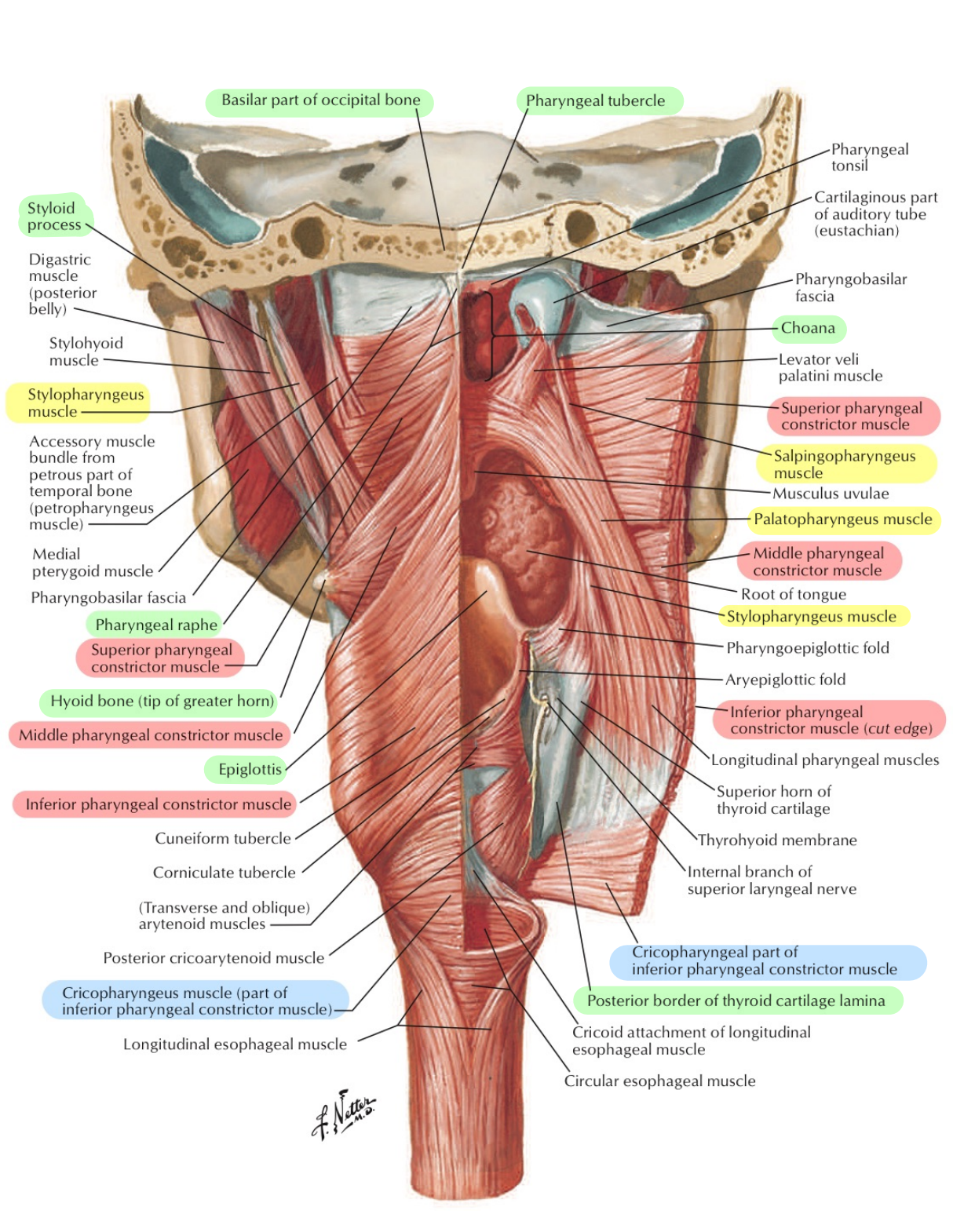
Basilar part of occipital bone
Pharyngeal tubercle
Pharyngeal tonsil
Cartilaginous part of auditory tube (eustachian)
Styloid process
Digastric muscle (posterior belly)
Pharyngobasilar fascia
Choana
Stylohyoid muscle
Levator veli palatini muscle
Stylopharyngeus muscle
Superior pharyngeal constrictor muscle
Salpingopharyngeus muscle
Accessory muscle bundle from petrous part of temporal bone (petropharyngeus muscle)
Musculus uvulae
Palatopharyngeus muscle
Medial pterygoid muscle
Middle pharyngeal constrictor muscle
Pharyngobasilar fascia
Root of tongue
Pharyngeal raphe
Stylopharyngeus muscle
Superior pharyngeal constrictor muscle
Pharyngoepiglottic fold
Aryepiglottic fold
Hyoid bone (tip of greater horn)
Inferior pharyngeal constrictor muscle (cut edge)
Middle pharyngeal constrictor muscle
Longitudinal pharyngeal muscles
Epiglottis
Superior horn of thyroid cartilage
Inferior pharyngeal constrictor muscle
Thyrohyoid membrane
Cuneiform tubercle
Internal branch of superior laryngeal nerve
Corniculate tubercle
(Transverse and oblique) arytenoid muscles
Cricopharyngeal part of inferior pharyngeal constrictor muscle
Posterior cricoarytenoid muscle
Posterior border of thyroid cartilage lamina
Cricopharyngeus muscle (part of inferior pharyngeal constrictor muscle)
Cricoid attachment of longitudinal esophageal muscle
Longitudinal esophageal muscle
Circular esophageal muscle
F. Netter M.D.

# Auditory tube : the opening of the Eustachian tube on the lateral wall of nasopharynx.

Advantage : Balance (equalize) of air pressure on the tympanic membrane ..

Disadvantage : Children who sleep on their back some Vomite will go upward to the nasal Cavity , and through the Eustachian tube will Reach the middle ear. → Otitis media → Spread of infection from the nasal Cavity to the middle ear

# Interior of the pharynx :

- A coronal section shows **three anterior openings:**
- The **choanae** (posterior openings of the nasal cavity, which lead to the nasopharynx)
- The **oropharyngeal isthmus** (the opening of the oral cavity which leads to the oropharynx)
- The epiglottis contain the **inlet of larynx** (third opening)
- Air enters through the inlet of the larynx to reach the trachea, which lies anterior to both the pharynx and the esophagus.

→ Posterior opening of the nasal Cavity جوه to the nasopharynx

- The pharynx is divided into three parts: the nasal pharynx, the oral pharynx, and the laryngeal pharynx.

# Coronal Section show the (3) Anterior opening [Cavities] ∃

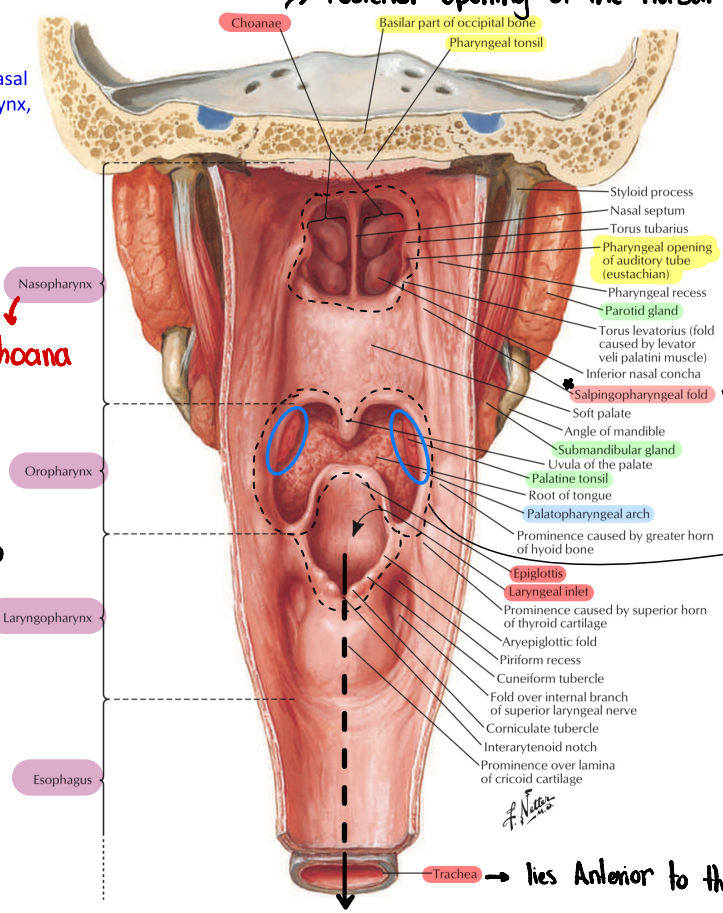


lie within the mid Sagittal Section.

Oropharyngeal isthmus the opening of Oral Cavity جوه to the Oropharynx.

Trachea → lies Anterior to the Pharynx and Esophagus.

1) Naso-Pharynx: Start from the base of the Skull → end in the Soft palate .. The lateral wall Contain Eustachian tube .. the Roof Contain Pharyngeal Tonsil Very important Sometime this tonsil will be infected and enlarged Caused (Adenoid) = Blocking in the Nasopharynx Children start breathing via mouth → need Surgical Removal..

2) Oropharynx: (behind the Oral Cavity) Palatine tonsil (between the palatoglossal and palatopharyngeal arch.) on the lateral wall of Oropharyngeal isthmus .infection in it Called (tonsilitis)...

→ Connection between the Tongue and The Epiglottis called (aryepiglottic) Glossoepiglottic fold

The Space between them Called Vallecula → Saliva Accumulation Site ..

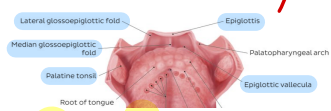


3) Laryngopharynx:

Depresion Between the Pharynx and Larynx there is Pyriform Fossa

Common site for the lodge of foreign bodies such as fish bone ...

## Midline Sagittal Section:

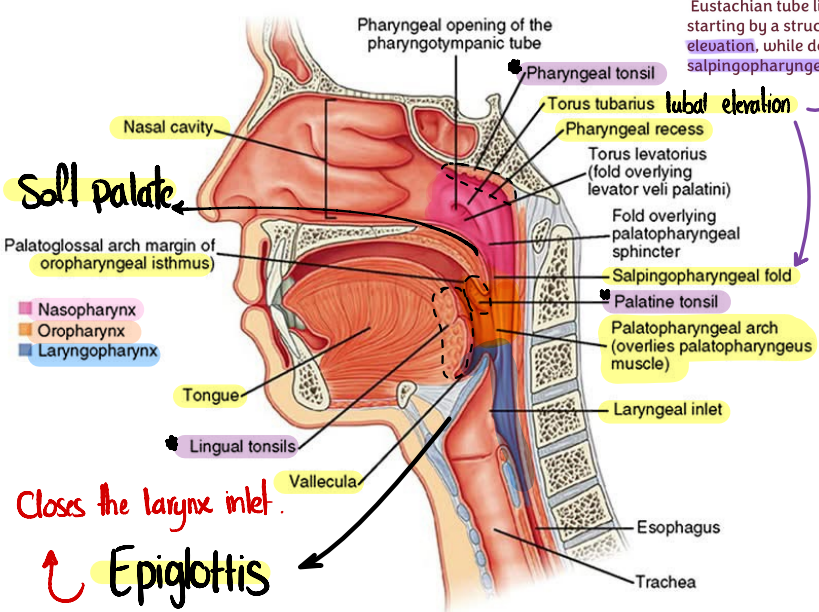


Eustachian tube lies at the lateral wall starting by a structure called tubal elevation, while downward to it is the salpingopharyngeal fold (process)

tubal elevation

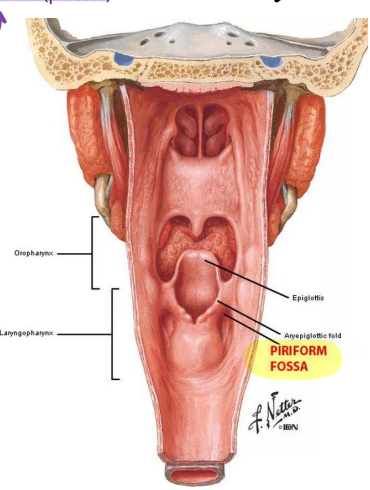


Closes the larynx inlet.

↑ Epiglottis

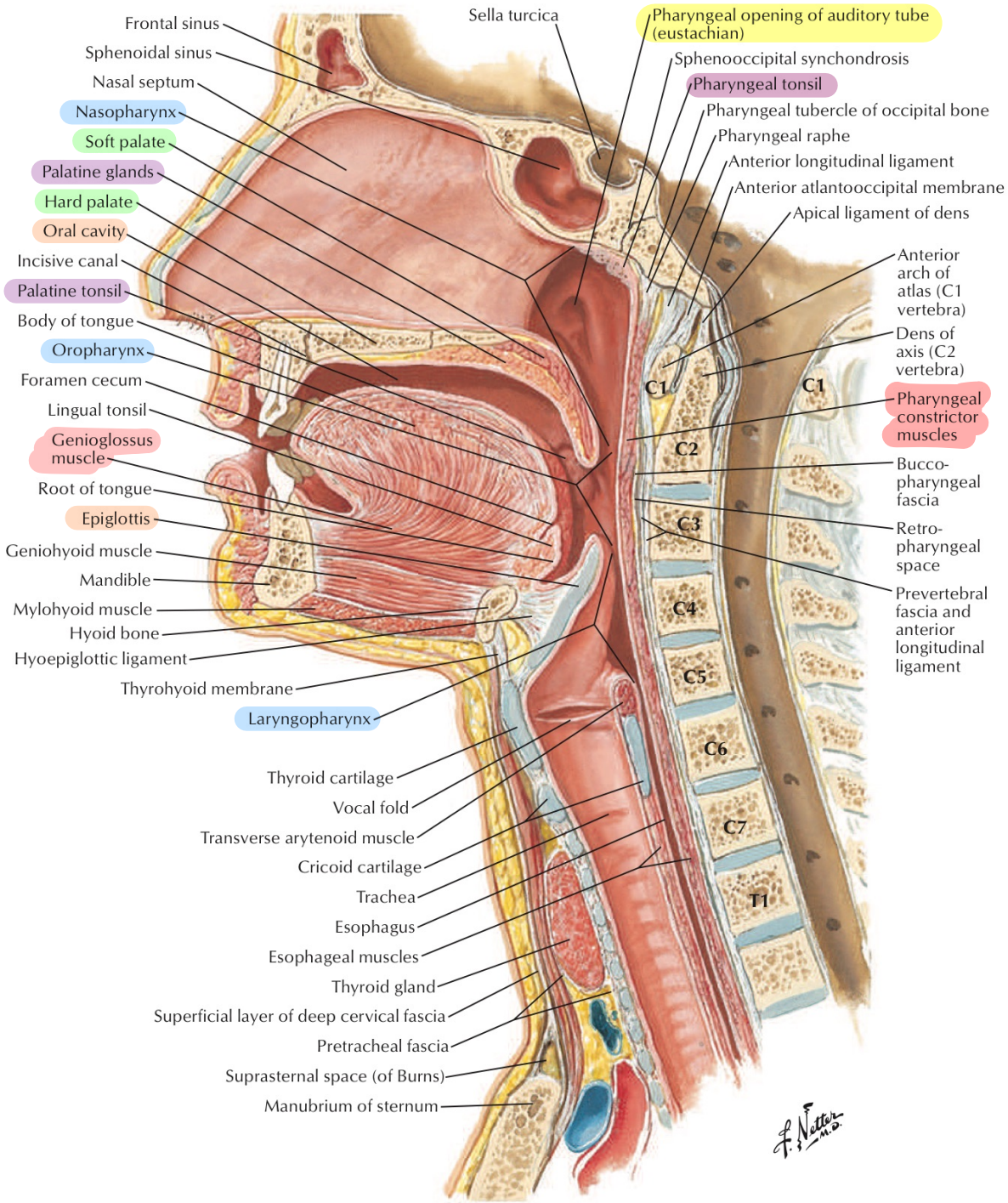
Frontal sinus
Sphenoidal sinus
Nasal septum
Nasopharynx
Soft palate
Palatine glands
Hard palate
Oral cavity
Incisive canal
Palatine tonsil
Body of tongue
Oropharynx
Foramen cecum
Lingual tonsil
Genioglossus muscle
Root of tongue
Epiglottis
Geniohyoid muscle
Mandible
Mylohyoid muscle
Hyoid bone
Hyoepiglottic ligament
Thyrohyoid membrane
Laryngopharynx
Thyroid cartilage
Vocal fold
Transverse arytenoid muscle
Cricoid cartilage
Trachea
Esophagus
Esophageal muscles
Thyroid gland
Superficial layer of deep cervical fascia
Pretracheal fascia
Suprasternal space (of Burns)
Manubrium of sternum
Sella turcica
Pharyngeal opening of auditory tube (eustachian)
Sphenooccipital synchondrosis
Pharyngeal tonsil
Pharyngeal tubercle of occipital bone
Pharyngeal raphe
Anterior longitudinal ligament
Anterior atlantooccipital membrane
Apical ligament of dens
Anterior arch of atlas (C1 vertebra)
Dens of axis (C2 vertebra)
C1
C1
Pharyngeal constrictor muscles
C2
Bucco-pharyngeal fascia
C3
Retro-pharyngeal space
Prevertebral fascia and anterior longitudinal ligament
C4
C5
C6
C7
T1
F. Netter M.D.

# Sensory Nerve Supply of the Pharyngeal Mucous Membrane:

- Nasal pharynx: The maxillary nerve (V2)
- Oral pharynx: The glossopharyngeal nerve
- Laryngeal pharynx (around the entrance into the larynx): The internal laryngeal branch of the vagus nerve

reach the Larynx between the middle and inferior Constrictor muscle of pharynx.

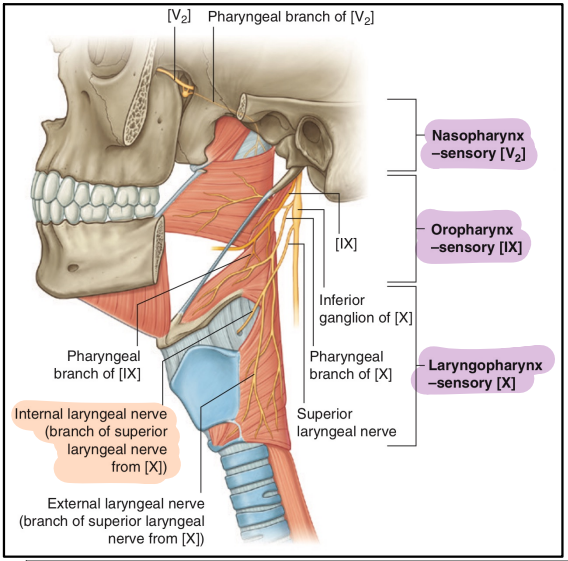


# Blood Supply to the pharynx :

- Ascending pharyngeal, tonsillar branches of facial arteries, and branches of maxillary and lingual arteries
- Lymph Drainage of the Pharynx
- Directly into the deep cervical lymph nodes or indirectly via the retropharyngeal or paratracheal nodes into the deep cervical nodes

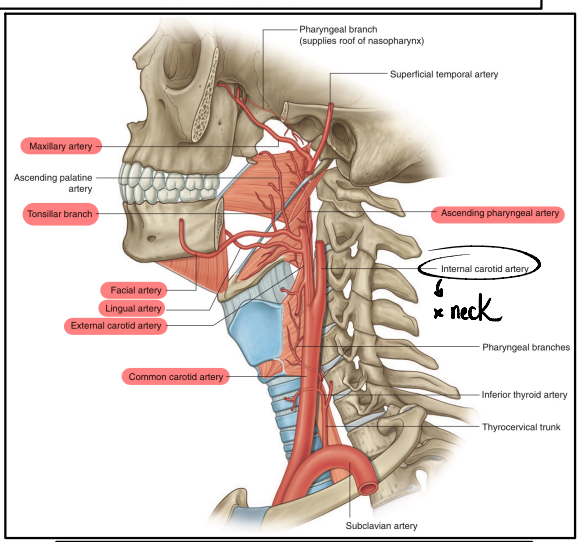


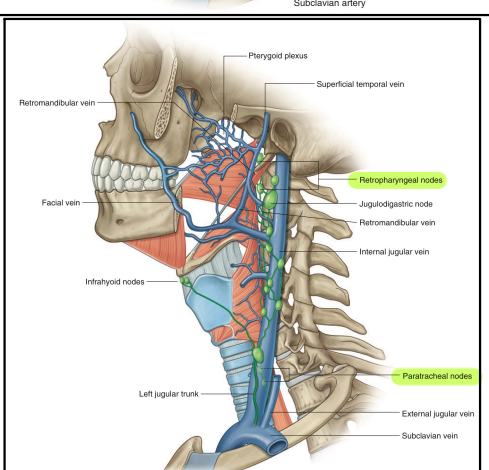

# The Process of Swallowing (Deglutition)

Sheet 2022

Masticated food is formed into a ball or bolus on the dorsum of the tongue and voluntarily pushed upward and backward against the undersurface of the hard palate

- This is brought about by the contraction of the styloglossus muscles on both sides, which pull the root of the tongue upward and backward. Also, the soft palate is pushed downward and forward closing the oral cavity (as long as the bolts is still on the dorsum of the tongue) .

- The palatoglossus muscles then squeeze the bolus backward into the pharynx. From this point onward the process of swallowing becomes an involuntary act.
- The nasal part of the pharynx is now shut off from the oral part of the pharynx by the elevation of the soft palate, and the pulling forward of the posterior wall of the pharynx by the upper fibers of the superior constrictor muscle, and the contraction of the palatopharyngeus muscles. This prevents the passage of food and drink into the nasal cavities

- The larynx and the laryngeal part of the pharynx are pulled upward by the contraction of the stylopharyngeus, salpingopharyngeus, thyrohyoid, and palatopharyngeus muscles
- The main part of the larynx is thus elevated to the posterior surface of the epiglottis, and the entrance into the larynx is closed
- The laryngeal entrance is made smaller by the approximation of the aryepiglottic folds, and the arytenoid cartilages are pulled forward by the contraction of the aryepiglottic, oblique arytenoid, and thyroarytenoid muscles.

The bolus moves downward over the epiglottis, the closed entrance into the larynx, and reaches the lower part of the pharynx as the result of the successive contraction of the superior, middle, and inferior constrictor muscles

- Some of the food slides down the groove on either side of theentrance into the larynx, that is,down through the piriform fossae—> which causes coughing to get bolus out
- Finally, the lower part of the pharyngeal wall (the cricopharyngeus muscle, the sphincter) relaxes and the bolus enters the esophagus.

موديفايد الغرق الحلمي

➢ **Eating is a complex process, which encompasses many steps going as:**

1) Upon food (bolus) enter pressure is made in the oral cavity.
2) Soft palate sense it then close the oropharynx (oropharyngeal isthmus) by moving downward, while the base of the tongue goes upward.
3) After the bolus pass, the soft palate returns upward and backward, so the posterior wall of the pharynx moves forward by a constrictor muscle leading to a closure of the nasopharynx (so food don't slide upward).
4) When a bolus moves down into the pharynx, it should not enter the laryngeal inlet, as doing so would trigger coughing reflexes until the bolus is expelled.
   To prevent this, the bolus pushes the epiglottis downward and backward, while the larynx moves upward along with the pharynx.
   This causes complete closure of the laryngeal inlet, directing the bolus into the esophagus.

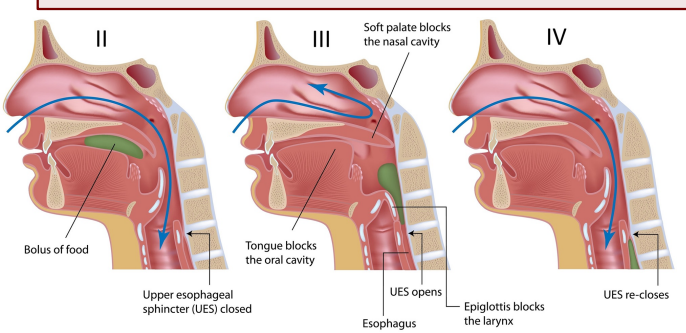


Tonsillitis :

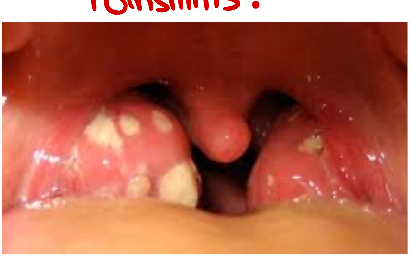

# Palatine Tonsils

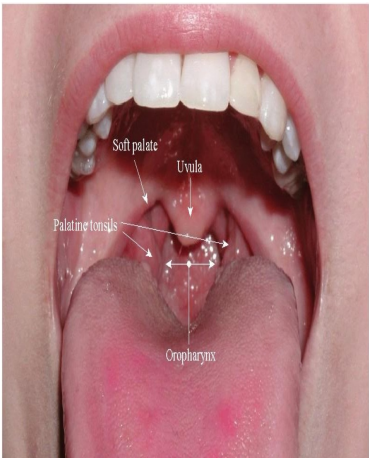


2 masses of Lymphoid tissue . Located Between palatoglossal arch and Palatopharengeal arch on the Latera wall of Oropharengeal isthmus .

Children filtration of the Bacteria . Viruses and foreign bodies ...

Adults Radimentation جاين this is why the inflammation in adult Decreased...

# each tonsil is Covered by Mucous Membrane , the medial Surface is Free and pilled by numerous Small opening lead to tonsillar Crypts , The Lateral Surface Covered with loose Connective tissue

The Blood , nerve , Vein Supply inter through it to the Tonsils ...

Common Carotid . tonsillar Branch of facial Artery

- The capsule is separated from the superior constrictor muscle by loose areolar tissue
- and the external (Supra) palatine vein descends from the soft palate in this tissue to join the pharyngeal venous plexus → Pierce the Superior Constrictor muscle
- Lateral to the superior constrictor muscle lie the styloglossus muscle, the loop of the facial artery, and the internal carotid artery.
- The tonsil reaches its maximum size during early childhood, but after puberty it diminishes considerably in size.

Lateral surface is close to common carotid artery, tonsillar branch of facial artery and veins

# The pharyngeal plexus of Veins :

Venous drainage of tonsils ..

When we remove them ? in Children who get infected more than (4-5) times . Because the Streptococcus bacteria Can Spread to the joint → causing Arthritis to the heart → Causing Endocarditis , to the Kidney → Causing Glomeolonepheritis → So we protect the child from the Complications ...

After Tonsillectomy . The Patient Should be under observation for 24h . Why ?? we afraid from postoperative Bleeding which Caused by the Vein ...

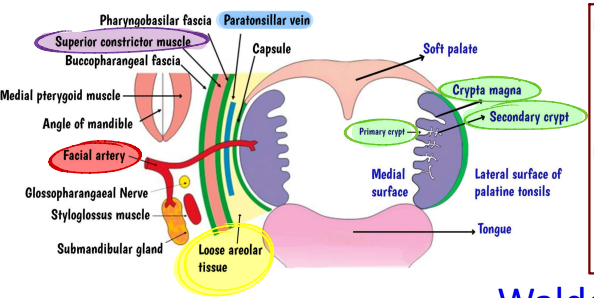


- We perform a tonsillectomy because Streptococcus bacteria, which cause tonsillitis, may spread to the joints (leading to arthritis), the heart (causing rheumatic fever), and the kidneys (causing glomerulonephritis).
  Since the human body contains abundant lymphoid tissue, removing the tonsils does not cause any significant harm.

- If tonsillectomy is to be done in case of repetitive inflammation in children (4 or 5 times) patient should be under observation for 24 hours as post-operative bleeding coming from the vein is possible due to its course along superior constrictor muscle, as the physician might cut the vein or artery accidentally while doing the tonsillectomy then ligate it, this connection could be severed whenever the constrictor muscle contract at the first-day post-operation, that operation is totally safe for the body in case of function as there are other lymphoid tissues in the body to compensate.

- The tonsillar branch of the facial artery. The veins pierce the superior constrictor muscle and join the external palatine, the pharyngeal, or the facial veins.
- Lymph Drainage of the Tonsil
- The upper deep cervical lymph nodes, just below and behind the angle of the mandible

## Waldeyer's Ring of Lymphoid Tissue

- The lymphoid tissue that surrounds the opening into the respiratory and digestive systems forms a ring
- The lateral part of the ring is formed by the palatine tonsils and tubal tonsils (lymphoid tissue around the opening of the auditory tube in the lateral wall of the nasopharynx)

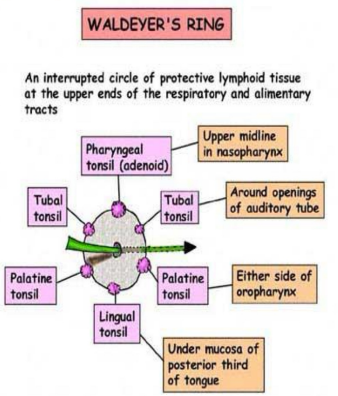


The pharyngeal tonsil in the roof of the nasopharynx forms the upper part, and the lingual tonsil on the posterior third of the tongue forms the lower part.

**Table 8.17** Constrictor muscles of the pharynx

| Muscle | Posterior attachment | Anterior attachment | Innervation | Function |
|---|---|---|---|---|
| Superior constrictor | Pharyngeal raphe | Pterygomandibular raphe and adjacent bone on the mandible and pterygoid hamulus | Vagus nerve [X] | Constriction of pharynx |
| Middle constrictor | Pharyngeal raphe | Upper margin of greater horn of hyoid bone and adjacent margins of lesser horn and stylohyoid ligament | Vagus nerve [X] | Constriction of pharynx |
| Inferior constrictor | Pharyngeal raphe | Cricoid cartilage, oblique line of thyroid cartilage, and a ligament that spans between these attachments and crosses the cricothyroid muscle | Vagus nerve [X] | Constriction of pharynx |

**Table 8.18** Longitudinal muscles of the pharynx

| Muscle | Origin | Insertion | Innervation | Function |
|---|---|---|---|---|
| Stylopharyngeus | Medial side of base of styloid process | Pharyngeal wall | Glossopharyngeal nerve [IX] | Elevation of the pharynx |
| Salpingopharyngeus | Inferior aspect of pharyngeal end of pharyngotympanic tube | Pharyngeal wall | Vagus nerve [X] | Elevation of the pharynx |
| Palatopharyngeus | Upper surface of palatine aponeurosis | Pharyngeal wall | Vagus nerve [X] | Elevation of the pharynx; closure of the oropharyngeal isthmus |

The End

اللَّهُمَّ صَلِّ وَسَلِّمْ وَبَارِكْ على نَبِيِّنَا مُحَمَّد

## Tongue tell the truth

**Lesion**

- Atrophy of ipsilateral tongue muscles
- Deviation of the tongue to the paralyzed side,

Why ????

The tongue being pushed by the genioglossus muscle of the normal side

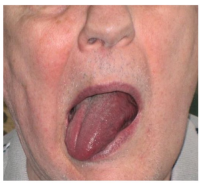

Right Hypoglossal Nerve palsy

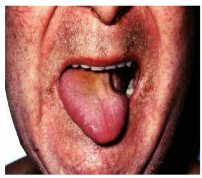

Left Hypoglossal Nerve palsy

This muscle is an important muscle, contraction of both muscles (right and left) protrudes the tongue straightly outside the mouth. While the rest of the muscles move it backwards, upwards, downwards.

So, Injury of the right hypoglossal nerve for example will cause paralysis of the right genioglossus muscle (and all muscles supplied by the right hypoglossal), resulting in right deviation of the tongue (the tongue will be deviated to the paralyzed side).

https://youtu.be/6eyp-TRFsDY?feature=shared

Explanation: when only the left side protrudes the tongue (because the right side is paralyzed) the tongue will be pushed towards the paralyzed side because it is not functioning and doing its job (no resistance on the right side).

# Sensory innervation of the Tongue :

General Special → taste

**Very Important**

Via the circumvallate papillae, although they are found in the anterior two thirds but they originated from the posterior third and follow its innervation.سؤال امتحان

- Sensory Innervation
  - Anterior two thirds: Lingual nerve branch of mandibular division of trigeminal nerve (general sensation) and chorda tympani branch of the facial nerve (taste)
  - Posterior third: Glossopharyngeal nerve (general sensation and taste)

Motor: Hypoglossal (XII), *except* Palatoglossus: Pharyngeal branch of Vagus (X)

**Posterior 1/3**

Sensory and Taste: Glossopharyngeal (IX)

Sensory: Lingual branch of V3 from Trigeminal (V)

Taste: Chorda tympani branch of Facial (VII), carried by lingual branch

**Anterior 2/3**

**Note:** Although the **posterior one-third of the tongue** is largely composed of **lymphoid tissue** (forming the **lingual tonsil**), **taste sensation** in this region is provided by the **circumvallate papillae**.

- Blood Supply
  - The lingual artery, the tonsillar branch of the facial artery, and the ascending pharyngeal artery supply the tongue, and all of those are branches from the external carotid artery.

- The veins drain into the internal jugular vein. Tributaries veins (opposite of arteries) drain into internal jugular vein.

- Lymph Drainage
- Tip: Submental lymph nodes
- Sides of the anterior two thirds: Submandibular and deep cervical lymph nodes
- Posterior third: Deep cervical lymph nodes

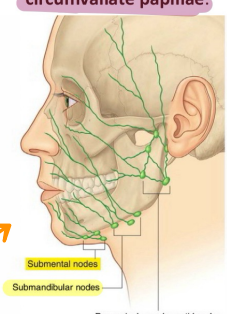


*Structures in the midline drain into the submental lymph nodes like the tip of the tongue , the philtrum , the mid of the lower lip and the tip of the nose

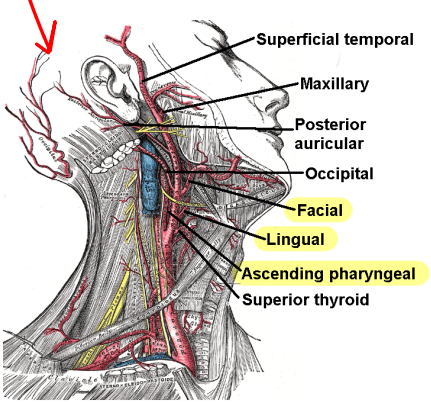


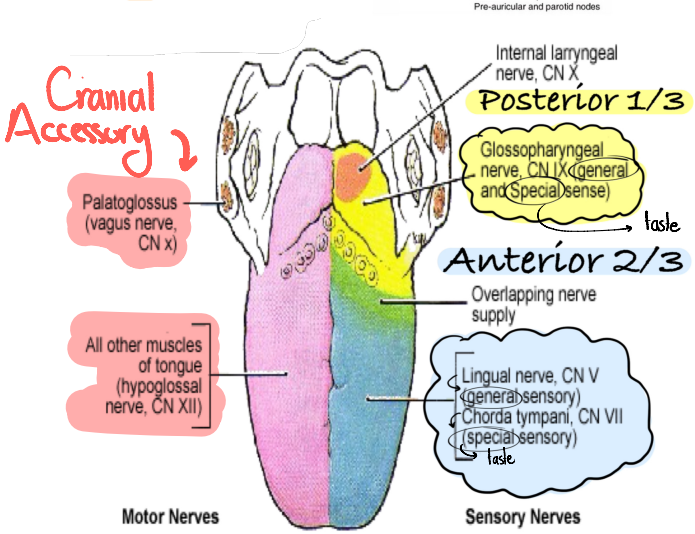

# The Palate is Divided into :-

5 muscles

- Hard palate
  - → is Dense C.T and adherent to the Periosteum
    - C.T
    - ملتزق بالعظم
  - 2 Bones forme it
    - maxilla bone
      - Palatine Process
    - Palatine bone
      - Horizontal Palate

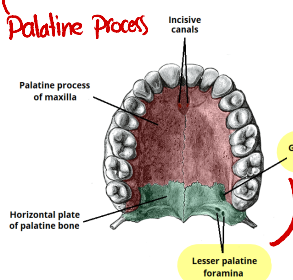


passes through them greater + lesser Palatine Vessels and nerves

- Soft palate = muscular Structure
  - → The Covering is loose C.T
  - There is an extension (Spine) → A tendon formed on it Called : "palatine tendon"
    - from the hard Palate
    - Soft palate
    - الـ أنسبس لل Soft palate

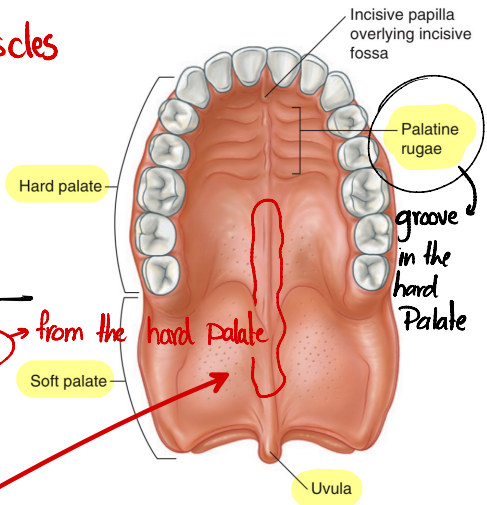


## Function of Soft palate: (movement)

1) Raised Upward, Backward
   - Close the nasopharengeal isthmus
     - During Vomiting ...
2) Raised Downward, forward
   - Close the Oropharengeal isthmus During Mastication
   - # Sudden Open During Swallowing
3) Normally in the midline = both nasal and Oral Cavity Opened → Used in Articulation of Vowels ...
4) During Respiration you Can Breath from both oral + Nasal Cavity.

- The mucous membrane covers the upper and lower surfaces of the soft palate.
- The palatine aponeurosis is a fibrous sheet attached to the posterior border of the hard palate
- It is the expanded tendon of the tensor veli palatini muscle.

# يتكون من عضلتين تلتقو في الـ Midline

- Tensor Veli Palatine → tense the S.P

The soft palate is a muscular structure composed of five muscles and covered by mucosa. It can move either upward and backward or downward and forward, depending on the functional need.

- When it moves upward and backward, it closes off the nasopharynx, as seen during vomiting, to prevent material from entering the nasal cavity.
- During mastication, tension is needed in the oral cavity, so the soft palate closes the nasopharyngeal isthmus by moving downward and forward. This helps increase intraoral pressure.
- During swallowing, the soft palate suddenly elevates to open the oropharyngeal passage, allowing the bolus to pass into the oropharynx.

In rest, it is important for articulation of vowels
When someone says the letter N It leaves from the nose, so air enters nasal cavity. Other letters that leave through oral cavity enter through nasopharyngeal isthmus
It is also important for respiration, you can either breathe from your nose or through the oral cavity

# MUSCLES OF THE SOFT PALATE

The soft palate is composed of :
1. mucous membrane: covers the upper and lower surfaces of the soft palate.
2. palatine aponeurosis: a fibrous sheet attached to the posterior border of the hard palatine. It is the expanded tendon of the tensor veli palatini muscle. (tensor: tenses)
3. muscles

- **The muscles of the soft palate are:**
  1) **tensor veli palatine** (tenses increasing the pressure)
  2) **levator veli palatine**(elevates)
  3) **palatoglossus** (around the palatine tonsils)
  4) **palatopharyngeus** (around the palatine tonsils)
  5) **musculus uvulae** (the uvula itself)

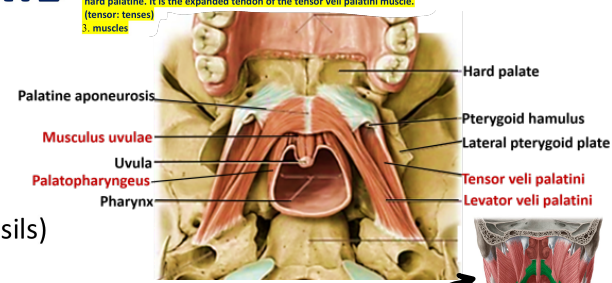


- Levator veli palatini :
- O: Petrous part of temporal bone, auditory tube
- I: Palatine aponeurosis
- Innerv.: Pharyngeal plexus
- Action: Raises soft palate

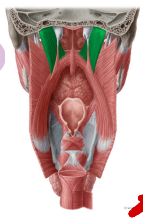

- Palatopharyngeus
- Palatine aponeurosis
- Posterior border of thyroid cartilage
- Pharyngeal plexus
- Elevates wall of pharynx, pulls palatopharyngeal folds medially

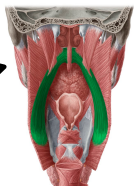

- Tensor veli palatini
- Spine of sphenoid, auditory tube
- With muscle of other side, forms palatine aponeurosis
- Nerve to medial pterygoid from mandibular nerve
- Tenses soft palate

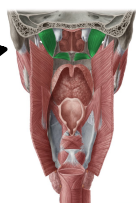

- Musculus uvulae
- Posterior border of hard palate
- Mucous membrane of uvula
- Pharyngeal plexus
- Elevates uvula
- Present in the midline.

# Pharyngeal plexus (3) nerves Vagus + Accessory + Glosopharyneus Located in the posterior wall of pharynx ...

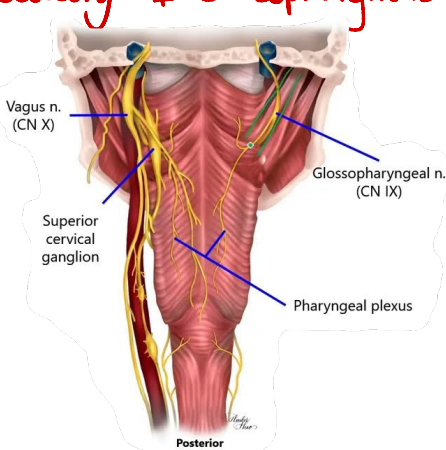


**Table 8.22** Muscles of the soft palate

| Muscle | Origin | Insertion | Innervation | Function |
|---|---|---|---|---|
| Tensor veli palatini | Scaphoid fossa of sphenoid bone; fibrous part of pharyngotympanic tube; spine of sphenoid | Palatine aponeurosis | Mandibular nerve [$V_3$] via the branch to medial pterygoid muscle | Tenses the soft palate; opens the pharyngotympanic tube |
| Levator veli palatini | Petrous part of temporal bone anterior to opening for carotid canal | Superior surface of palatine aponeurosis | Vagus nerve [X] via pharyngeal branch to pharyngeal plexus | Only muscle to elevate the soft palate above the neutral position |
| Palatopharyngeus | Superior surface of palatine aponeurosis | Pharyngeal wall | Vagus nerve [X] via pharyngeal branch to pharyngeal plexus | Depresses soft palate; moves palatopharyngeal arch toward midline; elevates pharynx |
| Palatoglossus | Inferior surface of palatine aponeurosis | Lateral margin of tongue | Vagus nerve [X] via pharyngeal branch to pharyngeal plexus | Depresses palate; moves palatoglossal arch toward midline; elevates back of the tongue |
| Musculus uvulae | Posterior nasal spine of hard palate | Connective tissue of uvula | Vagus nerve [X] via pharyngeal branch to pharyngeal plexus | Elevates and retracts uvula; thickens central region of soft palate |

- The greater and lesser palatine nerves from the maxillary division of the trigeminal nerve enter the palate through the greater and lesser palatine foramina
- The nasopalatine nerve, also a branch of the maxillary nerve, enters the front of the hard palate through the incisive foramen.

- The glossopharyngeal nerve also supplies the soft palate through the pharyngeal Plexus
- Blood Supply of the Palate
- The greater palatine branch of the maxillary artery, the ascending palatine branch of the facial artery, and the ascending pharyngeal artery

- Lymph Drainage of the Palate
- Deep Cervical Lymph Nodes

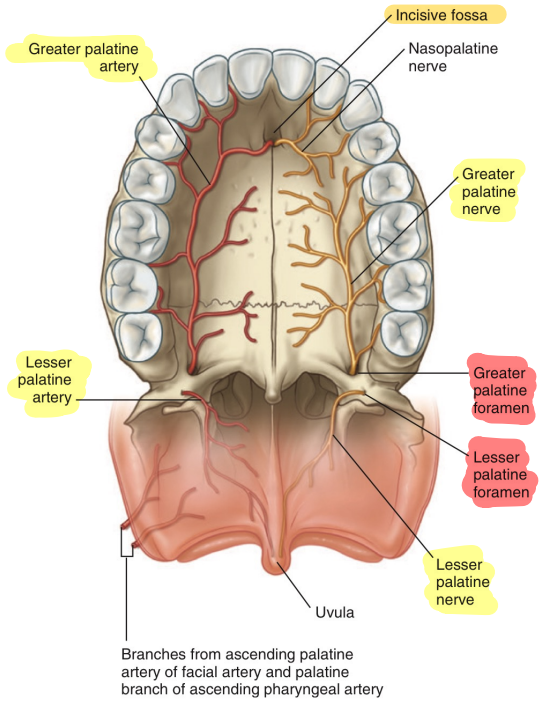


In the hard palate there is incisive fossa which contains incisive foramen. greater palatine artery supply nasal cavity (supply hard palate then go through incisive foramen to supply nasal cavity.

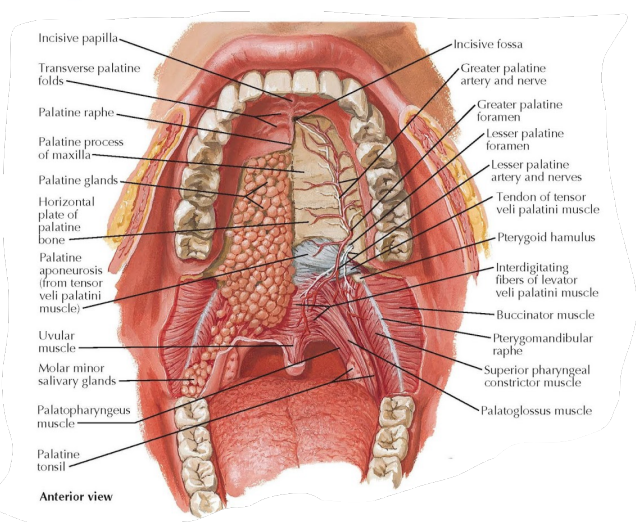


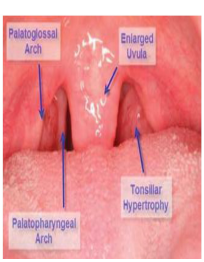


Located between palatoglossal arch and Palatopharengeal arch

The End

اللَّهُمَّ صَلِّ وَسَلِّمْ وَبَارِكْ على نَبِيِّنَا مُحَمَّد

lec (3)

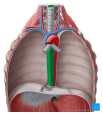

# Stomach and Esophagus

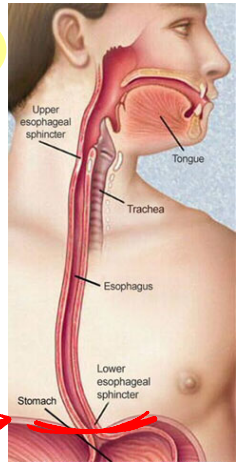


The esophagus is a Continuation of the Pharynx ...

In The lower border of Cricoid Cartilage the Pharynx end and the esophagus begin and Continue to the level of the Cardia

it's about (25 cm) = 10 inch in long, from incisors (45cm ±2) → Collapsible

why we are interested in the incisors length ? because nowadays almost all the Gastroenterologist use (Endoscope = A fiber optic tube enter from the Oral Cavity when it reaches to the Cardia of Stomach it length will be (45 cm)

The esophagus is muscular tube (muscles) → from inside (mucosa) . from outside (Adventitia) , in the middle (muscles)

13 cm

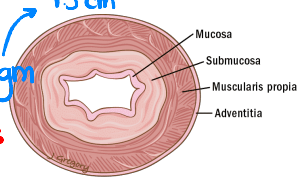


# Abdominal esophagus = The length of the esophagus below Diaphragm

So we Can Say that the esophagus Composed of 4 layers:

[ Mucosa → Submucosa → Muscular layer → Adventitia ]

* The Relations of the thoracic part of the esophagus. دايمًا بيجي عليهم سؤال

- The relations of the thoracic part of the esophagus :
- Anteriorly: The trachea and the left recurrent laryngeal nerve; the left principal bronchus, which constricts it; and the pericardium, which separates the esophagus from the left atrium — Oblique Sinuse
- Posteriorly: The bodies of the thoracic vertebrae; the thoracic duct; the azygos veins; the right posterior intercostal arteries; and, at its lower end, the descending thoracic aorta
- Right side: The mediastinal pleura and the terminal part of the azygos vein — right
- Left side: The left subclavian artery, the aortic arch, the thoracic duct, and the mediastinal pleura — left

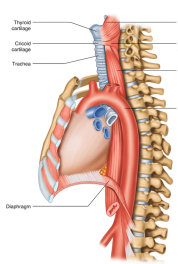


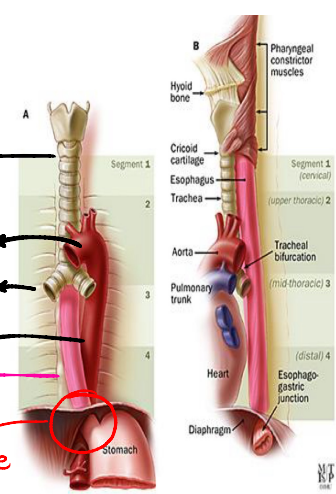

# * Blood Supply of the esophagus:

→ The left Vagus is in the left side of esophagus But after it passes the Diaphram it become Anterior Gastric and The Right Vagus become Posterior Gastric (posterior to the Stomach).

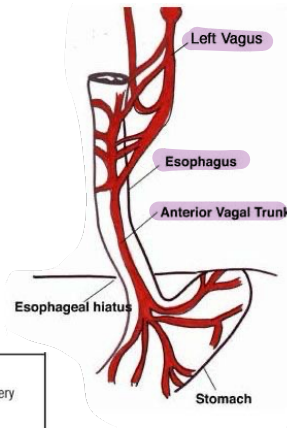


Drain in the inferior thyroid Vein ← Upper third → Inferior thyroid artery

middle third → Drain: Azygos vein

Descending thoracic Aorta give esophageal branch s

lower third → Stomach تابع لـ جزء

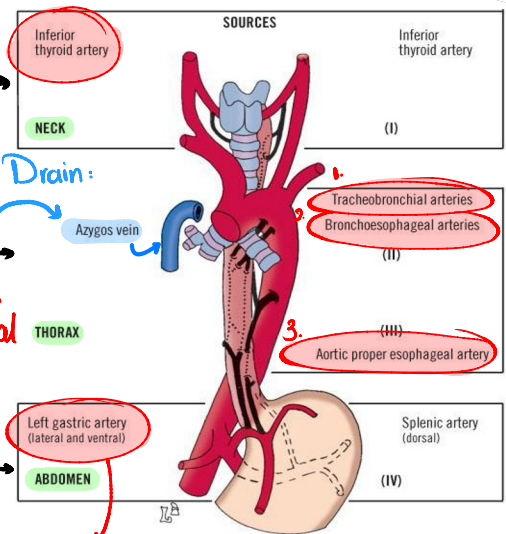


Branch from Celiac Trunk of abdominal Aorta.

left gastric Artery: give branches to the Stomach then to the lower third of esophagus

From the Left Gastric Vein → Portal Vein: Veinous drainage عكس الـ

Tributary of ↑

## * Lymphatic Drainage:

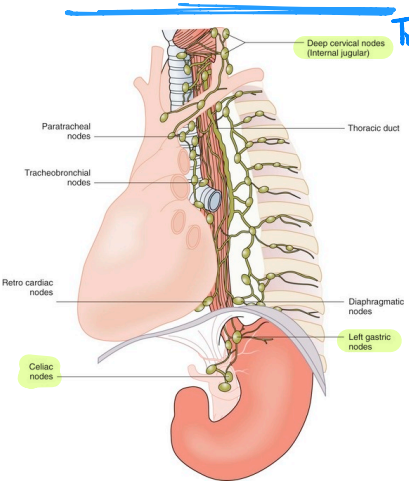


- Lymph vessels from the upper third of the esophagus drain into the deep cervical nodes,
- from the middle third into the superior and posterior mediastinal nodes, → related to the lung
- and from the lower third into nodes along the left gastric blood vessels and the celiac nodes → Abdomen تبع

- The esophagus is supplied by parasympathetic (from the vagus nerve) and sympathetic (from the superior cervical sympathetic ganglia) efferent and afferent fibers via the vagi and sympathetic trunks, forming esophageal plexus around the esophagus.

- In the lower part of its thoracic course, the esophagus is surrounded by the esophageal nerve plexus.

# There is an "esophageal plexus of Nerve" around the esophagus →

Sympathetic → come from the Superior Sympathetic Cervical ganglia.

Parasympathetic → Com from the Vagus Nerve.

* **Gastroesophageal Sphincter**: it's a physiological Sphincter

What Does that mean? Related to the function it's work as a Sphincter;

Preventing Regurgitation of the material (Gastric Juices) from the Stomach to esophagus

But Anatomically: it's not a true Sphincter → There is no Thickening of the Smooth muscle.

(Circular) (Physiological not Anatomical Sphincter)

* **Gastroesophageal Sphincter** is Supplied by the **Vagus nerve** ("Close it")

## Clinical point important to the esophagus:

"Lodge of foreign bodies in the esophagus"

Children Sometime Swallow object that may lodge in the GI tract → in esophagus Specially where we have Constriction ① & at the begening of it why? because the Pharynx is wider ② Through the Diaphram Opening ③ Left main Bronchus (Anteriorly) in the Crossing of esophagus because it Contain Cartilage ④ The Arch of Aorta because it press on the esophagus.

# on the left Side

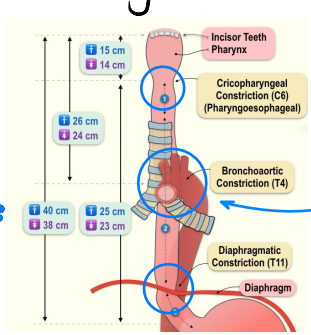


* The narrowing Parts of esophagus:

## * Stomach : located in the epigastric region (left upper Quadrant) of the abdomen and extend upward to the Left Hypochondriac region

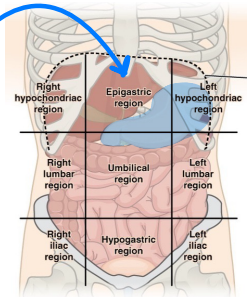


The Stomach is dilated part of the alimentary Canal between the esophagus and the Small intestine (Duodenum).

### the shape of the Stomach :

- It is roughly J-shaped
- Steer horn in obese person ← بوق
- has two openings, the cardiac and pyloric orifices
- Two curvatures, the greater and lesser curvatures
- Two surfaces, an anterior and a posterior surface

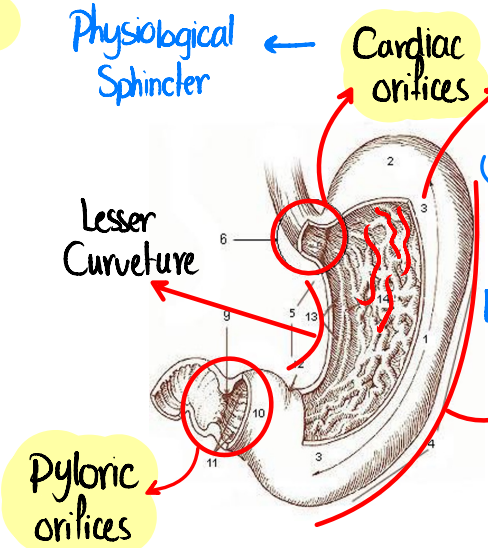

Thickening in the inner Circular Smooth muscle = Anatomically + Physiological Sphincter

---

→ when we eat there is always entry of air in Small amount why ? because the last muscle in the Pharynx Called (Cricopharyngeus muscle) Contract to prevent Passage of air (ومع هيك الهوا بيدخل) where we Can find it ? in The Fundus of the Stomach this is why when we have x-ray for the Stomach we will find dark Spots (gases)

Has three main functions:

- It stores food (in the adult it has a capacity of about 1500 mL)
- It mixes the food with gastric secretions to form a semifluid chyme
- It controls the rate of delivery of the chyme to the small intestine so that efficient digestion and absorption can take place.

The Digestion result in forming of Chyme → that Stay in the Stomach to (2 - 4 hours). then gradual evacuation → the pyloric sphincter open, Some chyme passes to the Duodenum then it Close, re-open again (Close then Open again) after (2-4)h. Complete evacuation to the Chyme.

---

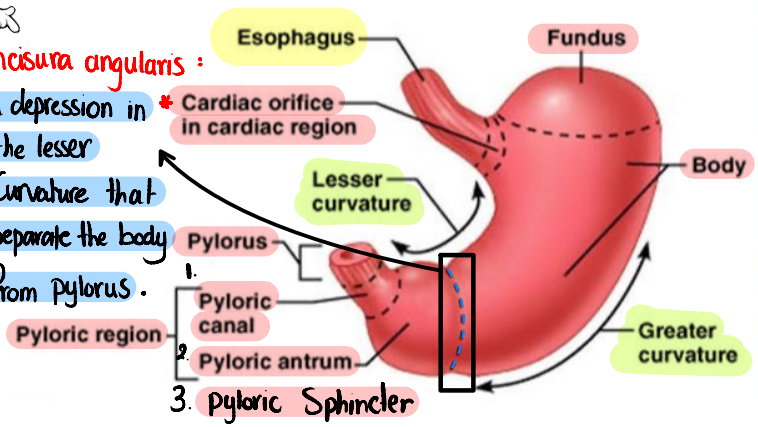


- incisura angularis : a depression in the lesser Curvature that Separate the body from pylorus.

* Lesser Curvature : on the left Side associated with the liver through 2 layers of Peritoneum Called lesser omentum ...

* Greater Curvature : on the right Side also have 2 layers of Peritoneum formed the the Greater Omentum.

---

**1- Fundus:**

- Dome-shaped
- Projects upward and to the left of the cardiac orifice
- It is usually full of gas.

**2 Body:**

-Extends from the level of the cardiac orifice to the level of the incisura angularis (a constant notch in the lower part of the lesser curvature)

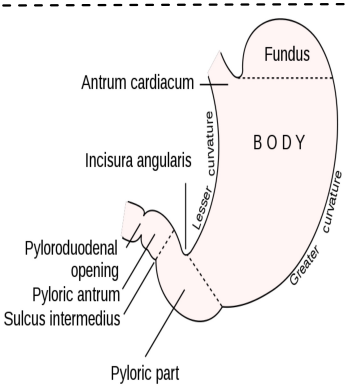


3 Pyloric region divided into:

**a- Pyloric antrum:**

- This extends from the incisura angularis to the pylorus

**b. pylorus Canal**

- The most tubular part of the stomach
- The thick muscular wall is called the

**c. pyloric sphincter**

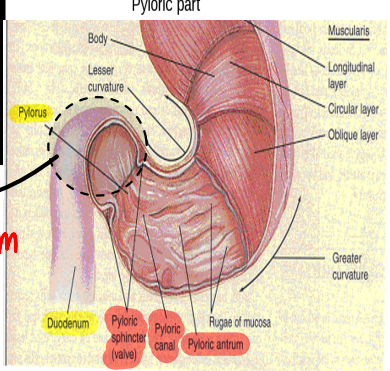


Deudenal Cape whic is the first part of the Duodenum → the most Common Sile for "Peptic Ulcer"

# The Stomach is Composed of 4 layer Same as the GI tube :

mucosa → Submucosa → Mucularis → Serosa

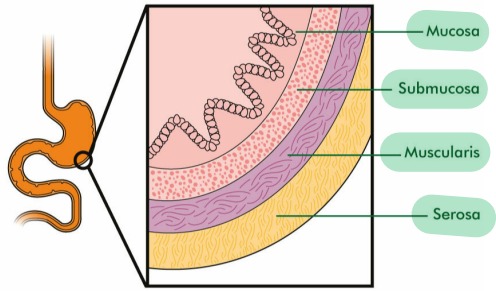


Composed of 3- Layers:

1. lining epithelium.
   - Simple Columnar without goblet Cells.
2. lamina propria.
   - loose Connective tissue → filled with gastric gland.
3. Muscularis Mucosa.
   - Small layer of Smooth muscle.

* All the Stomach is Covered by peritoneum
  - Mesothelium = Simple Squamous epithelium.

- The mucous membrane of the stomach is thick and vascular and is thrown into numerous folds, or **rugae** mainly longitudinal in direction
- The folds flatten out when the stomach is distended.

# Mucosa = Has Rogue Appearance
- Distribution:
  - lesser Curvature = Longitudinal
  - Other areas = Transverse

This is why when drinking water the passage through the Stomach is Very Rapid because it passes beside the lesser Curvature where we have Longitudinal Rogue. Only Small amount will be mixed ...

**Muscular layer:**

* in the GI tube 2-layers → 1. inner Circular. 2. outer longitudinal.

and between them Enteric plexus of nerves

**Except the Stomach:** 3- layers of Smooth muscle

the most inner Oblique → Circular → outer longitudinal

absent in the pylorus sphincter So: من بكون inner Circular.

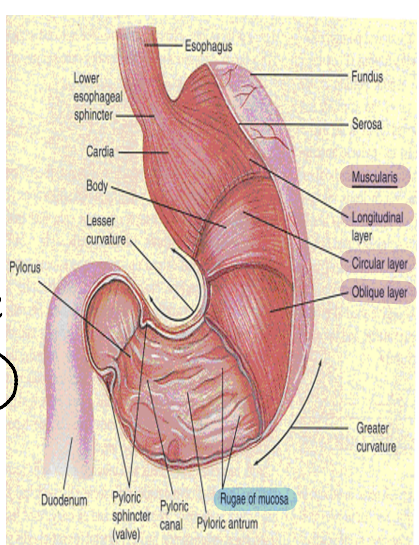

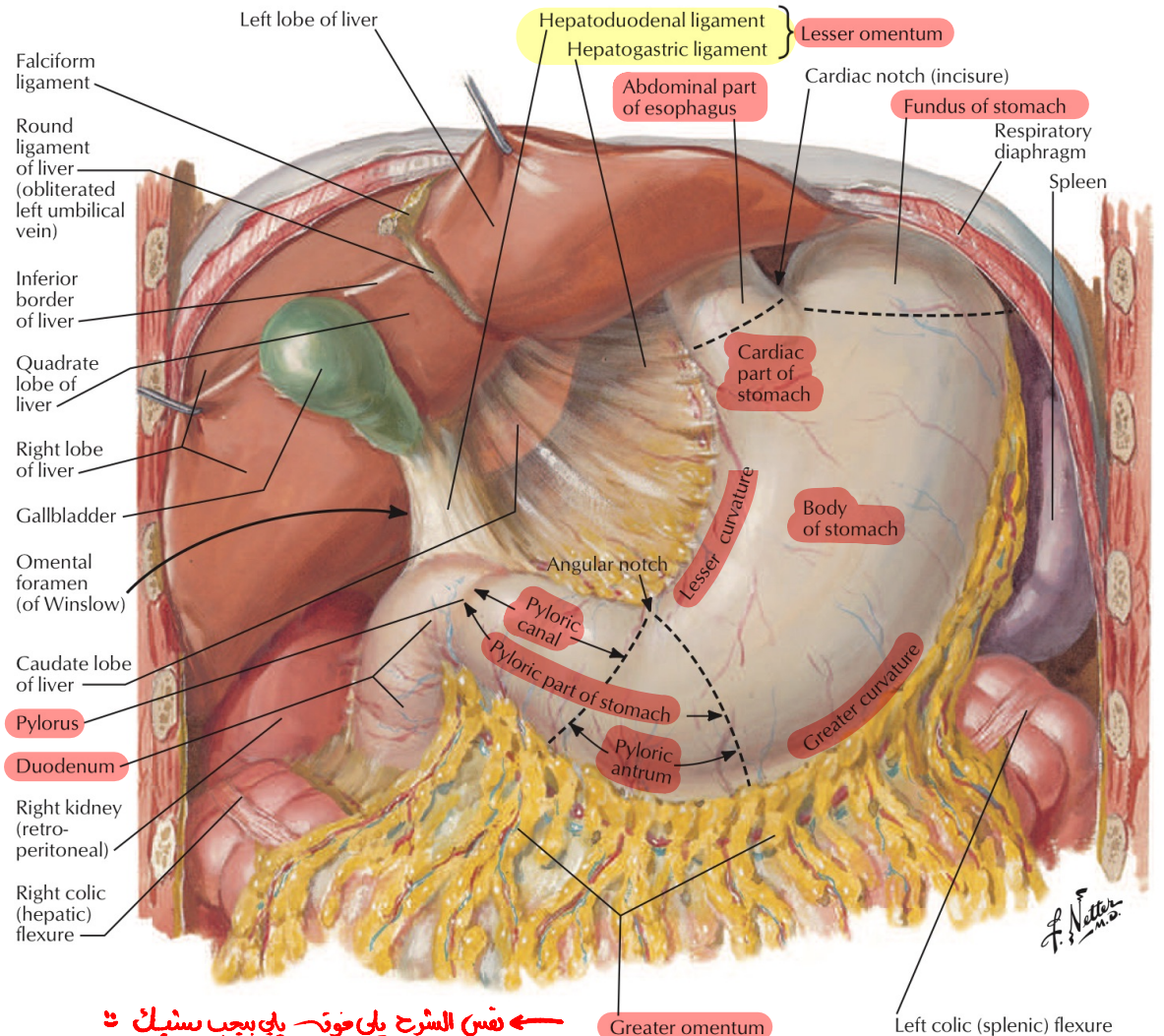


نفس الشرح اللي فوق ← اللي بيجب يشيلك ☺

- ✓ The stomach has 4 layers: **mucosa**, **submucosa**, **mascularis**, **serosa** (**mesothelium**; **simple squamous epithelium**) as the stomach is completely covered with **peritoneum**.
- ✓ Mucosa consists of 3 layers: simple columnar **lining epithelium (1)** without goblet cells, **lamina propria (2)** filled with gastric glands open into the bases of **gastric pits** that in turn open into the gastric lumen, and thin layer of smooth muscle; **mascularis mucosae (3)**.
- ✓ The lining epithelium of the luminal surface, gastric pits and glands is **simple columnar** devoid of **goblet cells**.
- ✓ Mucosal foldings of the stomach lining are called **Rugae**, oriented either longitudinally with the lesser curvature, transversely or obliquely. This explains the rapid and swift passage of fluids through the stomach passing through the longitudinal folds with the lesser curvature.
- ✓ **Lamina propria** of the mucosa, and **submucosa** are rich in blood and lymphatic vessels.
- ✓ Mascularis layer contains 3 sublayers, **oblique (innermost)**, **circular** and **longitudinal (outermost),** unlike other regions of the GI tube which mostly contain **circular** and **longitudinal** layers only and devoid of the **oblique** fibers. **Myenteric plexus** lies between the two longitudinal and circular surface.
- ✓ At the **pyloric sphincter**, oblique layer is absent, thickening of the inner circular smooth muscle layer with the longitudinal layer constitute this sphincter.

## Orifices of the stomach
- Cardiac orifice
- pyloric orifice

-The cardiac orifice is where the esophagus enters the stomach
↳ x thickening

-No anatomic sphincter can be demonstrated here

- A physiological sphincter → physiological mechanism exists that prevents regurgitation of stomach contents into the esophagus
↳ Supplied by Vagus Nerve

## Present at the end of pyloric canal ..
- On the level of L1 ↳ lumber
- 1 inch to the Rt. of the midline.
- The circular muscle coat of the stomach is much thicker here and forms the anatomic and physiologic pyloric sphincter

* the Sympathetic nervous System Stimulate Contraction on the Pyloric Sphincter .
* The Vagus nerve Relax the Sphincter for evacuation .

-The pyloric sphincter controls the outflow of gastric contents into the duodenum.
- The sphincter receives motor fibers from the sympathetic system and inhibitory fibers from the vagus nerve

## Surface anatomy of the Cardia:
- 7th Lt. costal cartilage
- 1 inch to Lt. of midline
- 45 cm from incisors in the oral cavity.
- 10 cm from ant. abdominal wall

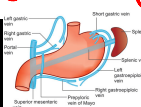

- There is a Vein that Cross the pyloric Sphincter Called Vein of Mayo
↳ Land mark for Surgeon.

in Some Cases Hypertrophy (enlargement) of this muscle can accrue in Newborn , this Case is Known as Pyloric Hypertrophy when this happen the muscle Obstruct the passage of food from the Stomach to the Small intestine that lead to Projectile vomiting after feeding ...

Treatment: Surgical Relief of this Sphincter.. to reduce the Contraction

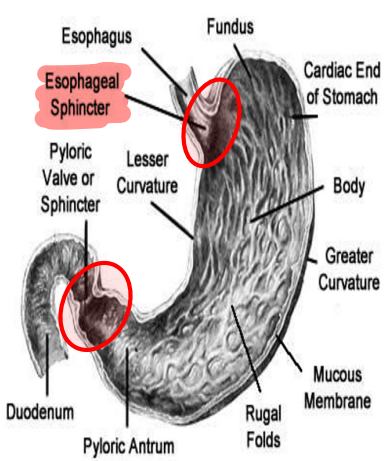


Notice the thickening ←

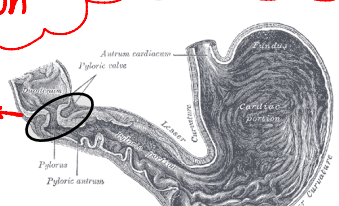

# Curvatures of the Stomach

- Much longer than the lesser curvature
- Extends from the left of the cardiac orifice, over the dome of the fundus, and along the left border of the stomach to the pylorus

## → lesser Curvature :

* on the left Side of Stomach associated with the liver through 2 layers of Peritoneum formed the lesser omentum .

? Omentum شو يعني

2 Layers of Peritoneum between the Stomach and Liver , between the 2 Layers there is fat , blood Vessels . nerves , lymph nodes and lymphatic ..

* lesser omentum is divided into 2parts: 1. hepatogastric ligament (Connect the liver to the Stomach)
2. Hepatoduodenal ligament Connect the liver to the Duedenom

## → Greater Curvature :

* on the right Side of Stomach arise "2" layers of Peritoneum that form the Greater omentum .

وين بروحو ؟

Descend in the Abdomen 2 layers , then Ascend in the Abdomen 2 layer , and finally attached to the :
« Transverse Colon » and Surraund it

* This is why it's :
intraperitoneal Organ Same as Stomach .
* The Ascending + Descending Colon are retroperitoneal Organ
يعني بس قدامهم جلد peritoneum !!

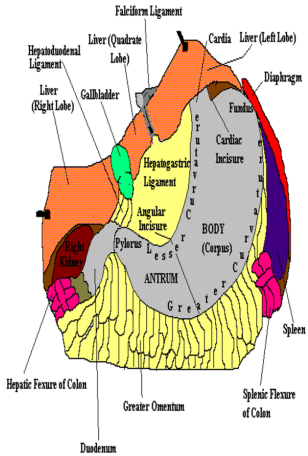


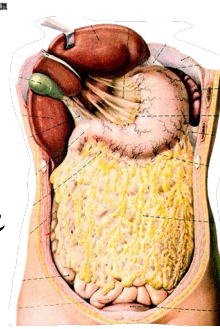

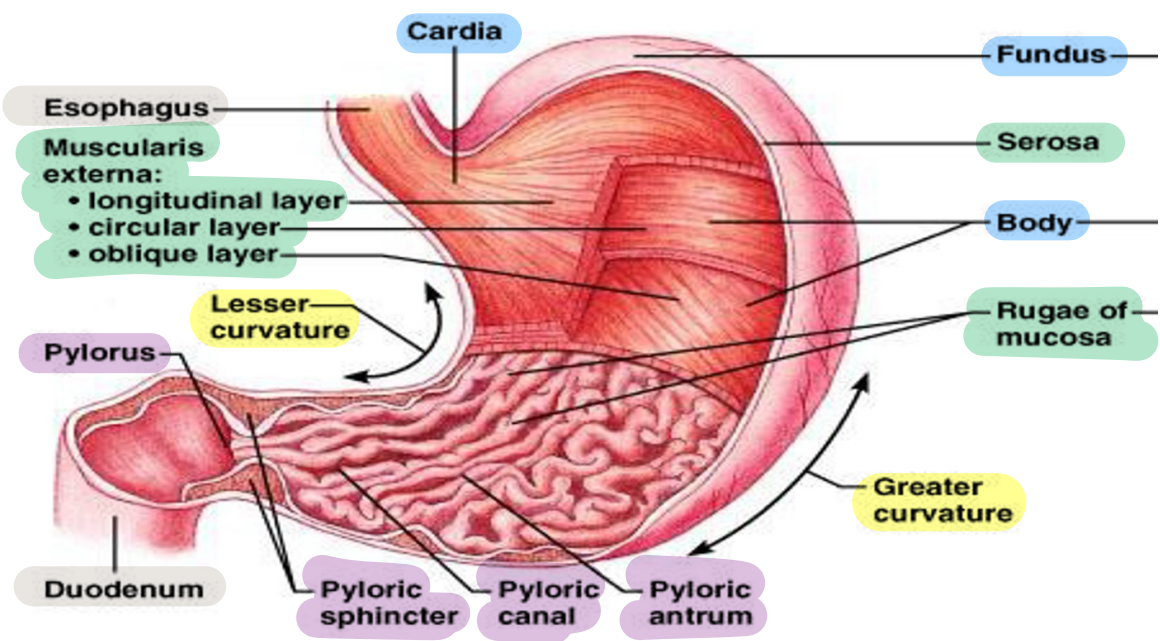

# LESSER AND GREATER OMENTUMS

✓ Two layers of the peritoneum arise from the lesser curvature, forming the ***lesser omentum***. The lesser omentum connects the stomach to the liver. Between these two layers, there are fat, blood vessels, nerves, and lymph nodes.

✓ Two layers of the peritoneum arise from the greater curvature, forming the ***greater omentum***. Like the lesser omentum, the greater omentum contains fat, blood vessels, nerves, and lymphatic vessels. It descends from the greater curvature of the stomach, then ascends, and attaching eventually to the transverse colon. The greater omentum originates from the greater curvature and ends at the transverse colon, surrounding it, therefore the **transverse colon** is an **intraperitoneal** organ just like the stomach, meaning it is entirely enclosed by the peritoneum, while the **ascending and descending colon** are **retroperitoneal** organs, meaning they lie behind the peritoneum (anterior to them).

✓ The lesser omentum is divided into two parts: the ***hepatogastric ligament*** (connecting the liver to the stomach) and the ***hepatoduodenal ligament*** (connecting the liver to the duodenum).

✓ ***Omental foramen (epiploic or foramen of winslow)*** is located behind the free edge of the the lesser omentum. It communicates with the lesser sac behind the stomach.

✓ Free edge of the lesser omentum contains **common bile duct**, **hepatic artery** and **portal vein**.

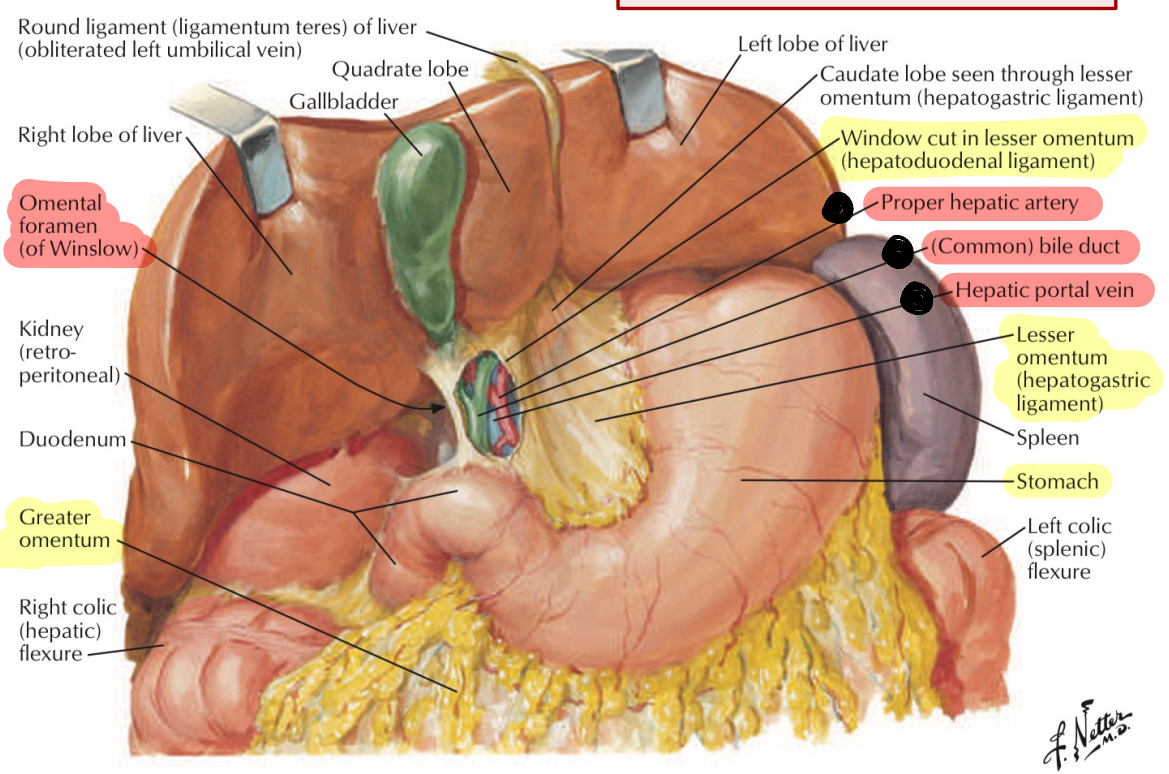

# Histology of the Stomach 8

Simple Columnar epithelium without Goblet Cells, Continue ↴ to the lining of Gastric Gland.

Canal

Contain *Gastric gland

Contain blood vessels + lymphatic Vessels

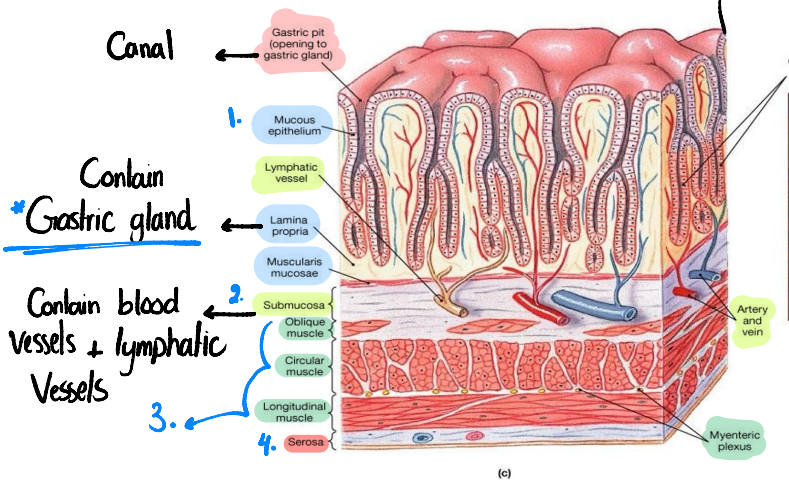


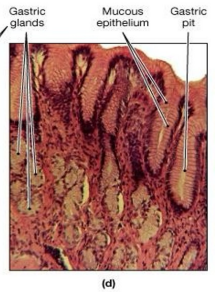


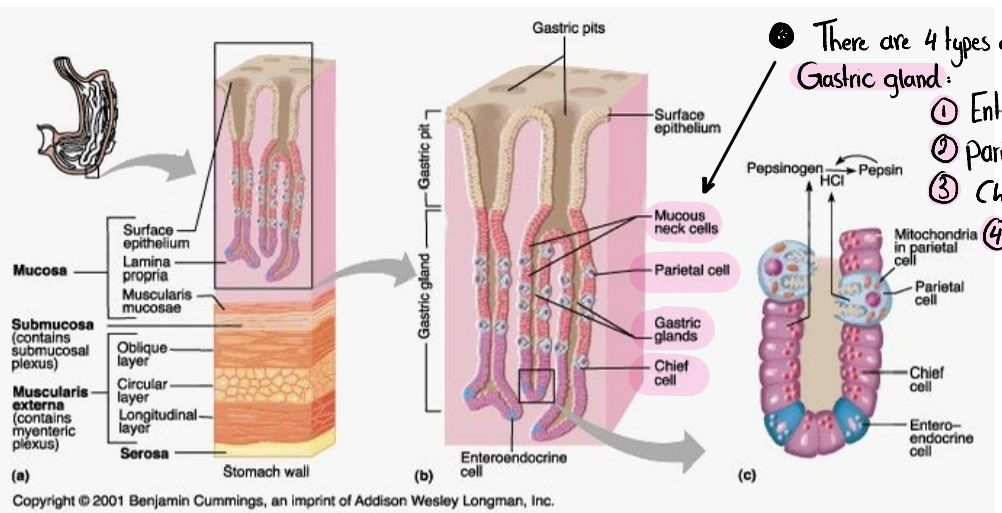


Copyright © 2001 Benjamin Cummings, an imprint of Addison Wesley Longman, Inc.

There are 4 types of Cells in the Gastric gland:

1. Enteroendocrine G-cells
2. Parietal Cells
3. Chief Cells
4. mucus neck cells

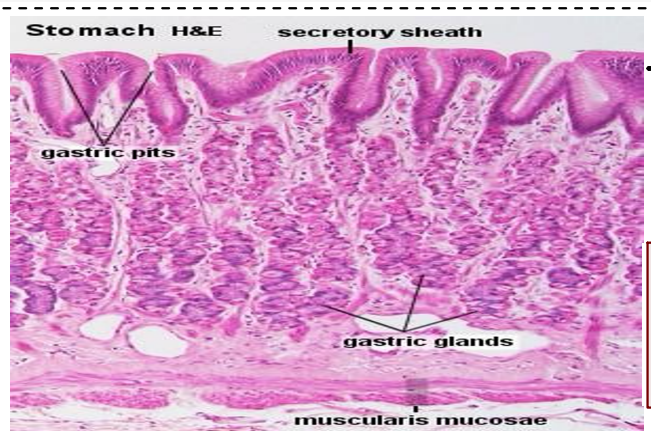


# The Goblet Cell always on the Surface

# The mucus Cell → inside

There are four different types of cells can be identified in the **gastric glands: enteroendocrine cells (G cells), parietal cells** (superficial to chief cells), **chief cells** (deep to parietal cells at the base of the gland), and **mucus neck cells** (differ from the mucous cells lining the luminal surface and the gastric pits).

# Peritoneum of Stomach:

حكينا عنهم فوق

- The peritoneum (visceral peritoneum) completely surrounds the stomach.
- It leaves the lesser curvature as the **lesser omentum**
- It leaves the greater curvature as the **gastrosplenic** ligament and the **greater omentum**
- The gastrosplenic ligament extends from the upper part of the greater curvature to the spleen, and the greater omentum extends from the lower part of the greater curvature to the transverse colon

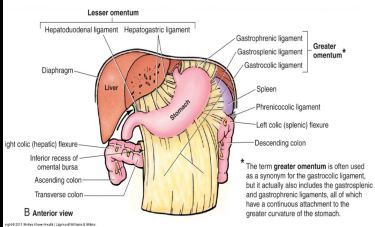


Lesser Omentum

Greater Omentum

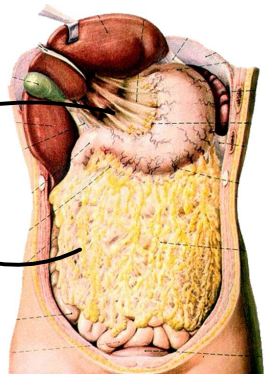

# Relation of the Stomach:

Splenic Artery.

**Anterior- superior**

- The anterior abdominal wall → at the epigastric region.
- the left costal margin → it extend to the left hypochondriac.
- the left pleura and lung
- the diaphragm → Separate the Stomach from the pleura.
- the left lobe of the liver

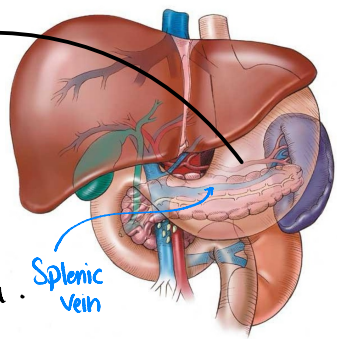


**Posteriorly = stomach bed** → The peritoneum form greater Sac + lesser Sac: the Greater located Anterior to the Stomach, while the lesser is posterior → when the Stomach is full it will enlarged backward (So we should have a Space).

- The lesser sac
- the Lt. crus of diaphragm
- the spleen
- the left suprarenal gland
- the upper part of the left kidney

Located at the edge of Stomach part of it Anterior and part is posterior.

- the splenic artery → The Splenic Vein is behind the pancreas.
- the body of pancreas
- the transverse mesocolon
- the transverse colon

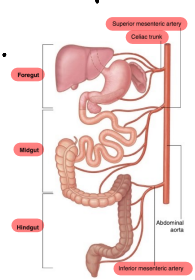


# The Blood Supply and Venous drainage of The Stomach:

## The GI tract is divided into:

### Foregut

- Lower esophagus.
- Stomach.
- Upper 1/2 of the Duodenum.

### Midgut

- lower 1/2 of Duodenum.
- Small intestine.
- large intestine to the lateral 1/3 of transverse Colon.

### Hind gut

- lateral 1/3 of transverse Colon → Descending → rectum → anal Canal.

Celiac trunk ↓ Superior mesenteric Artery ↓ inferior mesenteric Artery ↓

# The Celiac trunk (above the Pancreas) which is the main blood Supply to the Foregut .. give : ① Left Gastric , ② Splenic , ③ hepatic which are the main Branches

What Arteries go to the Stomach ? Left Gastric (in the lesser omentum) + from the hepatic Right Gastric + Right Gastroepiploic from the Hepatic + Left Gastroepiploic from the Splenic = both are in the Greater omentum

+ from the Splenic there is (5-7) Short Gastric to the Fundus

The Hepatic Artery go to the liver but it give Gastroduodenal branch that give: Superior pancreaticoduodenal + Right Gastroepiploic .

---

## Veinous drainage of the Stomach :

← عكس الـ Arteries تمامًا

# Left Gastric Vein from the esophagus and Stomach go to the portal, Right Gastric Vein also go to the portal then to the Superior mesenteric . that Communicate with the Splenic and give the portal Vein that go to the liver ..




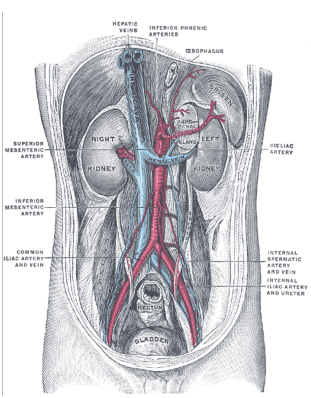


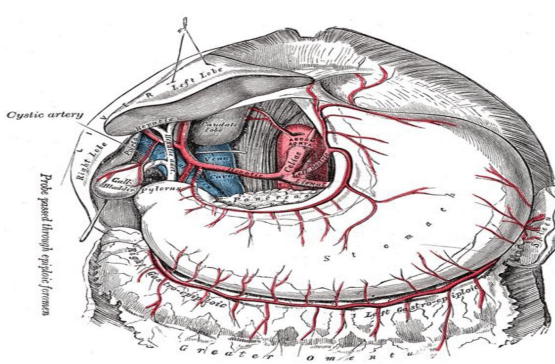

# STOMACH - BLOOD SUPPLY & VENOUS DRAINAGE

## Arterial supply

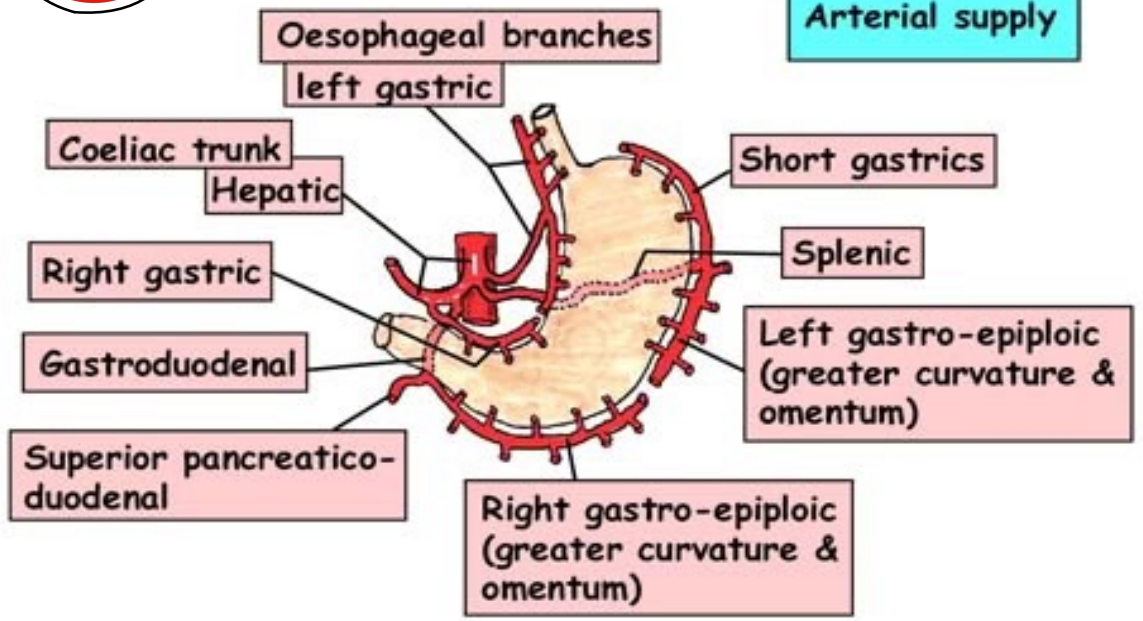


## Venous drainage

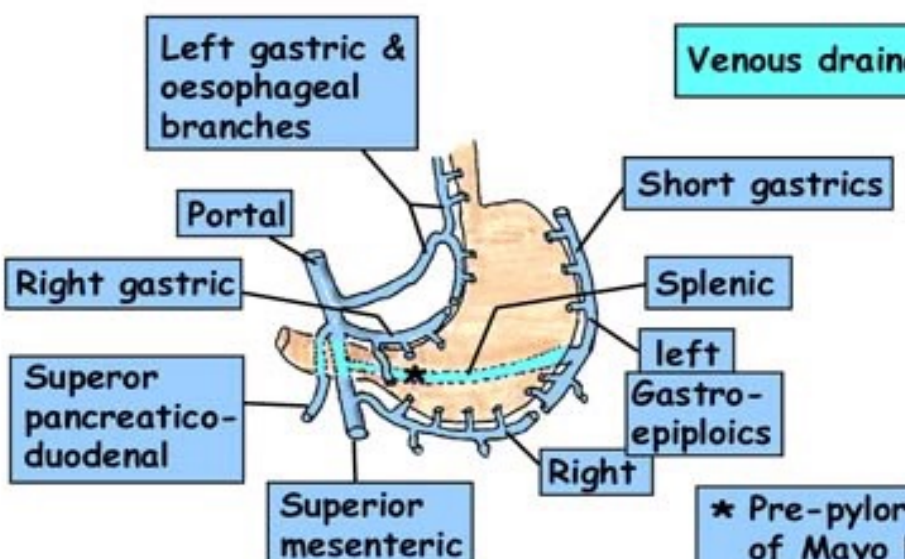


* Pre-pyloric vein of Mayo but first described by Laterjet

# Blood Supply of the Stomach:

## 1 The left gastric artery

- Arises from the celiac artery
- It passes upward and to the left to reach the esophagus
- Then descends along the lesser curvature of the stomach
- It supplies the lower third of the esophagus and the upper right part of the stomach

## 2- The right gastric artery

- arises from the hepatic artery
- runs to the left along the lesser curvature.
- It supplies the lower right part of the stomach.

## 3- THE SHORT GASTRIC ARTERIES

- Arise from the splenic artery (5-7 arteries)
- Arises from splenic artery
- pass upward in the gastrosplenic to supply the fundus

## 4- The left gastroepiploic artery

- Arises from the splenic artery
- Supply the stomach along the upper part of the greater curvature in the greater omentum

## 5- The right gastroepiploic artery

- arises from the gastroduodenal branch of the hepatic artery
- It passes to the left and supplies the stomach along the lower part of the greater curvature in the greater omentum.

# Veinous drainage of the Stomach:

- The veins drain into the portal circulation
- The left and right gastric veins drain directly into the portal vein
- The right gastroepiploic vein joins the superior mesenteric vein(which meet the splenic vein behind the neck of pancreas to form the portal vein

Torlus Artery why ? When the Stomach enlarged it will press on it and to Prevent the rapture it will elongate ...

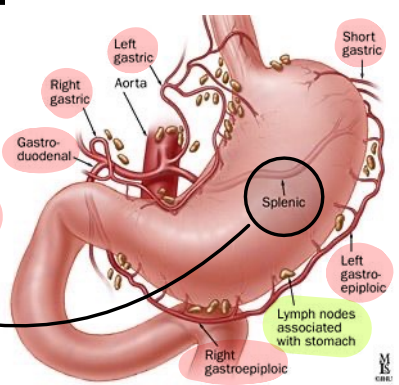


# The lymphatic Drainege of Stomach:

- Follow the arteries of stomach
- The left and right gastric nodes
- The left and right gastroepiploic nodes
- The short gastric nodes
- All lymph from the stomach eventually passes to the celiac nodes located around the root of the celiac artery on the posterior abdominal wall.

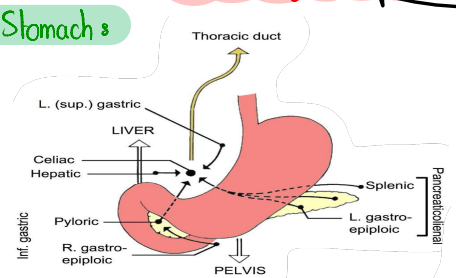


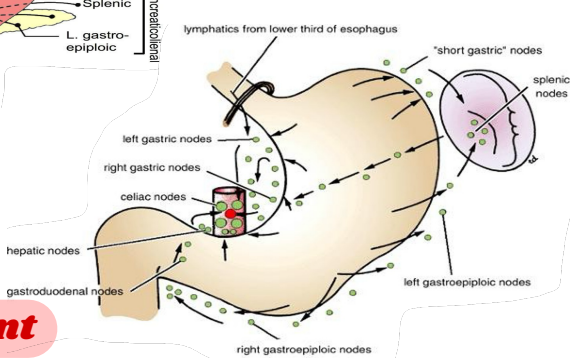


**Very Important**

# ARTERIAL BLOOD SUPPLY OF THE STOMACH

الفريق العلمي ♡
* كل الشغلات مذكورة بلي بيحب يشيّن بشكل متسلسل ...

- ✓ The ***celiac trunk*** is the main arterial supply to the stomach. It gives off three primary branches: the ***left gastric artery***, the ***splenic artery***, and the ***hepatic artery***.
- ✓ Each of these branches contributes to the vascular supply of different stomach regions. The ***left gastric artery*** directly supplies the lesser curvature and lesser omentum and sends ***esophageal branches to sypply lower third of esophagus*** . From the ***hepatic artery***, the ***right gastric artery*** arises and also runs along the lesser curvature and lesser omentum.
- ✓ The ***gastroduodenal artery***, another branch of the ***hepatic artery***, gives off the ***superior pancreaticoduodenal artery*** and ***right gastroepiploic artery***, the latter supplies the greater curvature and greater omentum. While the ***left gastroepiploic artery*** arising from the ***splenic artery***, which also runs along the greater curvature and greater omentum.
- ✓ The ***splenic artery*** as well gives ***short gastric arteries***, which supply the fundus of the stomach.
- ✓ ***superior pancreaticoduodenal artery*** arises from the ***gastroduodenal artery,*** primarily supplies the pancreas and duodenum.

# VENOUS BLOOD SUPPLY OF THE STOMACH

- ✓ The venous drainage of the stomach generally follows the reverse path of the arteries.
- ✓ The ***left gastric vein*** drains blood from the oesophagus and the lesser curvature of the stomach, and it empties directly into the ***portal vein***.
- ✓ The ***right gastric vein*** also drains the lesser curvature and joins the ***portal vein*** as well.
- ✓ The ***right gastroepiploic vein*** (which accompanies the right gastroepiploic artery) drains into the ***superior mesenteric vein***.
- ✓ The ***left gastroepiploic vein*** and the ***short gastric veins***, both of which drain the greater curvature and the fundus respectively, empty into the ***splenic vein***.
- ✓ The ***splenic vein*** and the ***superior mesenteric vein*** come together to form the ***portal vein***, which ultimately carries the blood to the liver.

- ✓ All the lymphatic drainage from the organs supplied by the coeliac trunk—including the **stomach, spleen, and duodenum**—first drains into the **celiac lymph nodes**, which are located around the **coeliac trunk**.
- ✓ From there, lymph flows into larger lymphatic vessels that drain into the **cisterna chyli**, located near the abdominal opening of the aorta and then to the **thoracic duct**.

Very important

# Nerve Supply for Stomach :

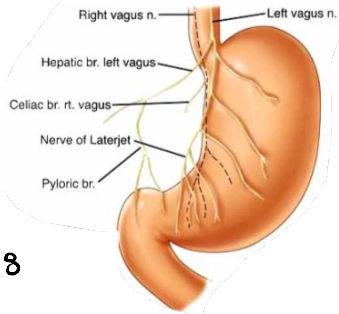


## Sympathetic

→ Come from the Superior Sympathetic Cervical ganglia :

→ in the Abdomen the Sympathetic Supply mostly Come from the Chest the Superior Sympathetic Cervical ganglia that have fiber extend downward via Sympathetic Chain go to the abdomen as Splanchnic nerve

Greater — lesser

both Carry Sympathetic fiber as postganglionic after passing through Ciliac ganglia without Synapse .

## parasympathetic

Through Vagus Nerve :

Descend to the abdomen as Trunk from the esophogus then piece the Diaphram . the left Vagus become Anterior + the right become posterior both of them give branches

- **The anterior vagal trunk**
  - mainly from the left vagus nerve

**Distribution**

1. The anterior surface of the stomach.
2. A large hepatic branch passes up to the liver
3. Ant. Nerve Laterjet → pylorus

it's important in the evacuation of Stomach all the food will stay in the Stomach تخيّل يتعطّج

- The nerve supply includes **sympathetic fibers** derived from the celiac plexus
- **parasympathetic fibers** from the right and left vagus nerves .
- The sympathetic innervation of the stomach carries a proportion of **pain sensation**
- The parasympathetic vagal fibers are **secreto-motor** to the **gastric glands** and motor to the muscular wall of the stomach( peristaltic movement)
- The pyloric sphincter receives **motor fibers** from the sympathetic system and inhibitory fibers from the vagus.n.

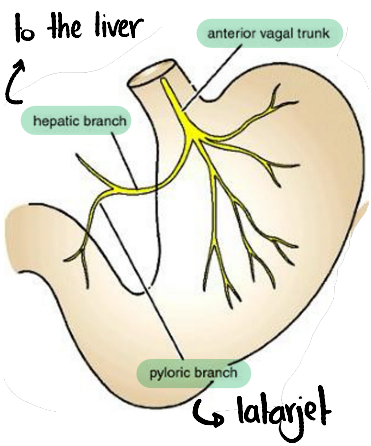

- **The posterior vagal trunk**
  - mainly from the right vagus nerve
  - **Distribution**
1. mainly the posterior wall of the stomach.
2. Ant. Wall of body of stomach
3. Celiac branch→ small intestine+ as far as to splenic flexure+ pancreas
4. post. Nerve latarjet→ pylorus

Duodenum + jenjum + ilium → large intestine to the Lateral 1/3 of transverse Colon

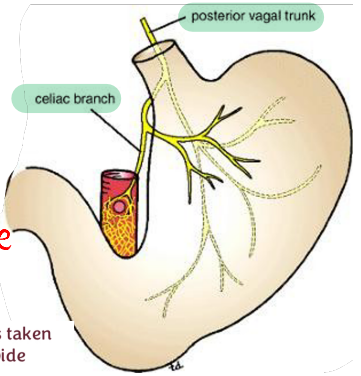


✓ After that point, the parasympathetic innervation is taken over by the **S2, S3, and S4 spinal nerves**.These provide parasympathetic supply to the **hindgut**.

## STOMACH – LYMPHATIC DRAINAGE & NERVE SUPPLY

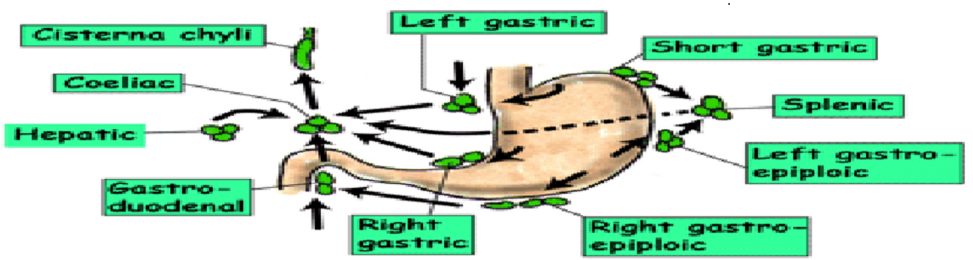


**Sympathetics** Greater splanchnic nerves (T5–9) for decreasing motility, vaso-constriction, closing pylorus & sensation

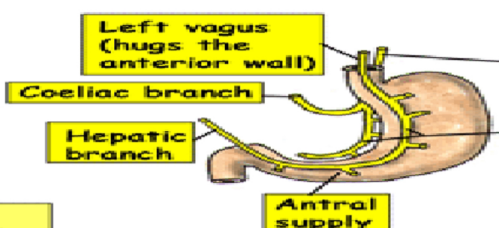


**Vagus nerves** are 80% sensory, 20% motor for increasing motility, opening pylorus & initiating secretions

Note: Highly selective vagotomy destroys vagus to fundus & body but preserves nerve to antral pump

## Clinical notes

- Gastric Ulcer
- Truncal vagotomy →Sectioning the vagus nerves below the diaphragm around the esophagus. This was the surgical procedure before; it has many problems and complications.
- Highly selective vagotomy (cut all branches of the vagi except latarjet nerve)
- Peptic ulcer(D.U)
- Gastroscopy is now present in every clinic.
- Pyloroplasty (drainage of the stomach)= gastro- jejunostomy

✓ **Peptic ulcers** are mainly **duodenal ulcers**, **gastric ulcers** on the other hand are rare to occur and if it happens, it is mostly **malignant**.

✓ Therefore, the general rule is: **any gastric ulcer is considered malignant until proven otherwise.**

✓ On the contrary, in the duodenum, the rule is the opposite: **any Duodenal ulcer is considered peptic ulcer until proven otherwise.**

✓ **Helicobacter pylori** is now recognized as the main cause of peptic ulcers.

✓ Nowadays treatment is devoid of any surgical intervention, only two antibiotics with proton pump inhibitors are given.

### NERVE SUPPLY FOR THE STOMACH

✓ The **sympathetic fibers** come from the **superior cervical sympathetic ganglia** and travel down along **sympathetic chain**. On the other hand, the **parasympathetic fibers** come through the **vagus nerve**.

✓ In the abdomen, the sympathetic supply mostly comes from the thoracic region. The **superior cervical sympathetic ganglia** fibers extend downward via **sympathetic chain** to reach the abdomen in the form of the **splanchnic nerves**.

✓ The **greater and lesser splanchnic nerves**, which carry sympathetic fibers. These fibers are postganglionic, meaning they pass through the **celiac ganglia** without **synapsing**.

### NERVE SUPPLY FOR THE STOMACH

✓ The **vagus nerve** descends into the abdomen in the form of a **vagal trunk**, which wraps around the esophagus.

✓ As it passes through the diaphragm:The **left vagus nerve** becomes the **anterior vagal trunk**.The **right vagus nerve** becomes the **posterior vagal trunk**.

✓ Both the anterior and posterior vagal trunks give off branches to supply abdominal organs.

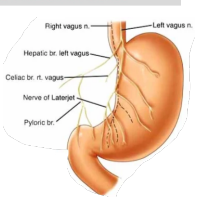

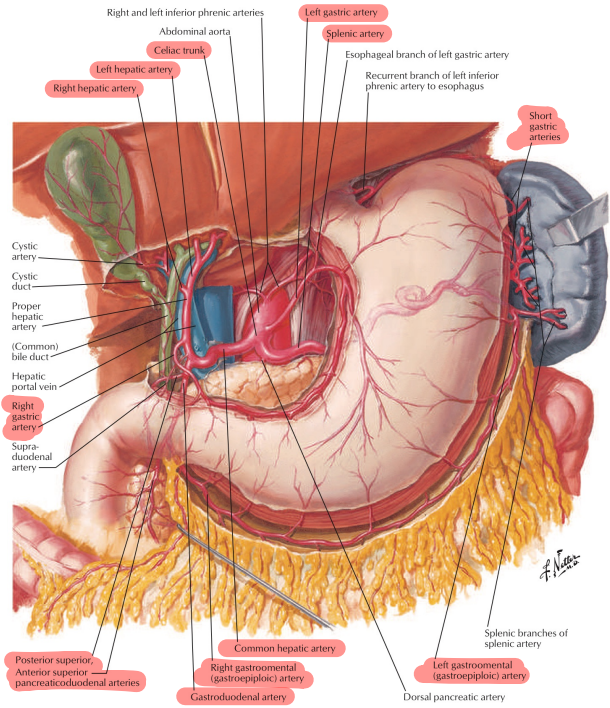


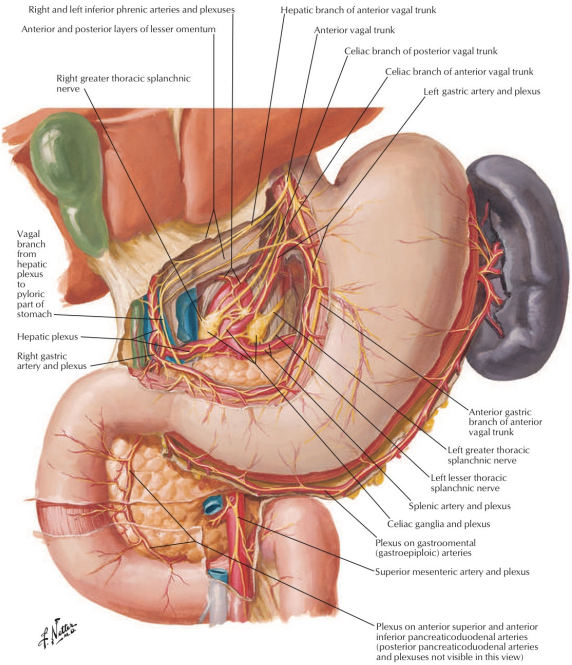


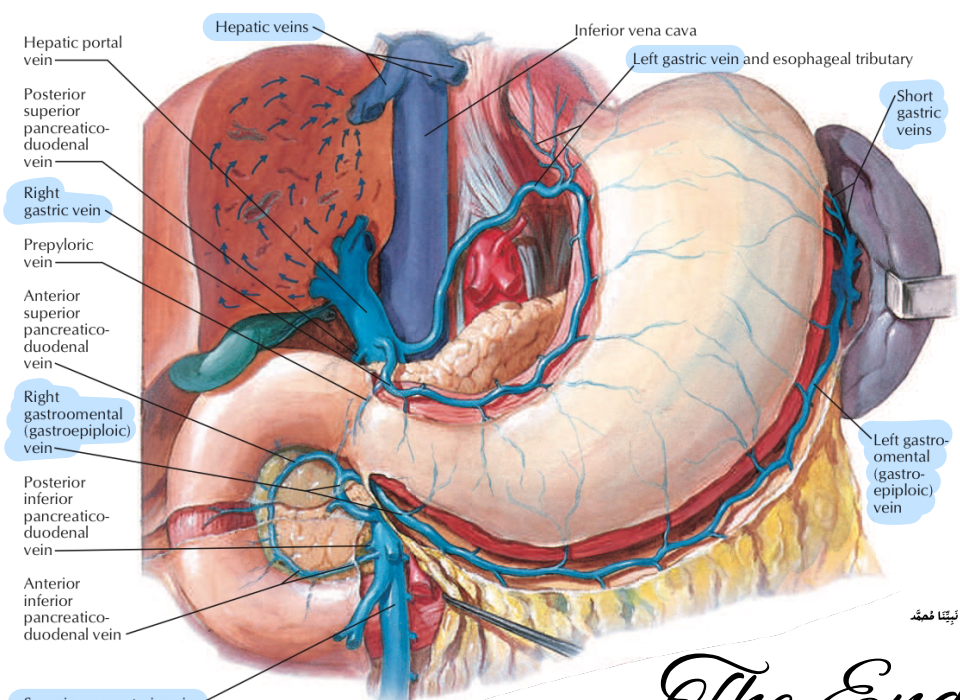


اللَّهُمَّ صَلِّ وَسَلِّمْ وَبَارِكْ على نَبِيِّنَا مُحَمَّد

The End