

HEMATOLYMPHOID SYSTEM BLEEDING DISORDERS


Dr. Tariq Aladily

Associate professor

Department of Pathology

The University of Jordan

tnaladily@ju.edu.jo



ABNORMAL BLEEDING

- Defined as spontaneous bleeding or prolonged bleeding after trauma
- Caused by abnormality in:
 - 1) platelets
 - 2) clotting factors
 - 3) blood vessels – endothelial cells



FRAGILE BLOOD VESSELS

- High corticosteroid
- Scurvy (vitamin C deficiency)
- Vasculitis (autoimmune or infectious)
- Inherited disorders of connective tissue
- Patients develop spontaneous petechiae and ecchymoses in skin and mucous membranes
- Laboratory tests of platelets and clotting factors are normal



DISSEMINATED INTRAVASCULAR COAGULATION (DIC)

- Systemic activation of coagulation system in the body
- Formation of myriads of thrombi in the microcirculation, may cause ischemia and microinfarction
- Followed by activation of fibrinolysis
- Then patients become at risk of severe bleeding (consumed platelets and clotting factors)
- Patients develop thrombocytopenia, anemia and schistocytes



PATHOGENESIS

- 1) Release of tissue factor into the circulation (activates extrinsic pathway)
- 2) Widespread endothelial damage (causes release of tissue factor and expose the subendothelial von Willebrand factor)
- 3) Release of negatively charged substances in the circulation (activates intrinsic pathway)



HIGH TISSUE FACTOR RELEASE

- From placenta, in obstetric complications
- From certain cancer cells (acute promyelocytic leukemia, adenocarcinoma)
- Bacterial sepsis, bacterial toxins activate TF on monocytes, also monocytes secrete tumor necrosis factor and IL-1 that stimulate expression of TF on endothelium and inhibit thrombomodulin



WIDESPREAD ENDOTHELIAL DAMAGE

- Deposition of antigen-antibody complexes (systemic lupus erythematosus, vasculitis)
- Severe heat exposure (heat stroke, burn injury)
- Snake venom
- Certain infections (meningococci, rickettsiae, COVID19), this condition is called systemic inflammatory response syndrome



ACTIVATION OF INTRINSIC PATHWAY

- Massive tissue damage (trauma, surgery)
- Head injury
- Brain substance and collagen are negatively charged particles that are released in blood



CLINICAL AND LABORATORY FINDINGS

- Thrombocytopenia, prolonged PT and PTT, schistocytes
- Acute DIC (e.g. obstetric complication) shows ecchymosis, severe hemorrhage into body cavities
- Chronic DIC (e.g. cancer related) shows recurrent thrombosis
- -----
- Waterhouse-Friderichsen syndrome: meningococcal sepsis → DIC → adrenal hemorrhage → acute adrenal failure (no steroids, hypotension)
- Sheehan syndrome: complicated labor → DIC → severe hemorrhage → pituitary ischemia and necrosis



THROMBOTIC THROMBOCYTOPENIC PURPURA (TTP) & HEMOLYTIC UREMIC SYNDROME (HUS)

- Widespread formation of platelets-rich thrombi in microcirculation
- NO activation of clotting factors (normal PT and PTT)
- Leads to thrombocytopenia and tendency for bleeding
- Clinically: fever, thrombocytopenia, microangiopathic hemolytic anemia, renal failure and neurologic symptoms (the latter not present in HUS)



TTP

- Congenital or acquired
- Deficiency in metalloproteinase ADAMTS13, normally controls vWF production
- ADAMTS13 normally cleaves the precursor of vWF (large multimer molecule) into vWF. This multimer is capable of binding multiple platelets causing thrombosis



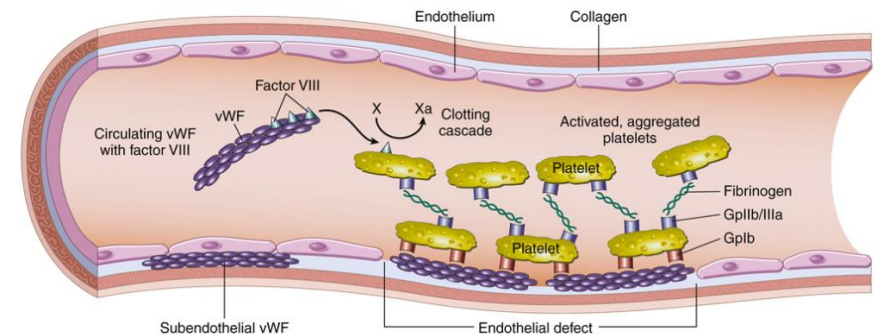
HUS

- Caused by E. Coli O157:H7 bacterial infection
- Food borne
- Bacteria secretes toxin that activates complement system and causes endothelial damage, mainly in kidneys



VON WILLIBRAND FACTOR

- Endothelial cells are normally the major source of vWF
- It is also present in platelets granules and subendothelial area
- Facilitate platelets adhesion to damaged blood vessels
- It also stabilizes factor VIII
- Precursor of vWF is a large multimer molecule
- Examined by ristocetin aggregation test (ristocetin enhances vWF binding to platelets), if no aggregation → vWF deficiency



VON WILLIBRAND DISEASE

- Autosomal dominant
- Most common inherited bleeding disorder (1% of population in US)
- Affects platelets function (dominant symptom) and coagulation (factor VIII)
- Patients present with ecchymosis, easy bleeding and menorrhagia
- In homozygous disease, factor VIII deficiency becomes severe enough to resemble hemophilia A disease
- Type 1: most common, modest reduction of vWF level
- Type 2A: the precursor of vWF is not synthesized, too
- Type 2B: the precursor of vWF is unstable with very short half-life, capable of binding to multiple platelets causing thrombocytopenia as well



HEMOPHILIA A

- X-linked disease
- Most common cause of inherited serious bleeding
- Deficiency in factor VIII (prolonged PTT)
- 70% have a family history, 30% appears as a new mutation
- Severe disease occurs when the level of factor VIII drops to 1% of normal level (spontaneous bleeding)
- Mild deficiency: bleeding occurs after trauma or surgery
- In 10% of patients: normal level but abnormal function
- Bleeding occurs in body cavities (joints, abdomen, chest), no petechiae
- Hemophilia B: identical to hemophilia A, less common, factor IX deficiency



THROMBOCYTOPENIA

- Defined as platelets count below 150,000 cell/uL
- Increased risk of bleeding occurs when count drops below 50,000
- Spontaneous bleeding: <5,000
- Bleeding occurs in superficial parts of body (skin, mucous membranes), called petechiae and ecchymosis
- Larger hemorrhage occurs in brain
- Thrombocytopenia may occur in the setting of increased platelets destruction (bone marrow shows increased megakaryocytic activity) or decreased production from bone marrow
- HIV infection causes thrombocytopenia (both increased destruction and decreased megakaryocytic survival)



IMMUNE THROMBOCYTOPENIC PURPURA

- Acute ITP is seen in children after viral infection (self-limited)
- Chronic ITP is commonly seen in middle-age women
- Formation of autoantibody (IgG) against glycoprotein IIb/IIIa or Ib/IX complexes
- Splenic histiocytes remove coated platelets and destroy them
- Splenomegaly is NOT prominent, but patients benefit from splenectomy
- Bone marrow shows proliferating megakaryocytes



HEPARIN-INDUCED THROMBOCYTOPENIA

- Moderate to severe thrombocytopenia affects 5% of patients receiving heparin after 1-2 weeks of therapy
- Formation of IgG antibody that binds factor-4 in a heparin-dependent manner, resulting in platelets activation and thrombosis (consumptive thrombocytopenia)
- Mostly seen in high-molecular weight heparin

