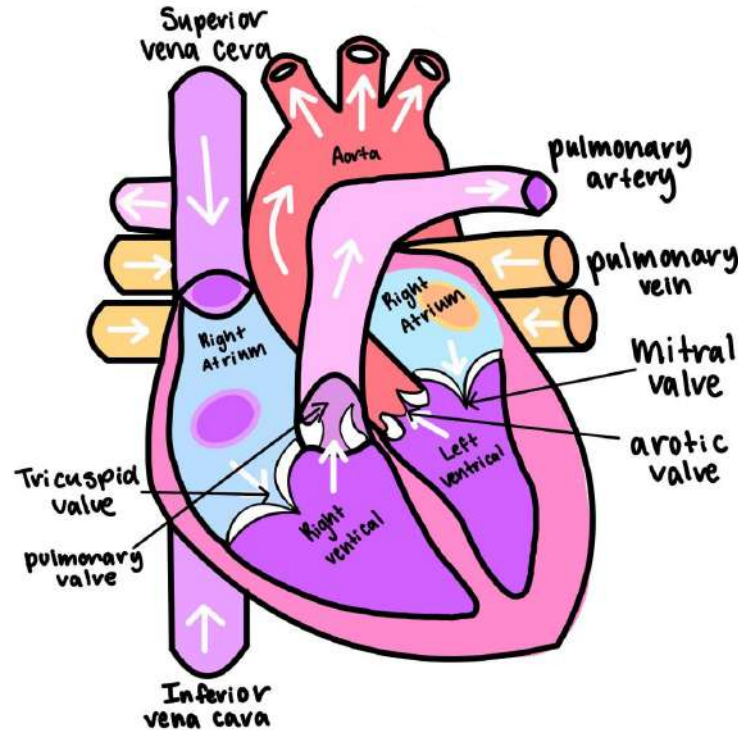
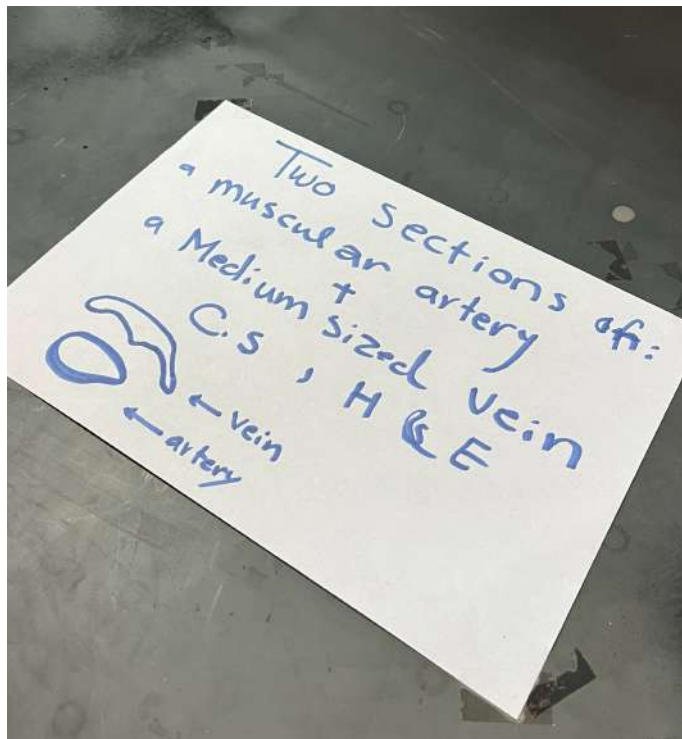
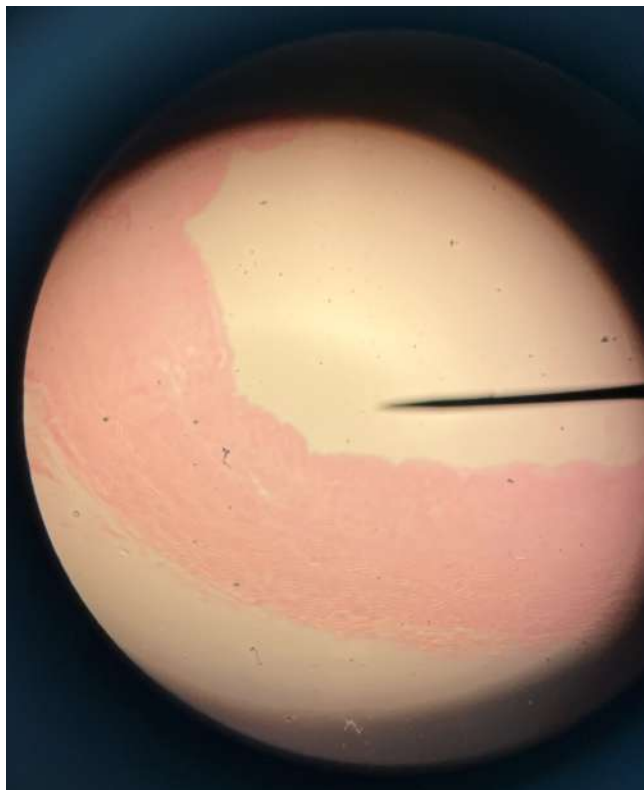
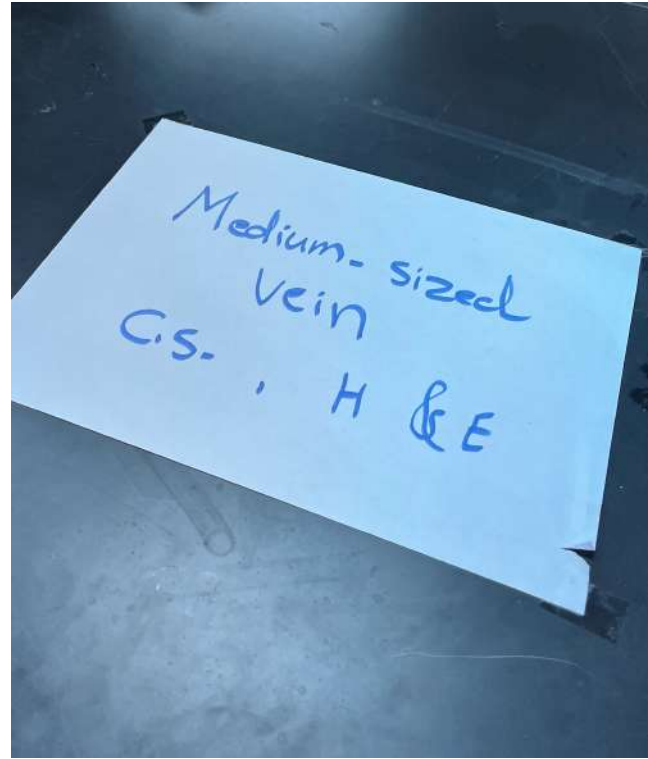
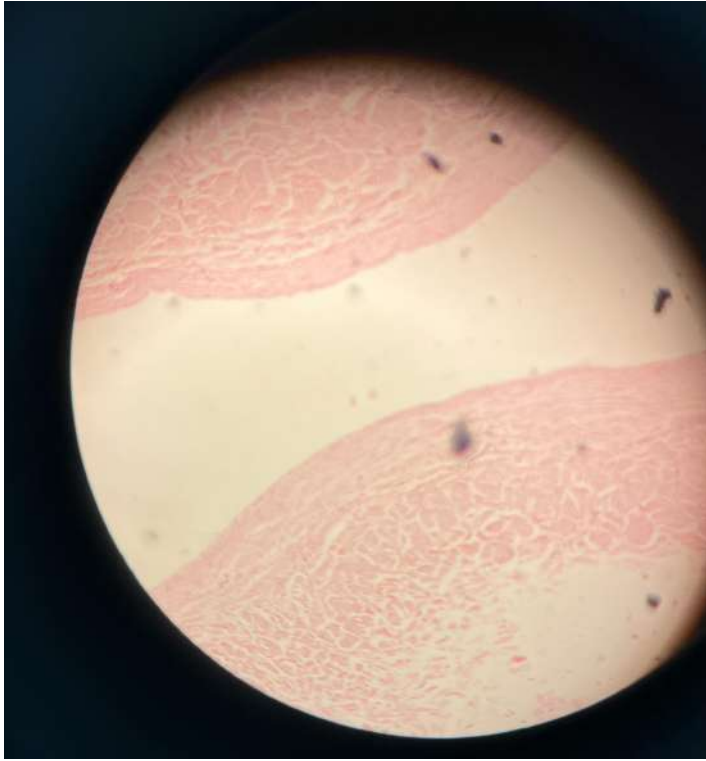


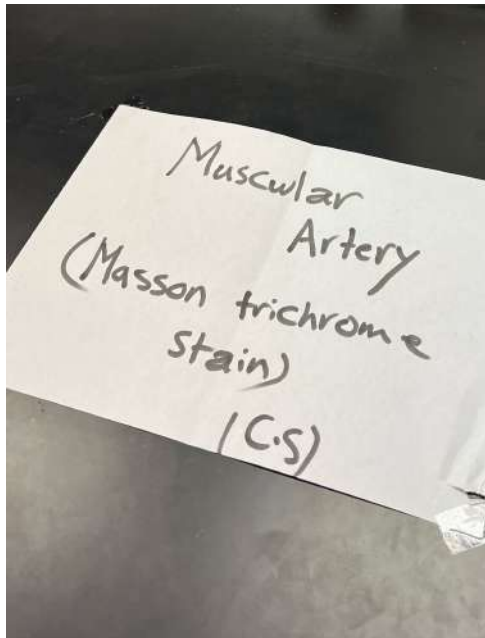
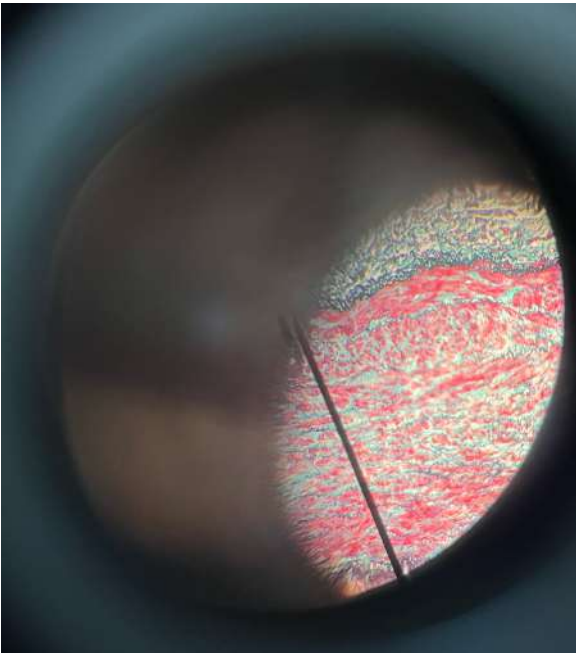
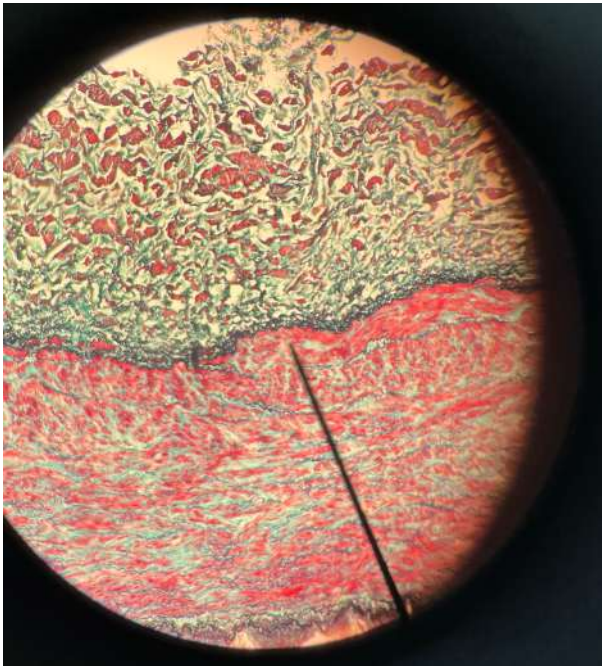
# The histology of the cardiovascular system

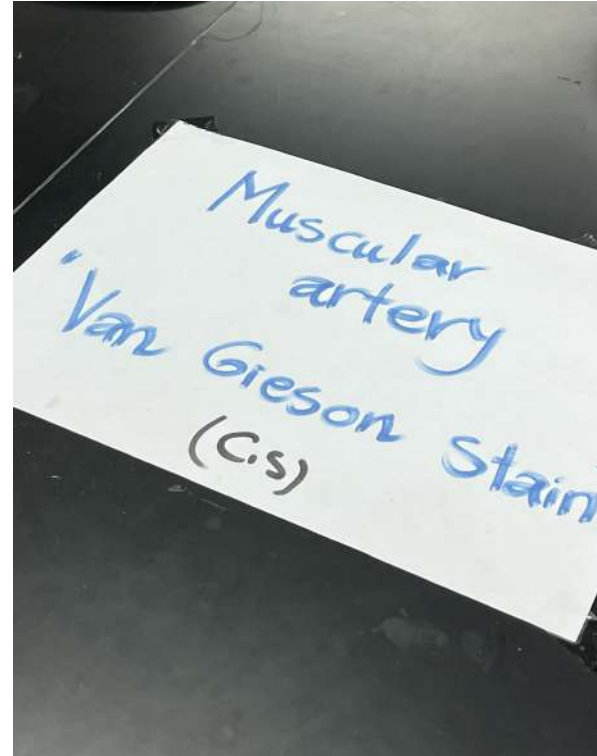
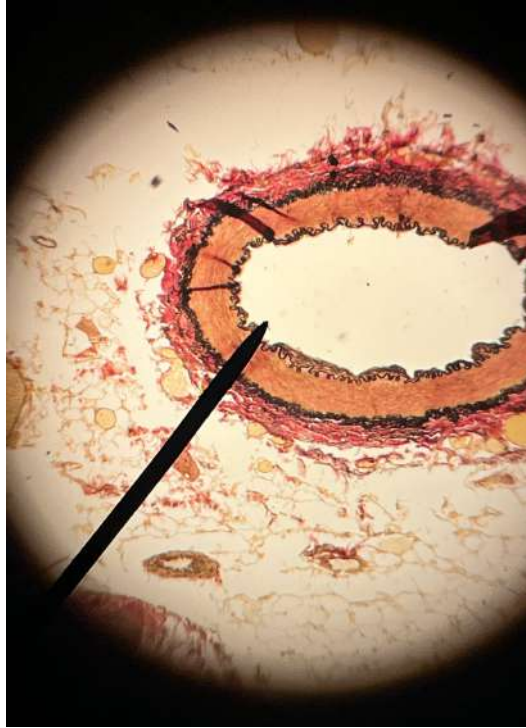
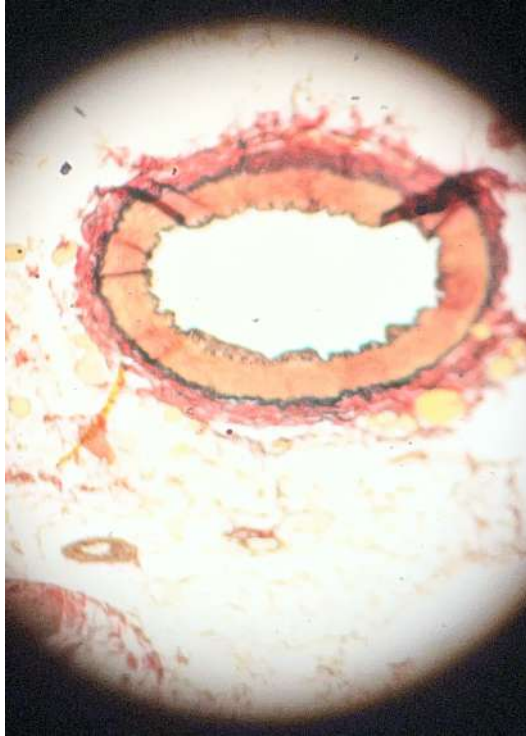

Done by : Aya AlJazazi

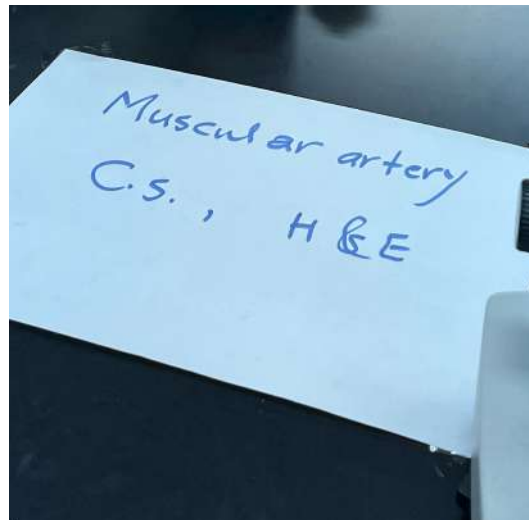
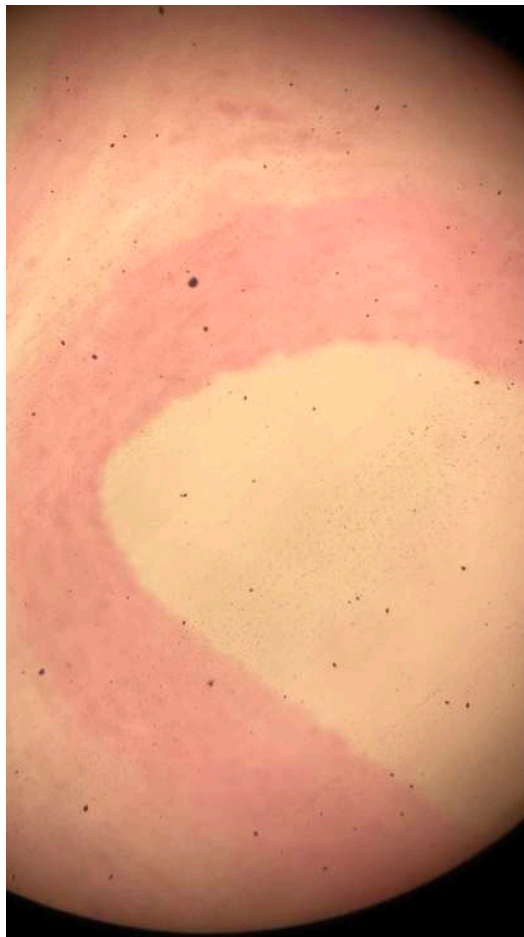
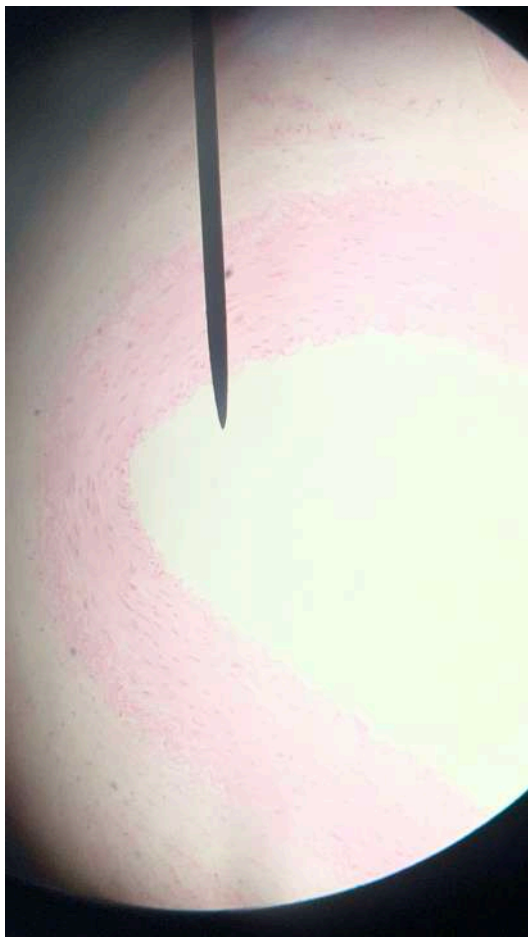
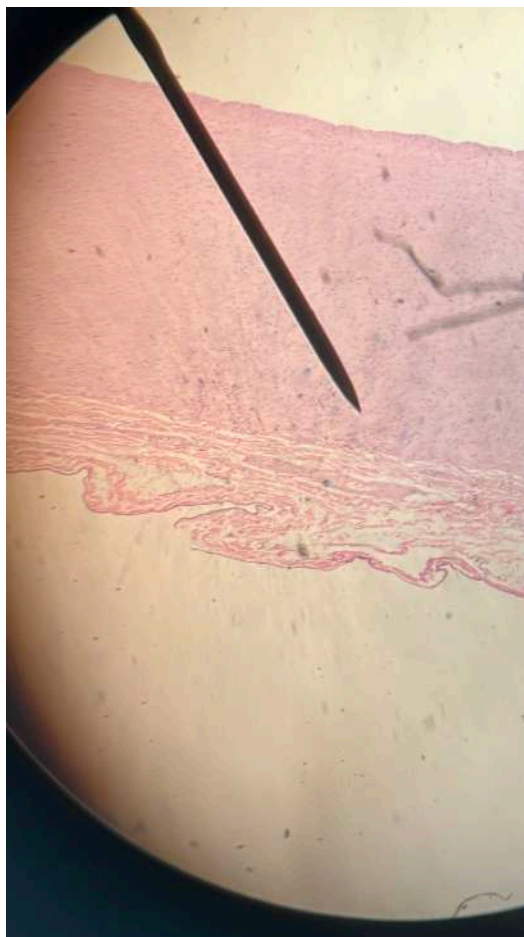


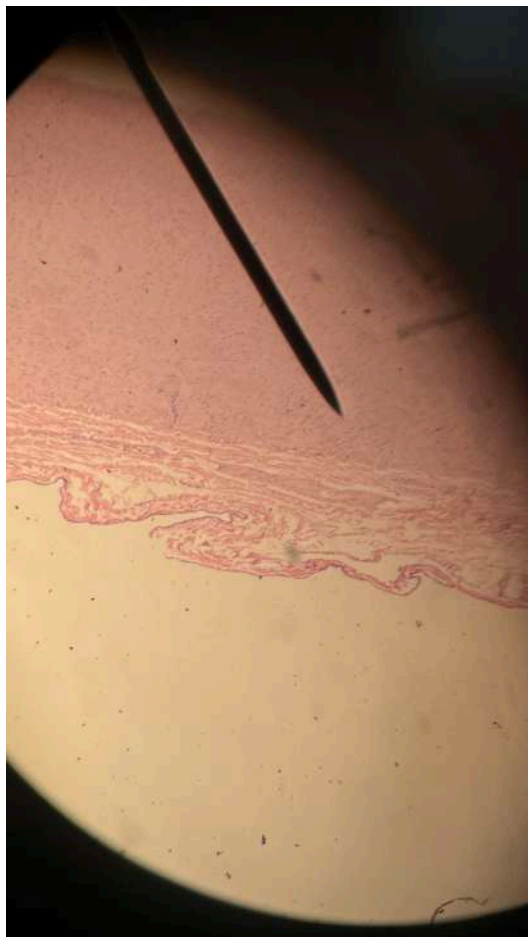

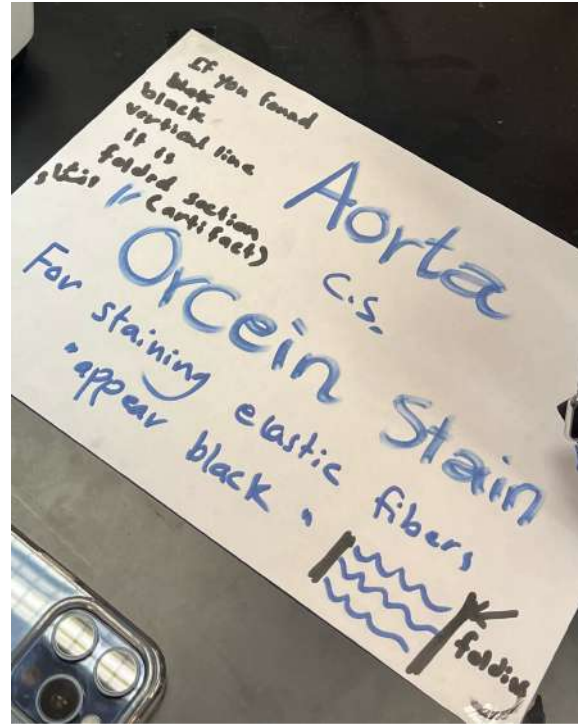
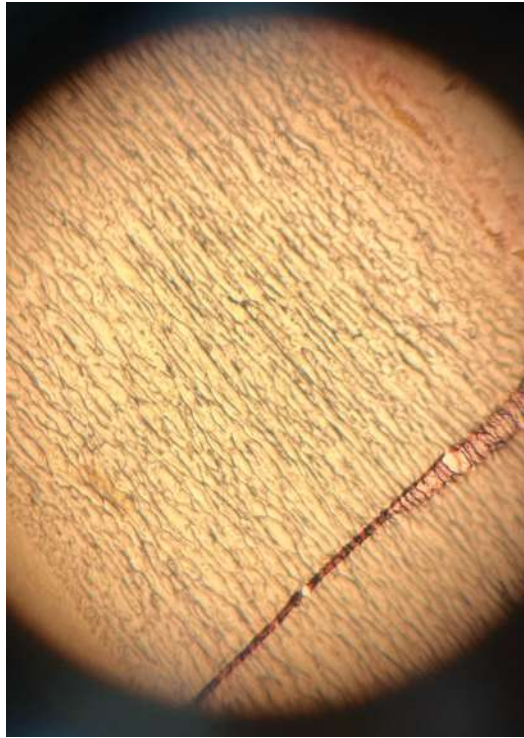
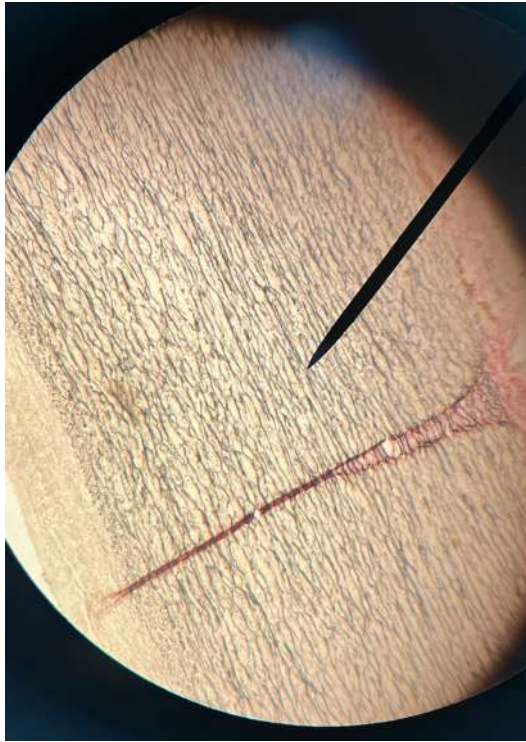




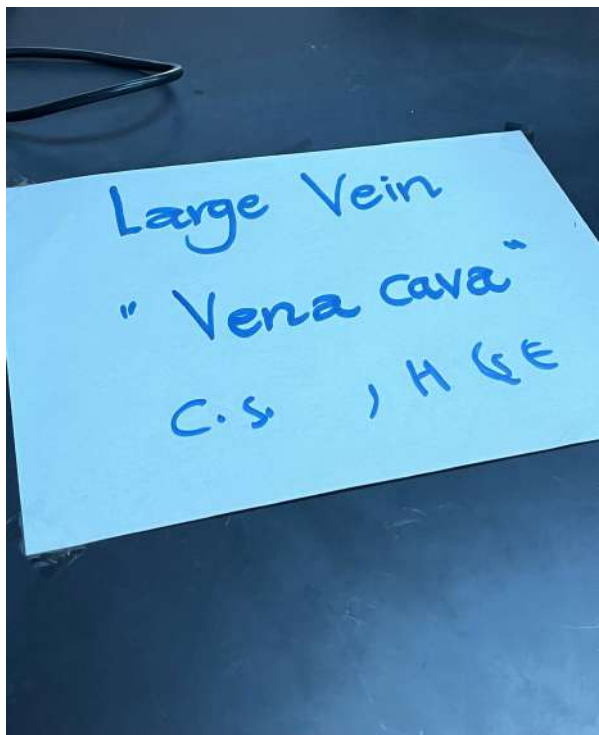
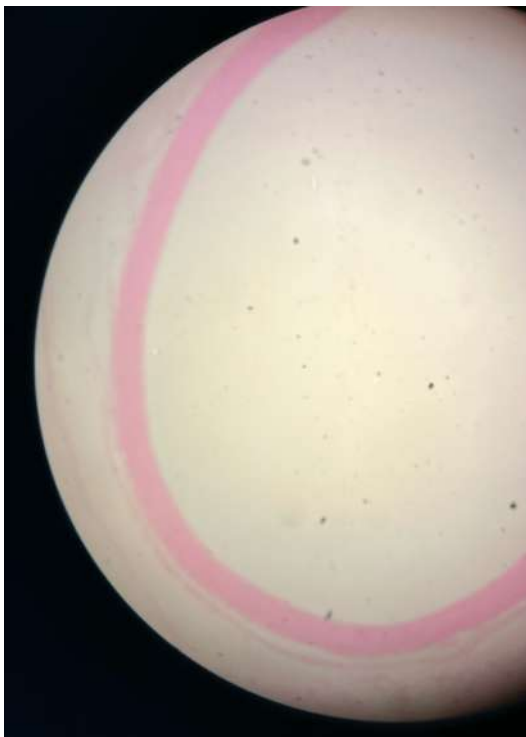
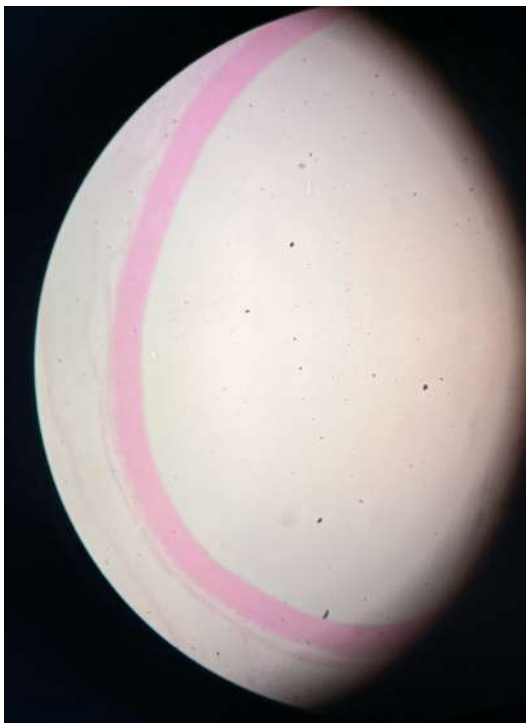


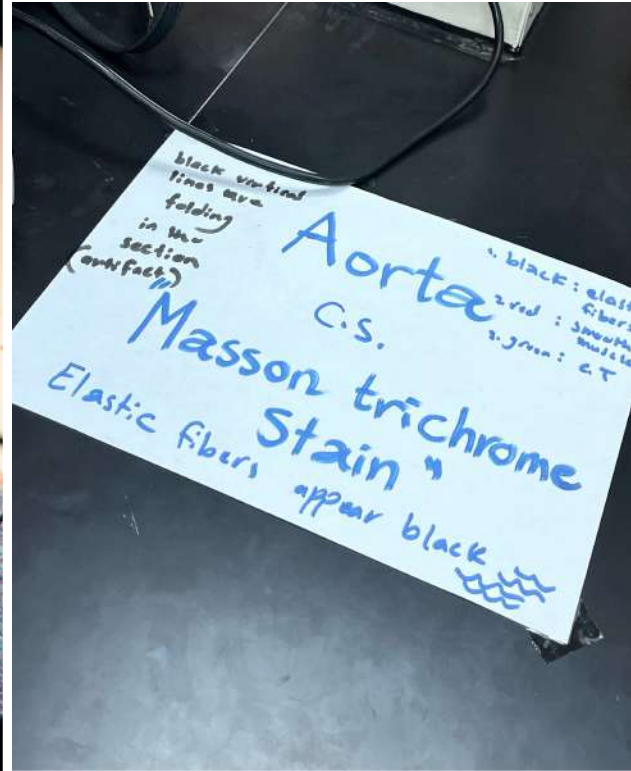
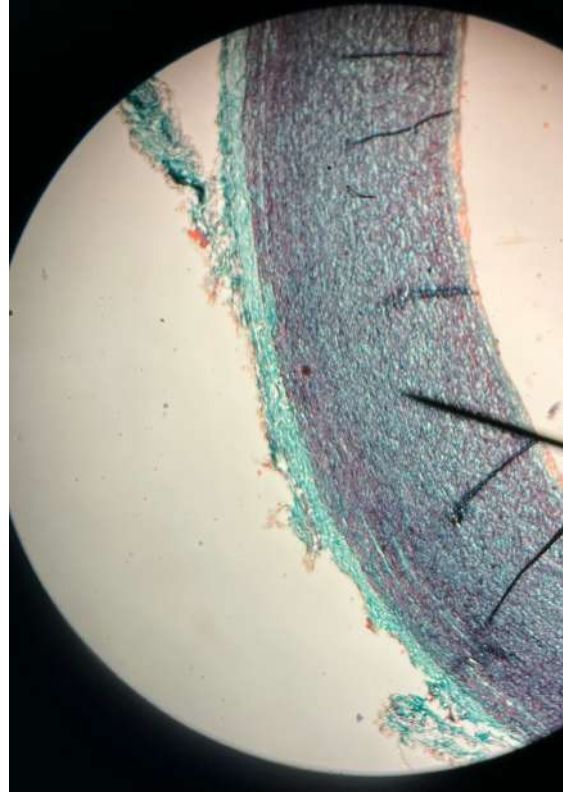
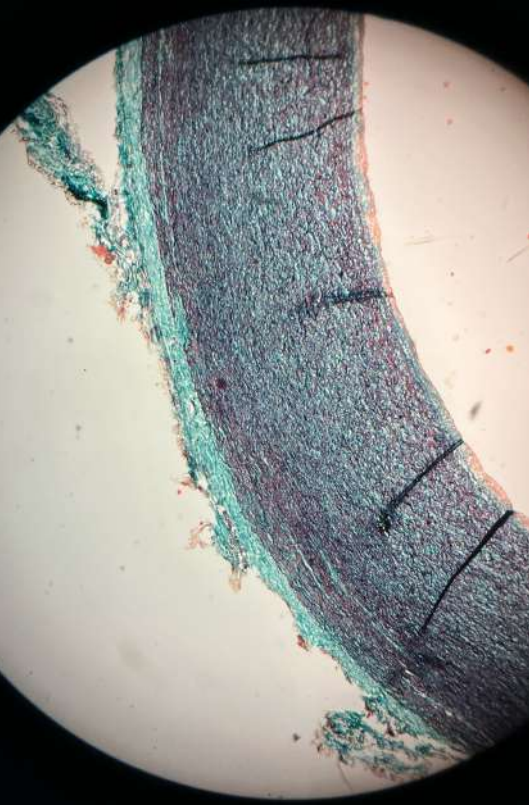


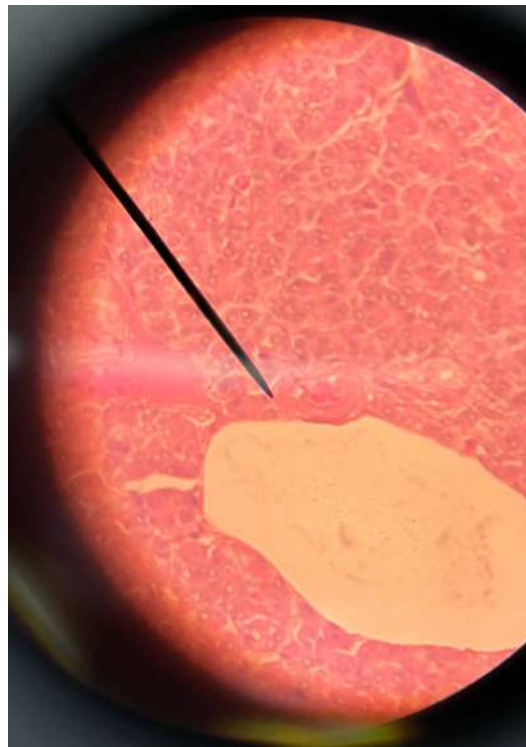
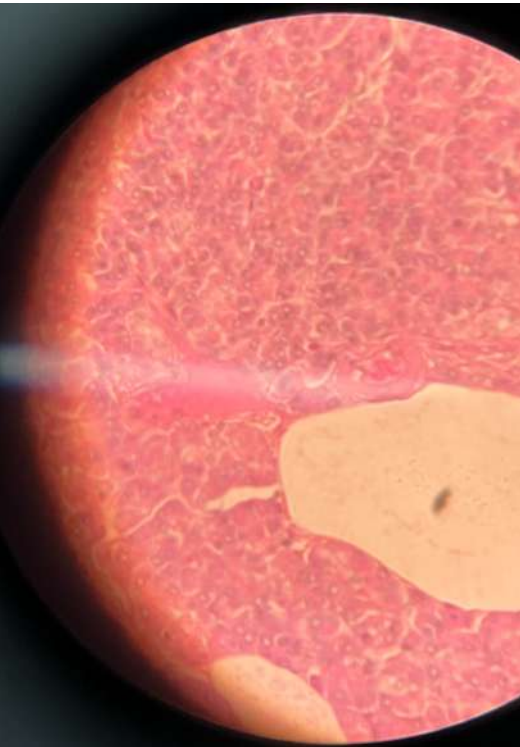Elastic artery  
Aorta  
C.S. , H & E









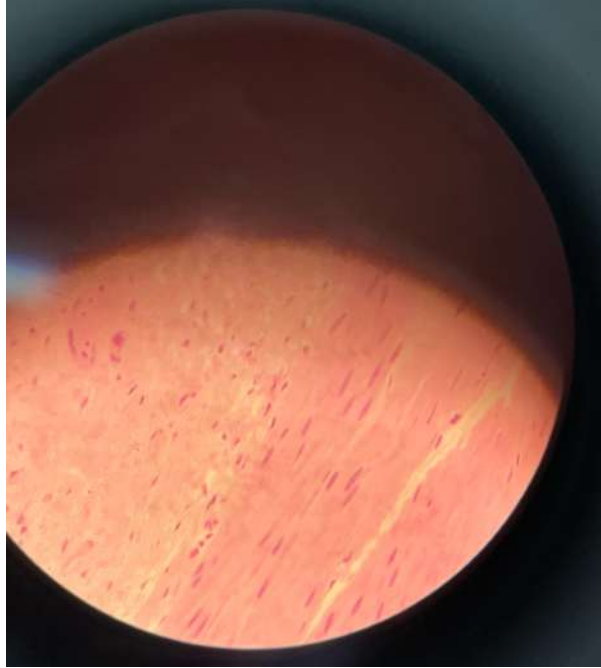
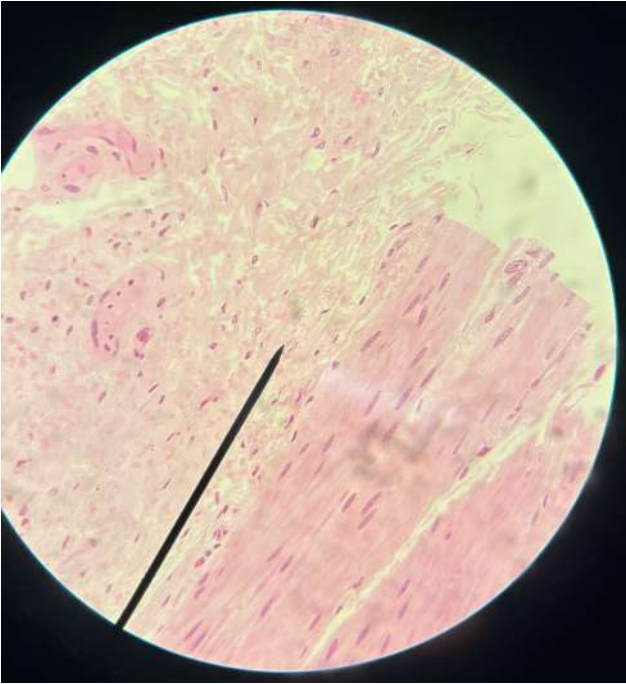


Blood vessels  
"Pancreas"  
"different size"

Identify

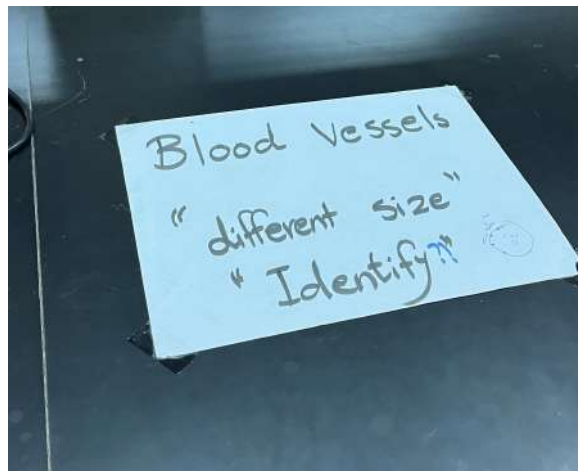
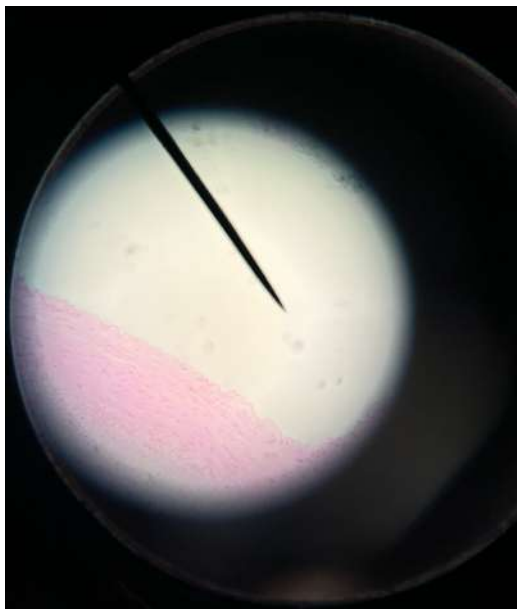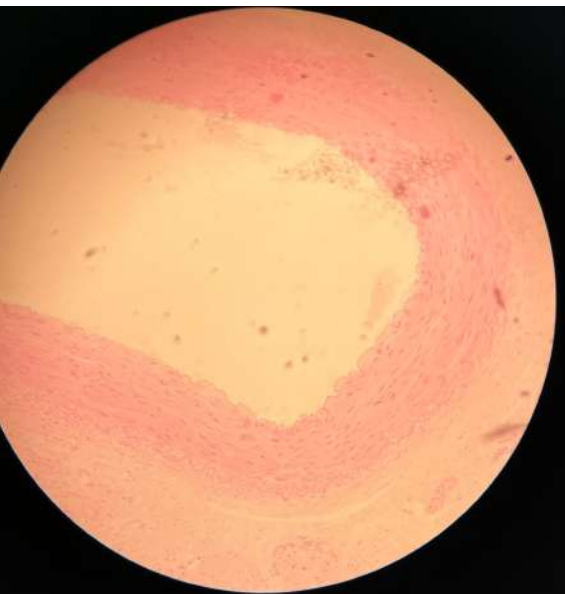
- arterioles
- venules
- capillaries

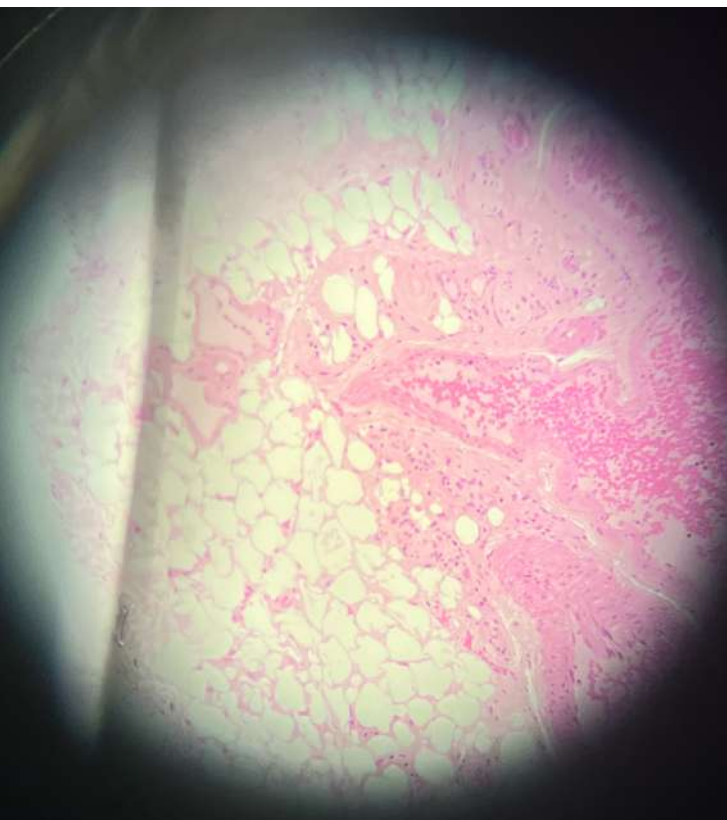C.S. & L.C.



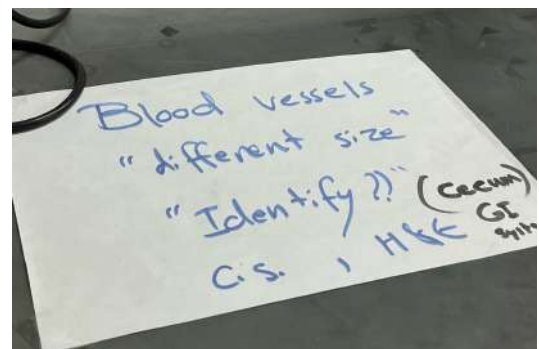
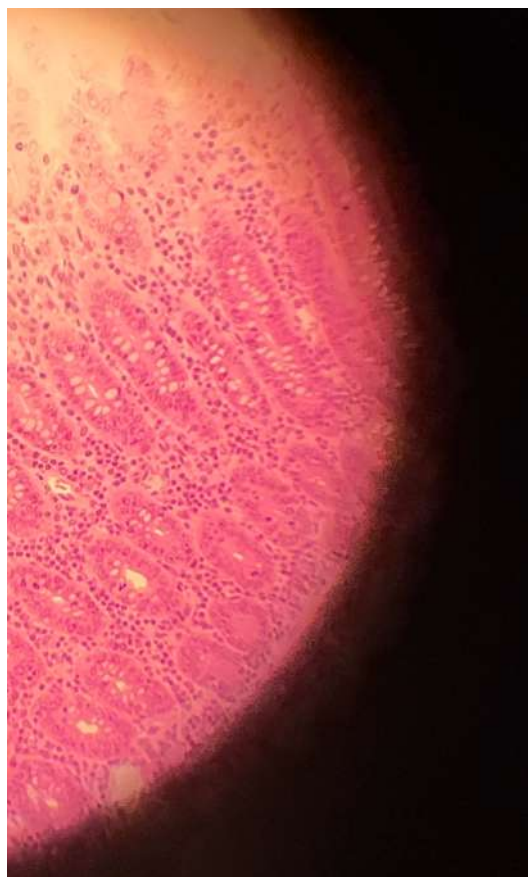
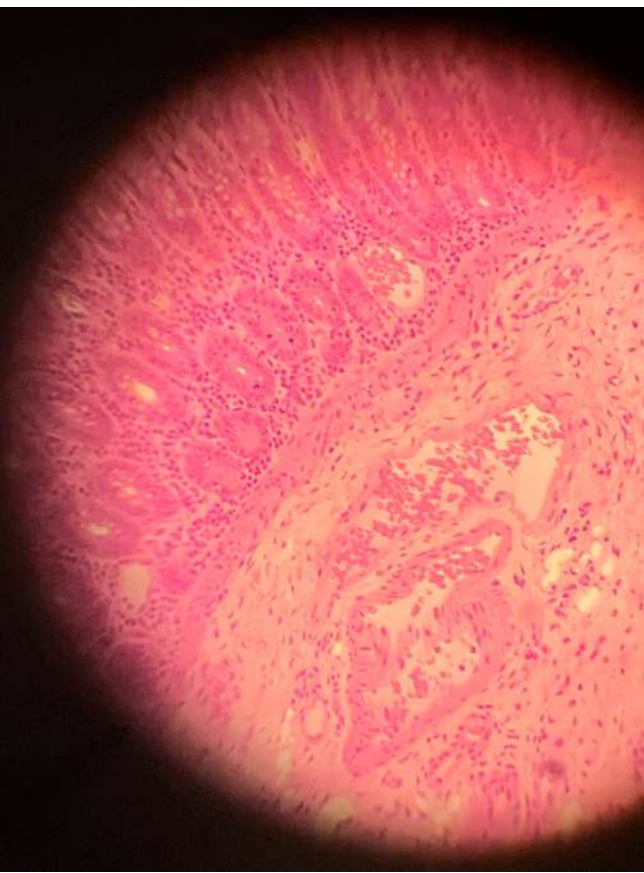
Blood vessels  
 "Esophagus"  
 "different size"  
 "Identify"  
 arterioles  
 venules  
 capillaries



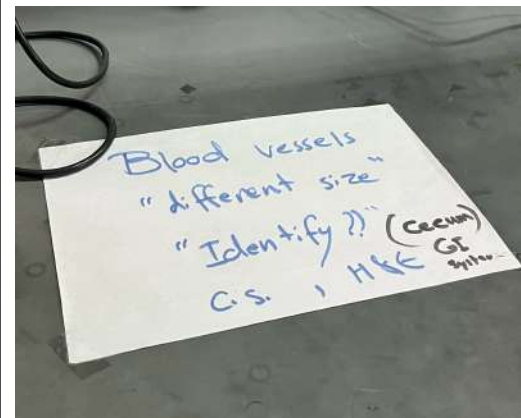




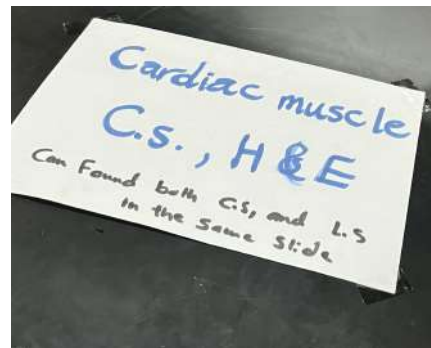
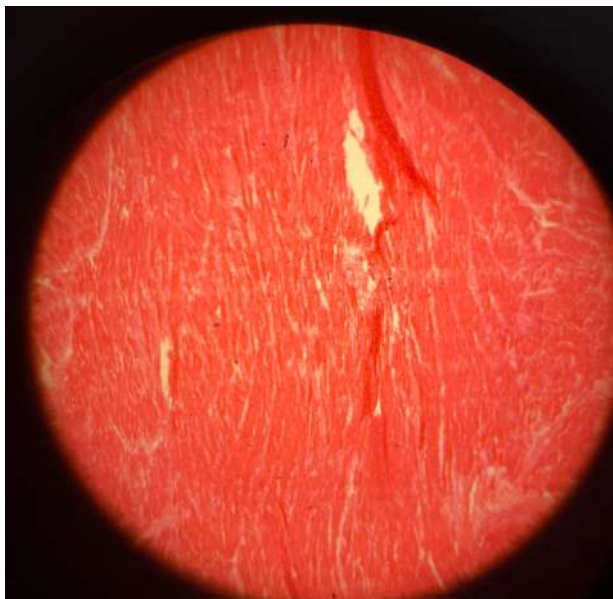
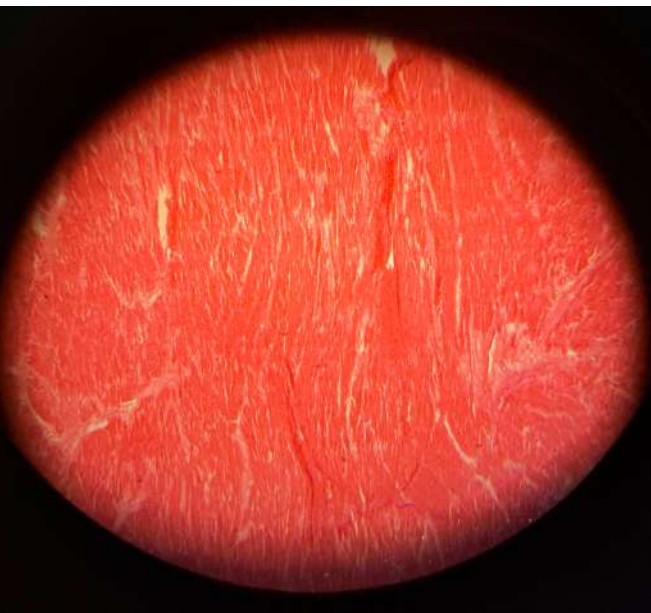Blood Vessels  
"different size"  
"Identify"  
"Lymph node"

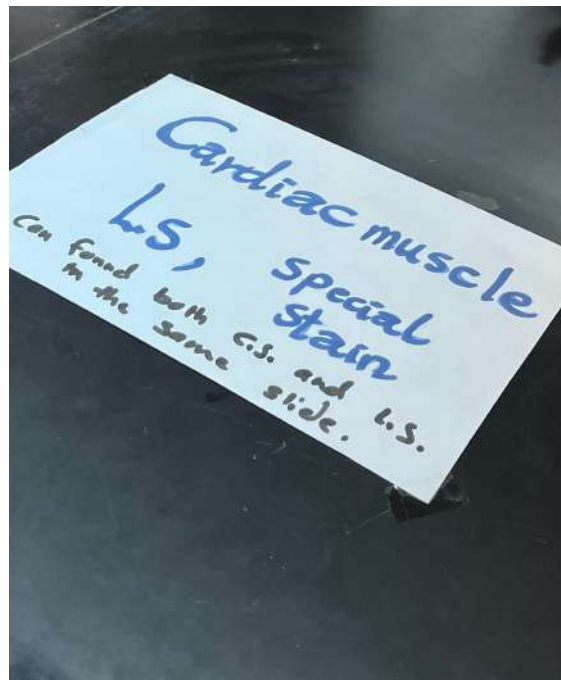
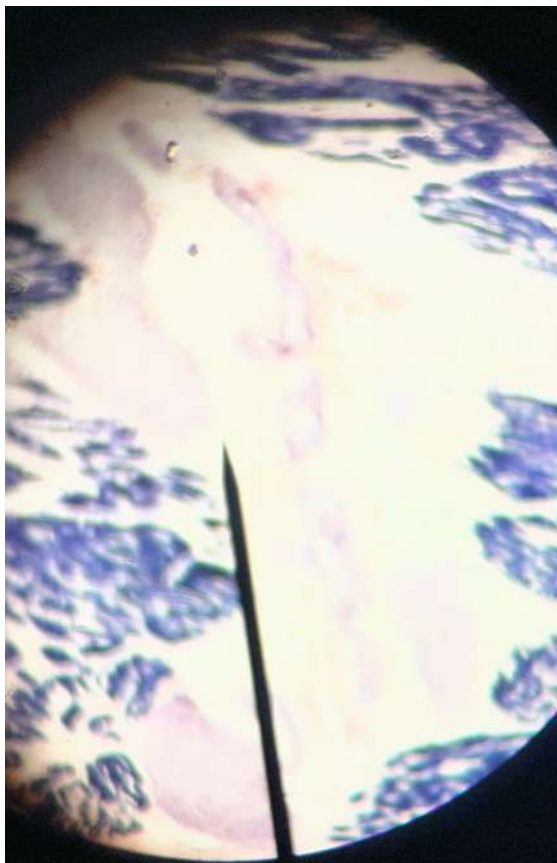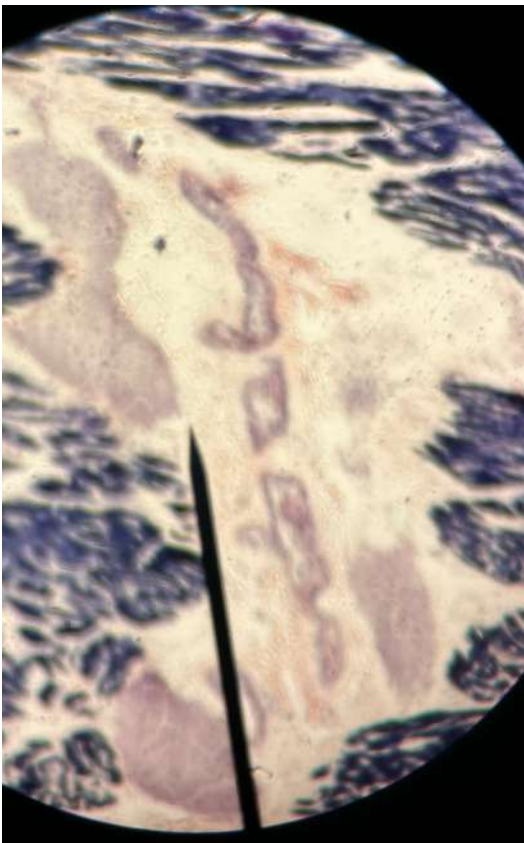



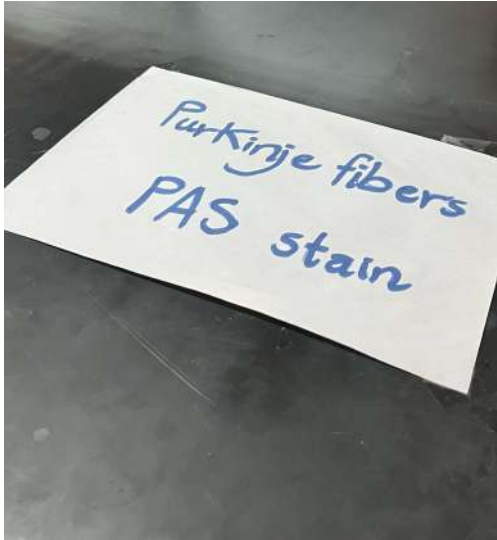
هون نادينا دكتور همام وسالناه وين  
فحركلنا العينه **blood vessels**  
بهاد الشكل

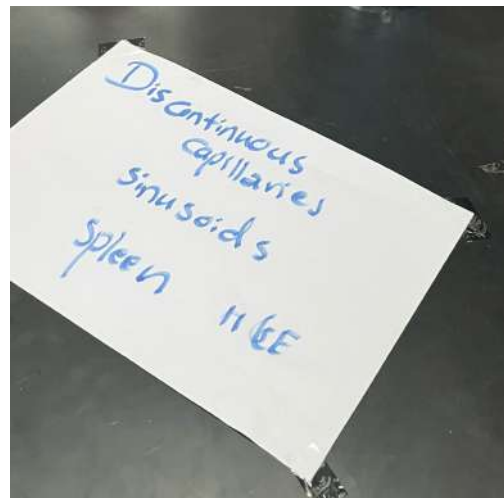
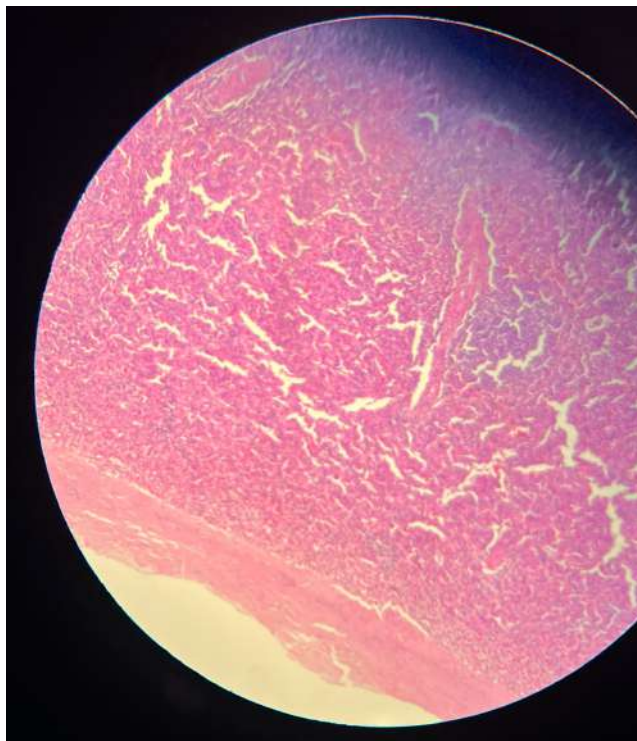
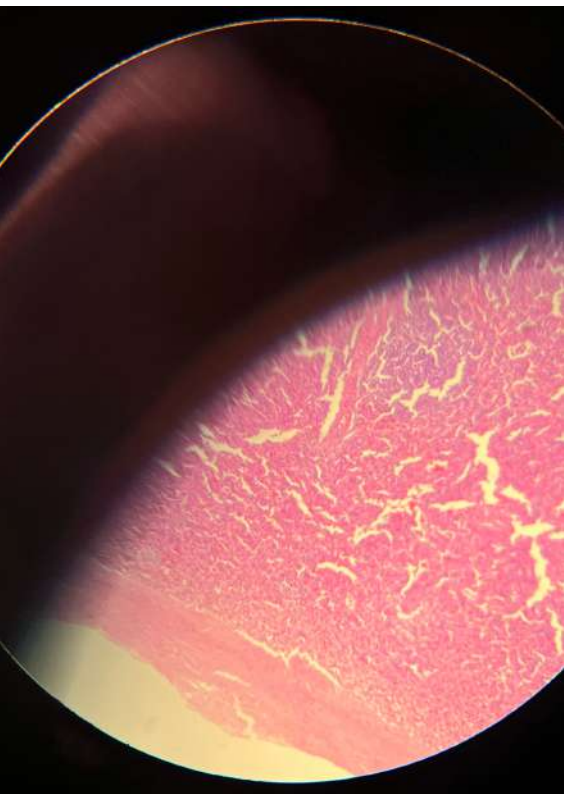



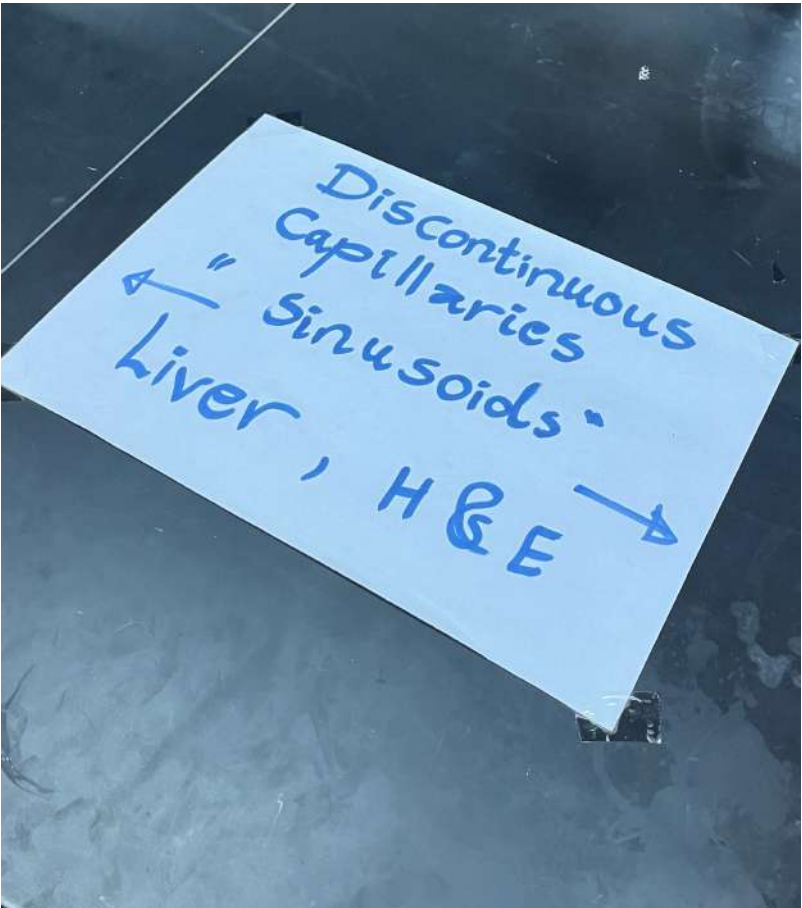
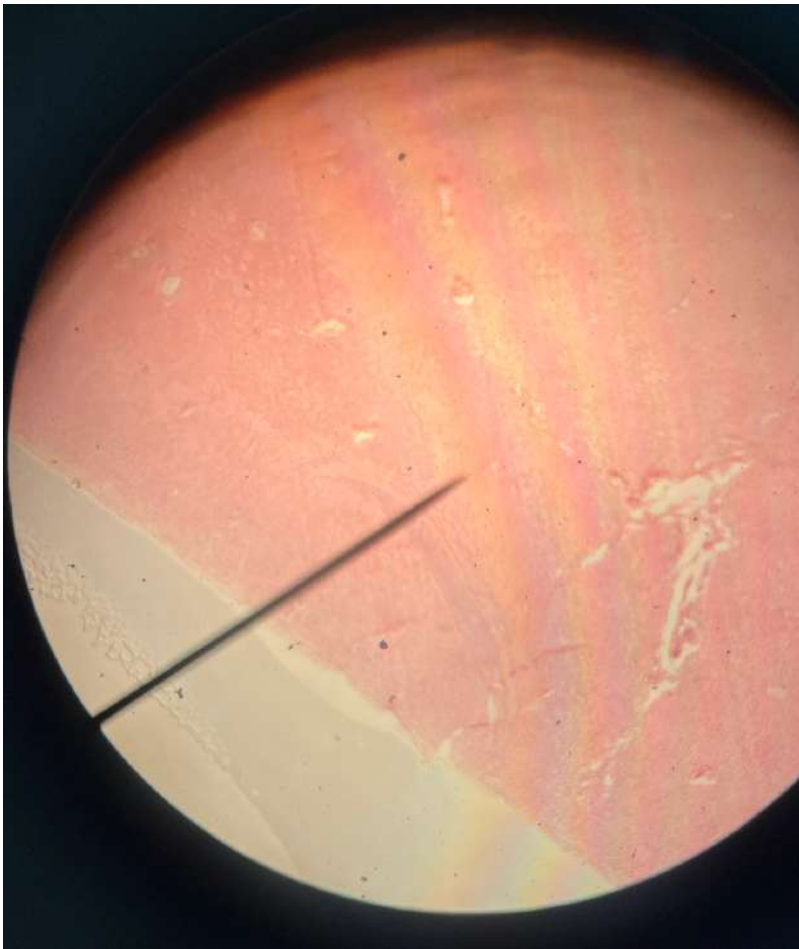


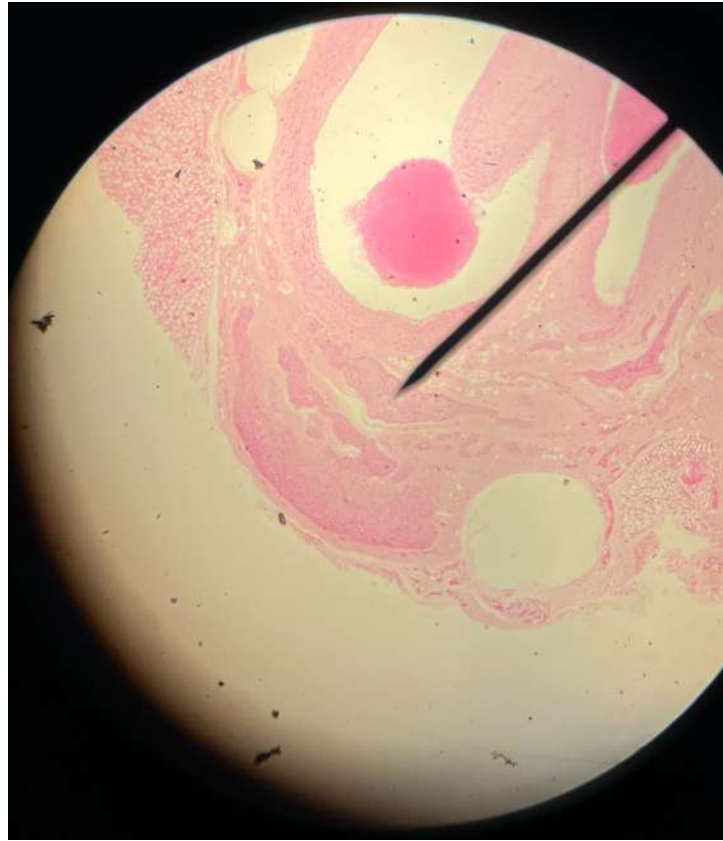
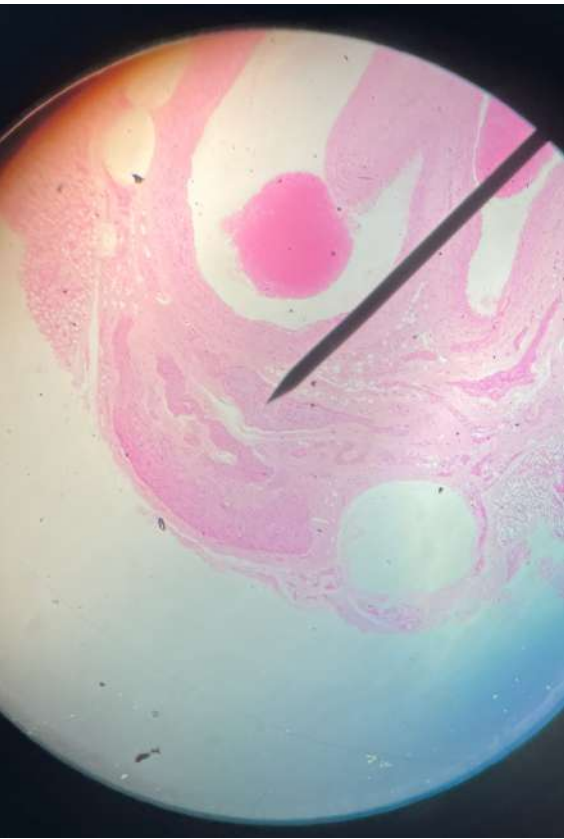




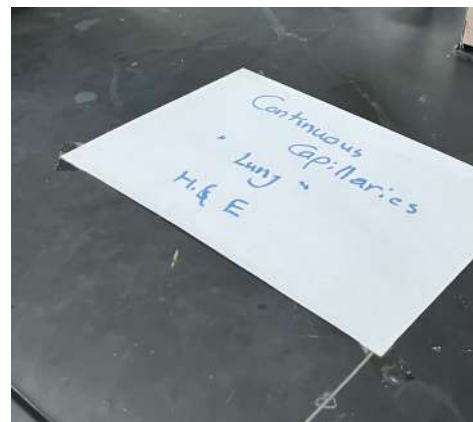
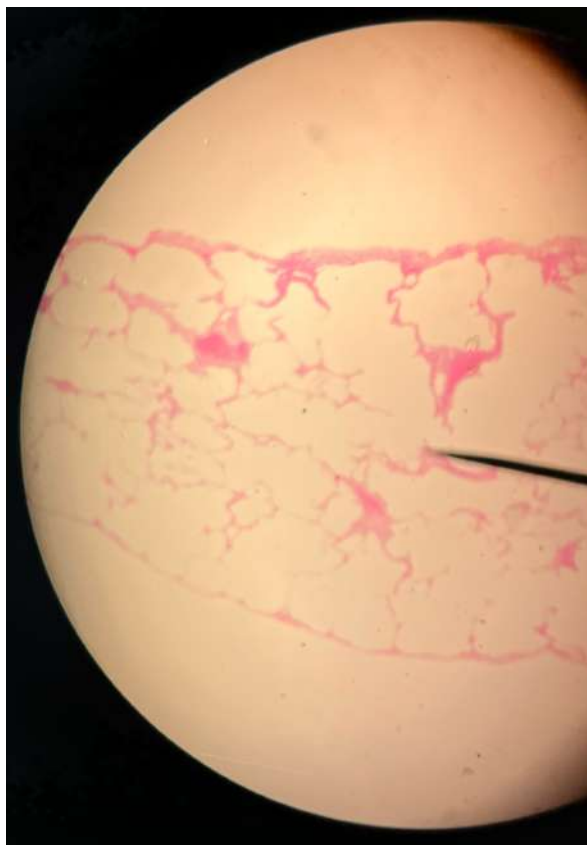
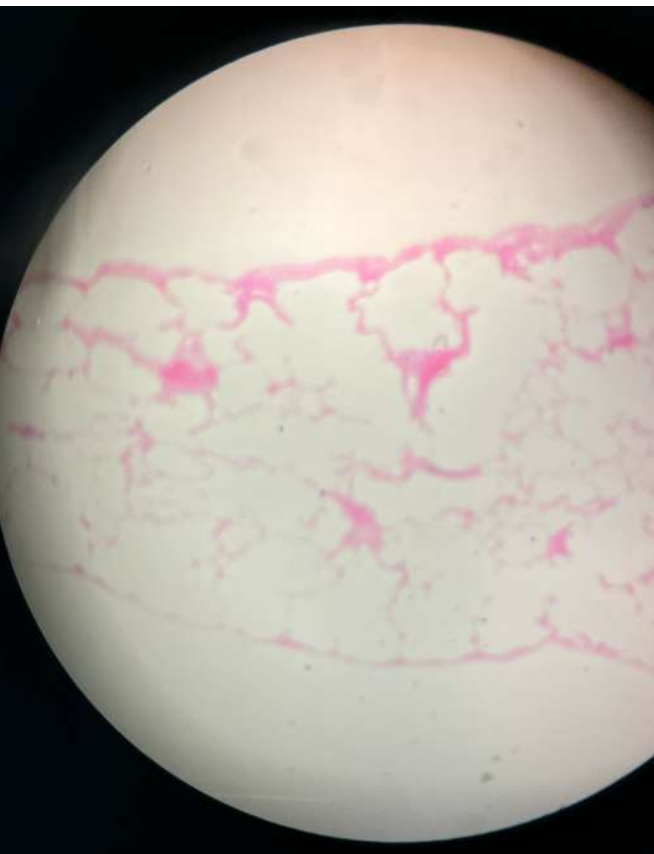


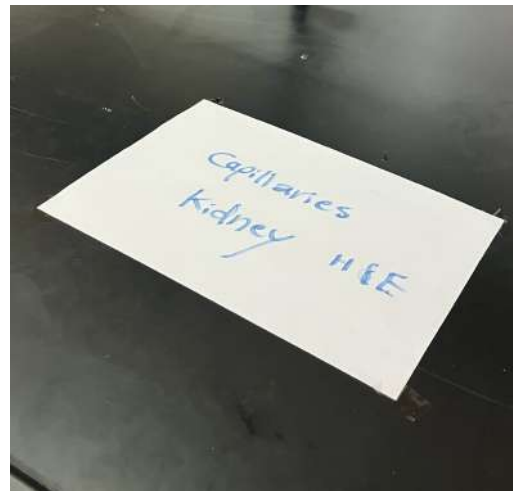
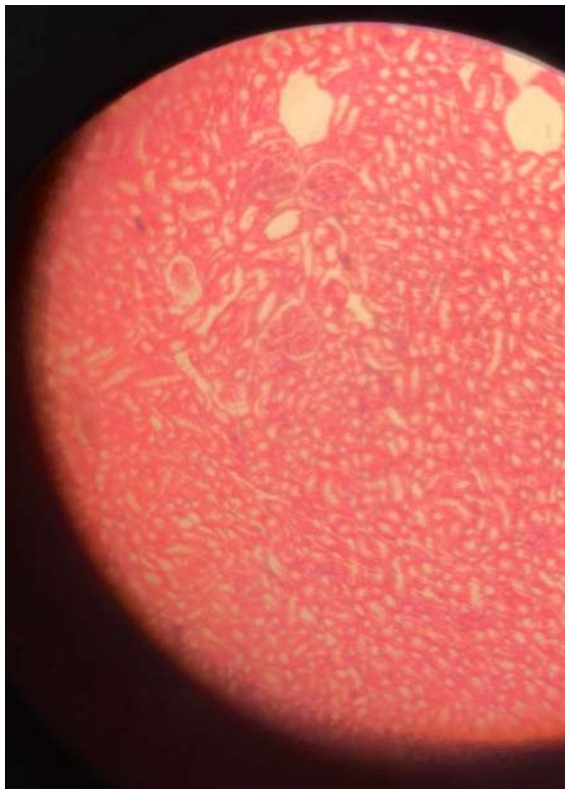
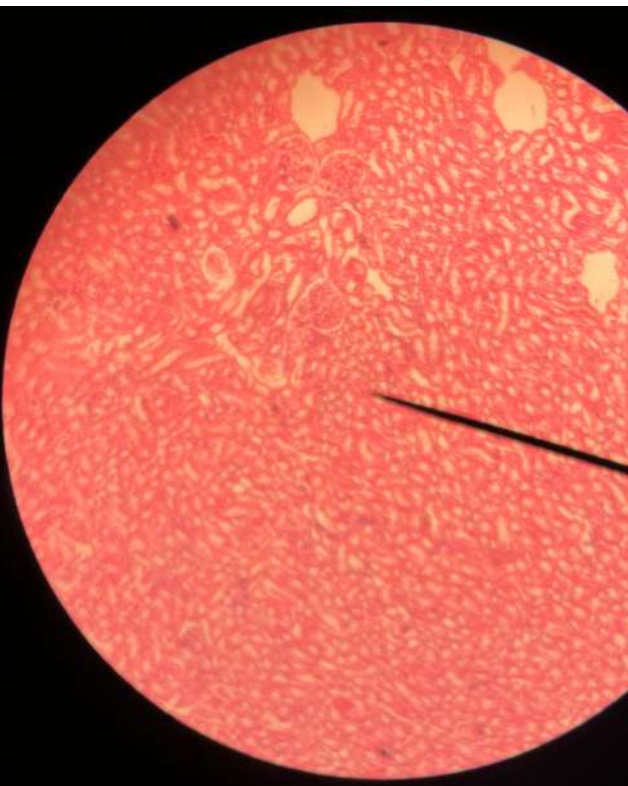






"Neurovascular  
Bundle"  
C.S. 1 H&E

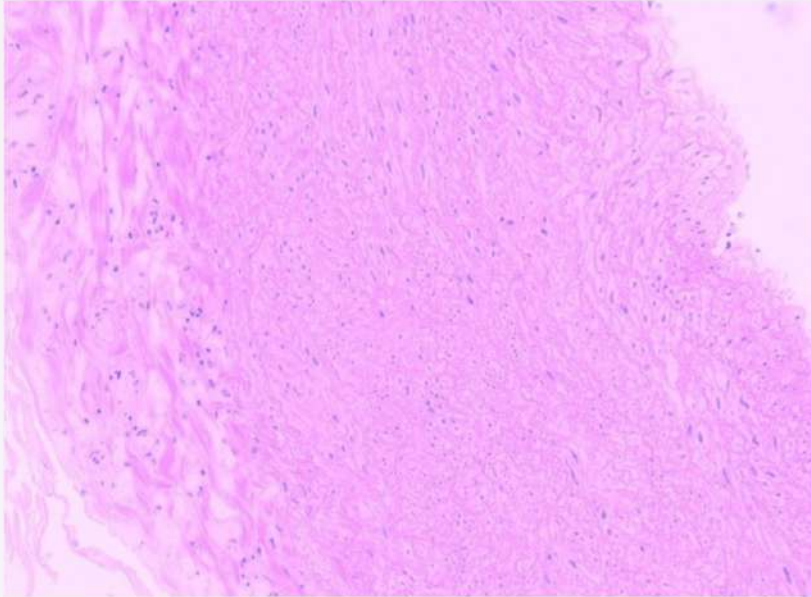






4

Identify this structure \* (1 Point)



- A) Aorta
- B) Radial artery
- C) Inferior vena cava
- D) Ulnar vein

**Answer: A**