

Clinical Pediatric Cardiology

CVS- 3rd year

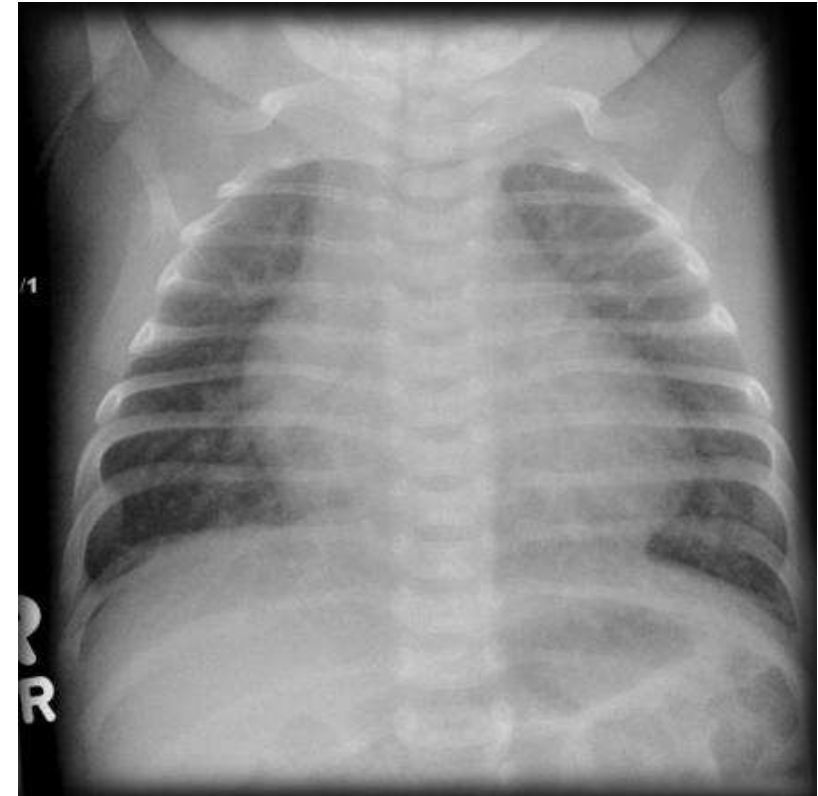
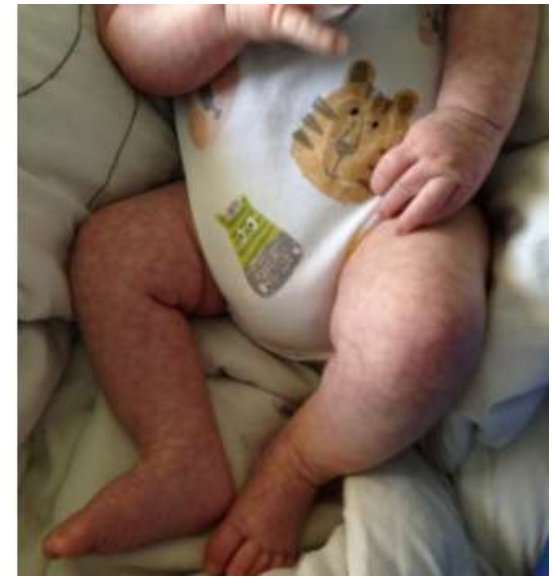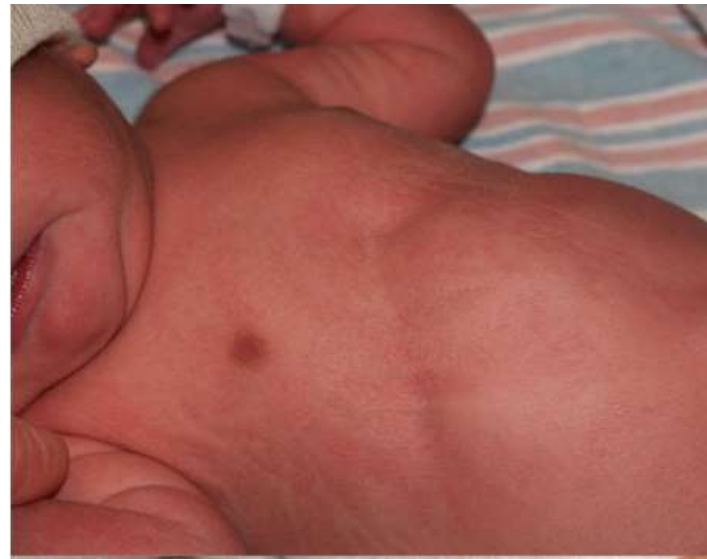Prof. Iyad AL-Ammouri
Pediatric Cardiology

Introduction

- Pediatric cardiac disease are largely congenital defects
- Some acquired heart disease may happen in Pediatrics
- Will present 4 common cases of children with heart disease
- In each case we will focus on:
 - Embryologic consideration leading to the anatomic defect
 - Physiology and hemodynamics leading to the clinical picture

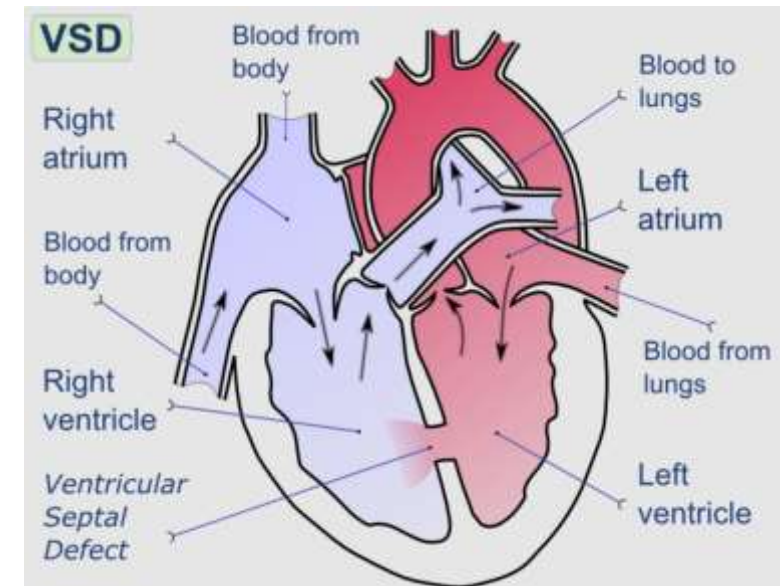
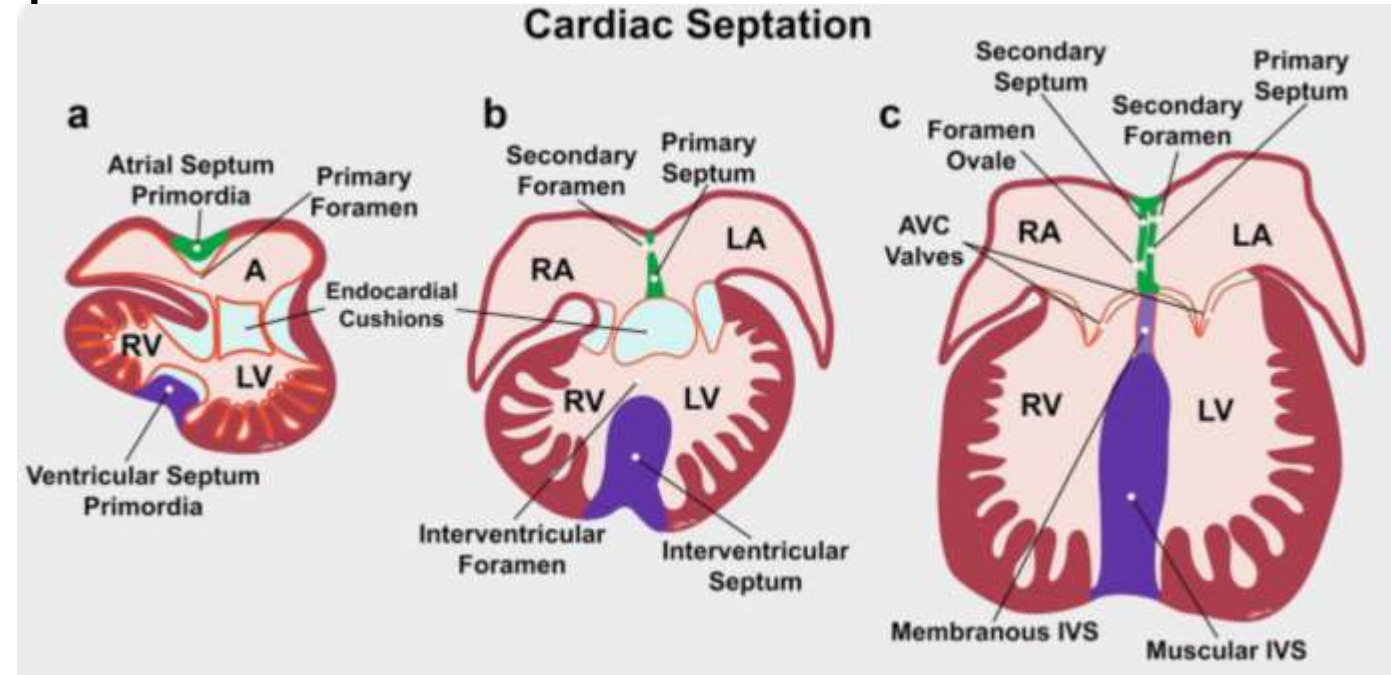
Case 1

- Two month old infant who has:
 - Rapid breathing (tachypnea)
 - Difficulty of feeding
 - Not gaining weight appropriately
- Examination:
 - Signs of respiratory distress
 - Rapid heart rate (tachycardia)
 - Weak pulses, skin hypo-perfusion
 - Systolic heart murmur
- Chest X ray showed:
 - Enlarged heart (cardiomegaly)
 - Congested lungs

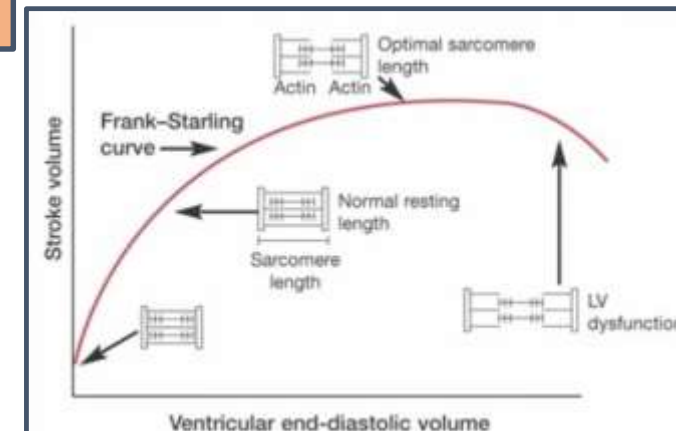
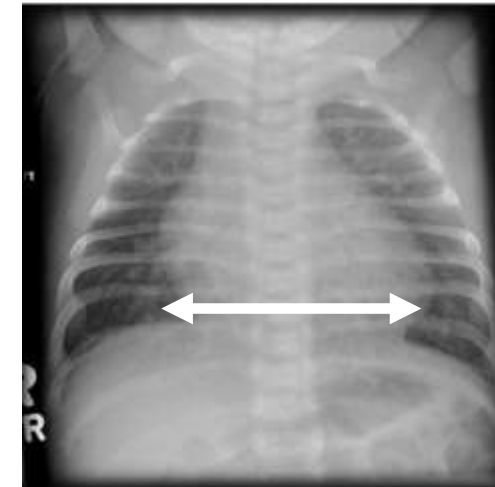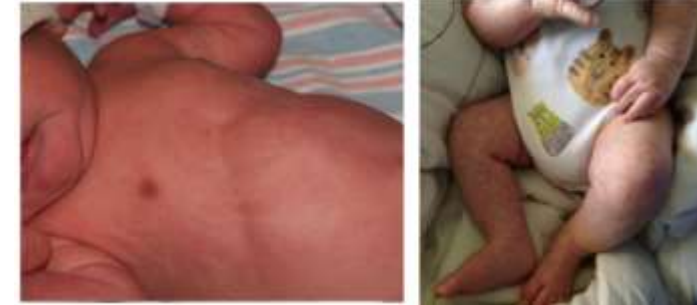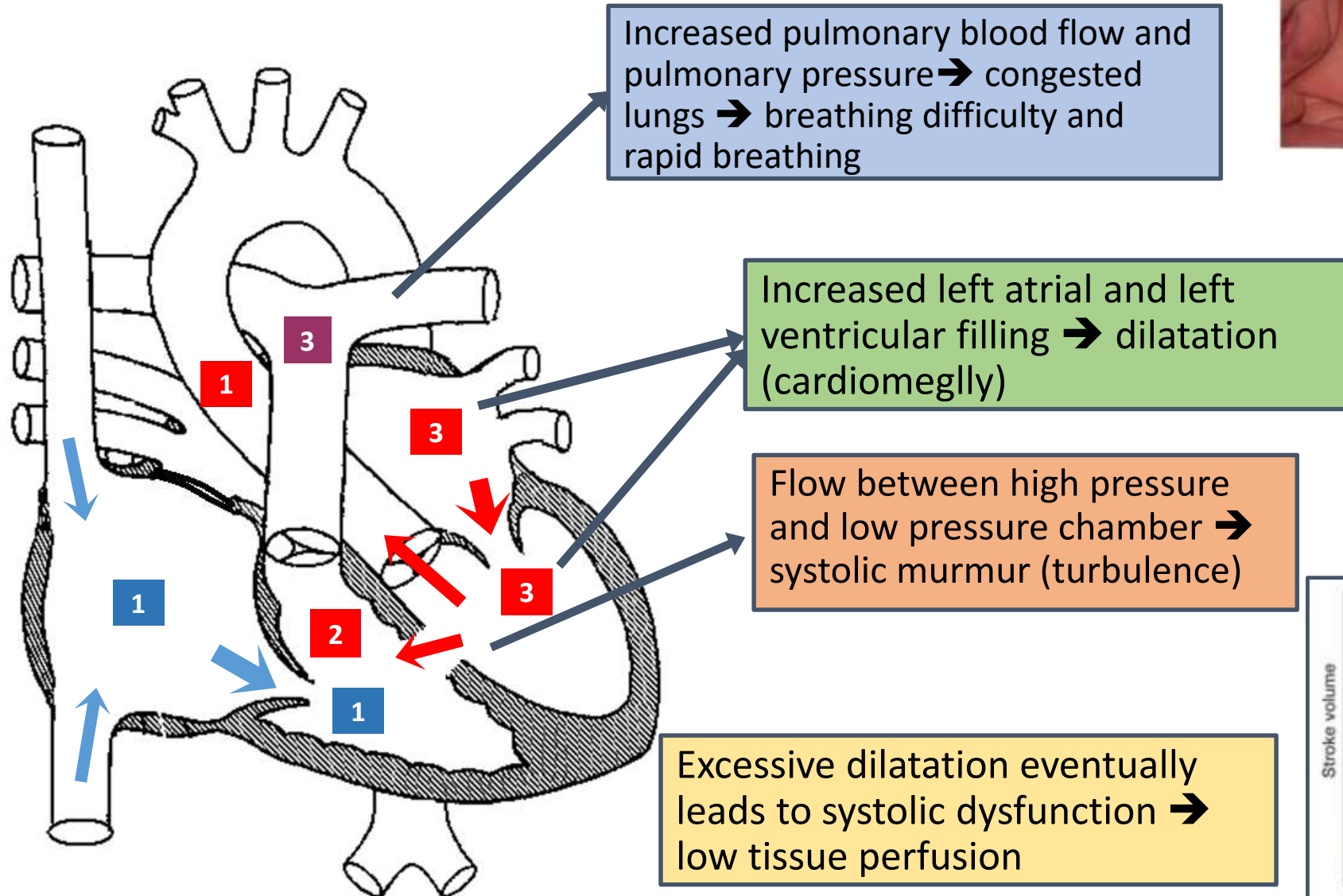


Diagnosis: Ventricular septal defect

- Embryologic defect: failure of ventricular septation
 - Septation starts after cardiac looping
 - Interventricular foramen
 - Ventricular septum is composed of muscular part, membranous part, and endocardial cushionings
- Anatomical result:
 - Defect between the ventricles
 - Types (muscular, membranous, inlet/canal types..etc)

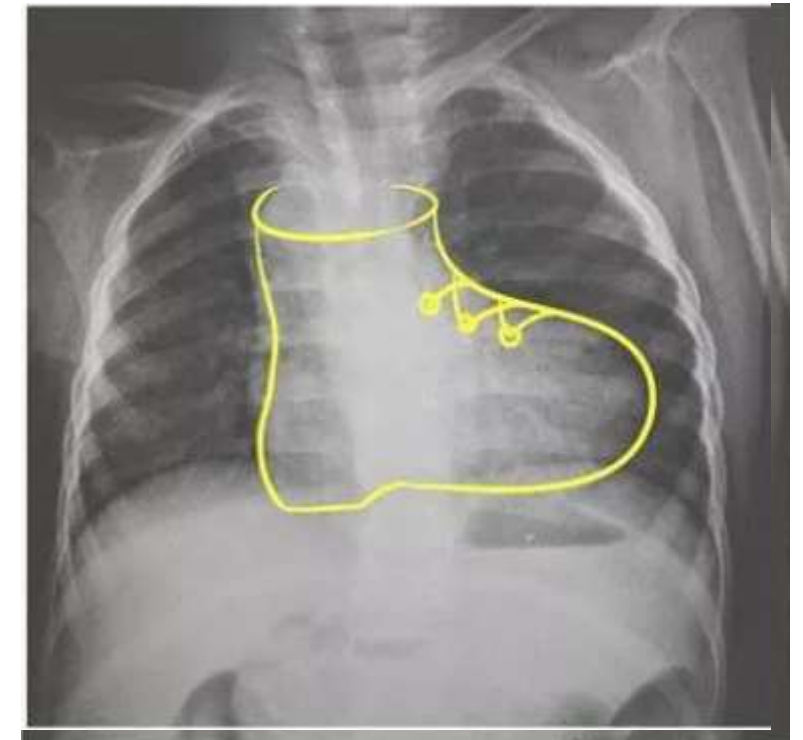
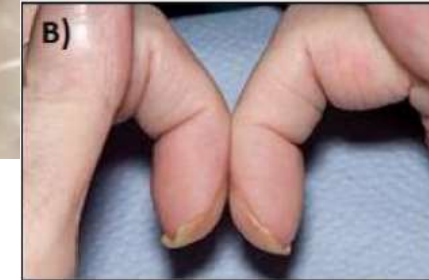
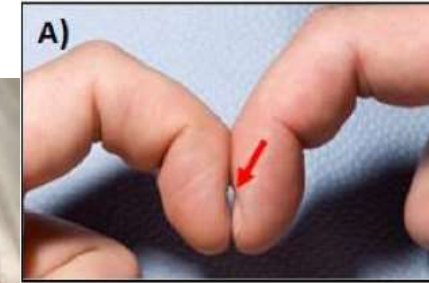
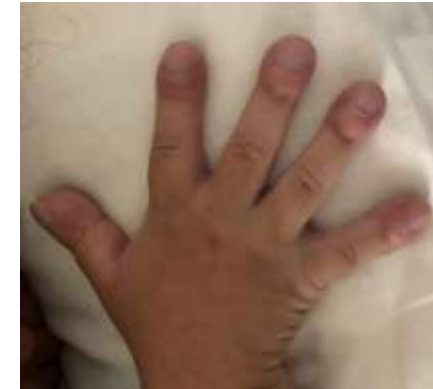Physiology of VSD → clinical picture



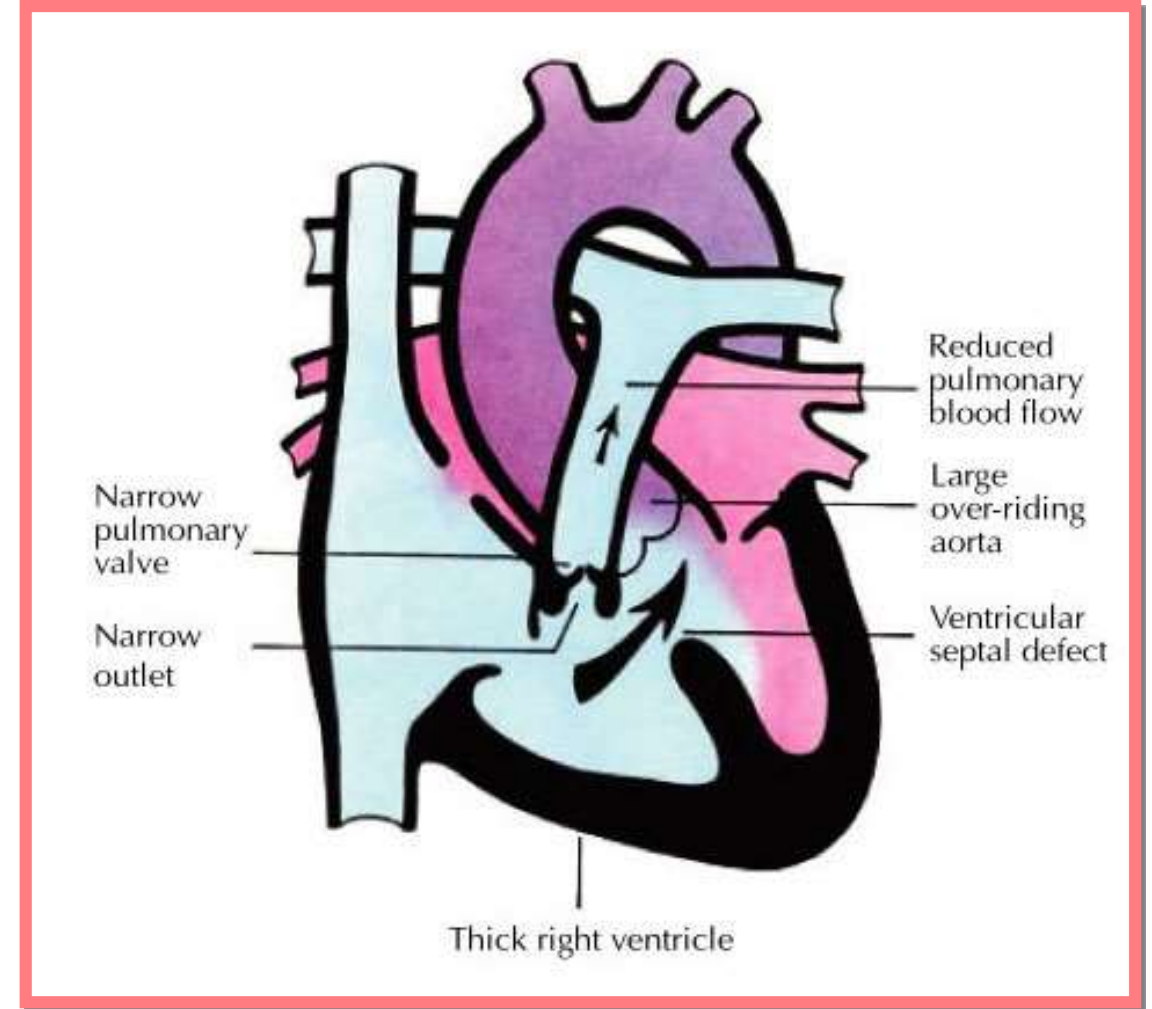
Case 2

- Two year old child who has:
 - Cyanosis that increases when he plays and cries
 - Occasional squatting
 - Generally growing well with good weight
- Examination:
 - Oxygen saturation of 80%
 - Plethoric face (opposite of pale)
 - Good pulse and perfusion
 - Systolic heart murmur
 - Finger clubbing
- Chest X ray showed:
 - Heart not enlarged, but boot shaped, with dark lungs
- Hemoglobin level was 17 gm/dL (polycythemia)

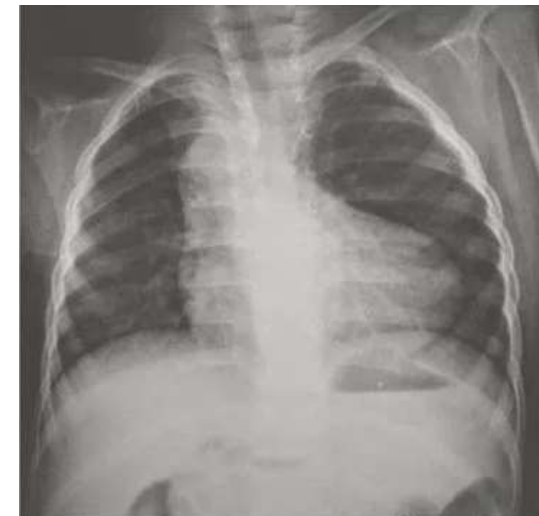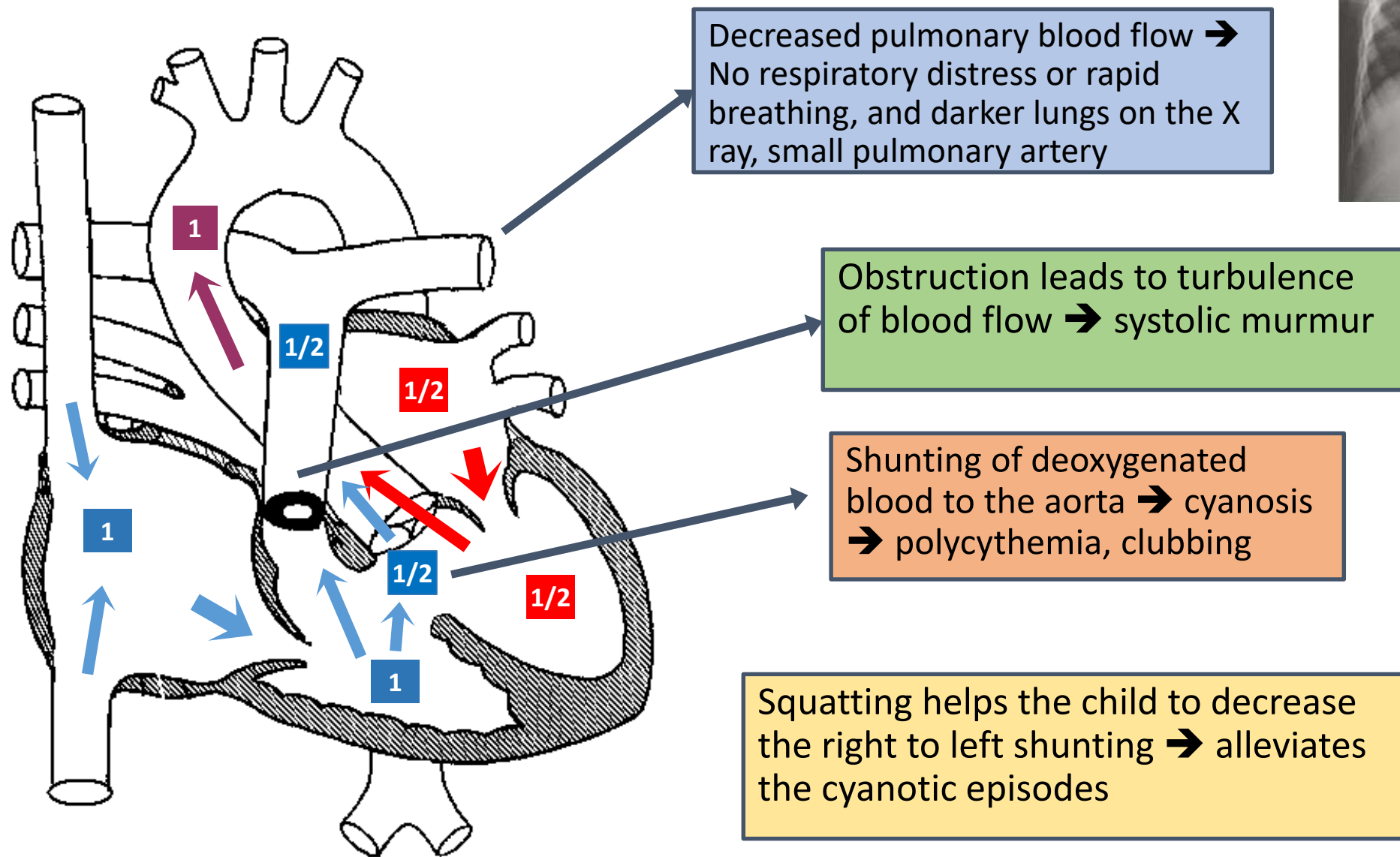


Diagnosis: Tetralogy of Fallot

- Embryologic defect: anterior and rightward deviation of the “conal” septum
- Anatomical result:
 - Failure of the muscular ventricular septum to fuse with conal septum (VSD)
 - Sub-pulmonary and pulmonary stenosis
 - Aorta overrides the septum
 - Secondary right ventricular hypertrophy

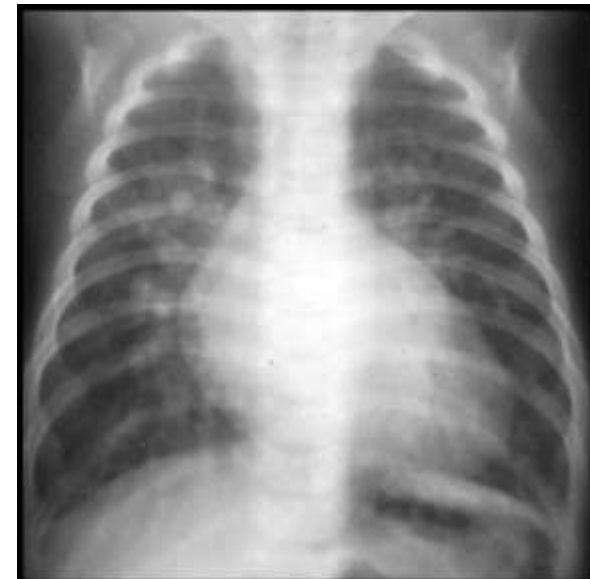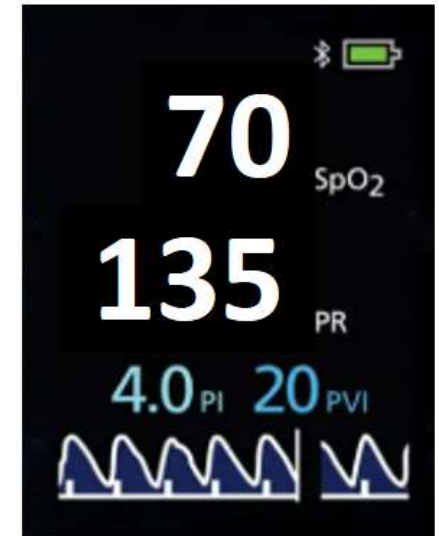

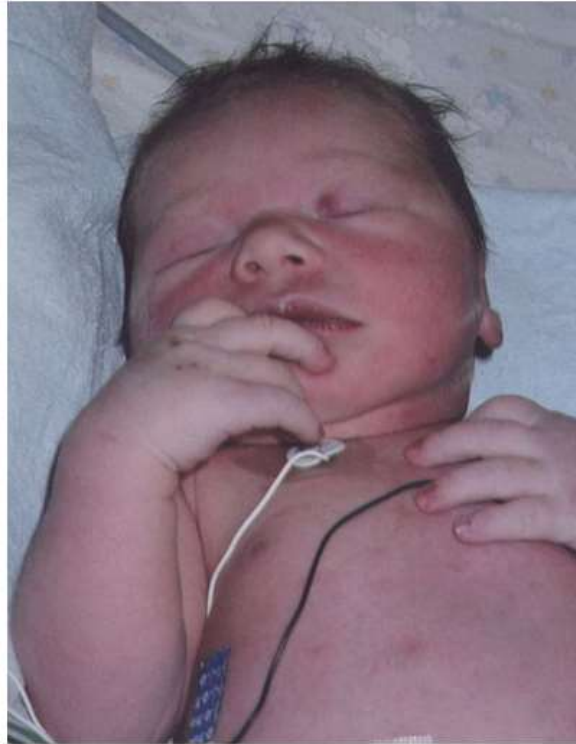
Physiology of TOF → clinical picture



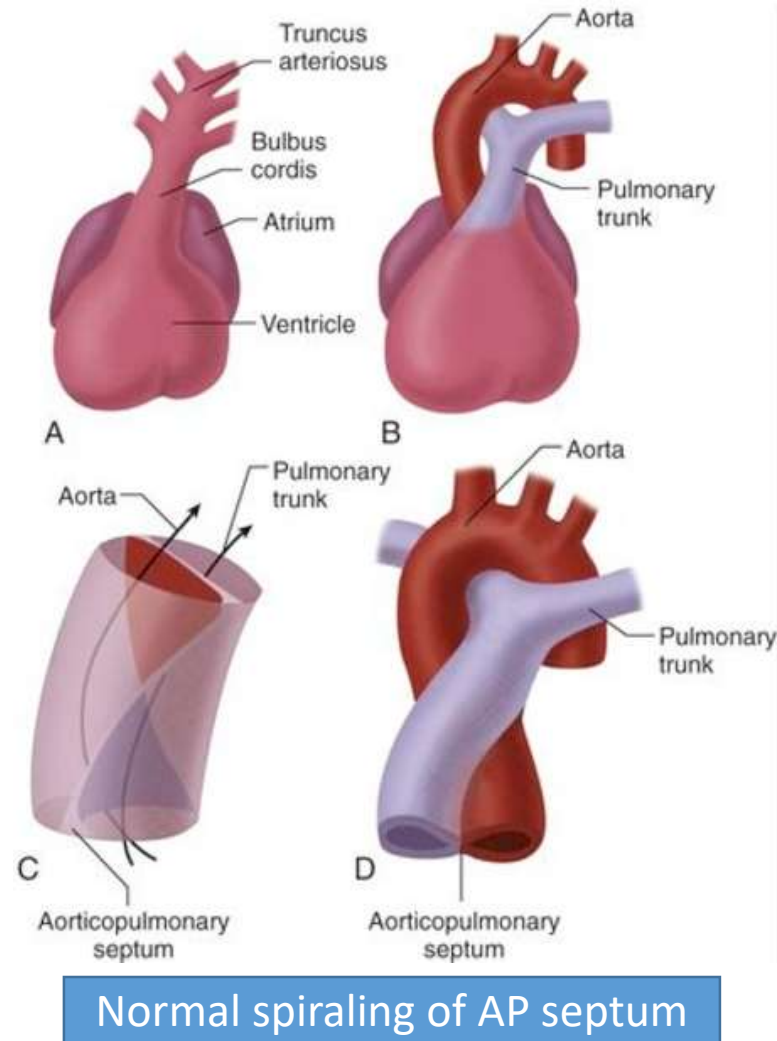
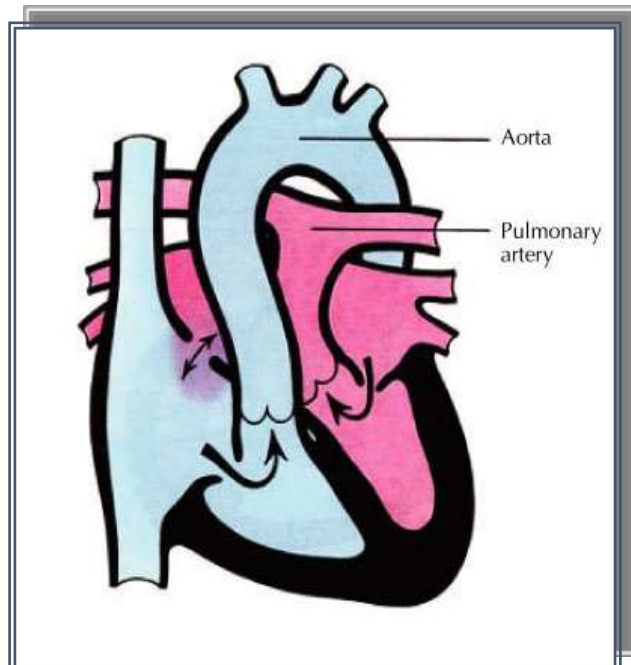
Case 3

- One day old newborn who has:
 - Severe cyanosis
 - No respiratory distress
- Examination:
 - Oxygen saturation of 70%
 - Good pulse and perfusion
 - No murmur
- Chest X ray showed:
 - Egg shaped heart, narrow mediastinum
- Cyanosis is getting worse with time

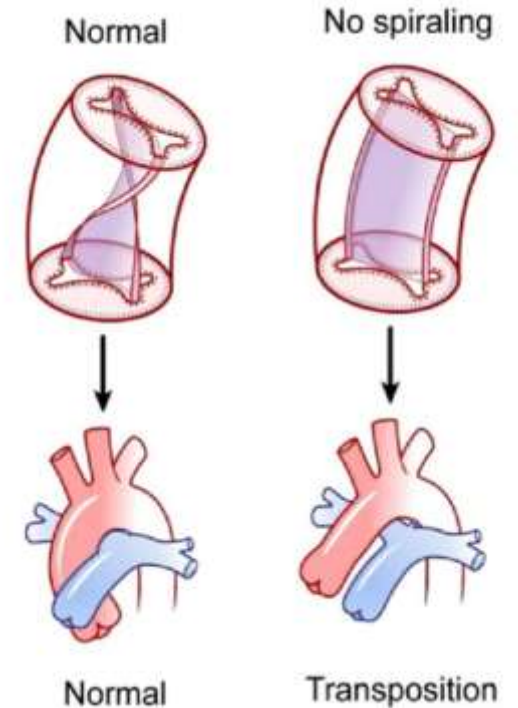


Diagnosis: Transposition of the Great Arteries

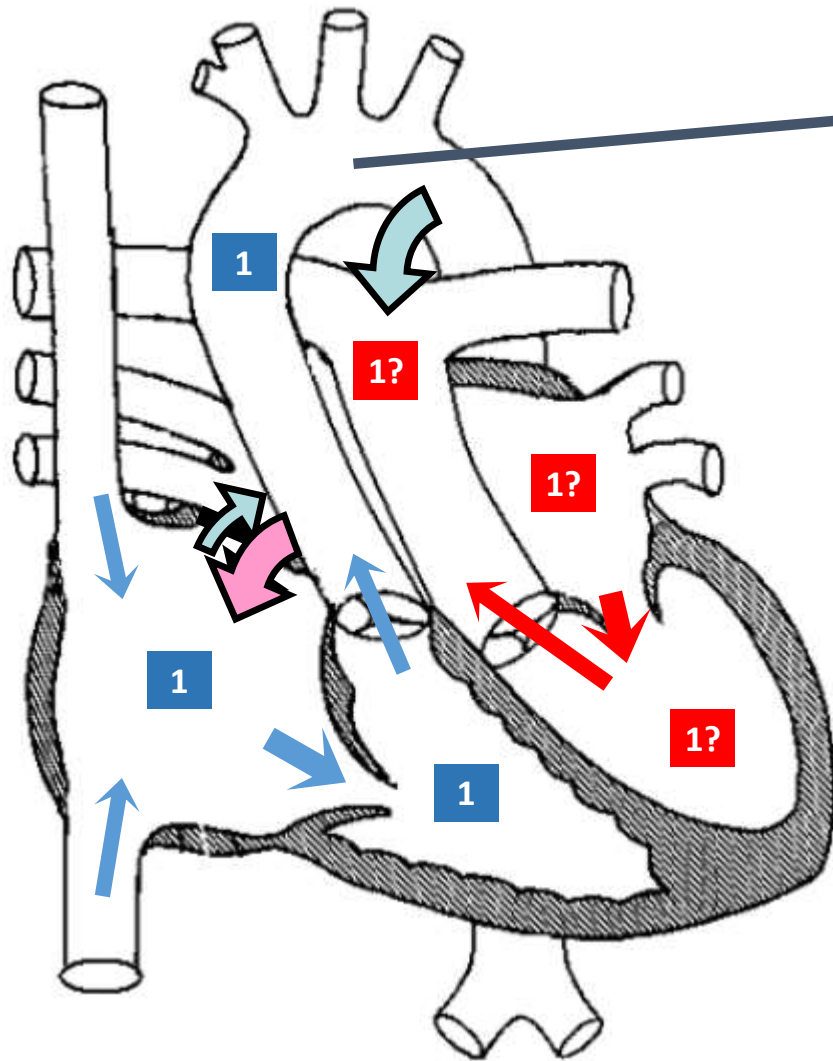
- Embryologic defect: Abnormal septation of the truncus arteriosus (failure of spiral septation)
- Anatomical result:
 - Aorta arises from the right ventricle
 - Pulmonary artery arises from the left ventricle



Normal vs abnormal spiraling



Physiology of TGA → clinical picture

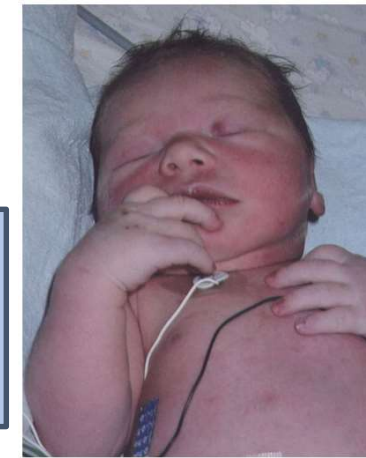


The two circulations are parallel, systemic and pulmonary blood re-circulate, resulting in severe cyanosis

For survival, atrial level mixing is mandatory (bidirectional flow)

Allows for some oxygenated blood to body, and deoxygenated blood to lung

Additional shunting via patent ductus arteriosus can also help the baby survive until surgical repair is done

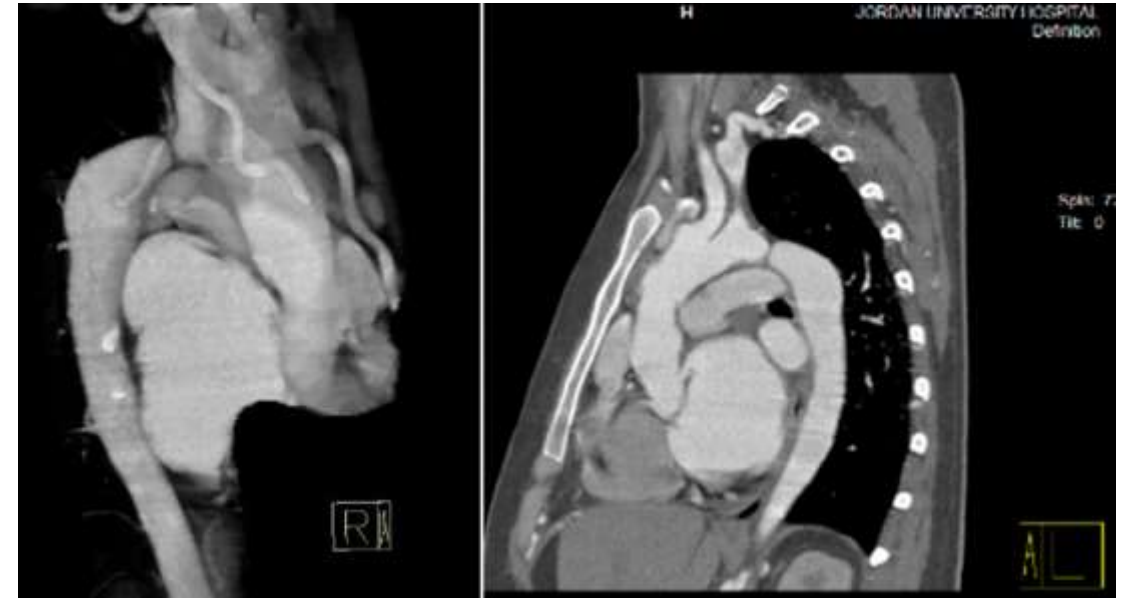
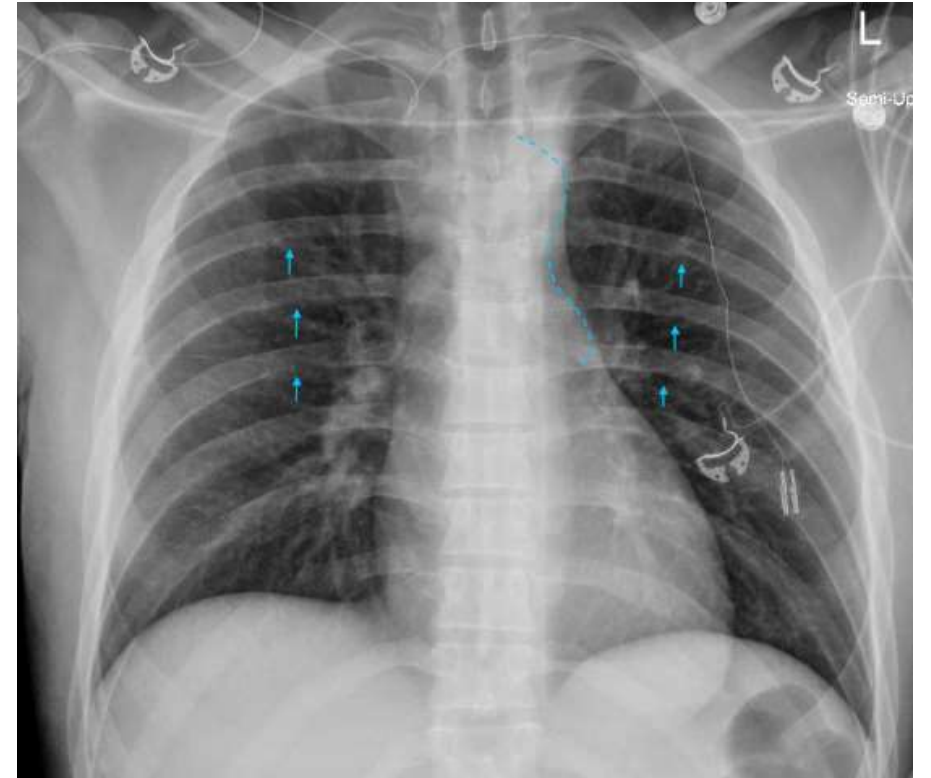


Emergency balloon septostomy can be life-saving

Prostaglandin infusion can be life-saving

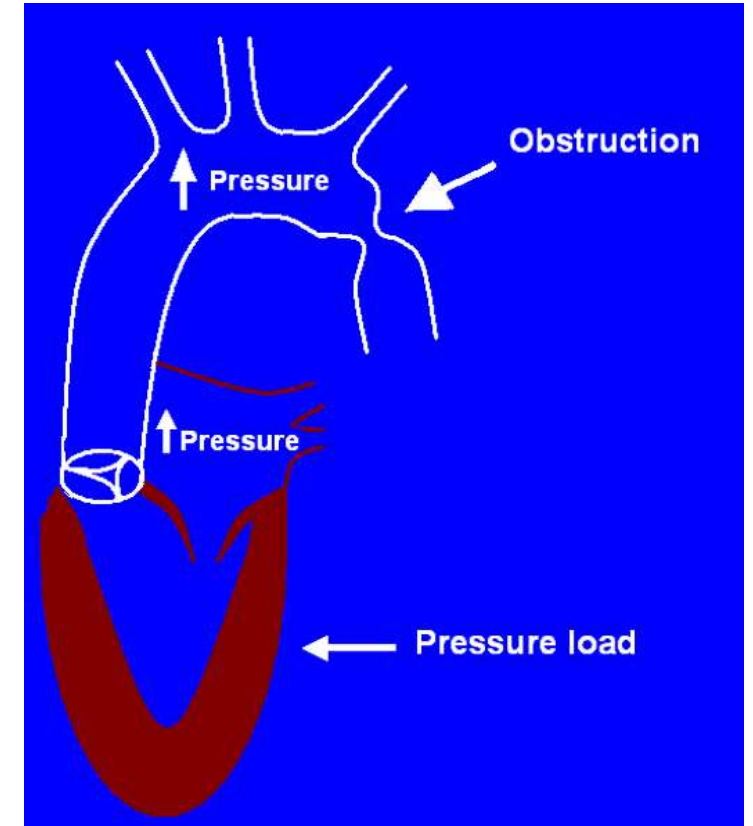
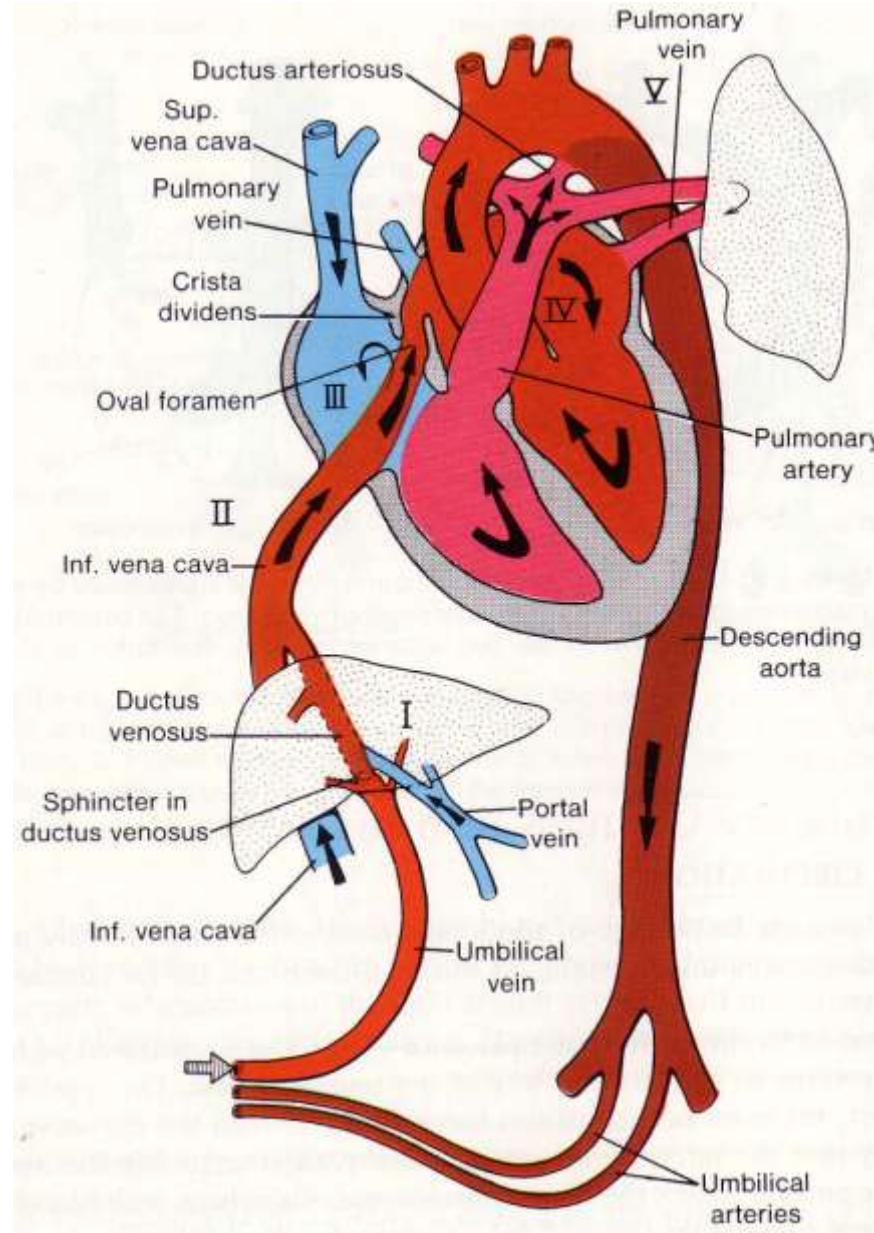
Case 4

- 12 year old child complains of headache, and occasional chest pain with exercise.
- He reports cramps of his leg when he walks for long distances.
- Examined by school nurse, and was found to have blood pressure of 160/100
- Other findings on examination:
 - Good radial pulse, but poor femoral pulse
 - BP in the leg measured 110/70
 - Cardiac palpation showed strong apical impulse (apical heave)
 - ECG showed left ventricular hypertrophy
- Chest X ray showed:
 - Notched ribs

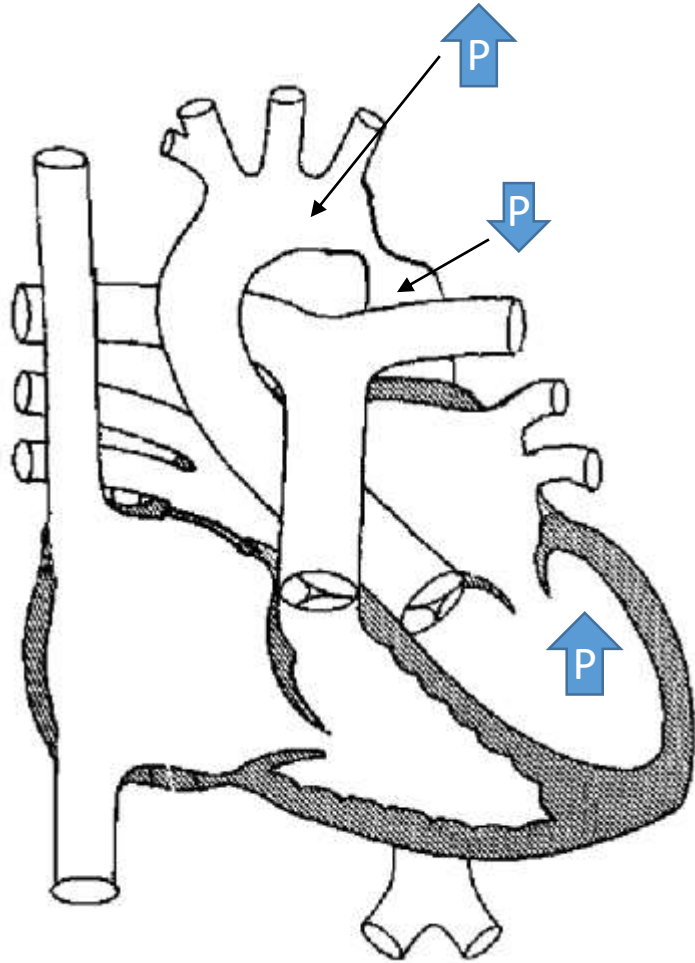


Diagnosis: Coarctation of Aorta

- Embryologic defect: decreased flow across the distal aortic arch during fetal life (most accepted theory)
- Anatomical result:
 - Narrowing of the distal arch (Isthmus), usually distal to the left subclavian artery



Physiology of TGA → clinical picture

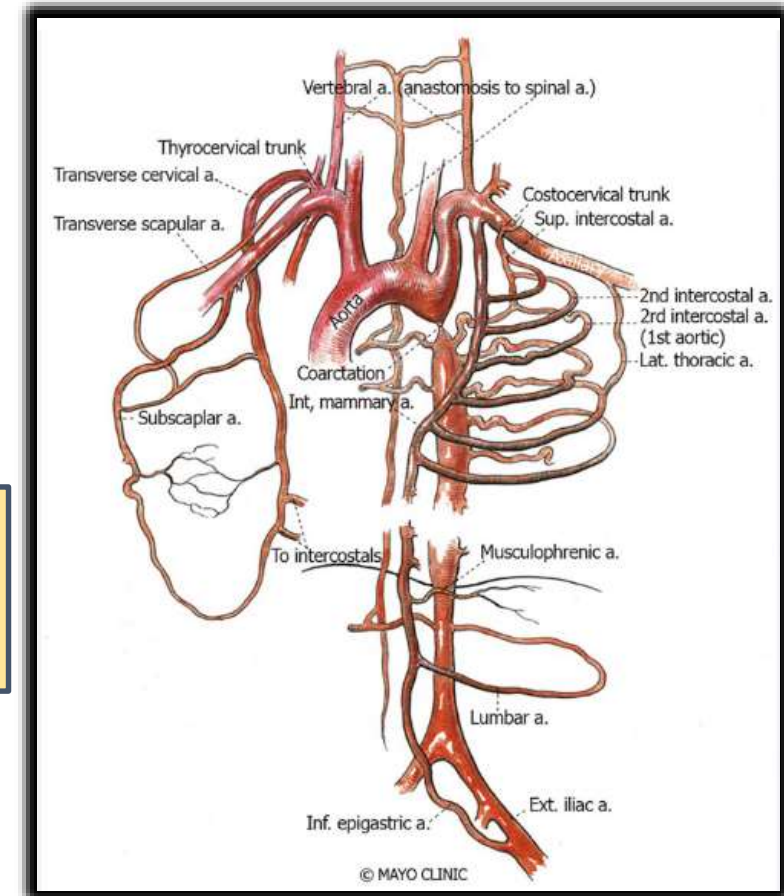
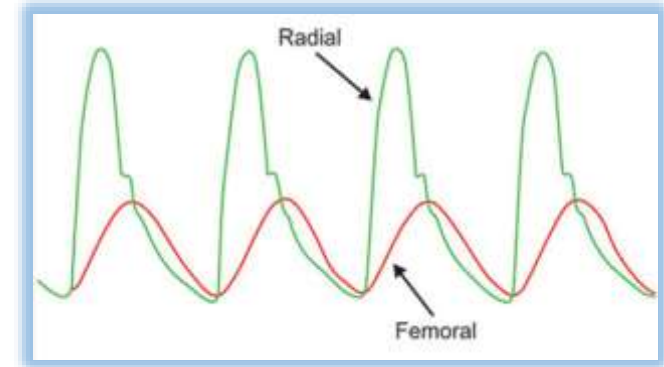


Hypertension in upper limbs, with normal or low pressure in lower limb

Left ventricle becomes hypertrophic to be able to handle the high pressure → increased myocardial oxygen demand → susceptible for exertional ischemia and exertional angina

Collateral circulation develops slowly, involving the intercostal arteries → ribs are notched

Lower limb blood supply may get compromised with exercise leading to muscle pain and cramping (claudications)



END