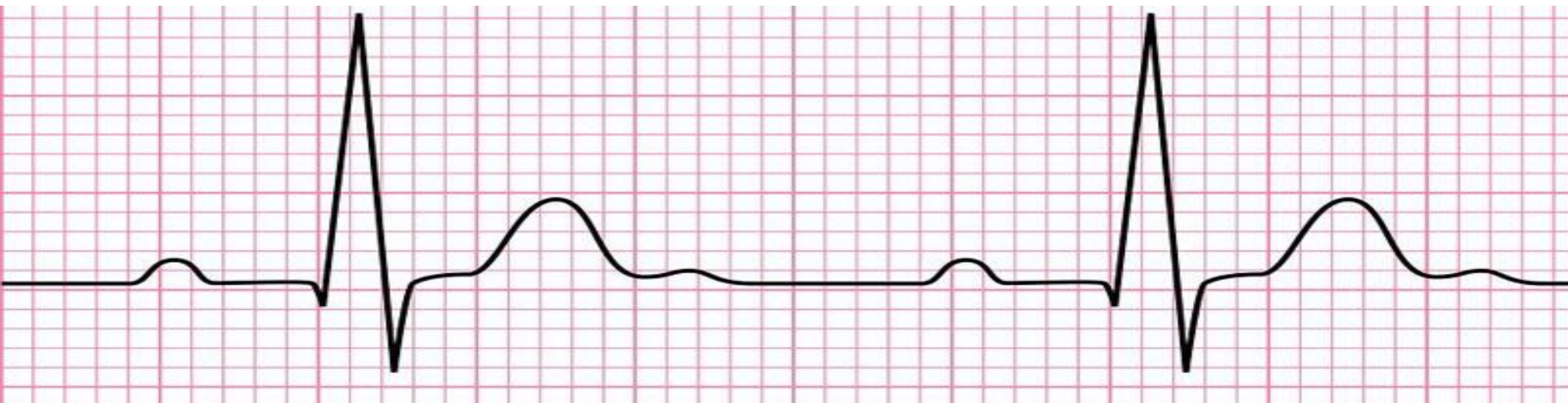


# THE ECG

---

Dr. Tamara Alqudah



# The electrocardiogram (ECG)

- The ECG is a special graph that represents the electrical activity of the heart from one instant to the next.
- It provides a time-voltage chart of the heartbeat.
- When the cardiac impulse passes through the heart, electrical current also spreads into the adjacent tissues all the way to the surface of the body.
- The device used to obtain and display the ECG is called the electrocardiograph, or ECG machine.
- It records cardiac electrical currents (voltages or potentials) by means of conductive electrodes selectively positioned on the surface of the body.
- A simple & non-invasive diagnostic test. It is a key component of clinical diagnosis and management in both inpatient and outpatient settings.

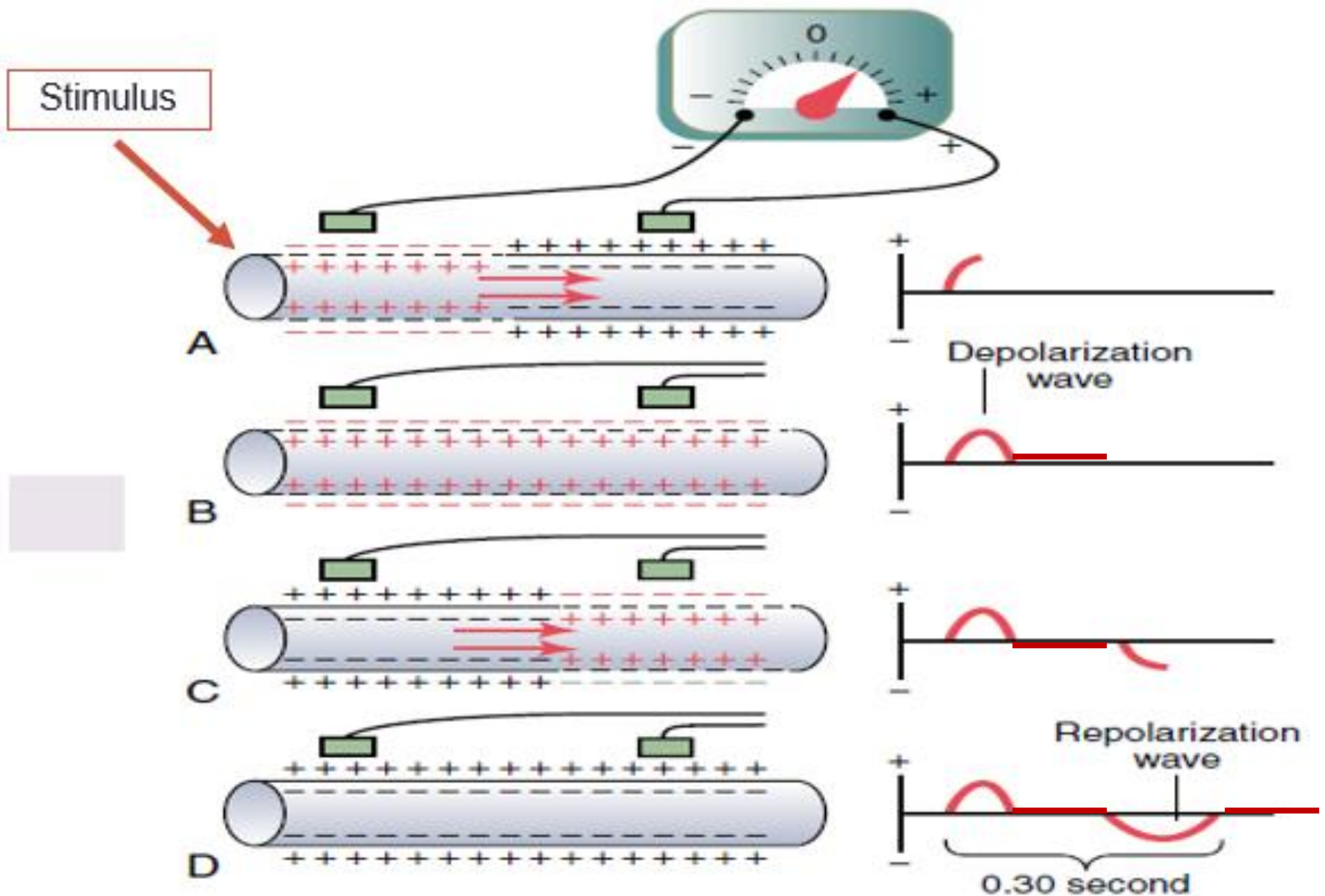
# Depolarization & Repolarization

- The resting heart muscle cell is polarized; that is, it carries an electrical charge, with the outside of the cell positively charged and the inside negatively charged



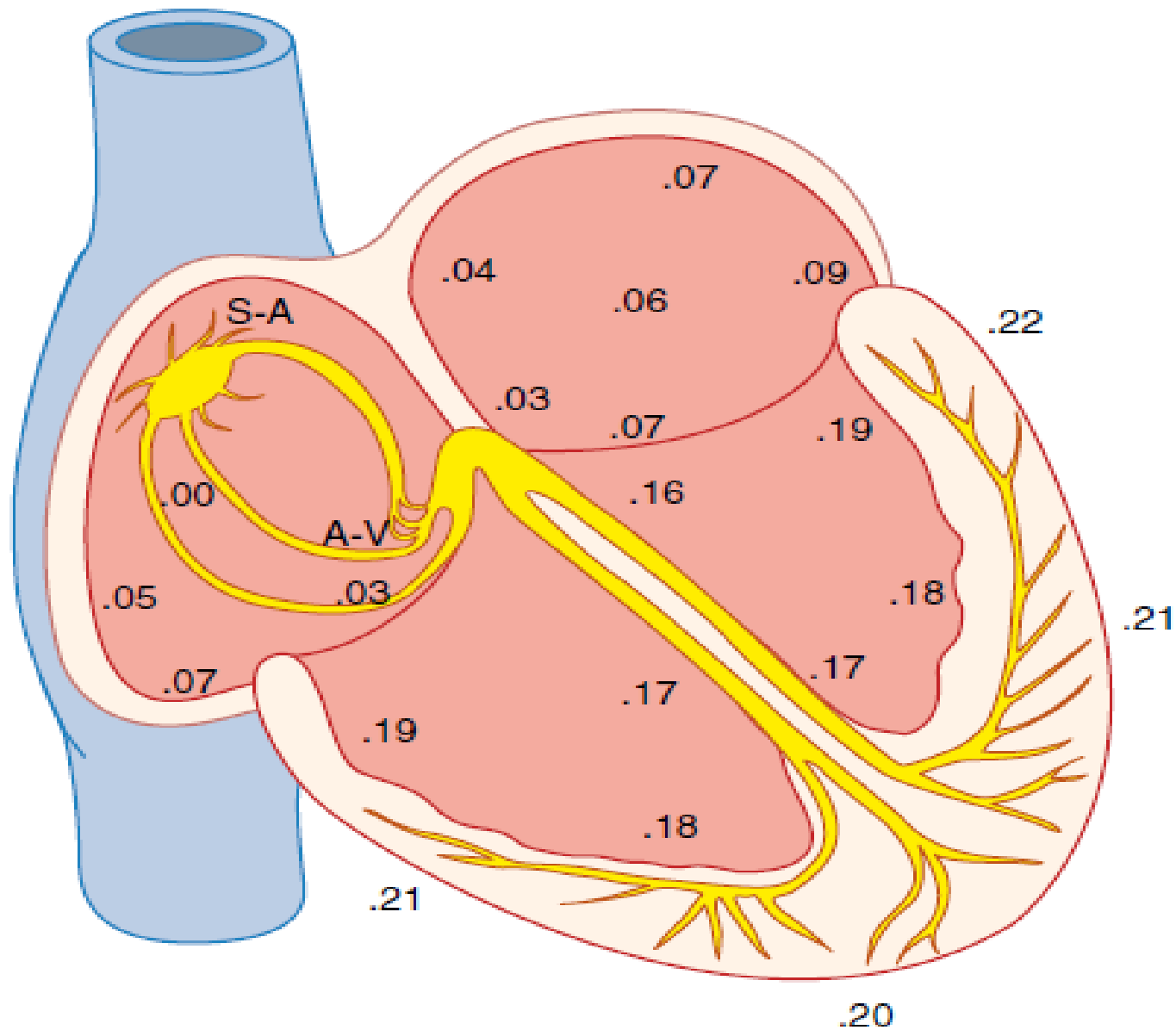
- When a heart muscle cell is stimulated, it depolarizes. As a result the outside of the cell, in the area where the stimulation has occurred, becomes negative and the inside of the cell becomes positive. This produces a difference in electrical voltage on the outside surface of the cell between the stimulated depolarized area and the unstimulated polarized area. Consequently, a small electrical current is formed.

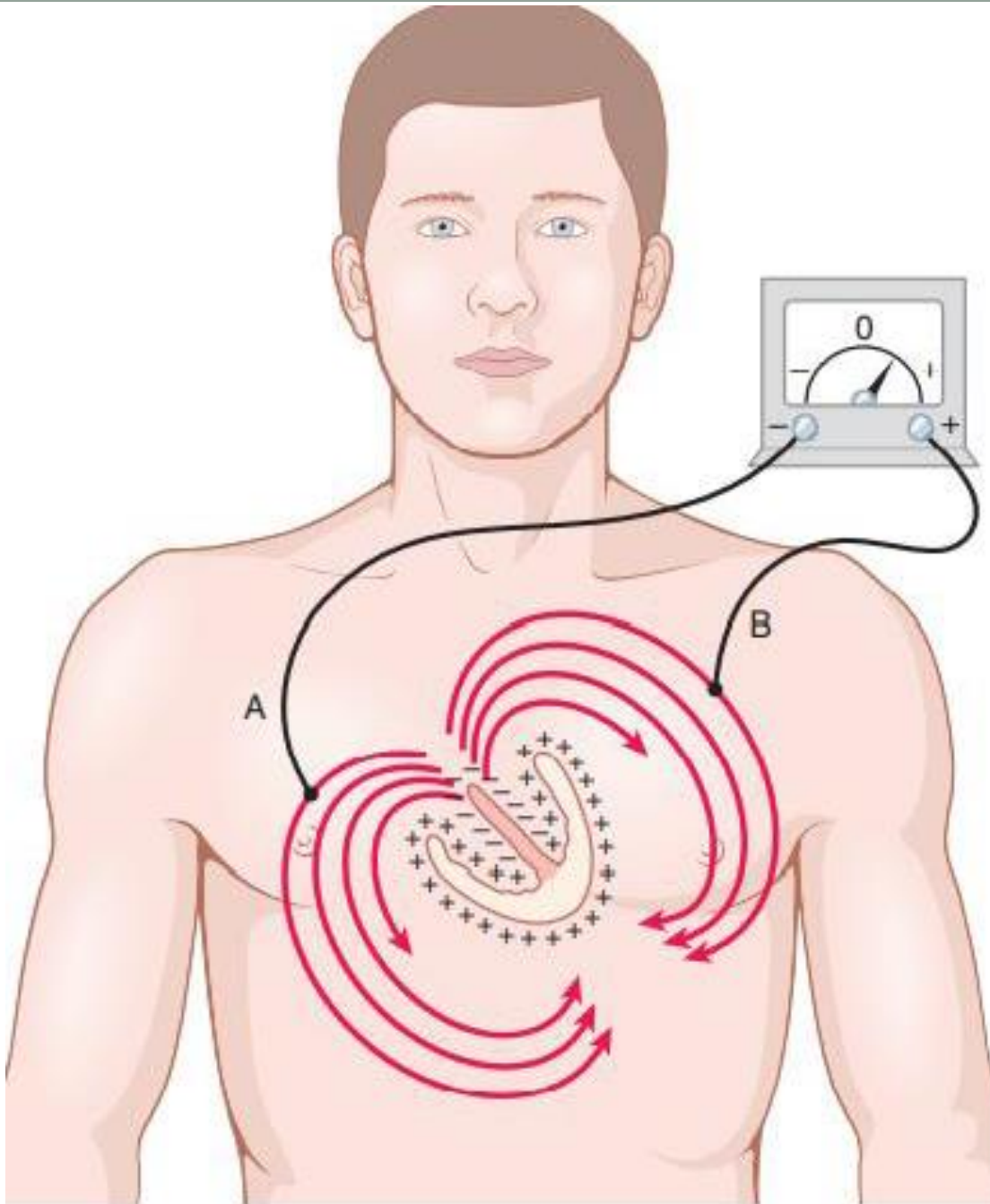
- Stimulation and depolarization occur until the entire cell is depolarized
- After a time the fully stimulated and depolarized cell begins to return to the resting state. This is known as repolarization.
- A small area on the outside of the cell becomes positive again and the repolarization spreads along the length of the cell until the entire cell is once again fully repolarized.
- The ECG machine records the electrical activity of a large mass of atrial and ventricular cells, not that of just a single cell.



**Figure 11-2** Recording the depolarization wave (A and B) and the repolarization wave (C and D) from a cardiac muscle fiber.

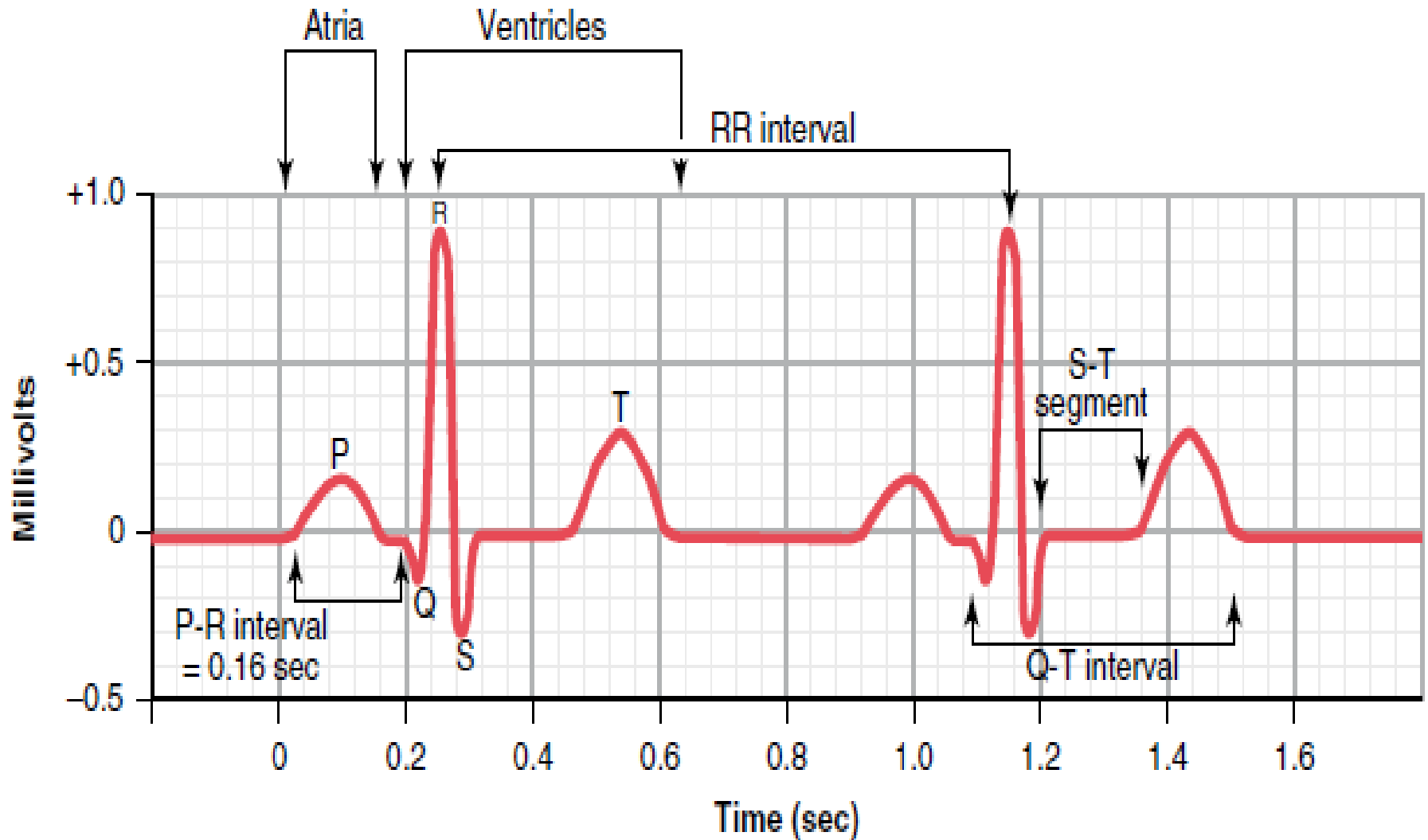
## Transmission of cardiac impulse





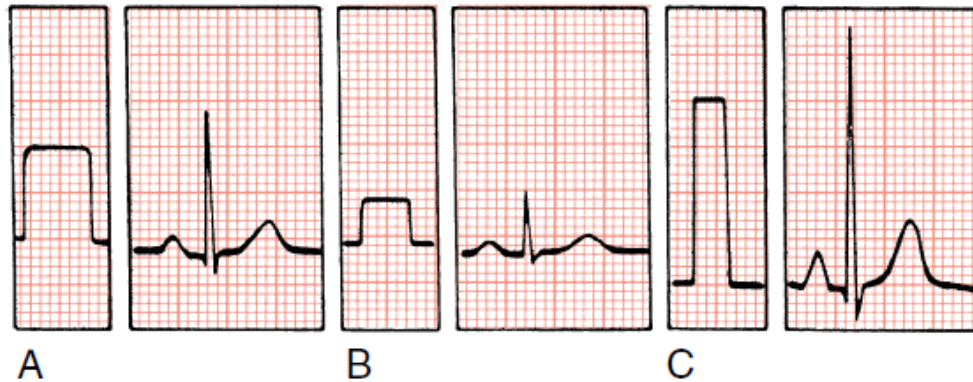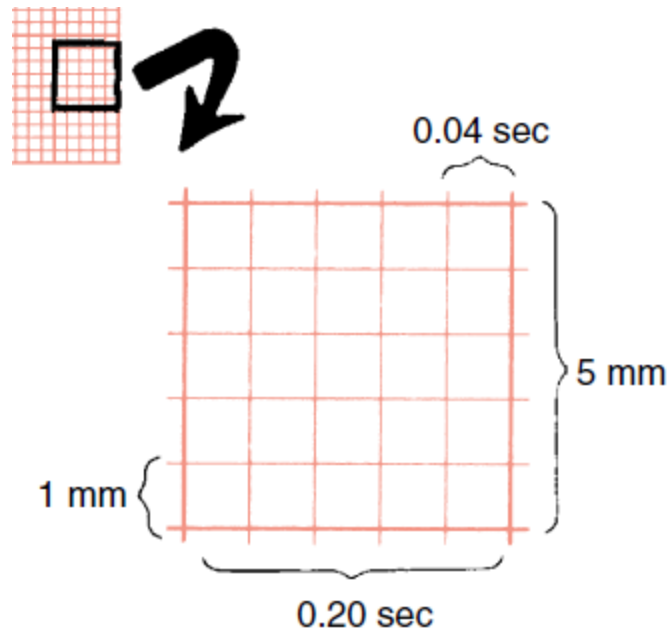
When one portion of the heart depolarizes and therefore becomes electronegative with respect to the remainder, electrical current flows from the depolarized area to the polarized area in large circuitous routes.

# The Normal ECG





- ECG is a plot of voltage on the vertical axis against time on the horizontal axis
- The ECG waves are recorded on a special graph paper that is divided into standard-sized squares. Each large square is 5 mm long and each small square is 1 mm long.
- ECG is recorded at a speed of 25mm/sec, So:
  - Each large square on the horizontal axis represents =0.2 sec (200ms)
  - Each small square on the horizontal axis represents =0.04 sec (40ms)
- Vertically, the ECG graph measures the height (amplitude) of a given wave or deflection, 10 mm (10 small squares) equals 1 mV with standard calibration.
- Paper speed and voltage are usually printed at the bottom of the ECG paper strip.

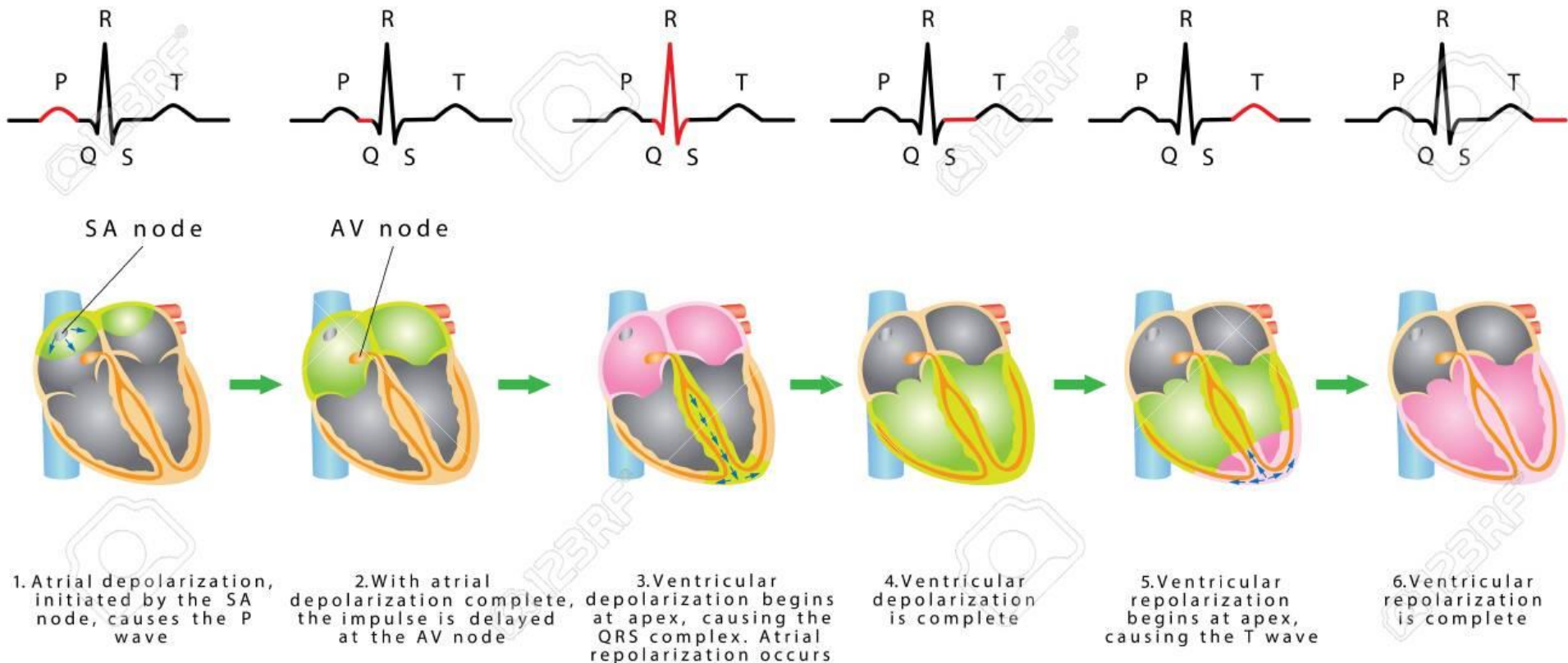


**Figure 2-5.** Before taking an ECG, the operator must check to see that the machine is properly calibrated, so that the 1-mV standardization mark is 10 mm tall. **A**, Electrocardiograph set at normal standardization. **B**, One-half standardization. **C**, Two times normal standardization.

# Main Components of ECG

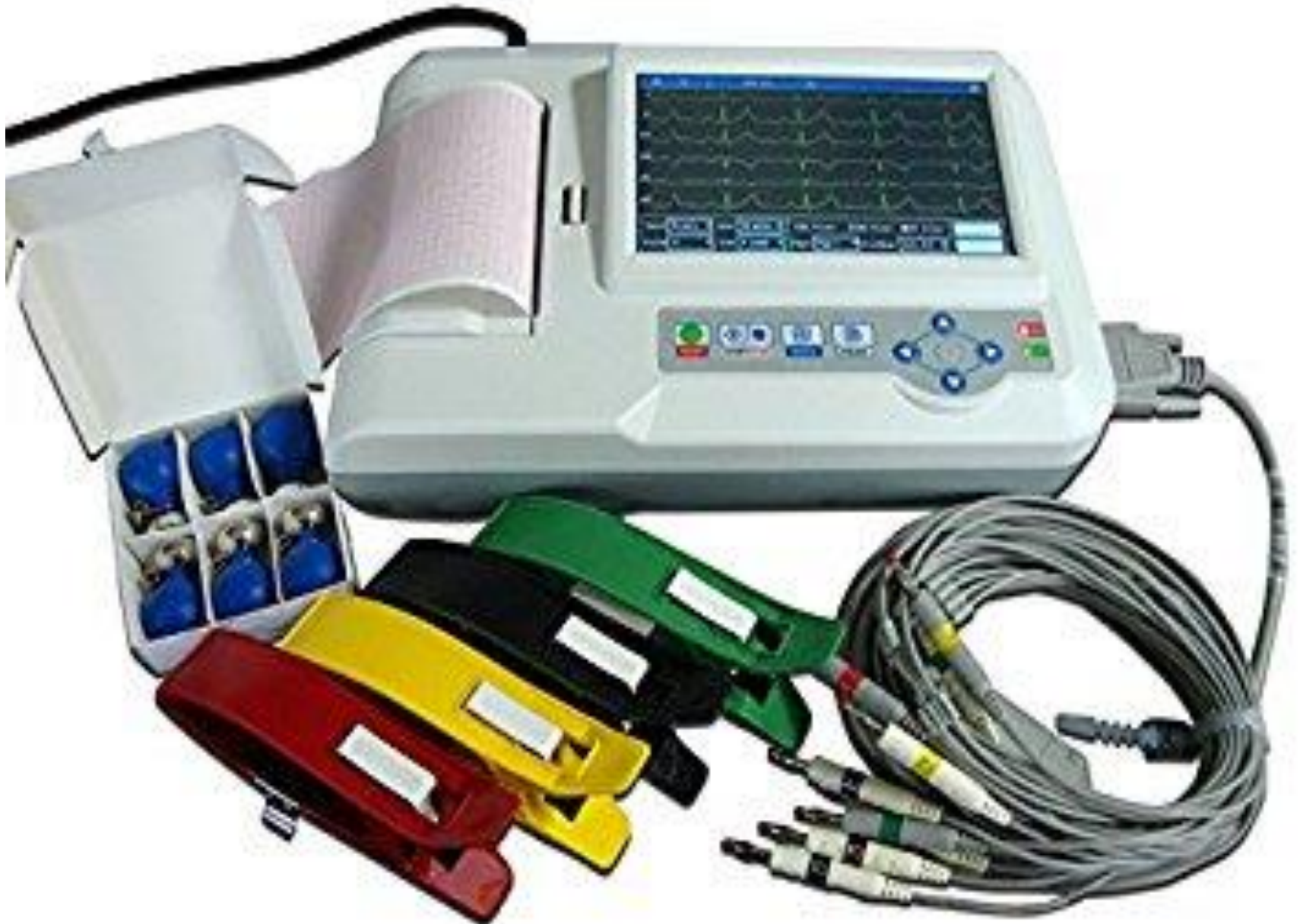- The ECG is made of: Depolarization and repolarization waves, Intervals, and Segments
- The **P wave** is caused by electrical potentials generated when the atria depolarize.
- The **QRS complex** is caused by potentials generated when the ventricles depolarize. The first downward deflection is called a Q wave. An upward deflection is called an R wave. Any downward deflection following an R wave is called an S wave
- The **T wave** is caused by potentials generated as the ventricles repolarize.
- The repolarization wave of the atria occurs at the same time as the QRS complex that's why it's not seen on the ECG record **normally**.

- PR interval
  - From the beginning of the P wave till the beginning of the QRS complex.
- QT interval
  - From the beginning of the QRS complex to the end of the T wave (ventricular depolarization & repolarization).
- R-R interval
  - Represents one cardiac cycle & is essential in calculating the heart rate.
- PR segment
  - Extends from the end of P wave to the beginning of QRS complex. It should be isoelectric.
- ST segment
  - Extends from the end of QRS complex to the beginning of T wave. It should be isoelectric.
- T-P segment
  - Extends from the end of T to the beginning of P. It should be isoelectric



## THE CARDIAC CYCLE

# Electrocardiograph Machine



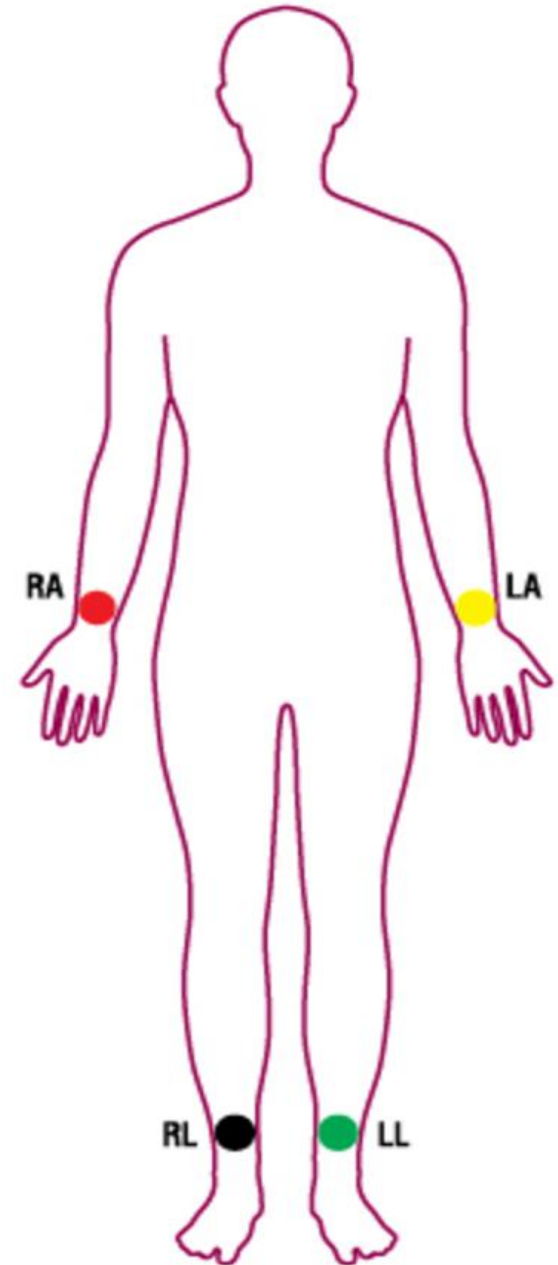


# The ECG machine

- This machine compares, amplifies and filters the electrical potential differences recorded by the ELECTRODES and presents the results as LEADS
- Electrode is a conductive pad which is attached to the skin and allows recording of electrical currents
- The electrodes placed on the surface of the body record only the currents that are transmitted to the area of electrode placement.
- An ECG lead is a graphical description of the electrical activity of the heart from a particular angle across the body. It is created by analysing the data obtained from two or more electrodes

# 12-Lead ECG

- 12-lead ECG is generated from 10 electrodes.
- These 10 electrodes allow the electrical activity of the heart to be looked at from 12 different positions. There are 4 limb electrodes and 6 chest electrodes.
- Limb electrodes:
  - LA – Left arm
  - RA – Right arm
  - LL – Left leg
  - RL – Right leg
- ✓ RL is a neutral lead and is solely present to complete the electrical circuit. It plays no role in the formation of the ECG leads

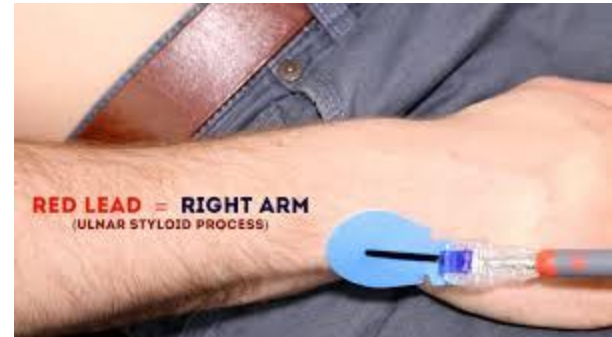



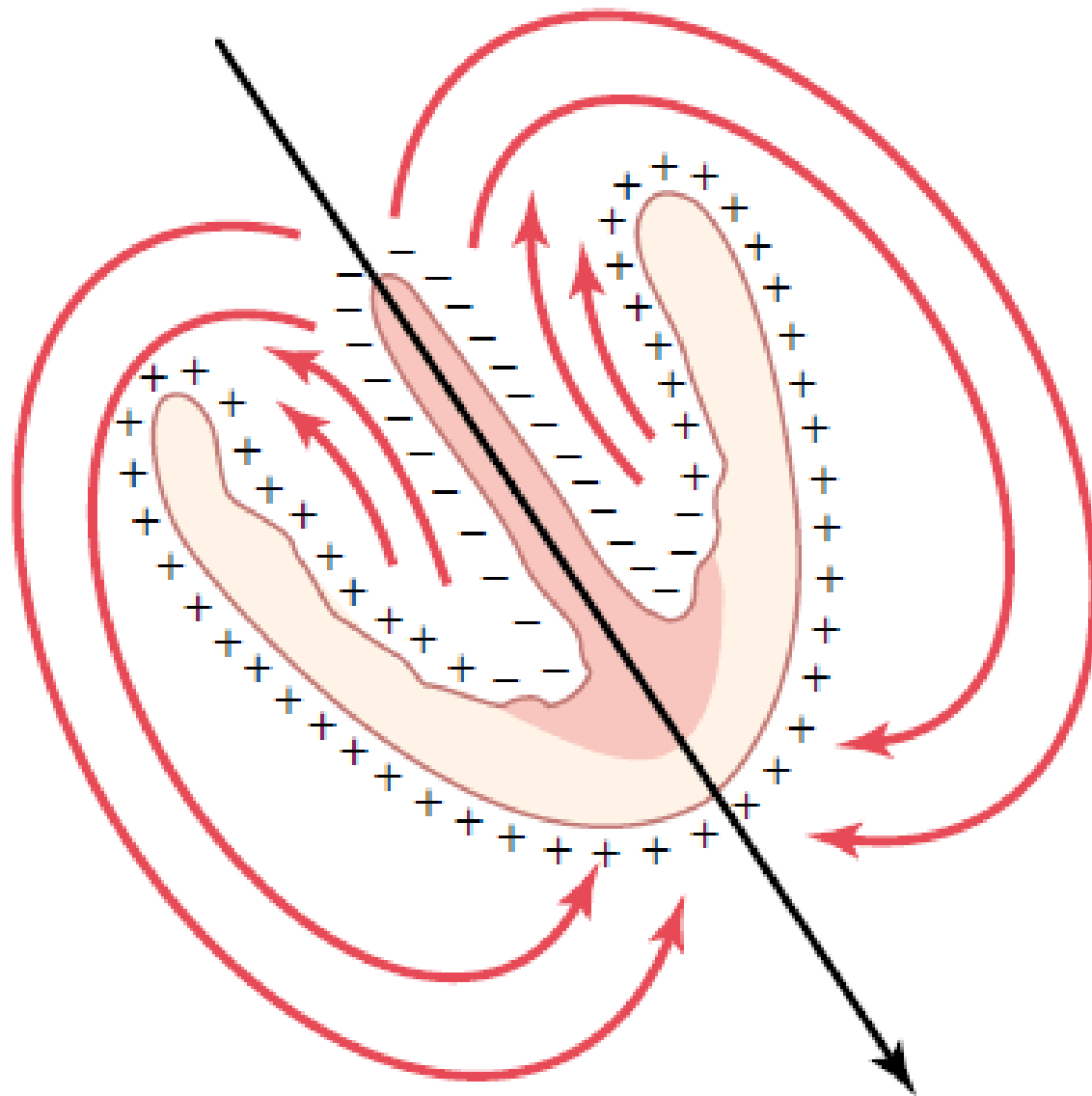
# Limb Electrodes



Clamp Electrodes

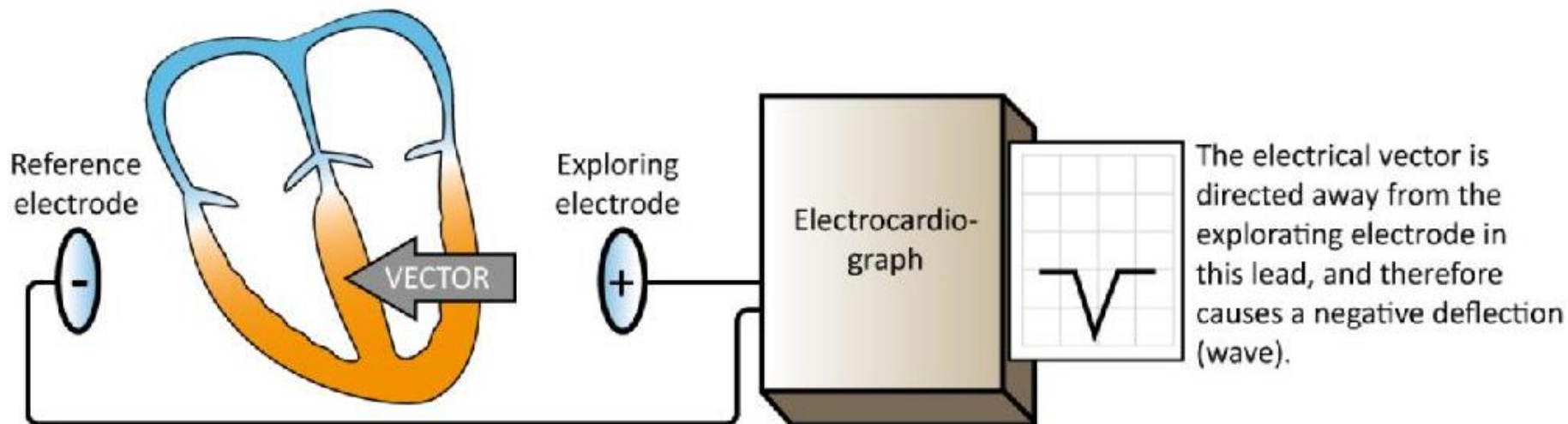
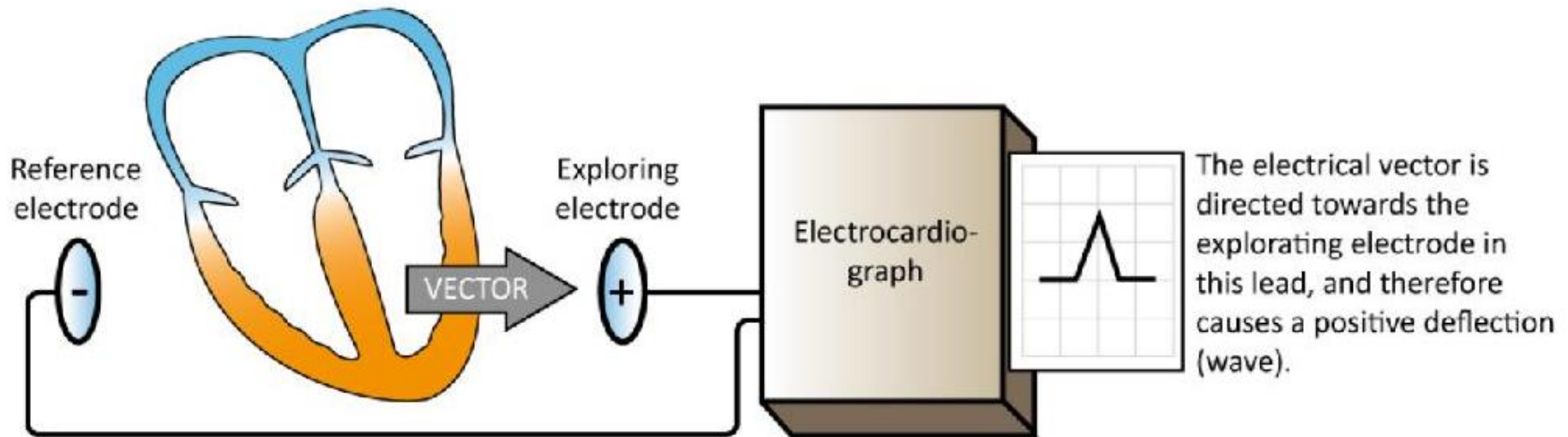


Disposable, adhesive



**Figure 12-1** Mean vector through the partially depolarized ventricles.

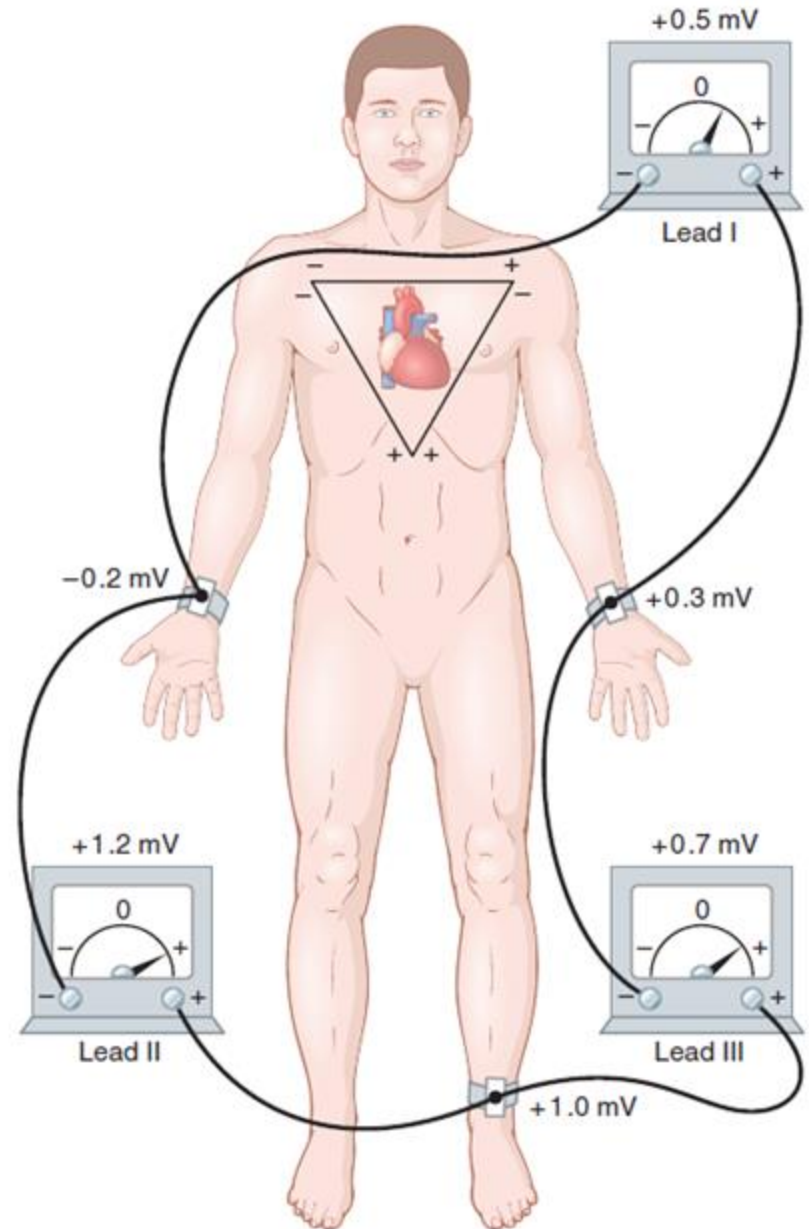
# Recording a wave of depolarization



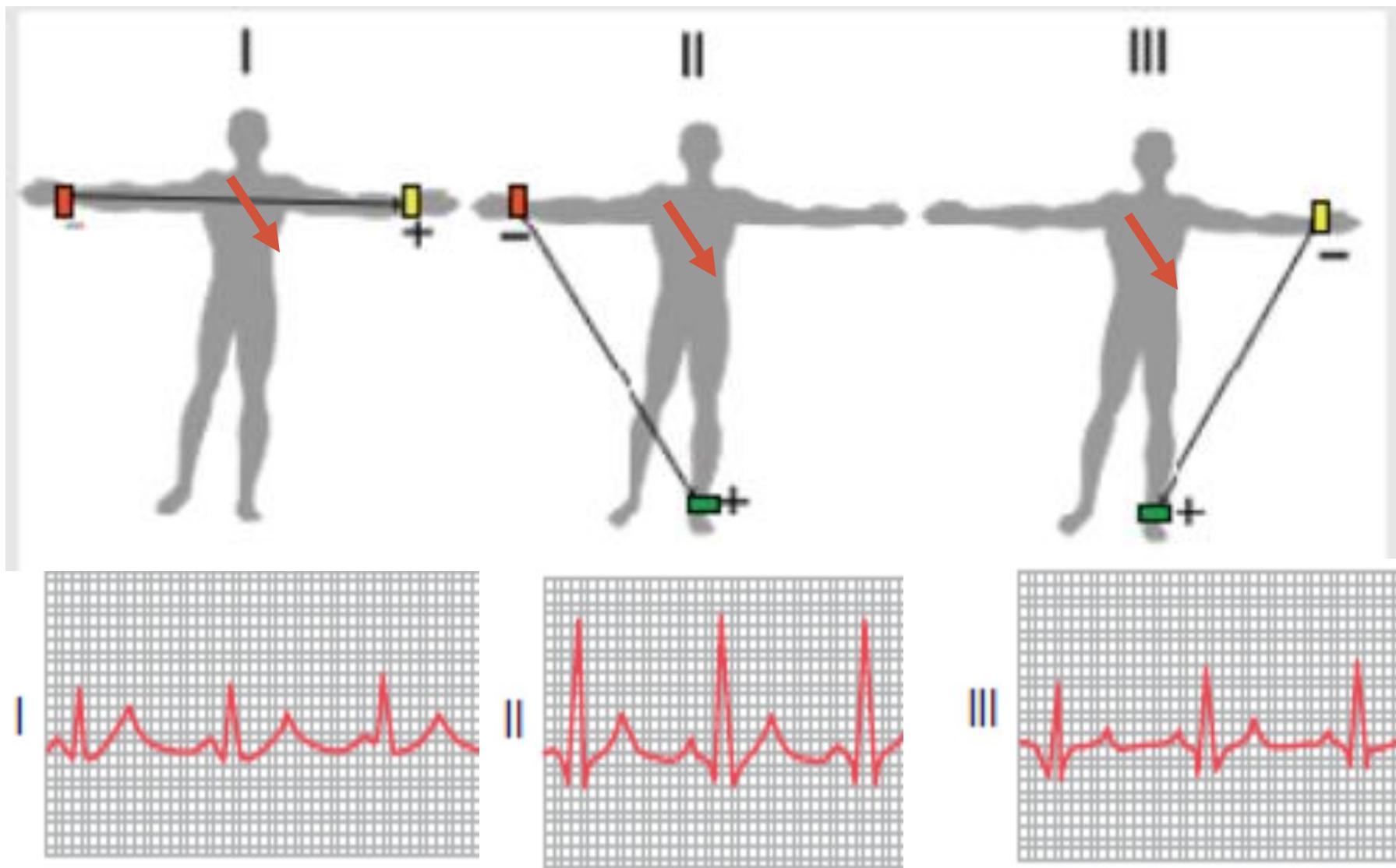
# Limb leads (Frontal Plane)

## ➤ Bipolar Limb Leads

- Lead I: RA (-) to LA (+)
- Lead II: RA (-) to LL (+)
- Lead III: LA (-) to LL (+)



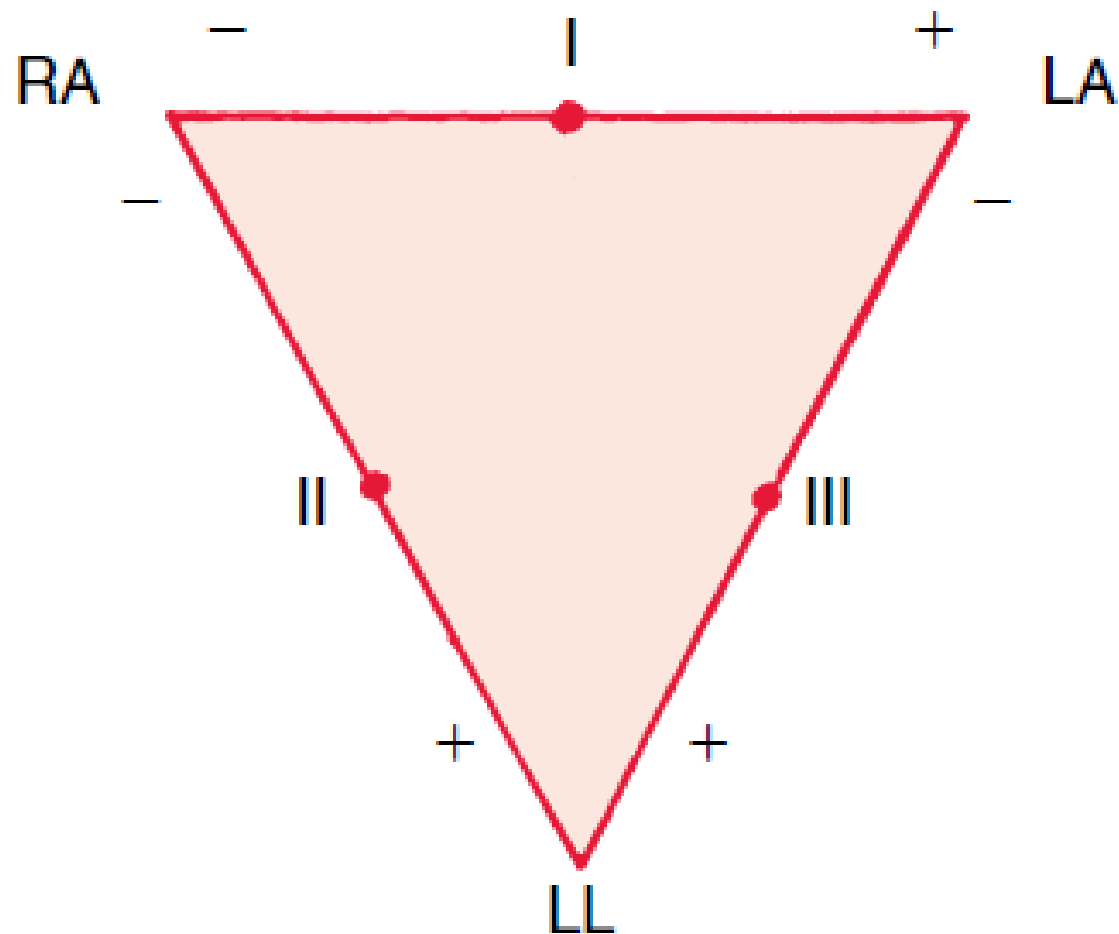
**Figure 11-6.** Conventional arrangement of electrodes for recording the standard electrocardiographic leads. Einthoven's triangle is superimposed on the chest.



# Einthoven's Triangle & Law

- Einthoven's triangle, the two arms and the left leg form apices of a triangle surrounding the heart.
- Einthoven's law states that if the electrical potentials of any two of the three bipolar limb leads are known at any given instant, the third one can be determined mathematically. Because:
- The sum of the voltages in leads I and III equals the voltage in lead II

# Einthoven's Triangle



# Limb leads (Frontal Plane)

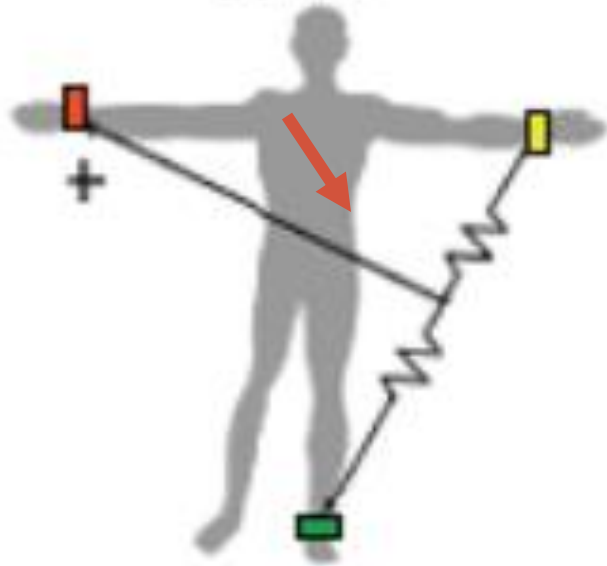
## ➤ **Augmented Unipolar Limb Leads**

➤ Connect two limbs to the negative (reference) electrode through very high resistance (the recorded voltage will be almost zero). The third limb is connected to the positive(exploring) electrode and its voltage is thus recorded.

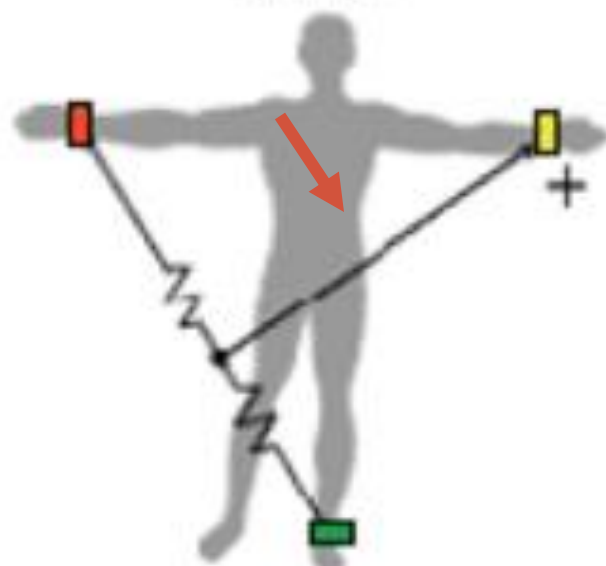
- Lead aVR: RA (+) to [LA & LL] (-)
  - Lead aVL: LA (+) to [RA & LL] (-)
  - Lead aVF: LL (+) to [RA & LA] (-)
- a refers to augmented; V to voltage; and R to right arm, L left arm, and F left foot (leg).



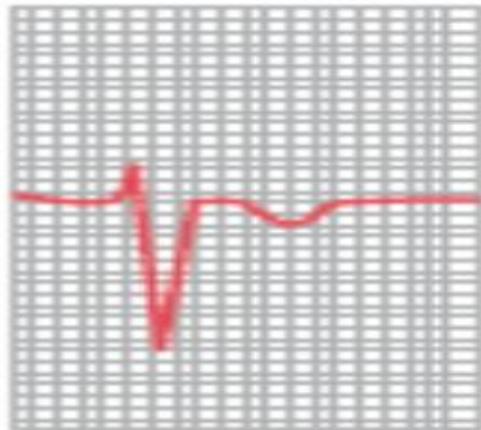
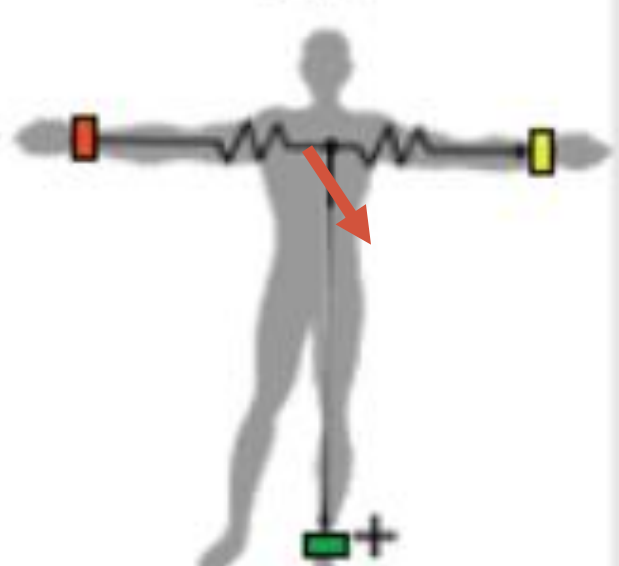
aVR



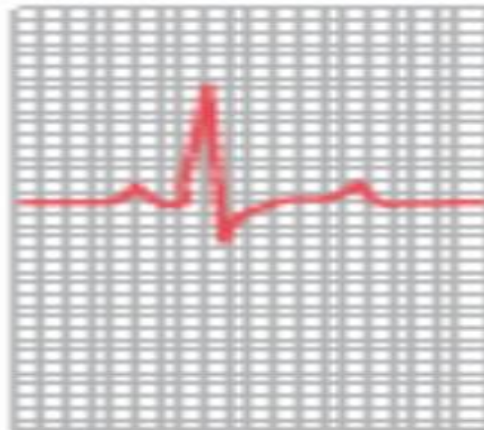
aVL



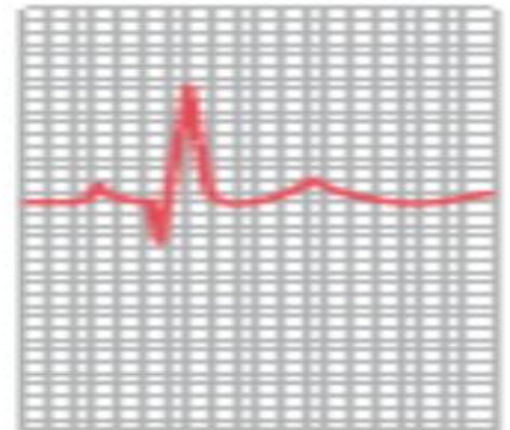
aVF



aVR



aVL

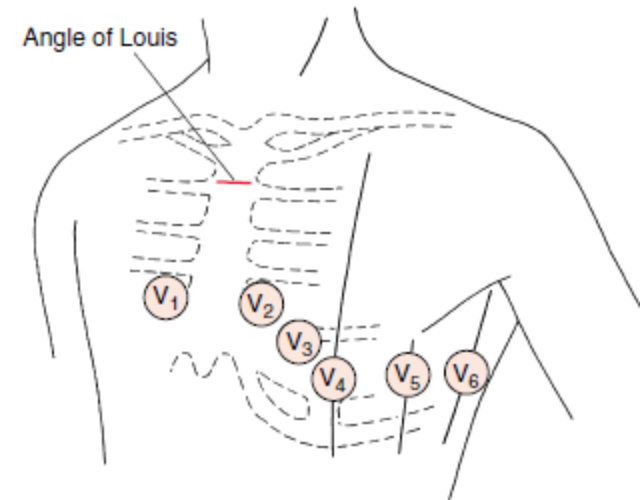


aVF

# Chest electrodes

## Position of the chest electrodes:

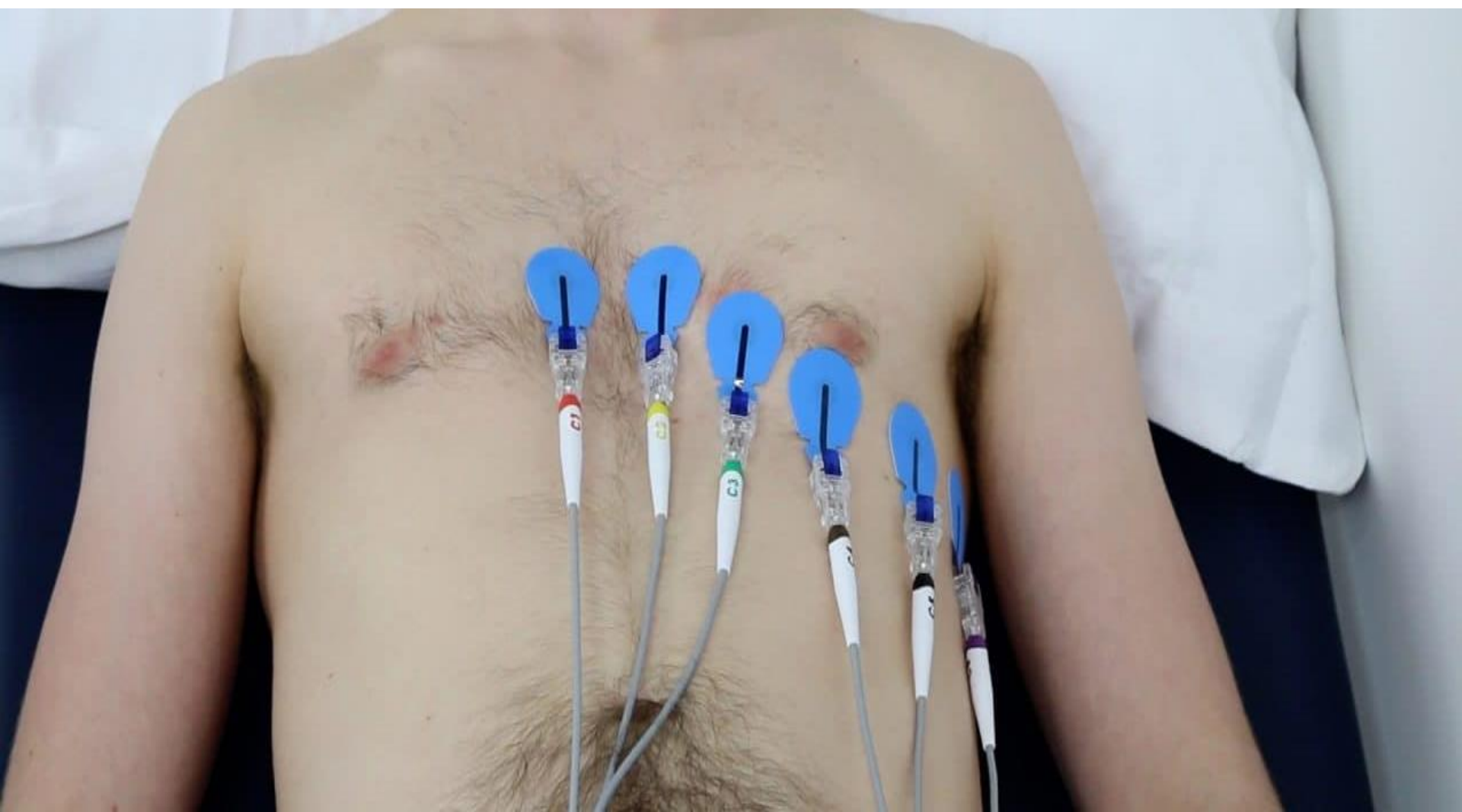
- V1: Right sternal edge, 4th intercostal space
- V2: Left sternal edge, 4th intercostal space
- V3: Midway between V2 and V4
- V4: Left mid-clavicular line, 5th intercostal space
- V5: Left anterior axillary line, 5th intercostal space
- V6: Left mid-axillary line, 5th intercostal space

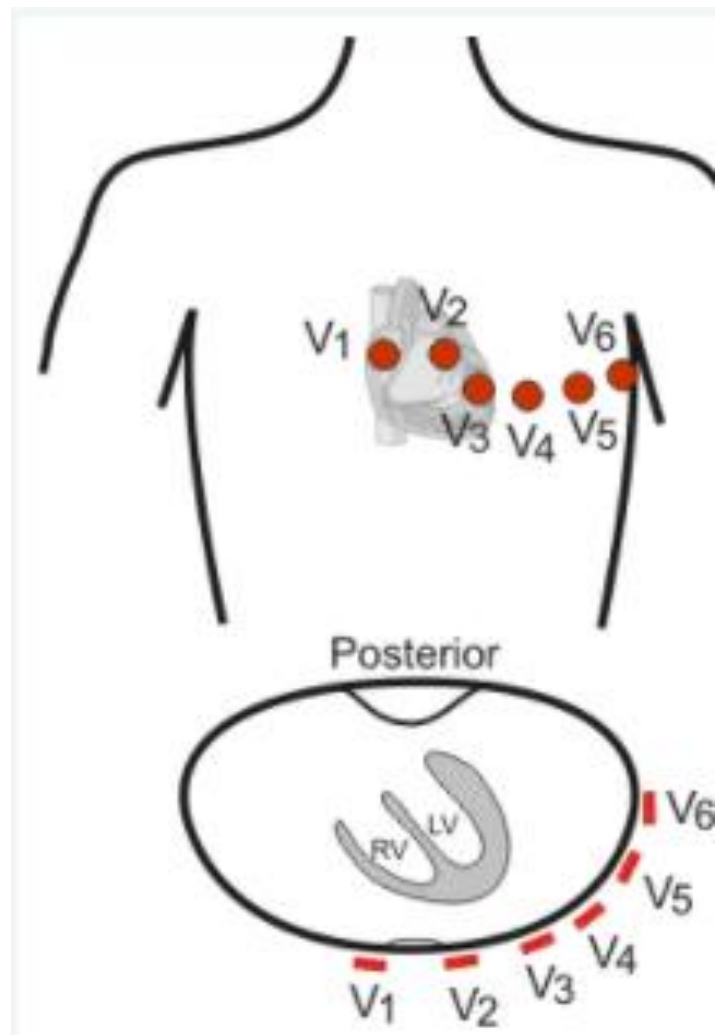
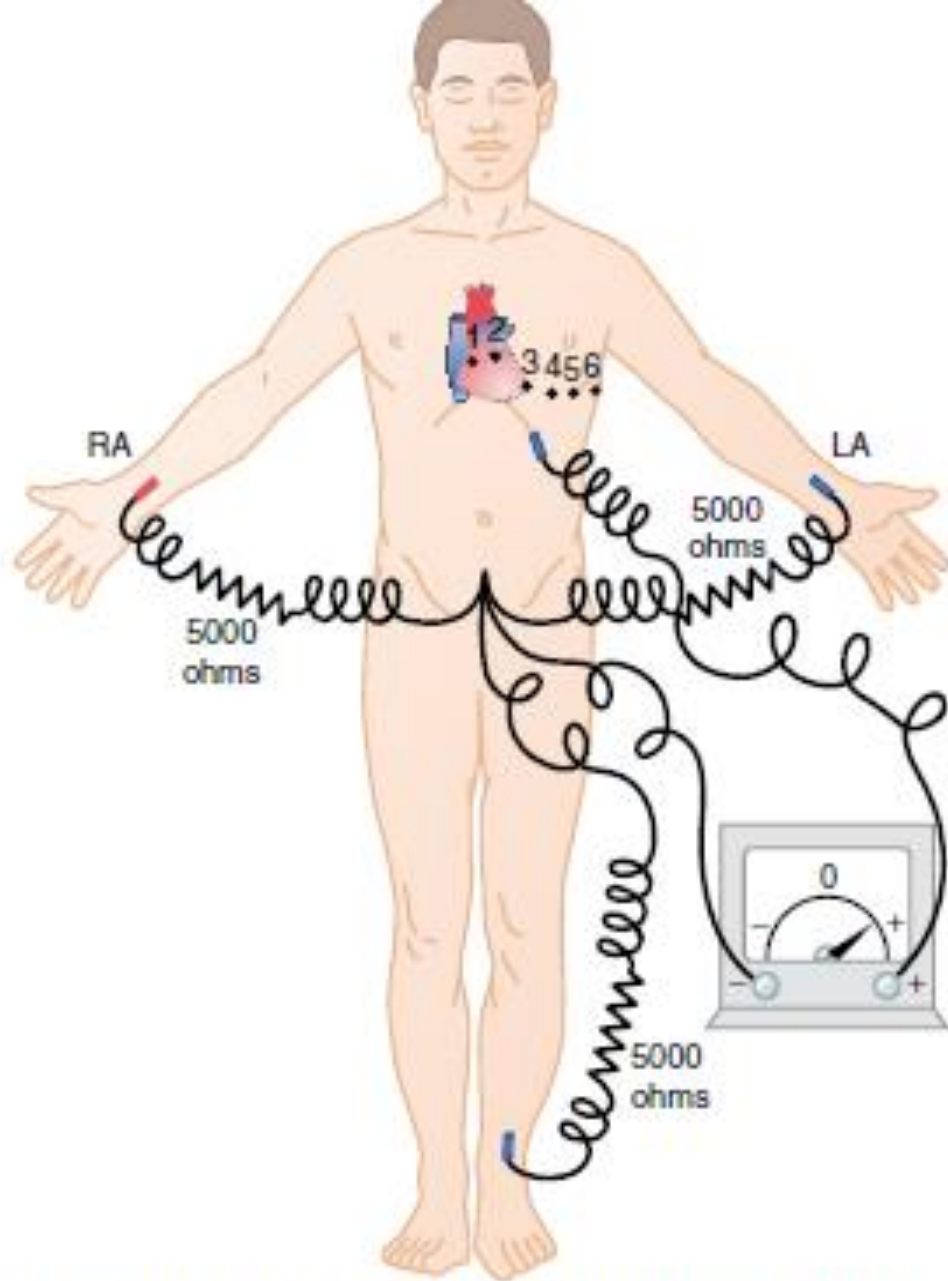


Disposable, adhesive



Suction bulb electrodes

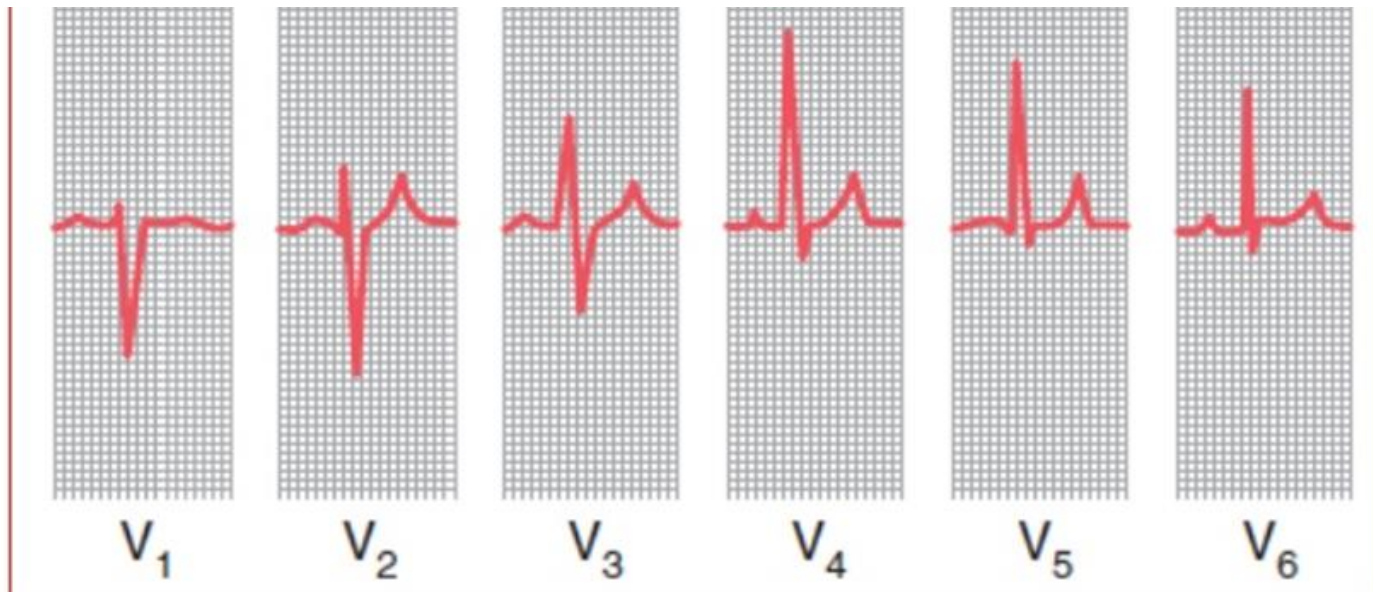




**Figure 11-8** Connections of the body with the electrocardiograph for recording chest leads. LA, left arm; RA, right arm.

# Chest Leads (Horizontal plane)

- These are unipolar leads.
- The positive (exploring) electrode is placed on the anterior surface of the heart and the negative (reference) electrode is attached to the three limbs through very high resistance



# QRS complex progression in chest leads

- The QRS complex in the chest leads shows a progression from lead V1, where it is predominantly negatively deflected, to lead V6, where it is predominantly positively deflected. The 'transition point', where the R and S waves are equal, indicates the anatomical position of the interventricular septum. It is normally seen in leads V3 or V4.



# What we need to perform a 12 lead ECG

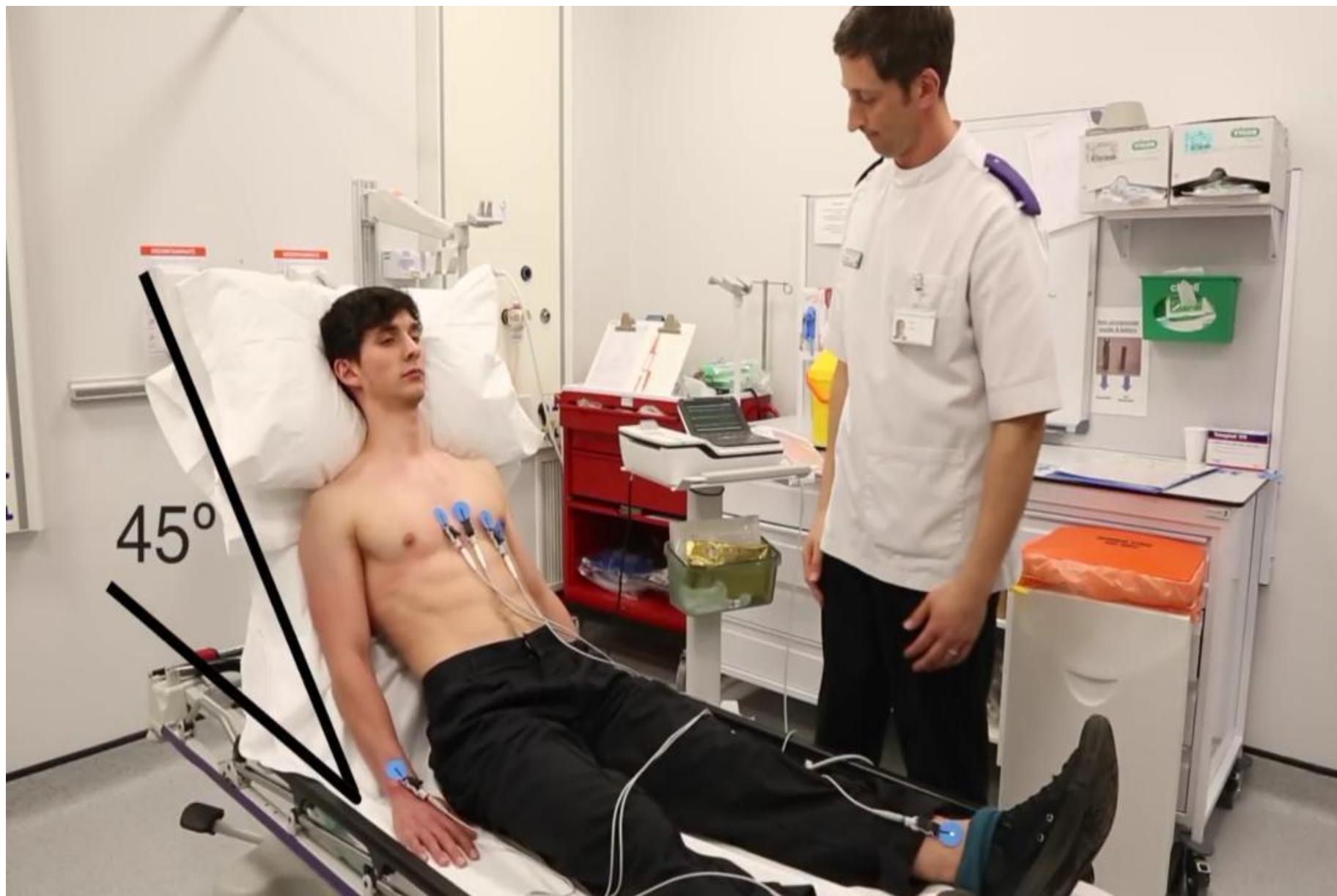- ECG machine
- 4 limb electrodes
- 6 chest electrodes
- Razors and skin cleansing wipes (alcohol swabs)
- Conducting gel

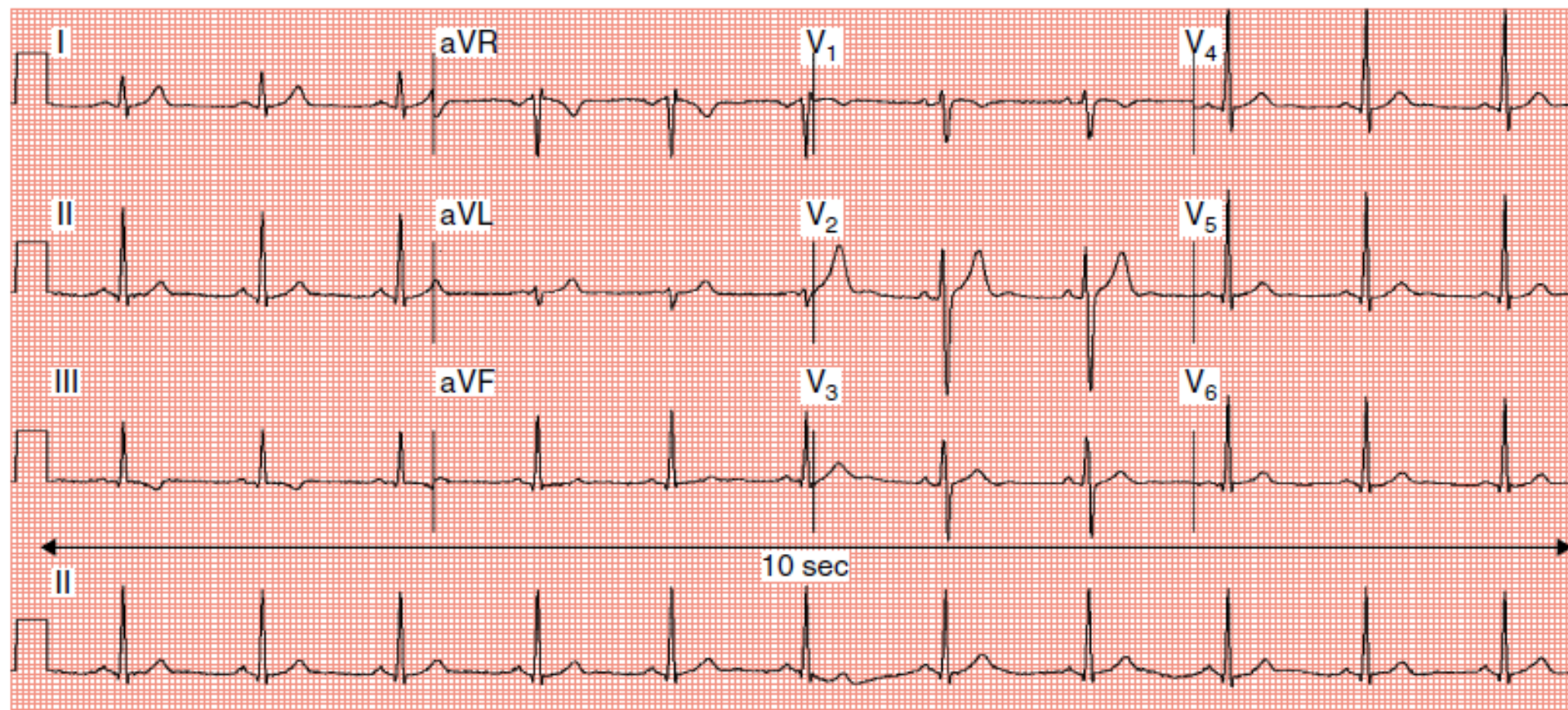


# MAKING A RECORDING – PRACTICAL POINTS

- Fully explain the procedure to the patient
  - Make sure the patient is relaxed, warm and lying in a Semi-recumbent position comfortably
  - Ask the patient to take off any jewellery, belts and clothes with metallic parts and to turn off the cell phone.
  - Shaving might be necessary since hair is a bad conductor of electrical activity.
  - Make sure the skin is clean and dry
  - The electrodes should be accurately positioned.
  - Apply the gel in sufficient quantities.
  - Ensure good contact between the electrodes and the skin.
  - Make sure the patient isn't moving or talking while making the record
  - Check the calibration & speed settings on the machine.
- 
- You can watch this video for further clarification
  - [//www.youtube.com/watch?v=1k4B\\_fIX\\_t0](https://www.youtube.com/watch?v=1k4B_fIX_t0)







### A good record of a normal ECG

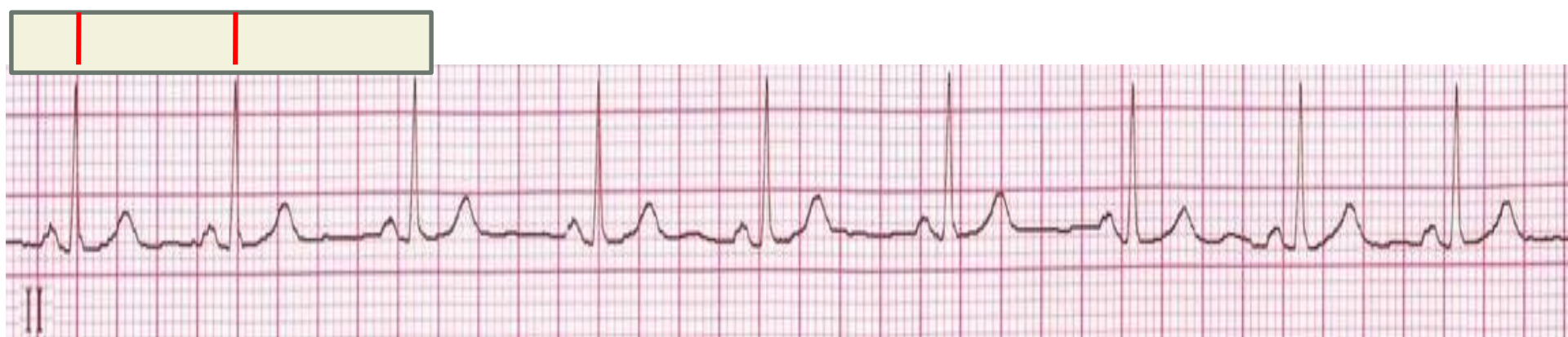#### Note

- The upper three traces show the six limb leads (I, II, III, VR, VL, VF) and then the six chest leads
- The bottom trace is a 'rhythm strip', entirely recorded from lead II (i.e. no lead changes)
- The trace is clear, with P waves, QRS complexes and T waves visible in all leads

# Heart rhythm

- When depolarization begins in the SA node and spreads in its normal pathway the heart is said to be in sinus rhythm. This is the normal heart rhythm
- If depolarization begins elsewhere the rhythm is named after the part where the depolarization starts. e.g nodal rhythm starts in AV node
- The best way to assess the ECG rhythm is by inspecting the rhythm strip. This is usually a 10 second recording from lead II

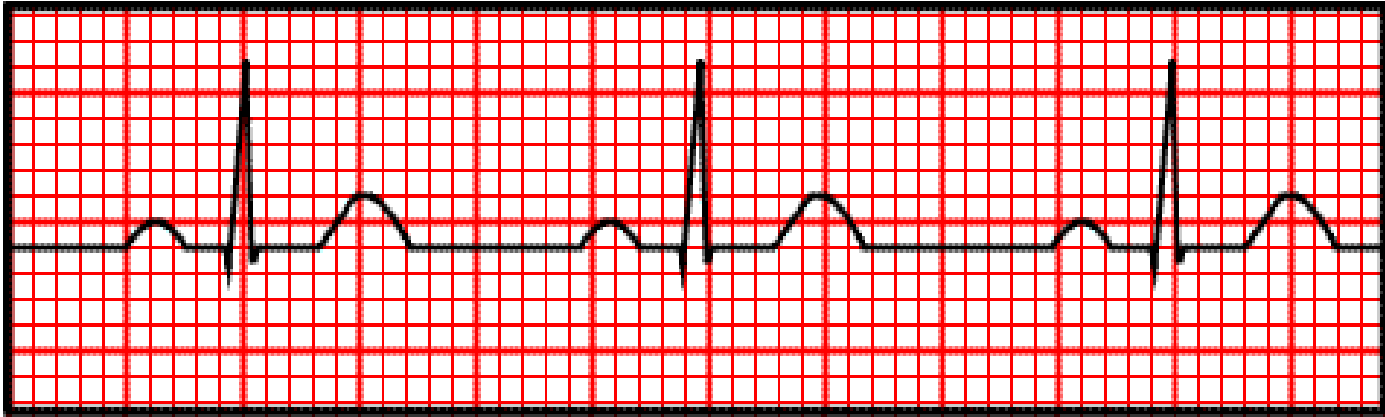
- ✓ Checking for the presence of sinus rhythm:
  - Ascertain the presence of a P wave prior to every QRS complex
  - The P wave should have the same contour in the same lead
  - R-R interval should have little variation ( $<0.12\text{sec}$ ) throughout the ECG. This can be checked by a ruler or by a marking on a piece of paper.



# Heart Rate

- Normal heart rate in adults ranges from 60 to 100 beats per minute
- Tachycardia vs Bradycardia
- How to calculate heart rate from ECG:
  - ✓ Determine the length of R-R interval
  - ✓ R-R interval represents one cardiac cycle SO
  - ✓ Heart Rate =  $60 / \text{time in R-R interval}$
  - ✓ Or Heart Rate =  $300 / \# \text{ large squares in R-R interval}$
  - ✓ Or Heart Rate =  $1500 / \# \text{ small squares in R-R interval}$

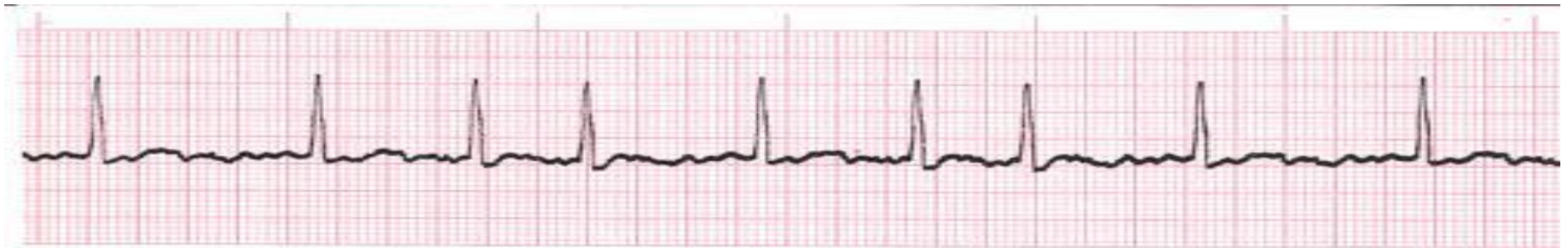



$HR = 60 / 0.8 = 75 \text{ B.P.M}$

$HR = 300 / 4 = 75 \text{ B.P.M}$

$HR = 1500 / 20 = 75 \text{ B.P.M}$



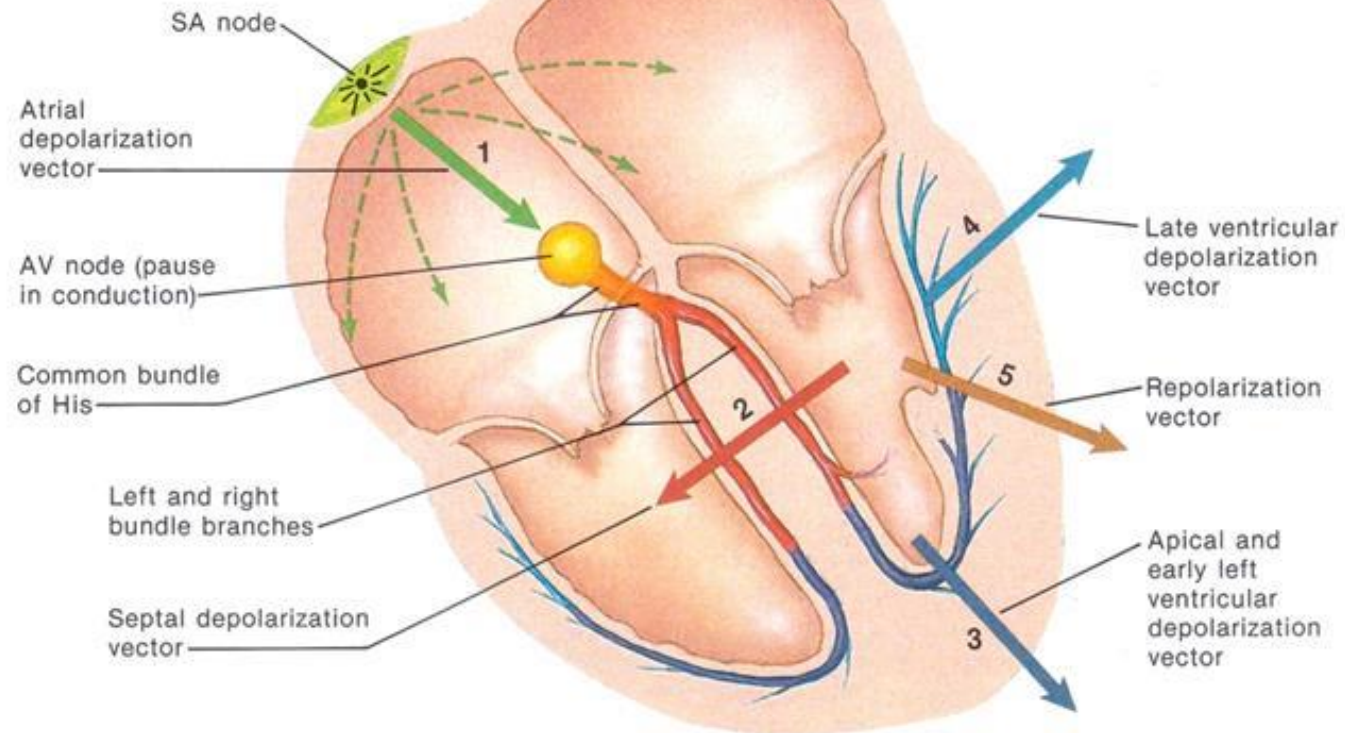
The heart rate = 90 according to the 6 second method

# Principles of vectorial analysis of ECG

- A vector is an arrow that points in the direction of the electrical potential generated by the current flow, with the arrow head in the positive direction. Also, by convention, the length of the arrow is drawn proportional to the voltage of the potential.
- When a vector is exactly horizontal and directed toward the person's left side, the vector is said to extend in the direction of 0 degrees. From this zero reference point, the scale of vectors rotates clockwise.
- In a normal heart during ventricular depolarization considerably more current flows downwards ;from the base of towards the apex ,than in the upward direction.
- The mean QRS vector, is about +59 degrees.
- This means that during most of the depolarization wave, the apex of the heart remains positive with respect to the base of the heart.

## F. Summary of cardiac electrical activity

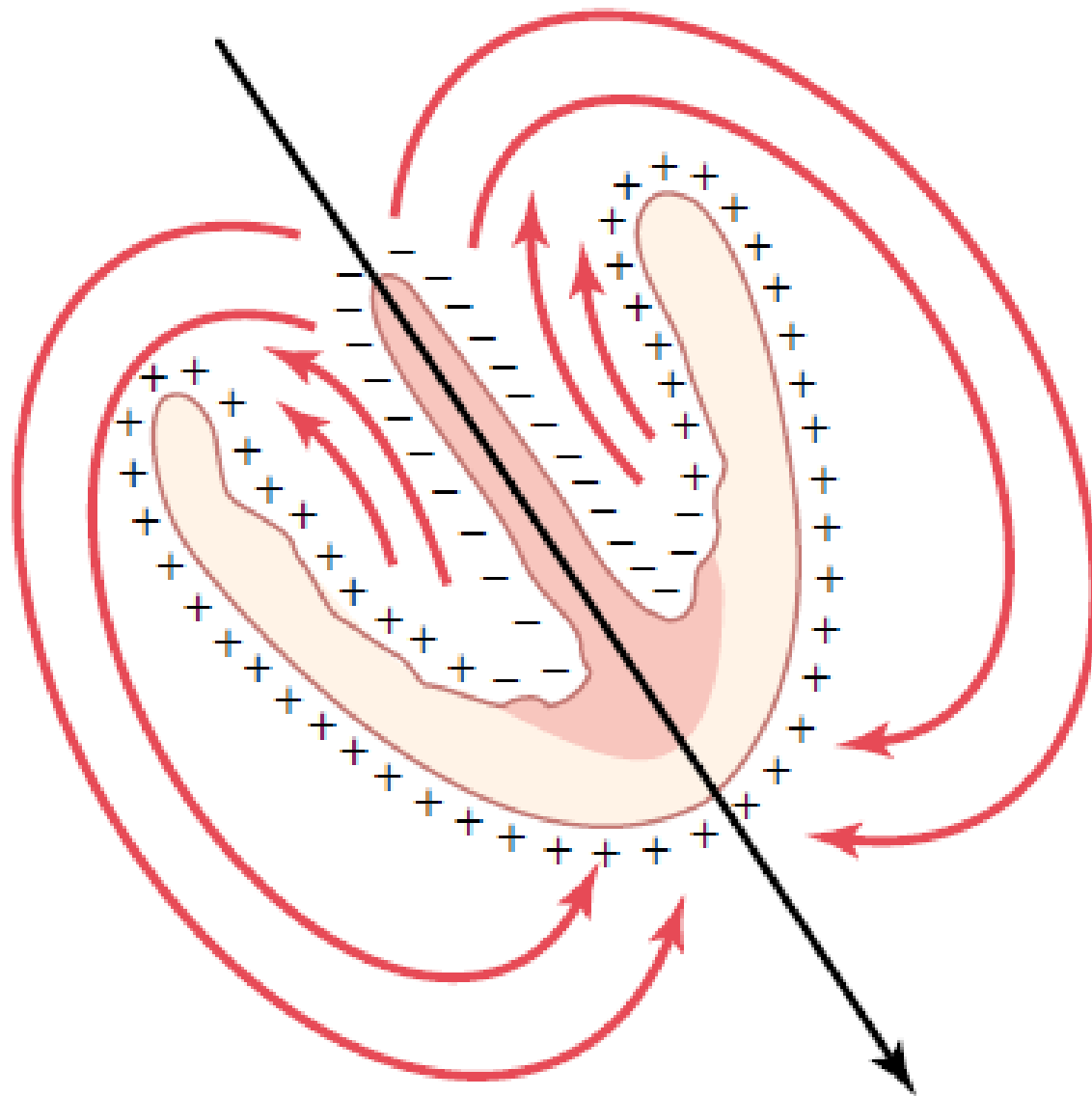
*F. Netter M.D.*  
© CIBA



QRS axis is a summation of all vectors during ventricular depolarization







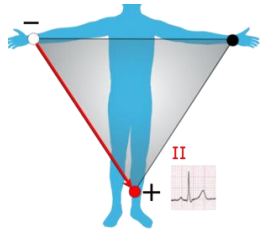
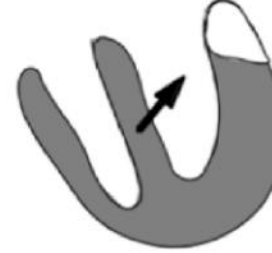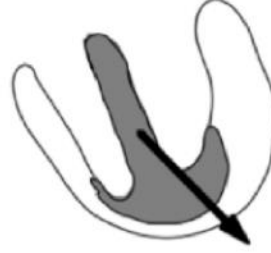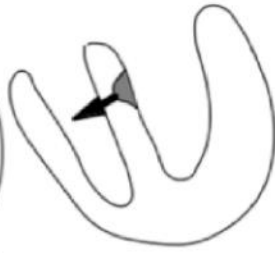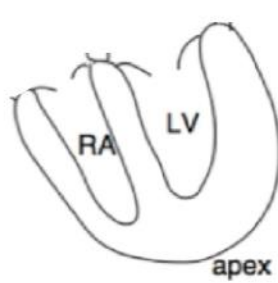
**Figure 12-1** Mean vector through the partially depolarized ventricles.

septal  
depolarization

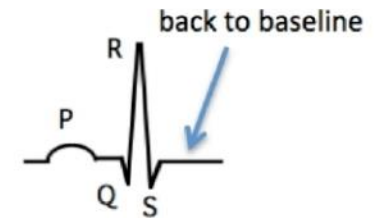

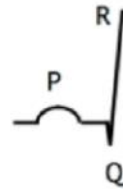
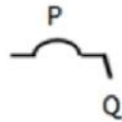
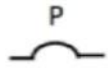
apical  
depolarization


late ventricular  
depolarization


complete ventricular  
depolarization (no dipole)

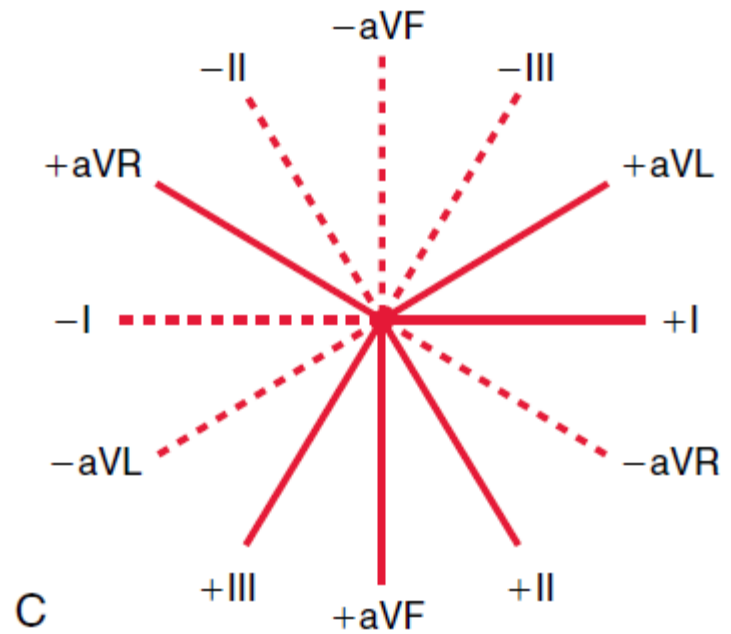
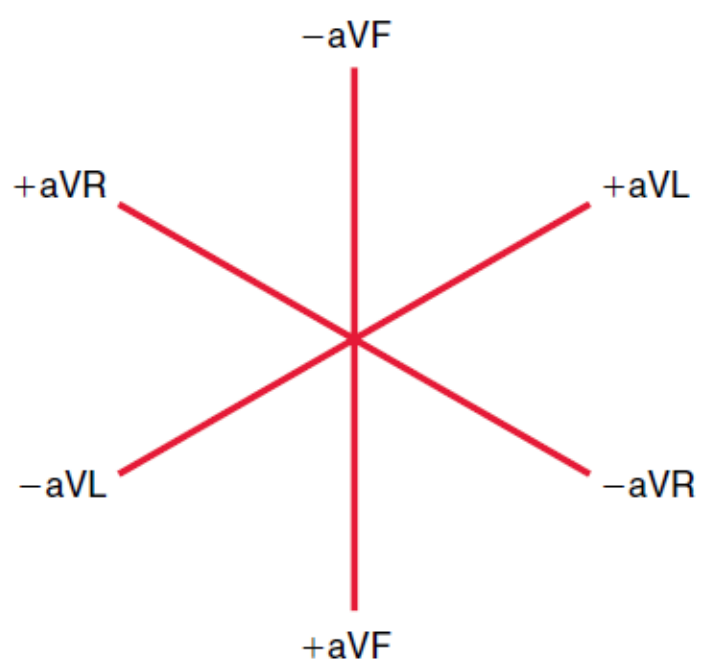
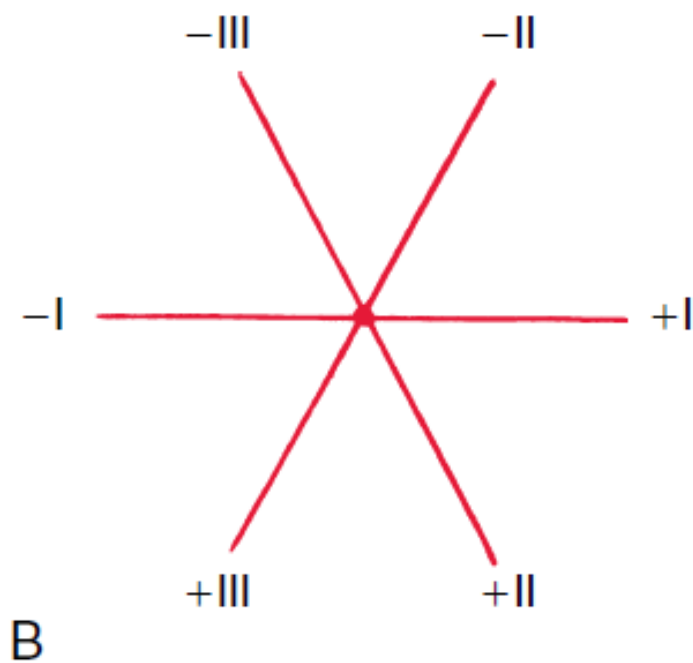
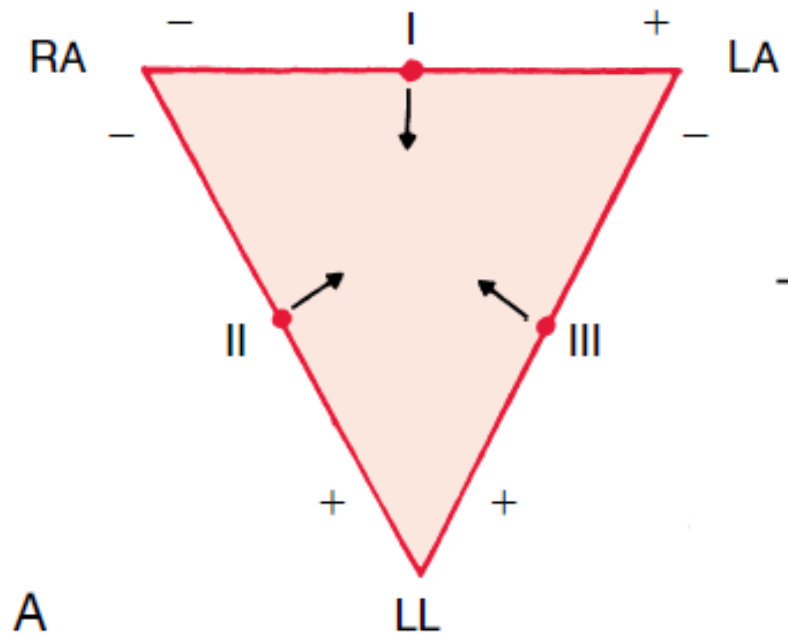


Lead II



 The cells are depolarized  
(surface voltage is negative)

 The cells are polarized  
(surface voltage is positive)



# Determining the Cardiac Axis

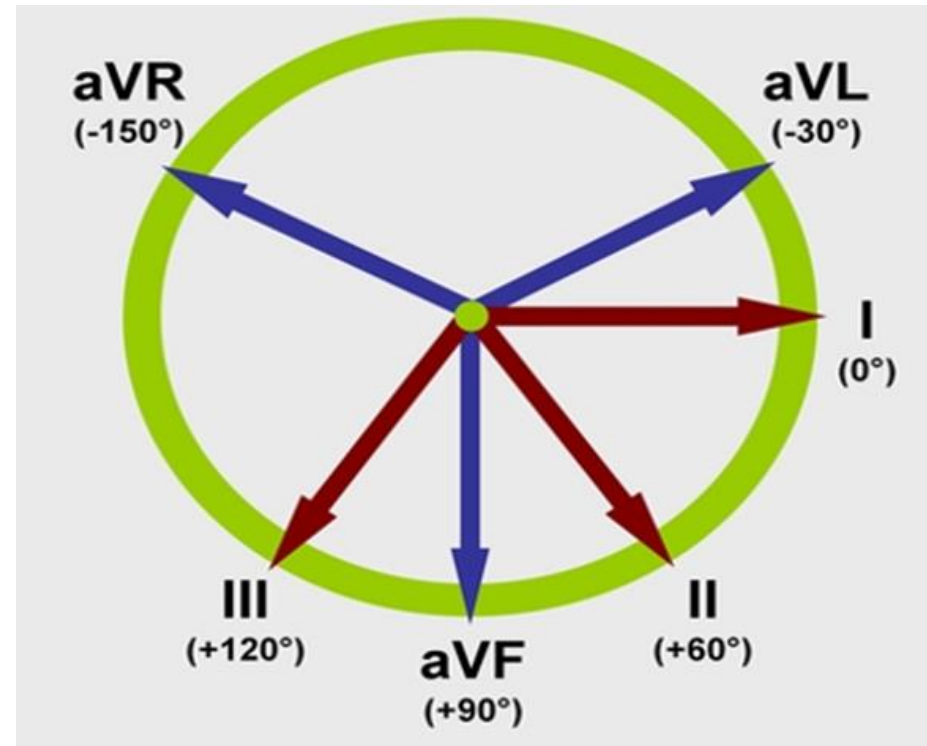
- The cardiac axis refers to the general direction in which the ventricles depolarize. ~ 59 degrees
- Normal cardiac axis can swing from - 30 degrees to 90 degrees, due to anatomical differences in the Purkinje distribution system or in the musculature itself.
- The axis varies normally with age & body built
- Some pathological conditions can cause axis deviation
- Any two limb leads can be used to determine the axis.
- There are a number of ways via which a cardiac axis can be determined using an ECG and the hexagonal reference system.

# Hexagonal reference system

For each limb lead the direction from the negative electrode to the positive electrode of that lead is called the “**axis**” of the lead.

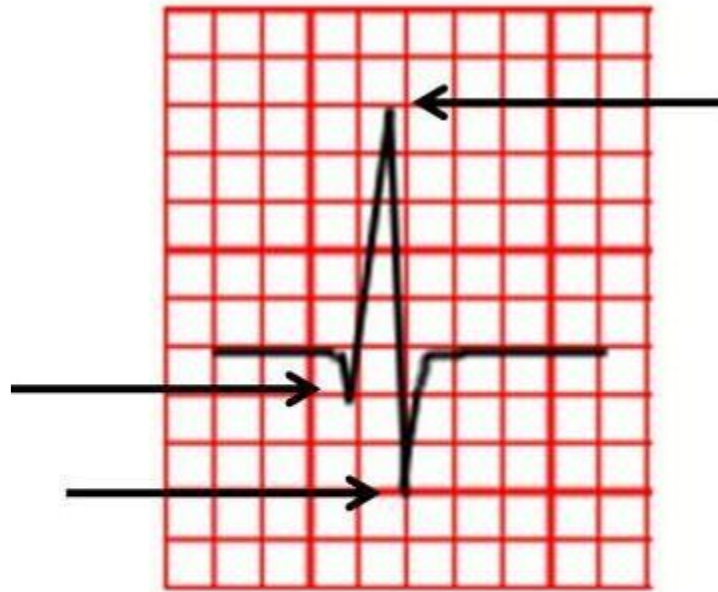
The upper half of the circle is negative and the lower part is positive

1. Lead I and aVF are perpendicular to each other.
2. Lead II and aVL are perpendicular to each other.
3. Lead III and aVR are perpendicular to each other.



# Calculating The Net QRS Potential(deflection)

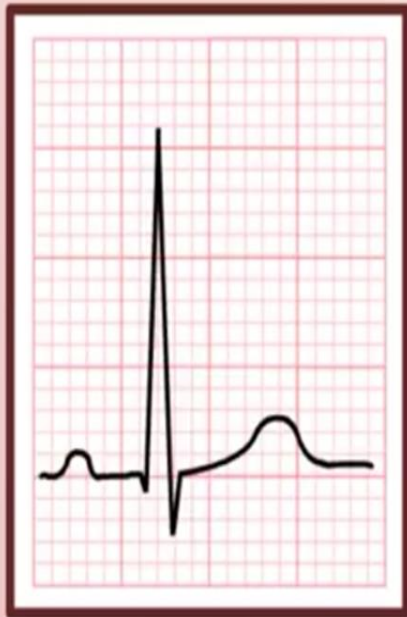If the recording is mostly positive but has some negative potential, this negative potential is subtracted from the positive part of the potential to determine the **net potential** for that lead and vice versa.



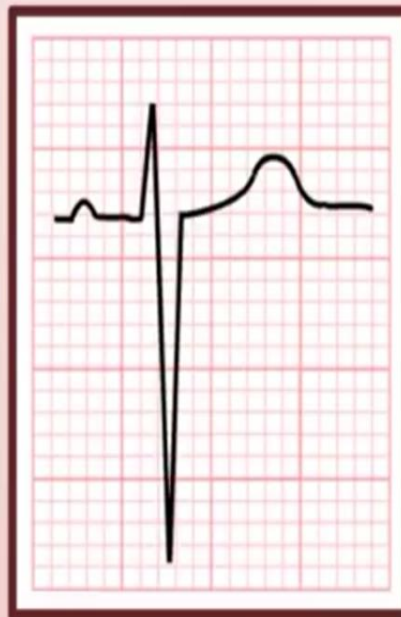
$$\begin{aligned}\text{Net deflection} &= 0.5 + (-0.3) + (-0.1) \\ &= +0.1 \text{ mV OR } 1\text{mm}\end{aligned}$$

**Voltage of the QRS complex** is measured from the peak of the R wave to the bottom of the S or Q wave. In the above example it is 0.8 mV

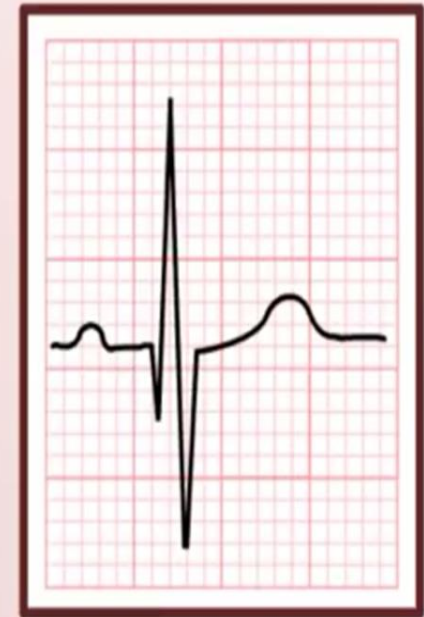



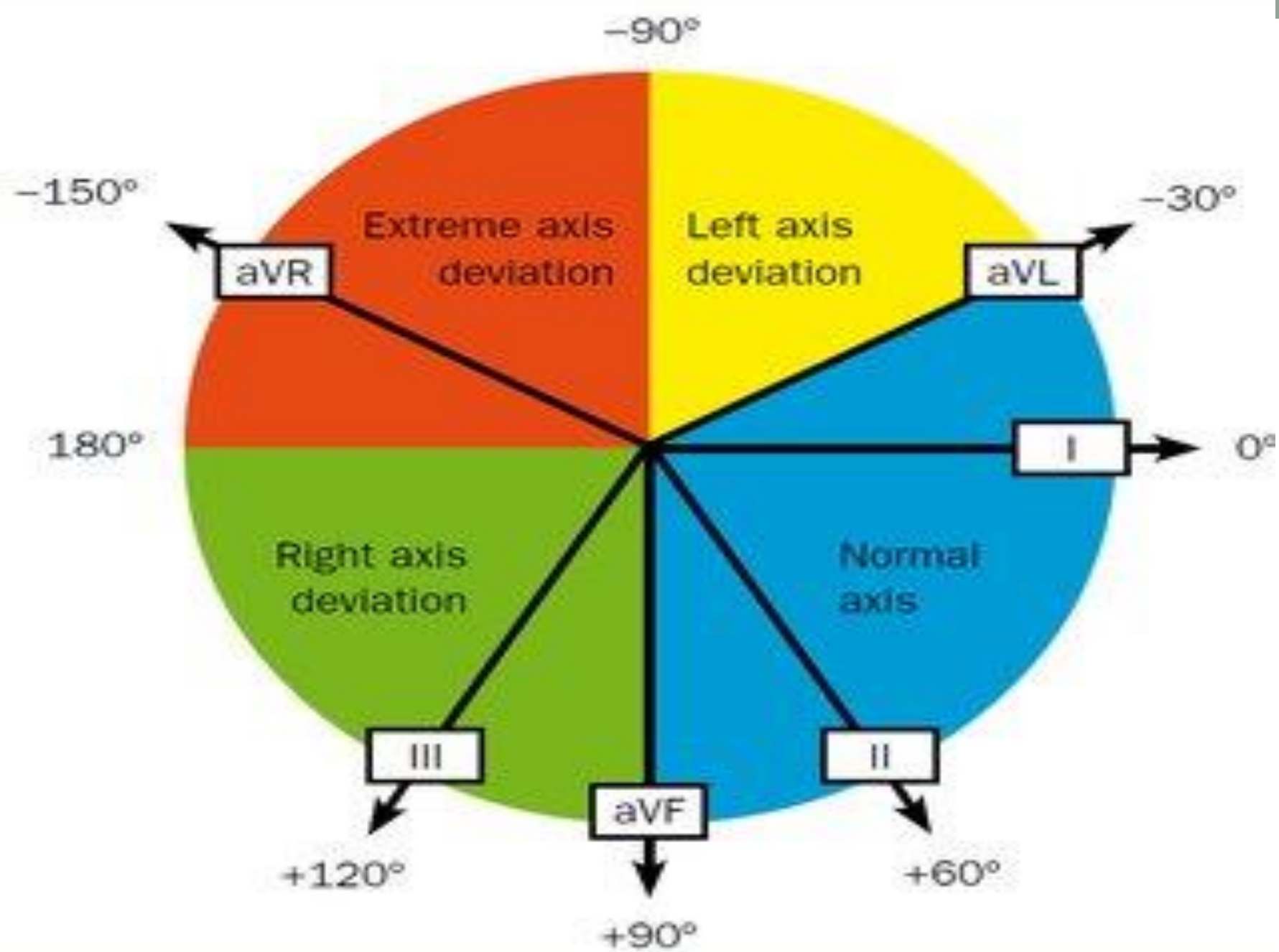
**Predominantly  
Positive**



**Predominantly  
Negative**



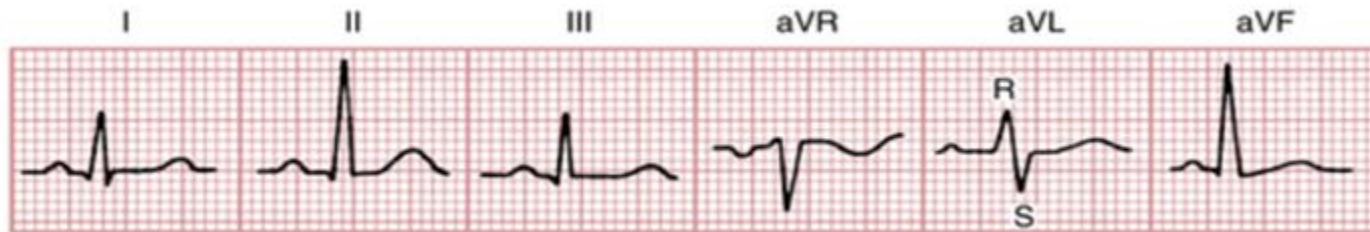**“Isoelectric”**




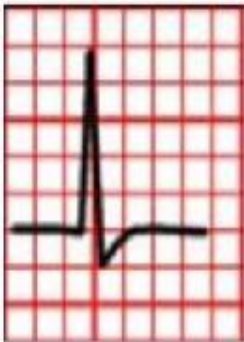







## Quadrant Method (Qualitative)

Lead I	Lead aVF	AXIS
Positive	Positive	Normal
Positive	Negative	Left Axis Deviation or Normal
Negative	Positive	Right Axis Deviation
Negative	Negative	Extreme Axis Deviation (marked left or right axis)

To further distinguish normal from left axis deviation When Lead I is positive & Lead aVF is negative we look at lead II. If lead II negative, then the cardiac axis is more towards  $-120$ , and left axis deviation is present. If the QRS complex in lead II is positive, then the cardiac axis is more towards  $+60$  degrees, and the cardiac axis is normal.

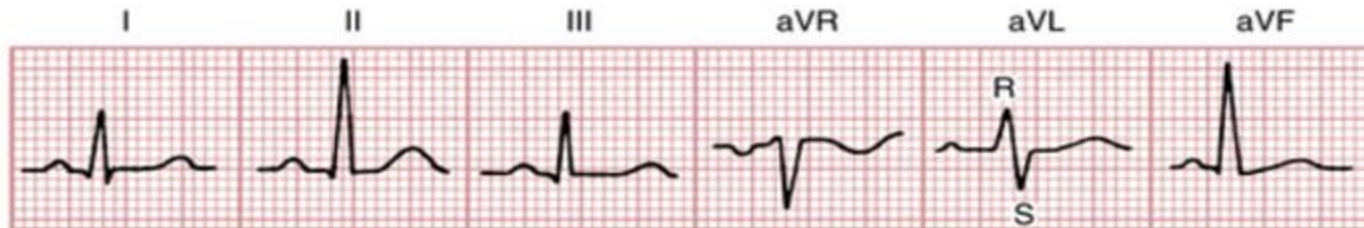

In the example above both lead I and aVF are positive so the axis is normal

	Lead I	Lead aVF	Description	Interpretation	Axis
ECG#1			Leads I and aVF equally positive. The axis will be midway between $0^{\circ}$ and $90^{\circ}$ .	Normal axis $\sim 40^{\circ}$ - $50^{\circ}$	
ECG#5			Lead I negative. Lead aVF positive. The axis will be oriented positively past $90^{\circ}$ .	Right axis deviation $\sim -120^{\circ}$	
ECG#6			Both leads I and aVF negative. The axis will be oriented between $-90^{\circ}$ and $-180^{\circ}$ .	Extreme Axis $\sim -135^{\circ}$	

# The isoelectric lead method

1. Find the isoelectric lead; it has zero net amplitude. This can be either:
  - A biphasic QRS where R wave height = Q or S wave depth.
  - A flat-line QRS with no discernible features.
2. Look for the lead perpendicular to the isoelectric lead. If the QRS complex in this lead is predominantly positive, the cardiac axis will be located in its direction; if the QRS is predominantly negative, the cardiac axis will be located on the opposite direction



In the above example, the most isoelectric lead is aVL. Lead II is perpendicular to it. Lead II is positive so the cardiac axis must be in its direction which is 60 degrees. So the axis is normal.

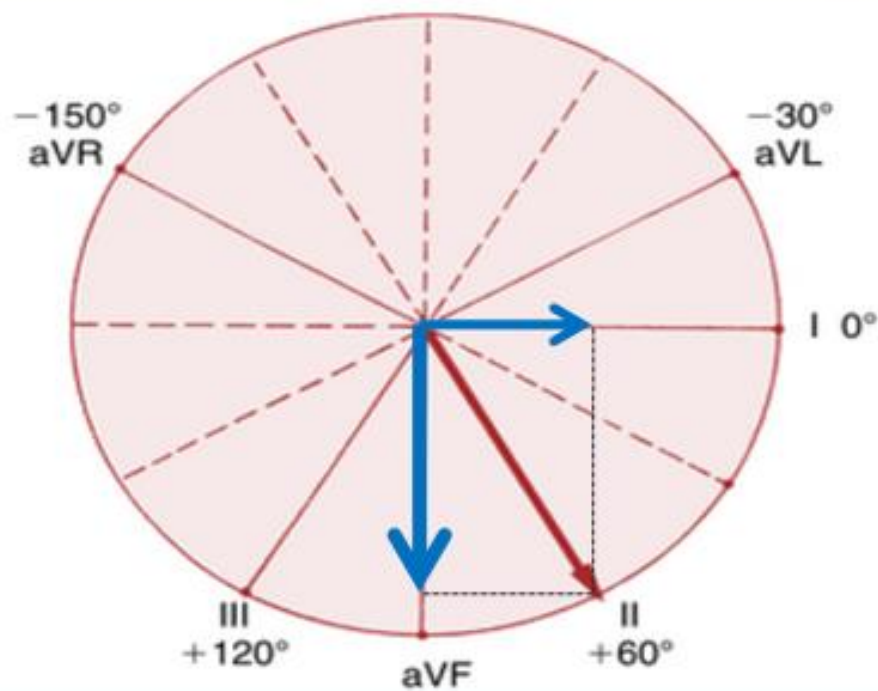
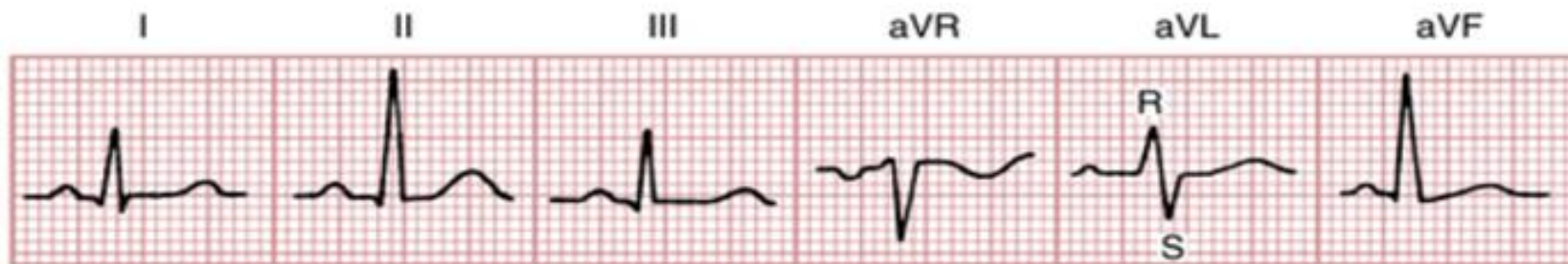

# Mathematical method

- Calculating the Axis:
  1. Record the bipolar and augmented limb leads
  2. Determine the net potential and polarity of the recordings in leads I and aVF.
  3. The net potential for leads I and aVF is plotted on the axes of the respective leads, with the base of the potential at the point of intersection of the axes. If the net potential of the lead is positive, it is plotted in the positive direction. Conversely, if this potential is negative, it is plotted in a negative direction.
  4. Draw perpendicular lines from the apices of leads I and aVF potentials. The point of intersection of these two perpendicular lines represents the apex of the mean QRS vector in the ventricles, and the point of intersection of the lead I and lead aVF axes represents the negative end of the mean vector. Therefore, the mean QRS vector is drawn between these two points.
  5. To determine the axis, measure the angle created by the vector using a **protractor** or use the tangent rule

The tangent of the angle =  $\frac{\text{the length of the opposite side}}{\text{the length of the adjacent side}}$

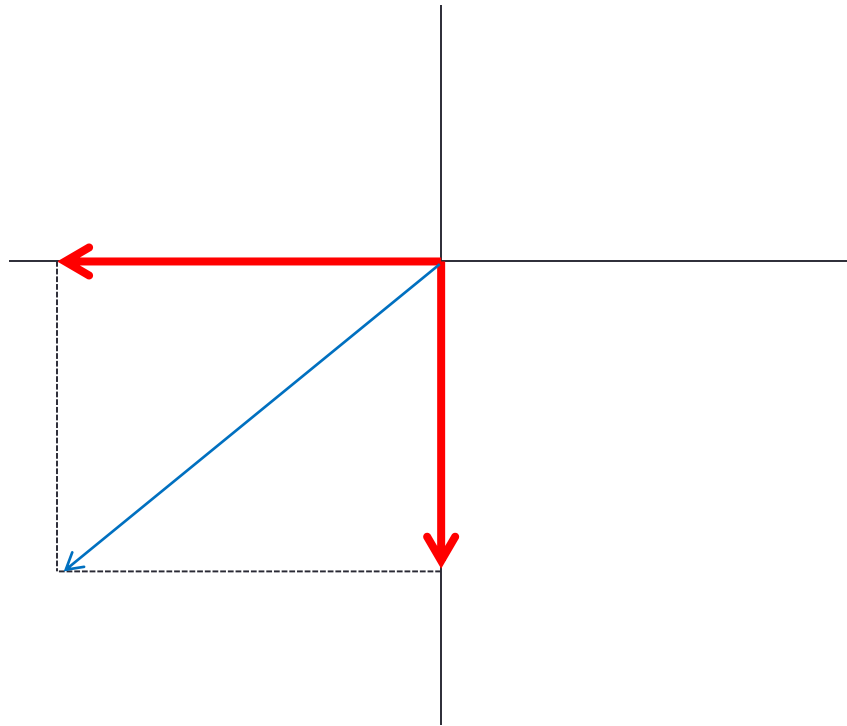
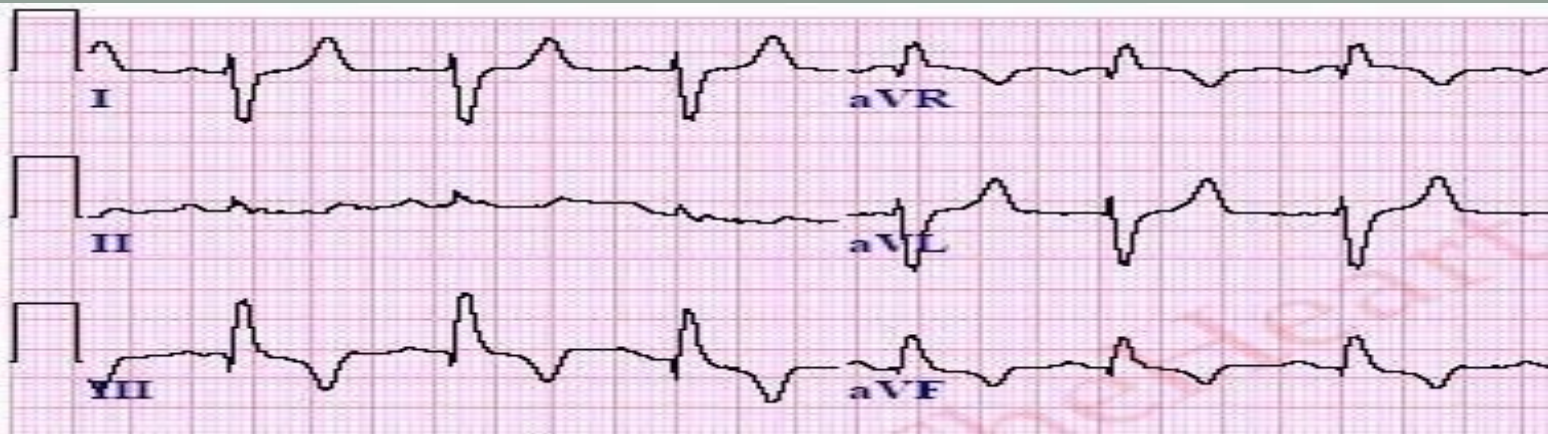




Lead I = 5mm

Lead aVF = 10mm

The angle of the calculated axis is 60°, So this is a normal axis



Lead I = -6mm

Lead aVF = 5mm

Angle is 140 so this is Right Axis deviation

# Ventricular Conditions That Cause Axis Deviation

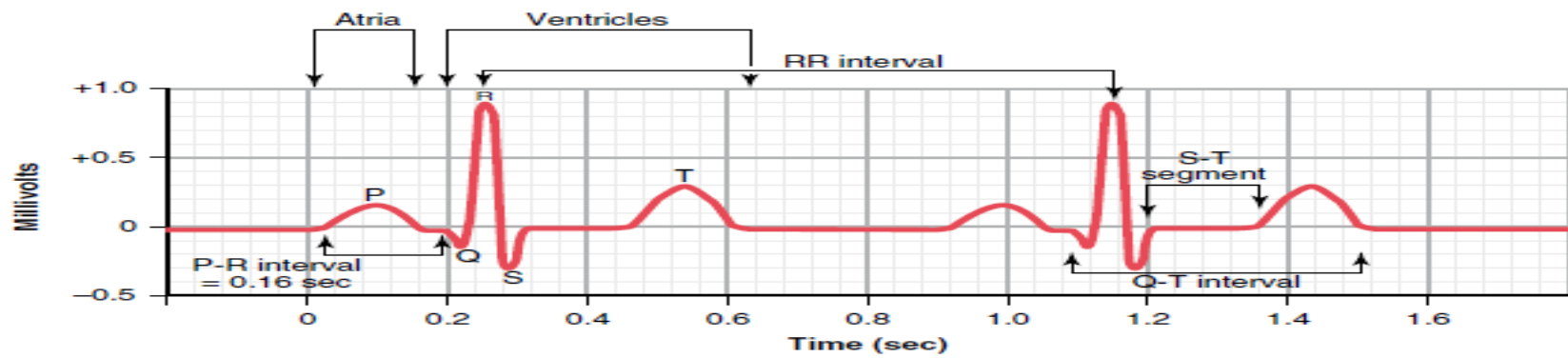
- Change in the Position of the Heart in the Chest.
  - Conditions that cause left angulation of the heart and left axis deviation:
    1. Deep expiration
    2. Lying down
    3. Obesity
  - Conditions that cause right angulation of the heart and right axis deviation:
    1. Deep inspiration
    2. Standing up
- Hypertrophy of One Ventricle
- Bundle branch block

# Hypertrophy of One Ventricle

- When one ventricle greatly hypertrophies, the axis of the heart shifts toward the hypertrophied ventricle, because:
  1. Greater quantity of muscle exists on the hypertrophied side of the heart which allows generation of greater electrical potential on that side.
  2. More time is required for the depolarization wave to travel through the hypertrophied ventricle.  
Consequently, the normal ventricle becomes depolarized in advance of the hypertrophied ventricle.

# Bundle branch block

- Left bundle branch block
- When the left bundle branch is blocked, cardiac depolarization spreads through the right ventricle greatly ahead of the left ventricle. This leads to left axis deviation and widening of the QRS complex.
- Right bundle branch block
- When the right bundle branch is blocked, cardiac depolarization spreads through the left ventricle greatly ahead of the right ventricle. This leads to right axis deviation and widening of the QRS complex

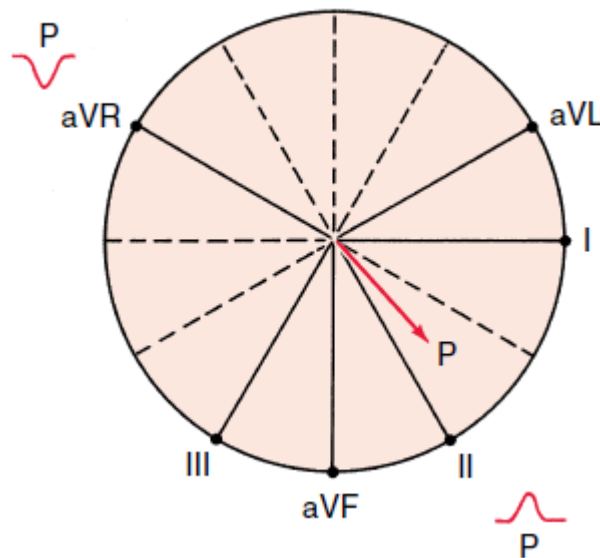


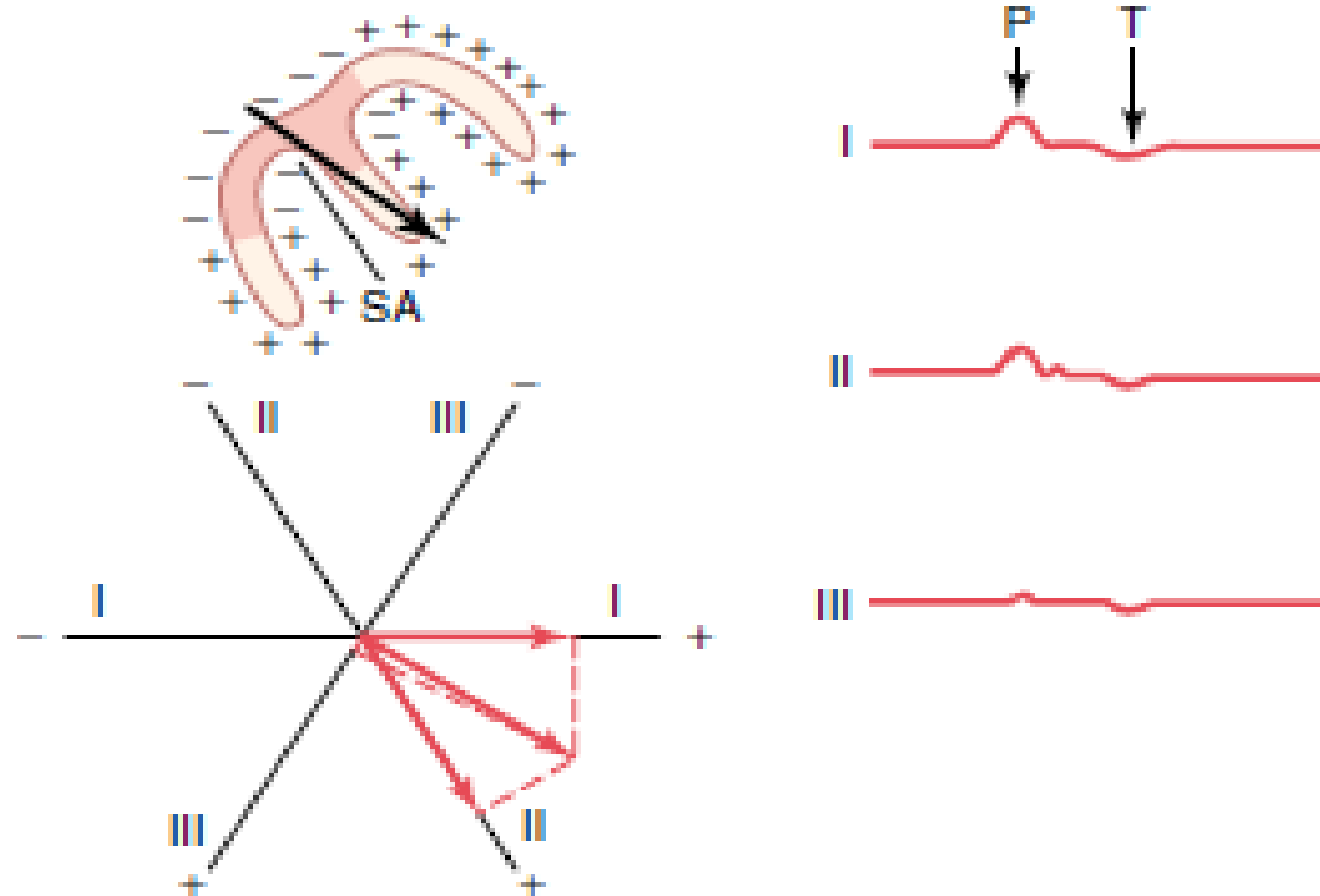
- The waves, intervals & segments of the ECG
  - P wave
  - QRS complex
  - T wave
  - PR interval
  - QT interval
  - ST segment



# P wave

- Represents Atrial depolarization
- The axis of atrial depolarization is 70 degrees. When sinus rhythm is present, the P waves are always negative in lead aVR and positive in lead II.
- The maximum height of the P wave is 2.5-3 mm.
- The P wave duration is shorter than 0.12 sec.



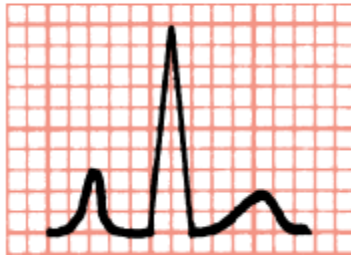


**Figure 12-9** Depolarization of the atria and generation of the P wave, showing the maximum vector through the atria and the resultant vectors in the three standard leads. At the right are the atrial P and T waves. SA, sinoatrial node.

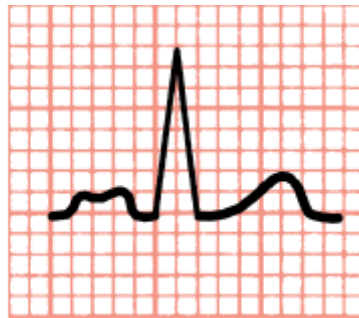
# P wave Abnormalities

- Right atrial enlargement results in a P wave that is peaked, higher and narrower than usual called **P Pulmonale**

**Right Atrial Abnormality (Overload)**

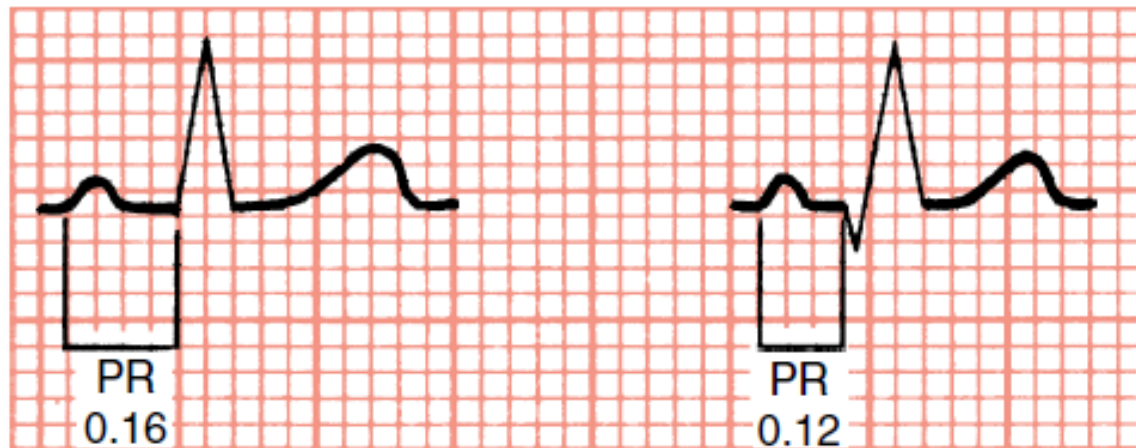


- Left atrial enlargement results in a notched P wave with prolonged duration called **P Mitrale**



# PR interval

- The PR interval is measured from the beginning of the P wave to the beginning of the QRS complex
- The normal PR interval is 0.12–0.2 seconds
- Short PR interval :
  - Abnormally fast conduction from the atria to the ventricles
- Long PR interval:
  - First degree heart block

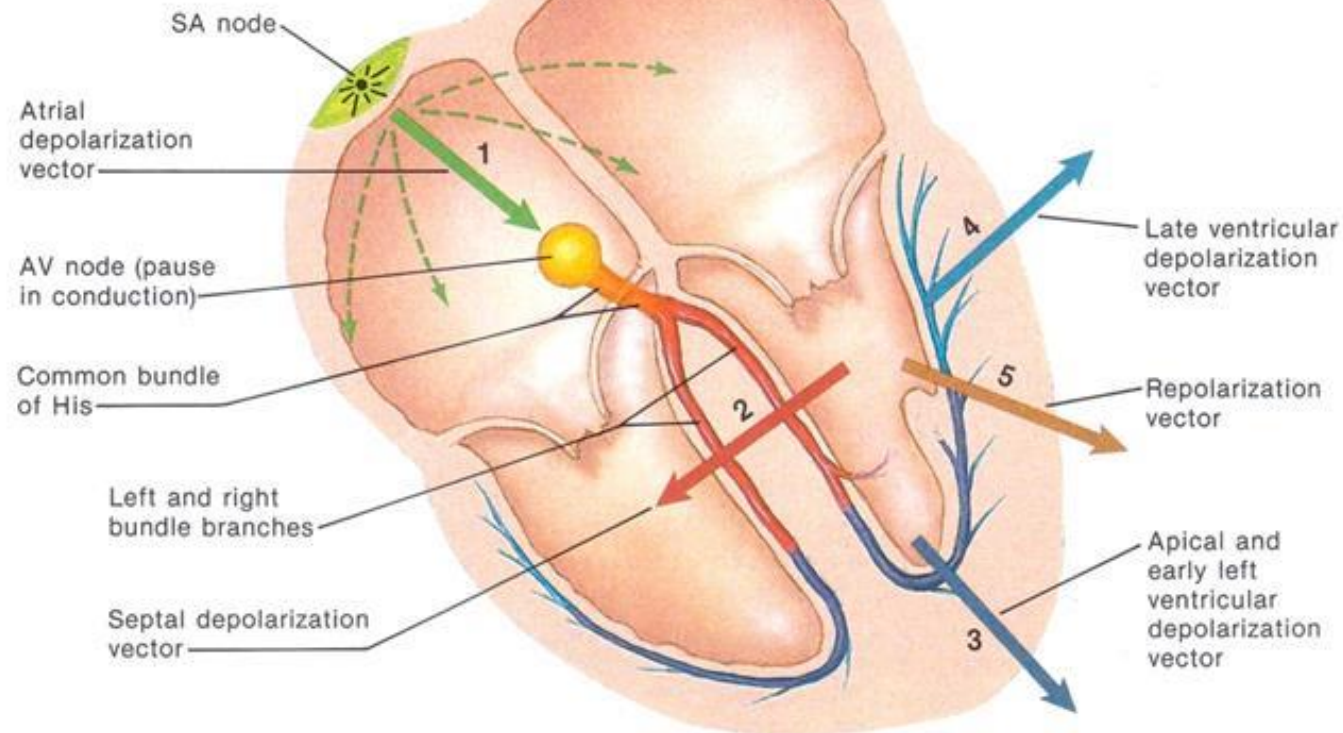


# QRS complex

- Q wave is the first negative deflection
- R wave is the first positive deflection
- S wave is any negative deflection following R wave.
- QRS Duration: 0.06 - 0.1 sec
- Normally, the voltages in the three standard bipolar limb leads vary between 0.5 and 2.0 millivolts,
- When the sum of the voltages of all the QRS complexes of the three standard leads is greater than 4 millivolts, the patient is considered to have a high-voltage electrocardiogram.

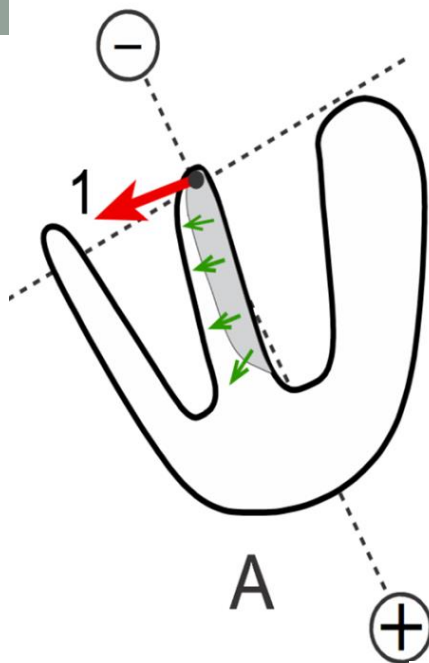
## F. Summary of cardiac electrical activity

*F. Netter M.D.*  
© CIBA

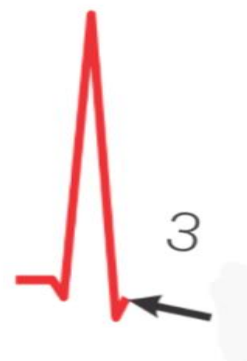
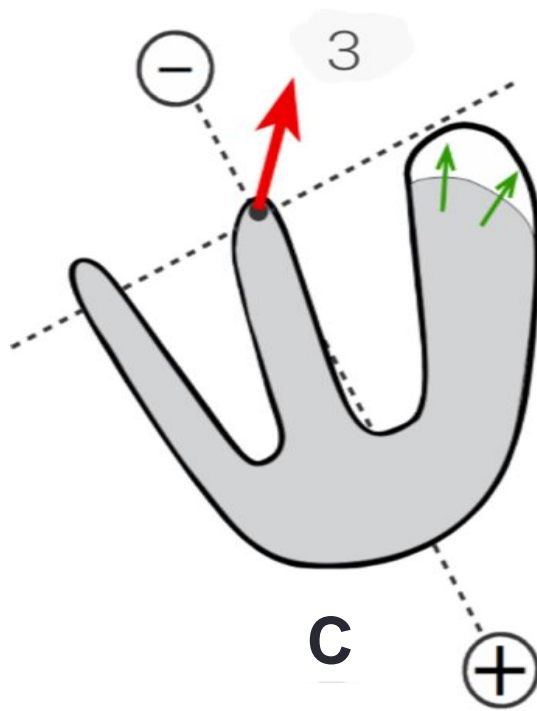
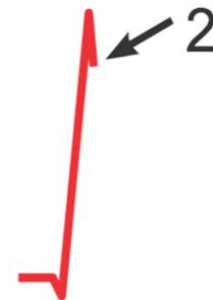
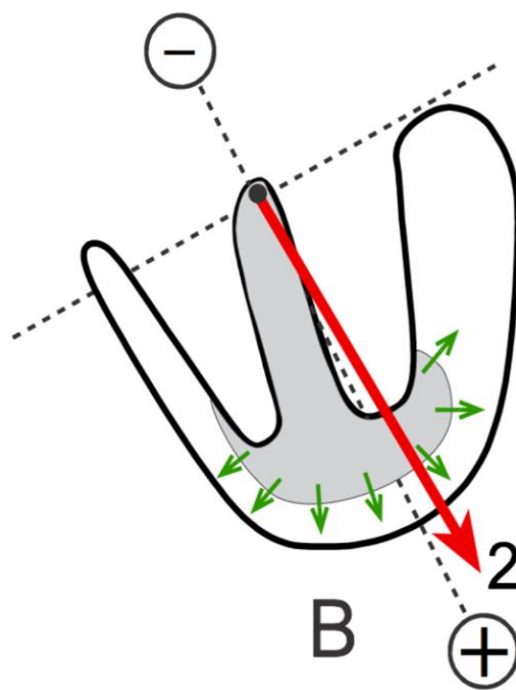


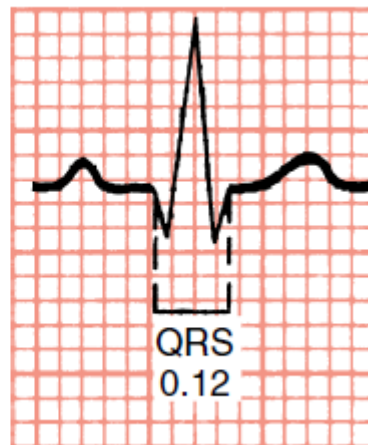
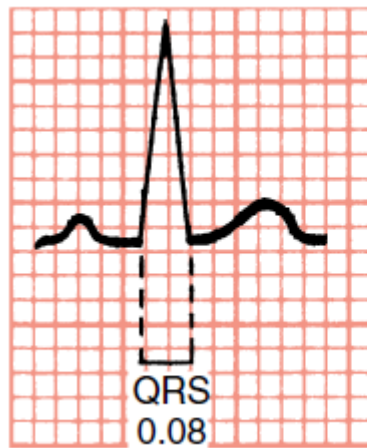
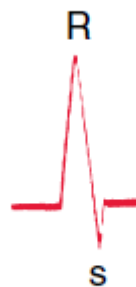
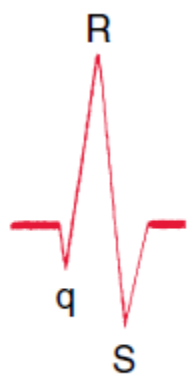
QRS axis is a summation of all vectors during ventricular depolarization





QRS Complex  
Lead II



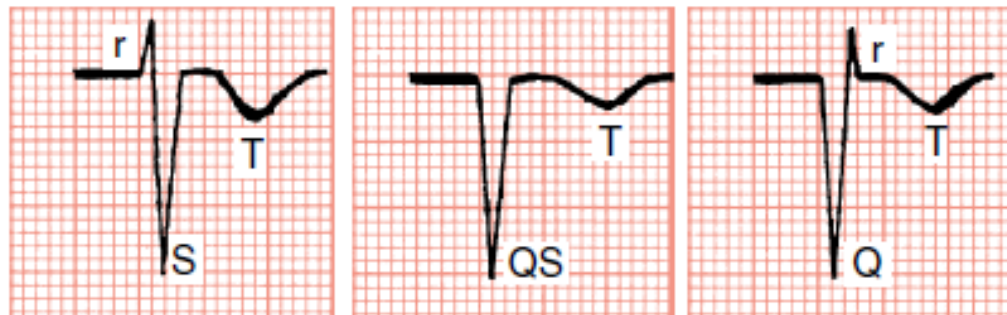


# QRS complex in limb leads

Limb leads in normal ECGs can show a variable QRS pattern.

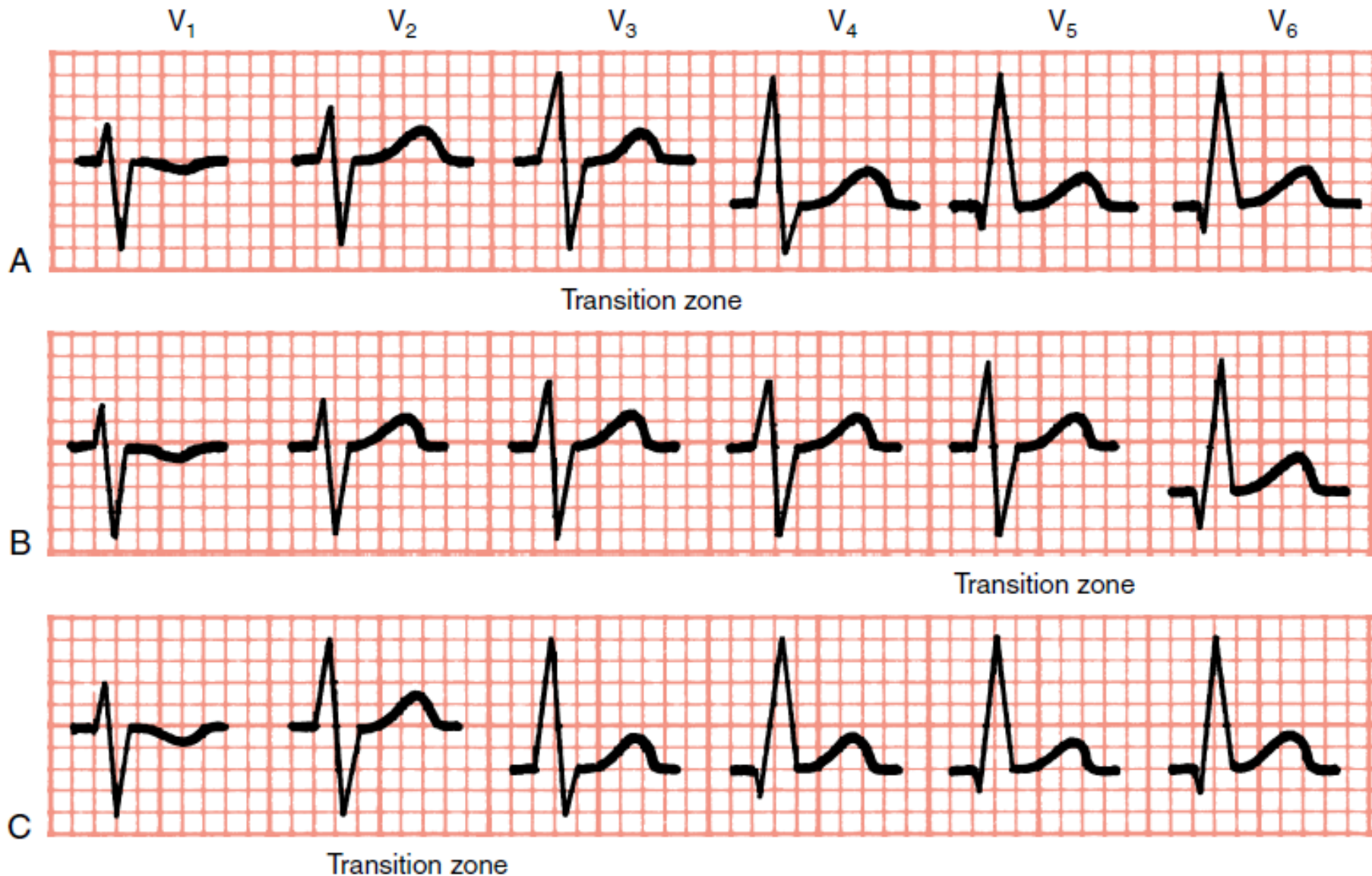
Lead aVR normally always records a predominantly negative QRS complex.

The QRS patterns in the other limb leads vary depending on the electrical position (QRS axis) of the heart.



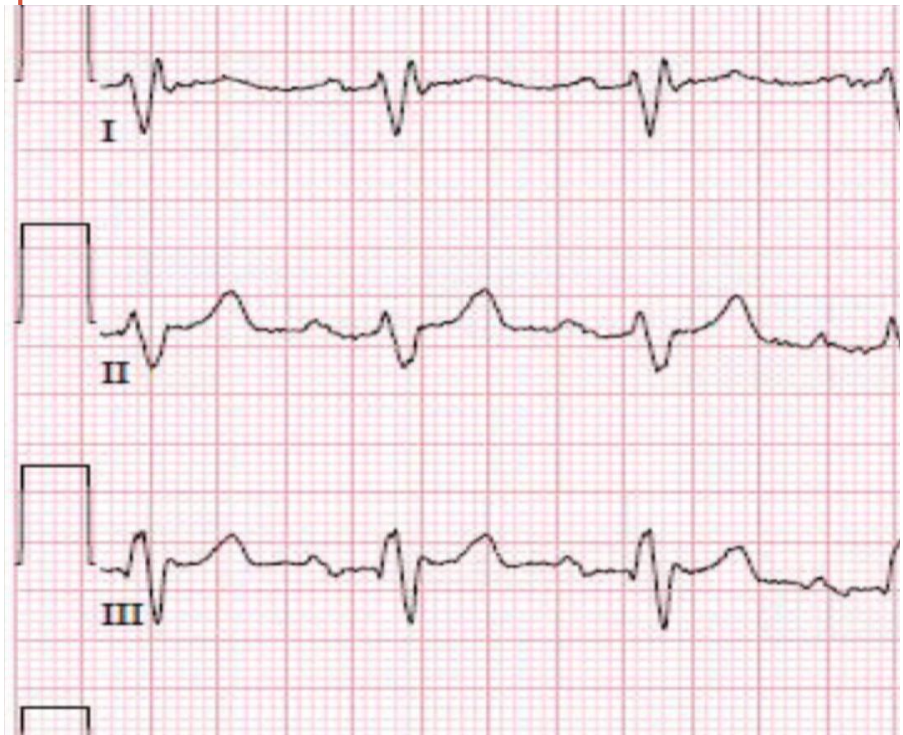**Figure 4-9.** Lead aVR normally shows one of three basic negative patterns: an rS complex, a QS complex, or a Qr complex. The T wave also is normally negative.

# QRS complex progression in chest leads



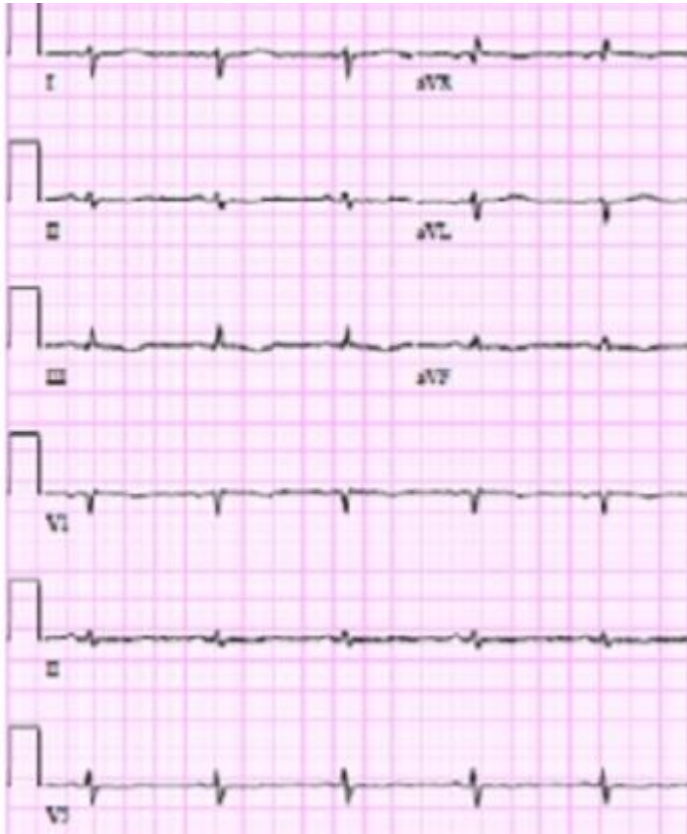# QRS Abnormalities

- Increased QRS width:
  - Cardiac hypertrophy or dilatation
  - Bundle branch block, in this case the QRS duration  $> 0.12$  sec



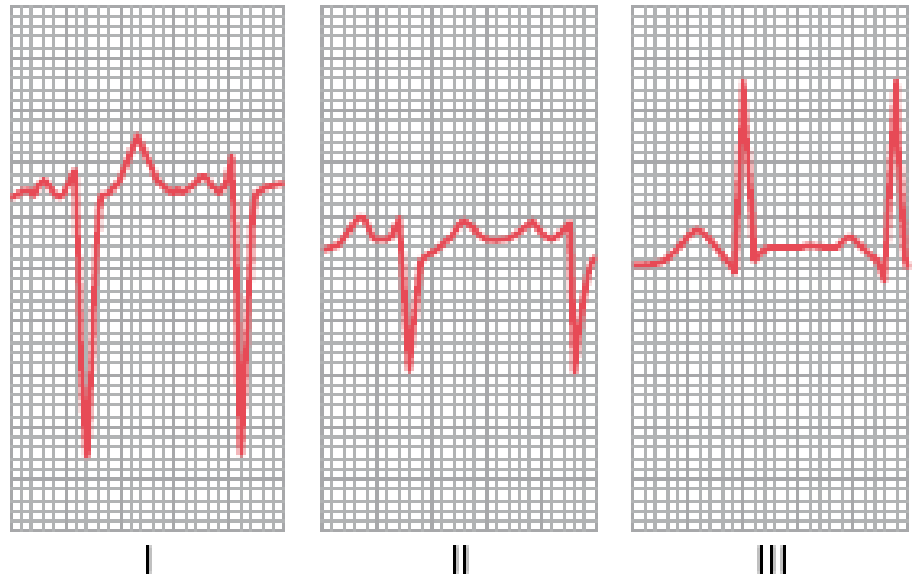
➤ Low voltage:

- Old myocardial infarctions
- Pericardial or pleural effusion



➤ High voltage :

- Cardiac hypertrophy

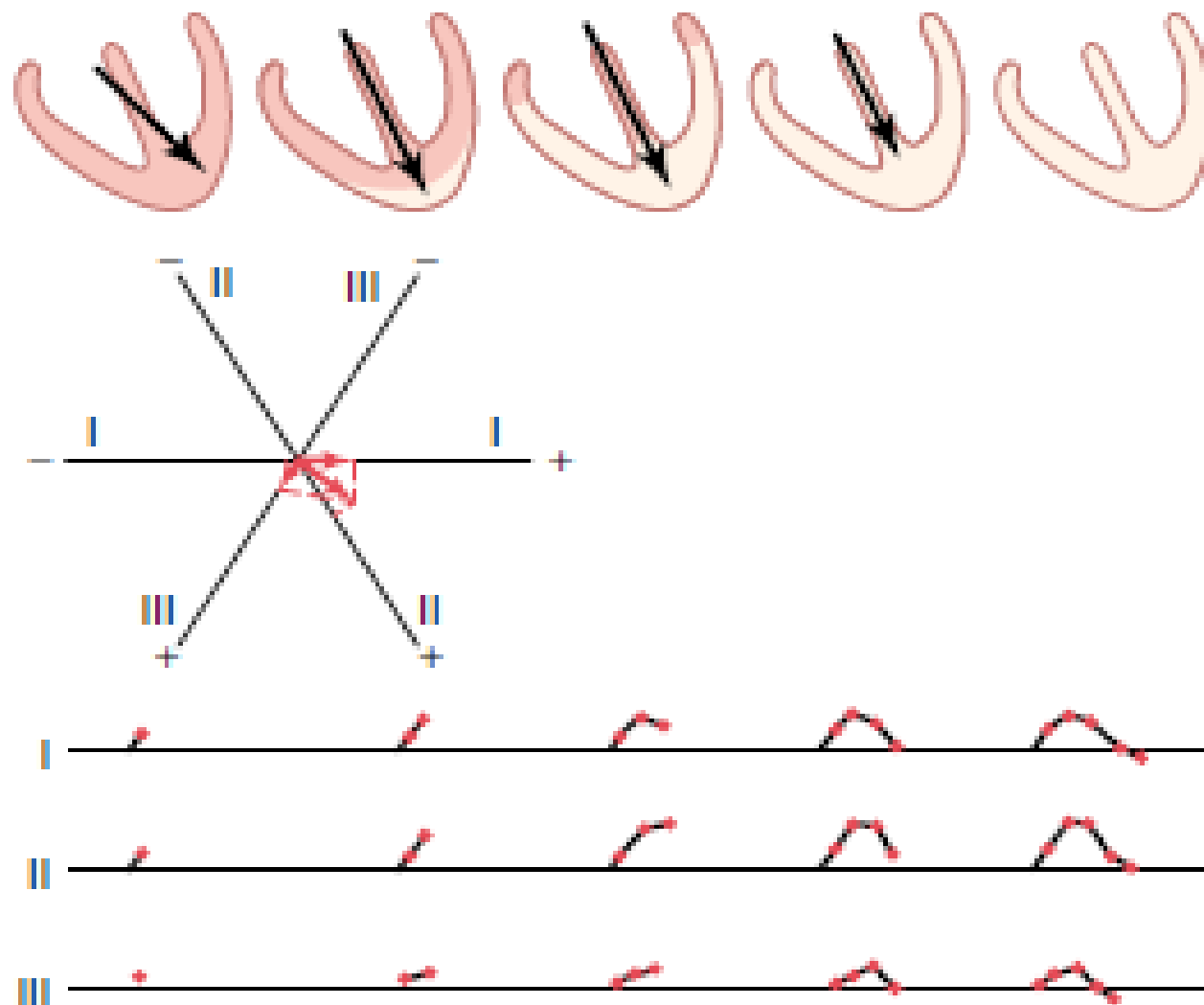




# T wave

- The outer surface of the ventricles, especially near the apex of the heart is the first to repolarize, and the endocardial areas repolarize last.
- The overall ventricular vector during repolarization is towards the apex of the heart.
- T wave deflection should be in the same direction as the QRS complex
- In normal adults, the T wave is usually upright in all leads, except the aVR and V1 leads
- Normally rounded and asymmetrical with a rounded peak.
- When compared to QRS complex it has longer duration and lower voltage. Because repolarization occurs slower than depolarization.
- The height of the T wave should not exceed 5 mm in limb leads and 10 mm in chest leads

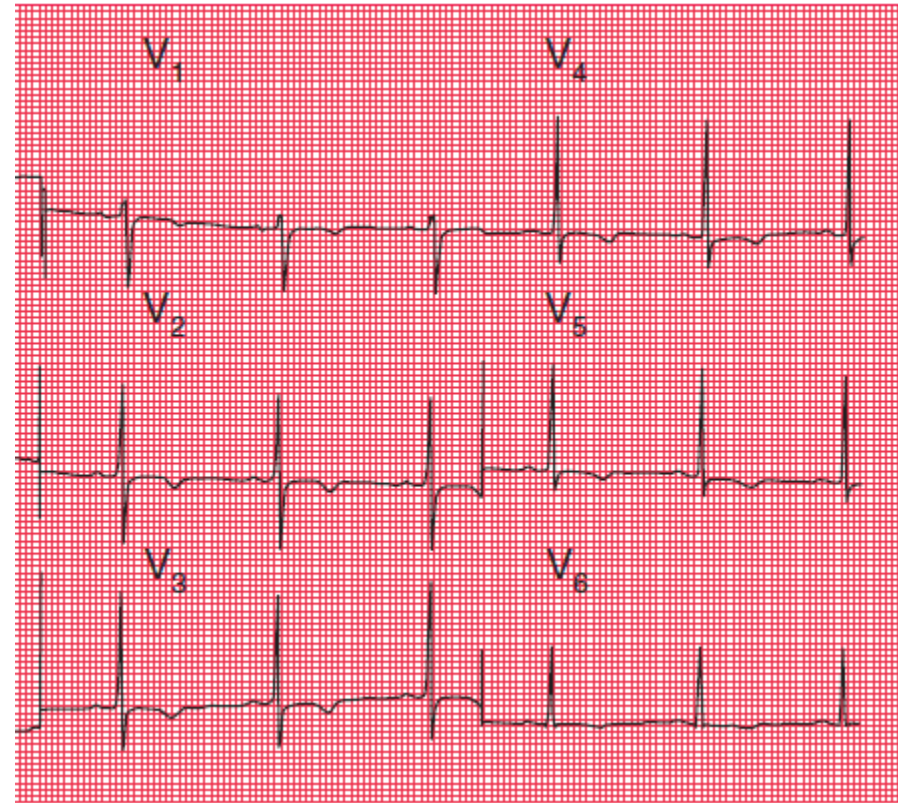




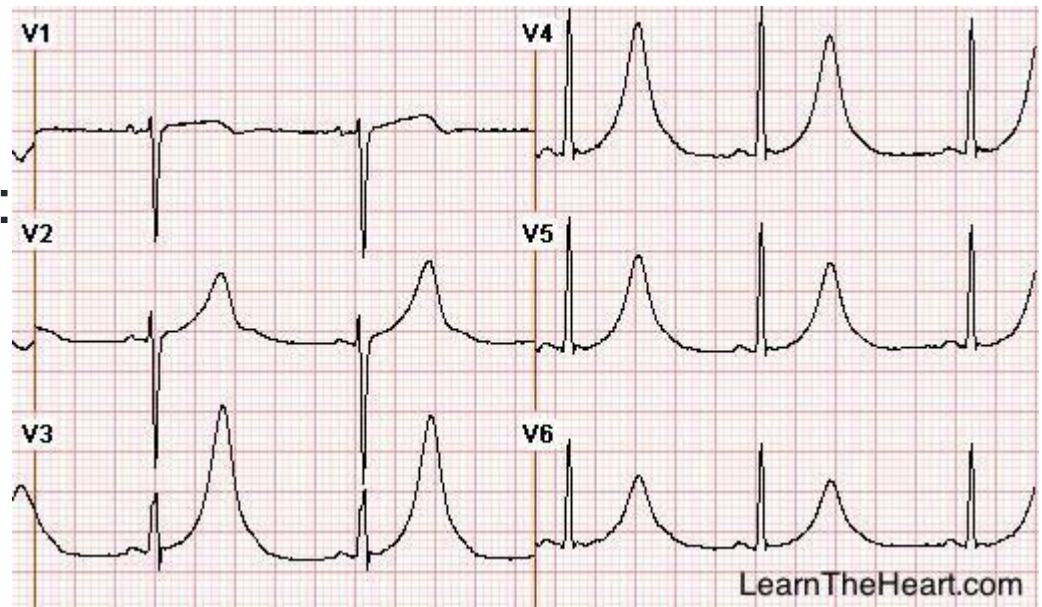
**Figure 12-8** Generation of the T wave during repolarization of the ventricles, showing also vectorial analysis of the first stage of repolarization. The total time from the beginning of the T wave to its end is approximately 0.15 second.

# T wave abnormalities

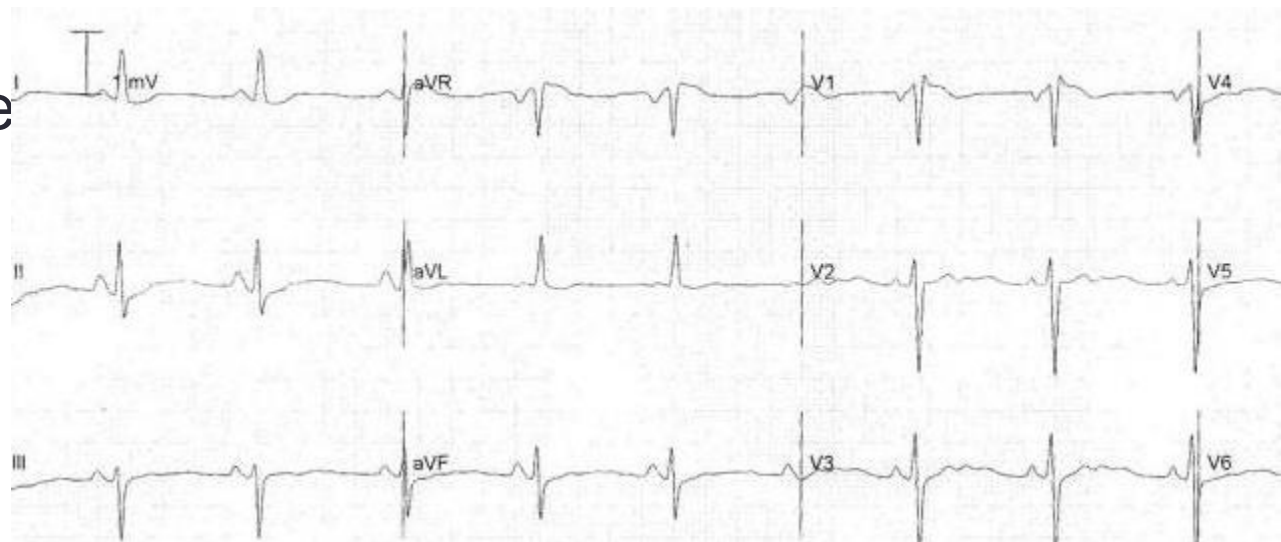
- T wave inversion:
  1. Mild ischemia
  2. Ventricular hypertrophy
  3. Bundle Branch Block
  4. Digoxin Toxicity
  5. Normal finding in aVR & V1



- Peaked & tall T waves:
  1. Early stages of myocardial infarction
  2. Hyperkalemia



- Flattened T Wave
  1. Hypokalemia
  2. Ischemia

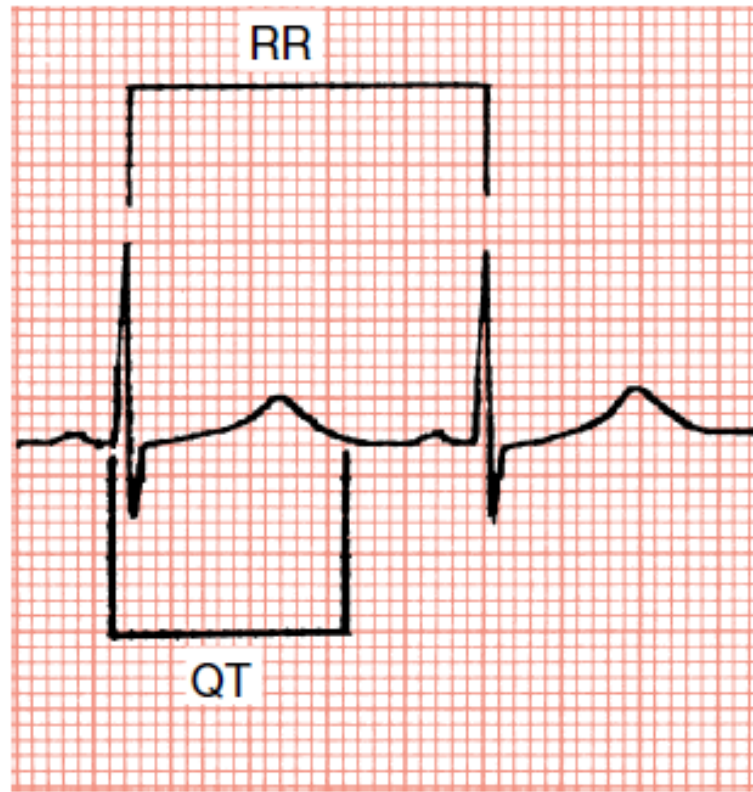


# QT interval

- The time from the beginning of the QRS complex to the end of the T wave
- Should be less than 0.44 seconds
- QT interval is inversely correlated with heart rate so it must be corrected for heart rate.
- The corrected QT interval is calculated using the following formula:

$$\text{QT corrected} = (\text{QT observed}) / (\text{square root of RR interval})$$

- Prolonged QT interval is seen in Long QT syndrome, hypokalemia, hypercalcemia & hypothyroidism.



QT = 0.6 sec

RR = 0.92

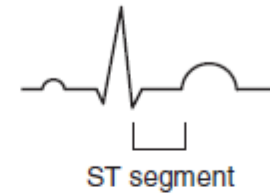
QTc = 0.63

# ST segment

- Extends from the end of the QRS complex to the beginning of the T wave
- Should be isoelectric
- Compare it to the T-P segment
- Should be checked in all leads
- Depressed or raised in ischemia or myocardial infarction
- To be considered significant , more than 1 mm of ST segment elevation/depression in at least two contiguous limb leads (e.g. I and VL; III and VF), or more than 2 mm of ST segment elevation/depression in at least two contiguous precordial leads

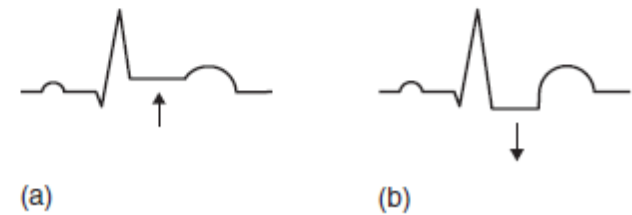
**Fig. 4.12**

**The ST segment**



**Fig. 4.13**

**(a) Elevated ST segment. (b) Depressed ST segment**



# How To Report An ECG

- When reporting an ECG the report should include:
  1. The patient's name, age & gender.
  2. The heart rate
  3. Cardiac Rhythm
  4. Cardiac axis
  5. A description of the P waves, QRS complexes,& T waves.
  6. A description of the ST segment.
  7. A description of conduction intervals
- ✓ Don't forget to check the speed of ECG record & the voltage calibration

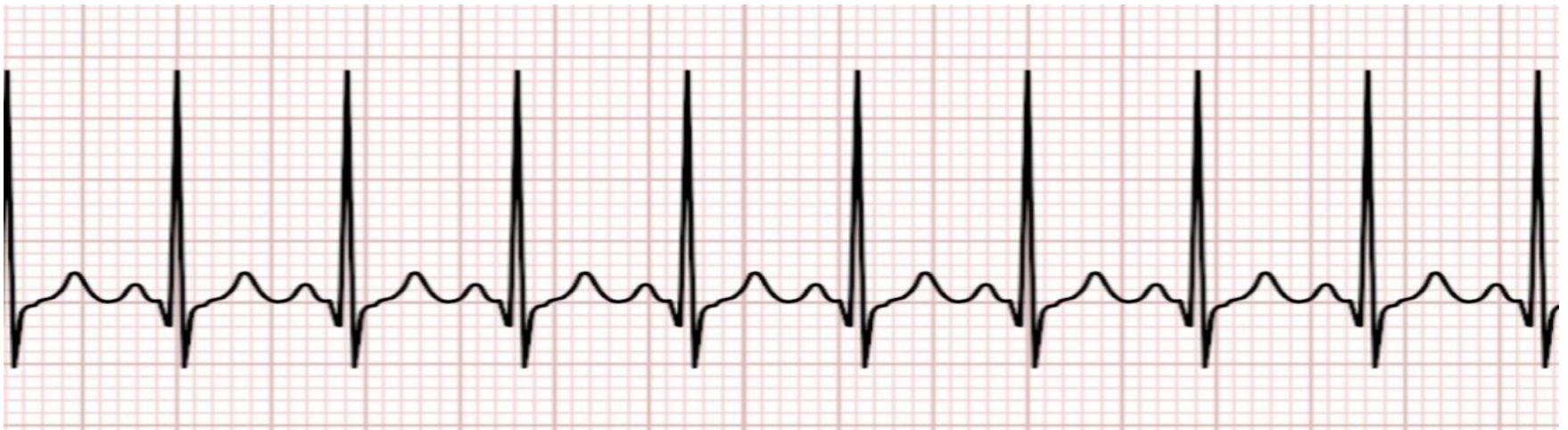


# Arrhythmias

- An abnormal heart rhythm.
- Might be associated with tachycardia or bradycardia
- The causes of the cardiac arrhythmias are usually one or a combination of the following abnormalities in the rhythmicity-conduction system of the heart:
  1. Abnormal rhythmicity of the pacemaker
  2. Shift of the pacemaker from the sinus node to another place in the heart
  3. Blocks at different points in the spread of the impulse through the heart
  4. Abnormal pathways of impulse transmission through the heart
  5. Spontaneous generation of spurious impulses in almost any part of the heart

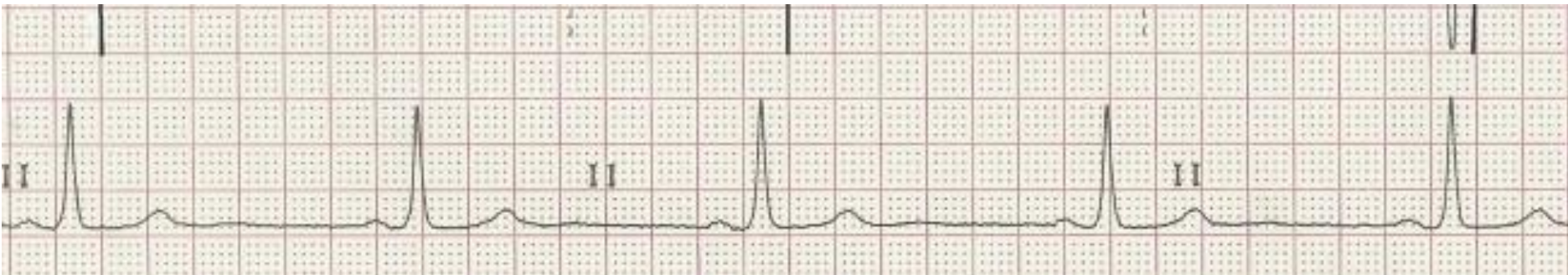# Sinus Tachycardia

- Fast heart rate above 100 beats per minute (B.P.M) usually caused by increased sympathetic tone in physiological stress, fever, pain, dehydration, hypovolemia, and anemia



# Sinus Bradycardia

- Slow heart rate below 60 B.P.M
- Seen normally in athletes at rest
- Vagal stimulation can trigger bradycardia
- Hypothermia, hypothyroidism, certain drugs like beta blockers

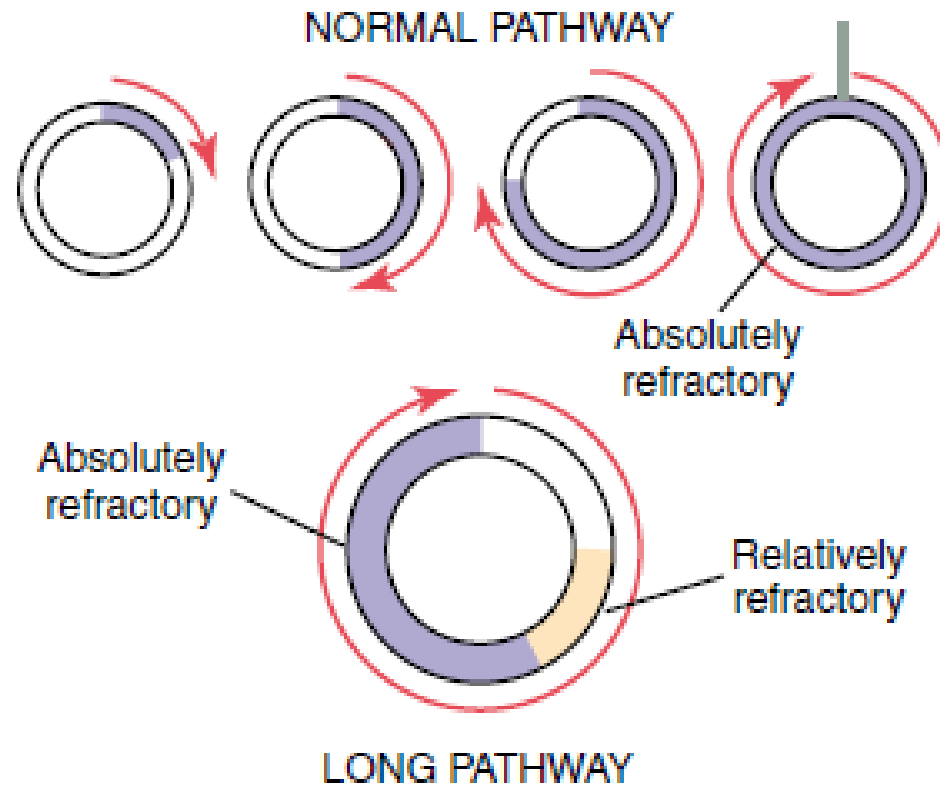


# Ventricular Fibrillation

- The most serious of all cardiac arrhythmias, if not stopped within 1 to 3 minutes, is almost invariably fatal
- Results from cardiac impulses that have gone berserk within the ventricular muscle mass, stimulating first one portion of the ventricular muscle, then another portion, then another, and eventually feeding back onto itself to re-excite the same ventricular muscle over and over never stopping.
- The ventricular muscle contraction is not coordinated. So no pumping of blood occurs.
- Caused by
  1. Sudden electrical shock of the heart
  2. Ischemia of the heart muscle, of its specialized conducting system, or both.
  3. Other forms of arrhythmia

# Phenomenon of Re-entry

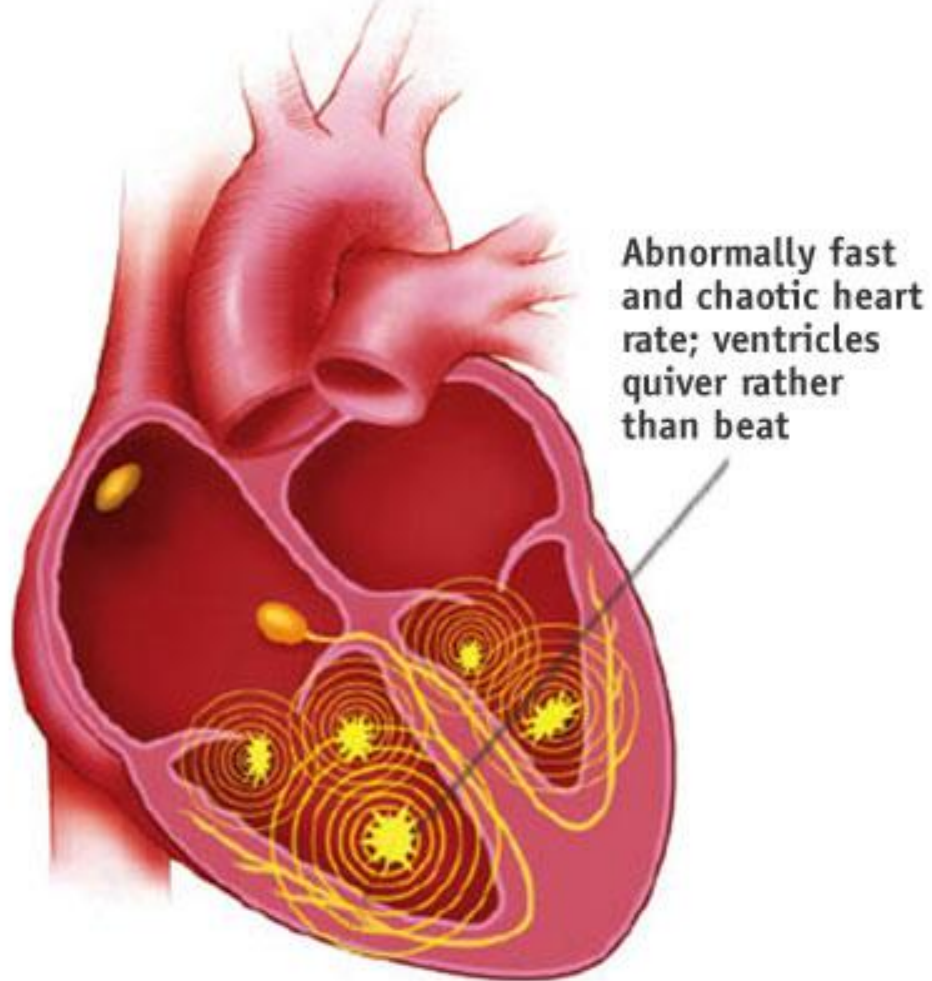
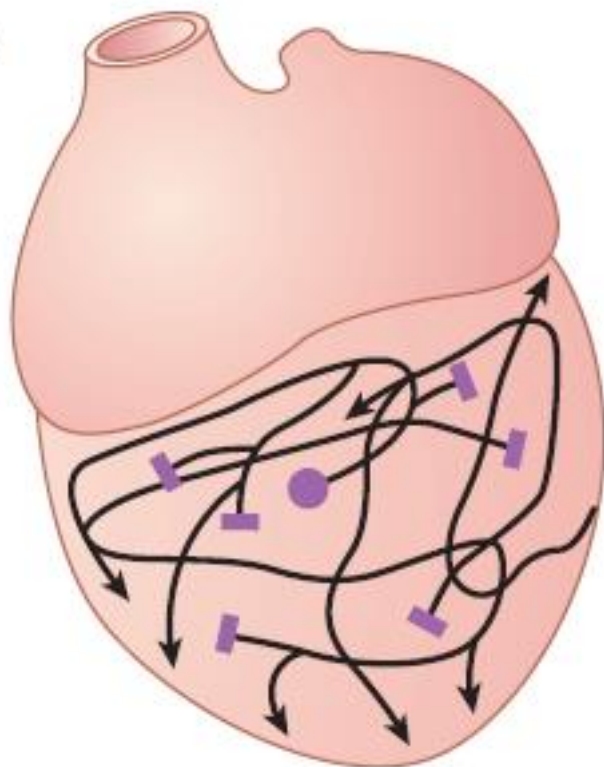
- When the normal cardiac impulse in the normal heart has travelled through the extent of the ventricles, it has no place to go because all the ventricular muscle is in refractory period and cannot conduct the impulse farther. Therefore, that impulse dies, and the heart awaits a new action potential to begin in the sinus node.
- Under some circumstances, however, this normal sequence of events does not occur. This initiates re-entry and lead to “circus movements,” which in turn cause ventricular fibrillation. Causes:
  1. A long pathway, typically occurs in dilated hearts.
  2. Decreased rate of conduction, frequently results from blockage of the Purkinje system, ischemia of the muscle or high blood potassium levels.
  3. A shortened refractory period commonly occurs in response to various drugs, such as epinephrine



**Figure 13-15** Circus movement, showing annihilation of the impulse in the short pathway and continued propagation of the impulse in the long pathway.

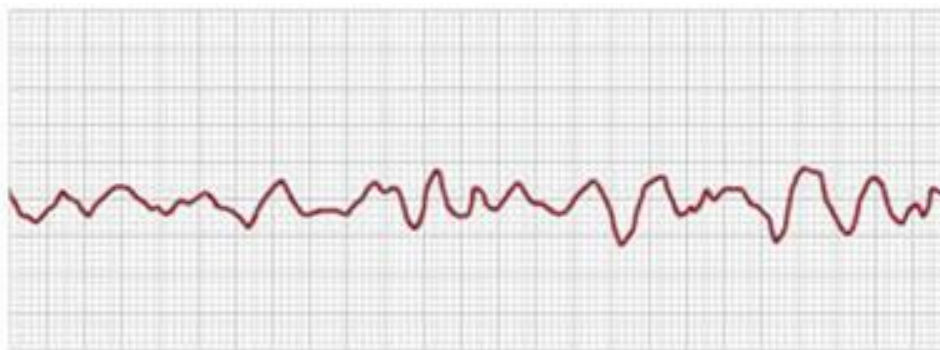


ig  
es


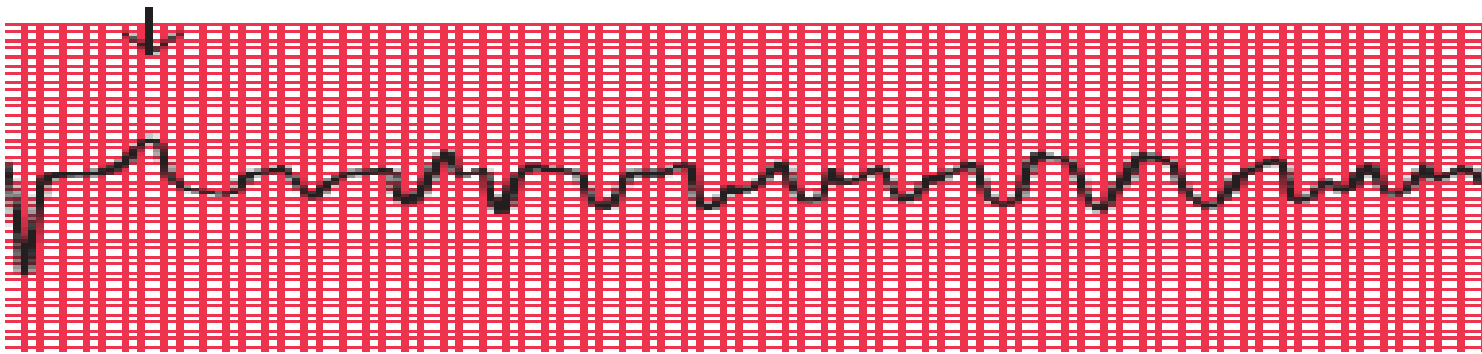


Abnormally fast  
and chaotic heart  
rate; ventricles  
quiver rather  
than beat

**Ventricular Fibrillation ECG**





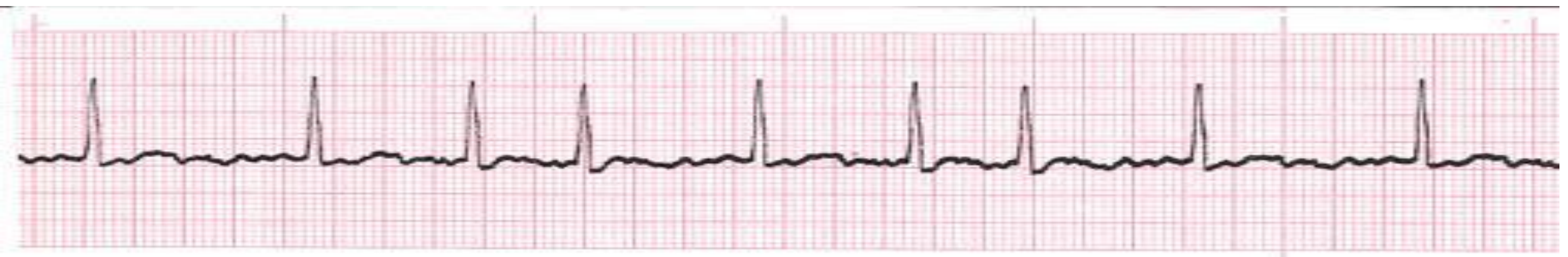

**Figure 13-17** Ventricular fibrillation (lead II).

- ECG is bizarre and shows no regular rhythm of any type.
- Voltages of the waves in the ECG are usually about 0.5 millivolt when ventricular fibrillation first begins, but they decay rapidly.

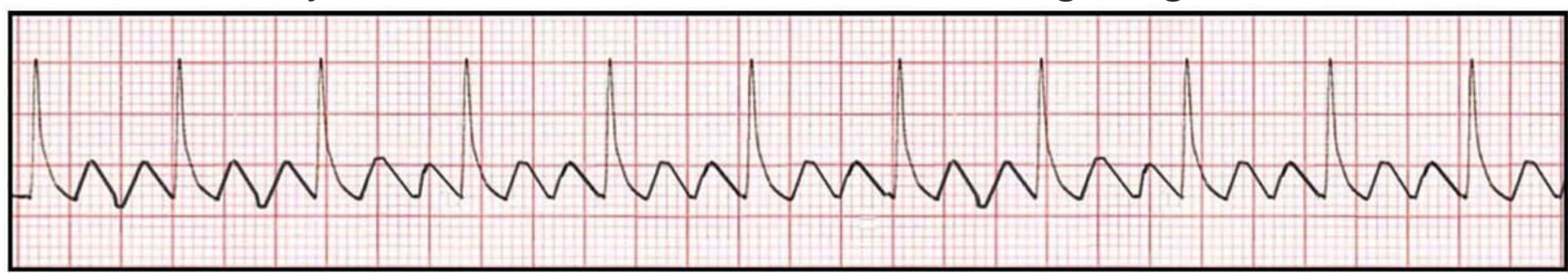# Atrial fibrillation

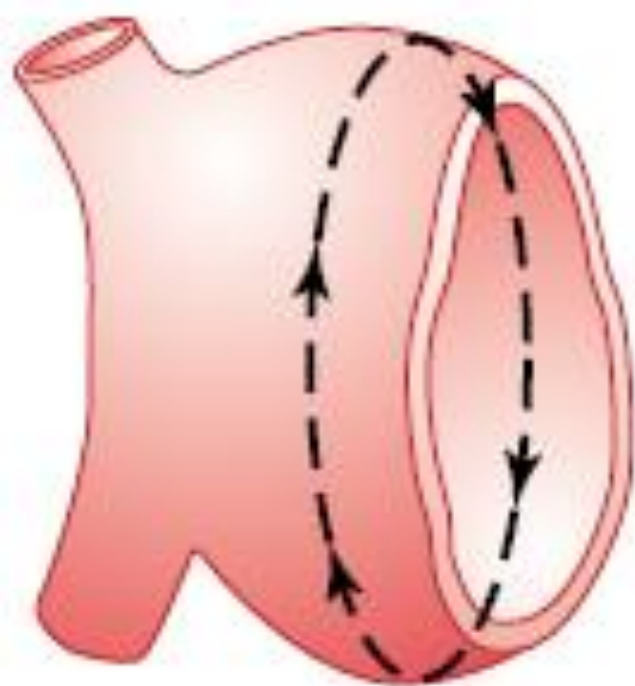
- The mechanism of atrial fibrillation is identical to that of ventricular fibrillation
- A frequent cause of atrial fibrillation is atrial enlargement
- The normal regular electrical impulses generated by the SA node are overridden by disorganized electrical impulses usually originating in the roots of the pulmonary veins.
- On the ECG either no P waves are seen or only a fine, high frequency, very low voltage wavy record. The QRS complexes are normal in shape but are irregular



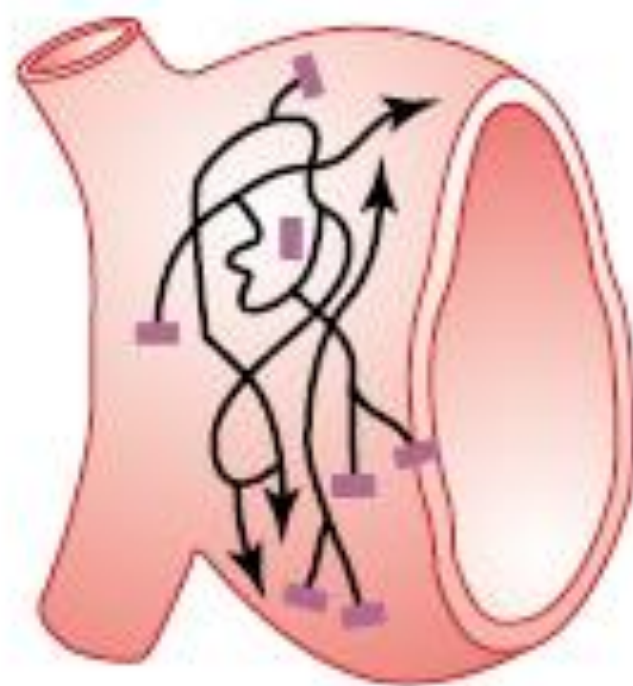
# Atrial flutter

- Caused by a re-entry circuit within the right atrium.
- The electrical signal travels along a circular pathway within the right atrium, causing the atria to beat faster than the ventricles.
- Atrial rate is around 300 bpm (200-400)
- Ventricular rate is determined by the AV conduction ratio. The commonest AV ratio is 2:1, resulting in a ventricular rate of ~150 bpm.
- P waves are strong (saw tooth appearance)
- QRS-T complex follows an atrial P wave only once for every two to three beats of the atria, giving a 2:1 or 3:1





Atrial flutter



Atrial fibrillation

**Figure 13-20** Pathways of impulses in atrial flutter and atrial fibrillation.

# Atrioventricular (AV) Block

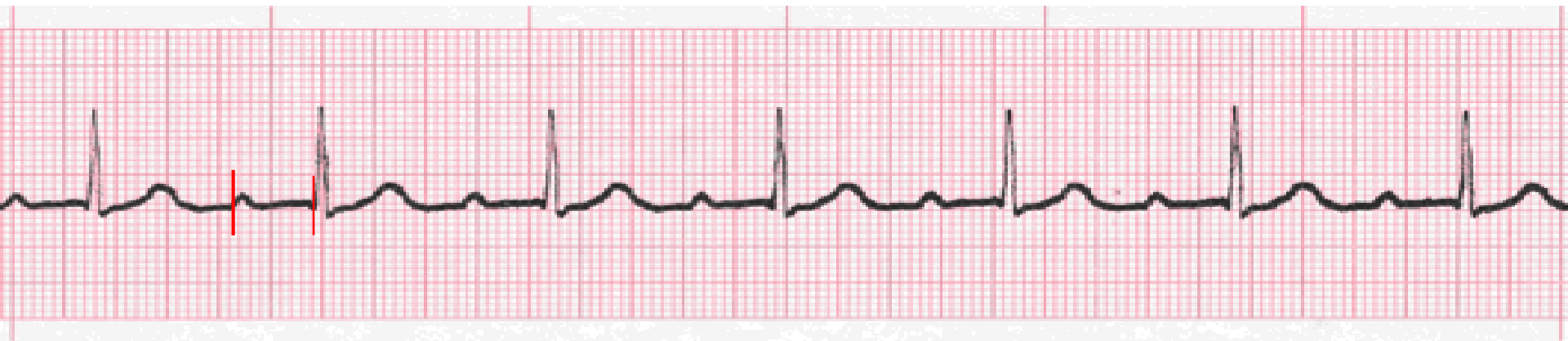- Results from conditions that can either decrease the rate of impulse conduction in the AV bundle or block the impulse entirely:
  1. Ischemia of the A-V node or A-V bundle fibers
  2. Compression of the A-V bundle by scar tissue or by calcified portions of the heart.
  3. Inflammation of the A-V node or A-V bundle
  4. Extreme stimulation of the heart by the vagus nerves

# Types of AV block

- First degree heart block
- Second degree heart block
- Third degree heart block

# First Degree Heart Block

- When the PR interval increases to greater than 0.2 sec, the P-R interval is said to be prolonged and the patient is said to have first-degree heart block.
- Caused by coronary artery disease, acute rheumatic carditis, digoxin toxicity or electrolyte disturbances.



PR interval here is 0.32 seconds

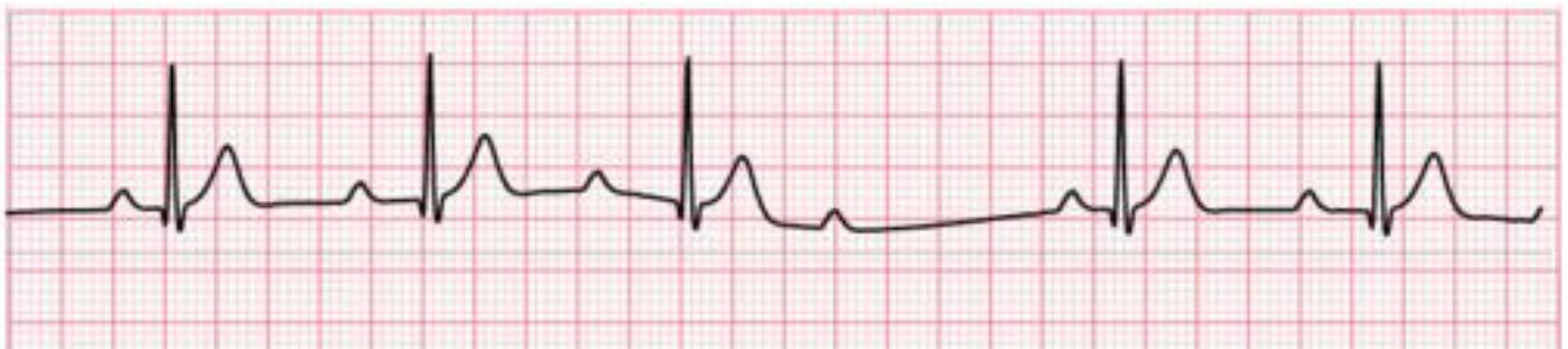

# Second Degree Block

- Happens when conduction through the A-V bundle is slowed enough to increase the P-R interval to 0.25 to 0.45 second
- The action potential is sometimes strong enough to pass through the bundle into the ventricles and sometimes not strong enough to do so.
- So occasionally there will be “dropped beats” ; an atrial P wave but no QRS-T wave.
- There are two types of second-degree A-V block:
  1. Type I (Wenckebach periodicity)
  2. Type II (Fixed ratio blocks)

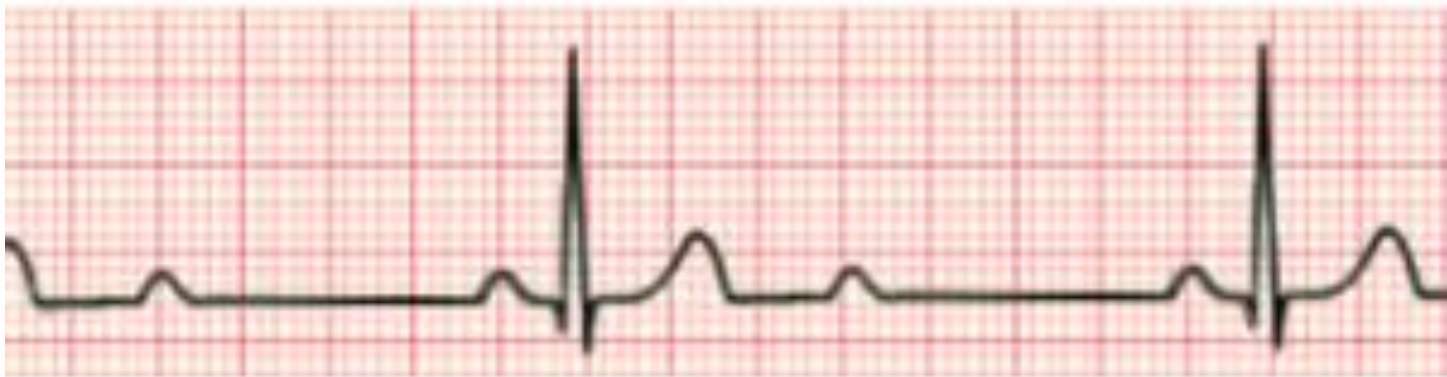## Type I (Wenckebach periodicity)

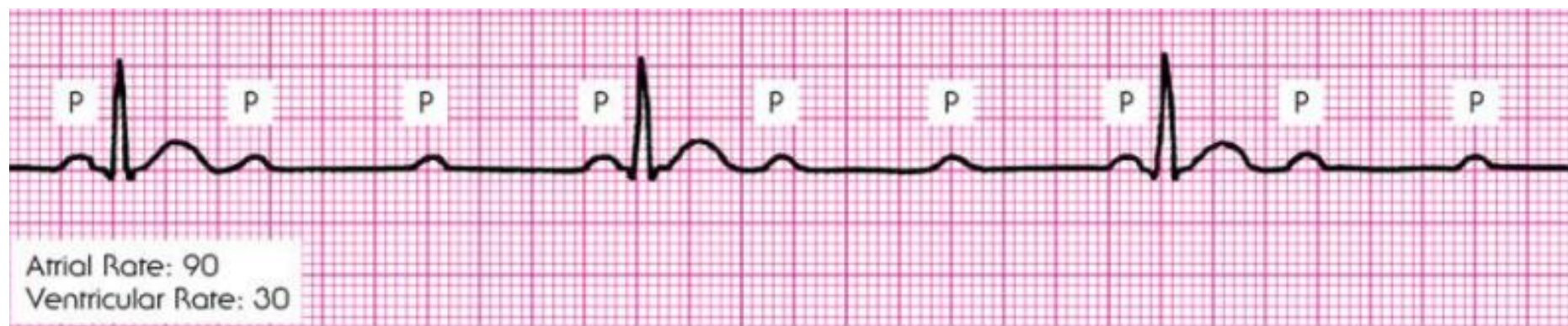- Progressive lengthening of the PR interval and then failure of conduction of an atrial beat, followed by a conducted beat with a shorter PR interval and then a repetition of this cycle.
- A type I block is almost always caused by abnormality of the A-V node. In most cases no specific treatment is needed.



# Type II (Fixed ratio blocks)

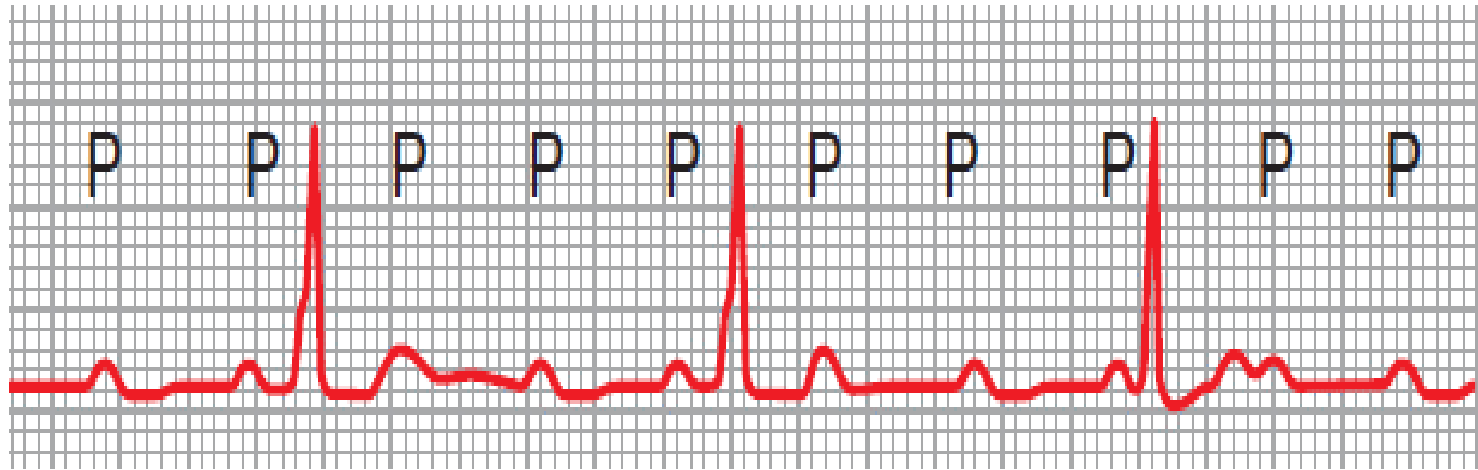
- There is usually a fixed number of non-conducted P waves for every QRS complex.
- Alternate conducted and non-conducted atrial beats(2:1) ,or one conducted atrial beat and then two (3:1) or three (4:1) non-conducted beats.
- Caused by an abnormality of the bundle of His-Purkinje system and may require implantation of a pacemaker





# Third degree block

- Occurs with complete block of the impulse from the atria into the ventricles.
- The ventricles spontaneously establish their own signal, usually originating in the AV node, AV bundle or purkinji fibers. Therefore, the P waves become dissociated from the QRS-T complexes.
- Third-degree block is characterized by:
  1. Regular P-P interval
  2. Regular R-R interval
  3. Lack of an apparent relationship between the P waves and QRS complexes
  4. Atrial rate is higher than ventricular rate
- Occur as an acute phenomenon in patients with myocardial infarction or it may be chronic, usually due to fibrosis around the bundle of His.



The A-V nodal fibers, when not stimulated by SA node discharge at an intrinsic rhythmical rate of 40 to 60 times per minute, and the Purkinje fibers discharge at a rate somewhere between 15 and 40 times per minute

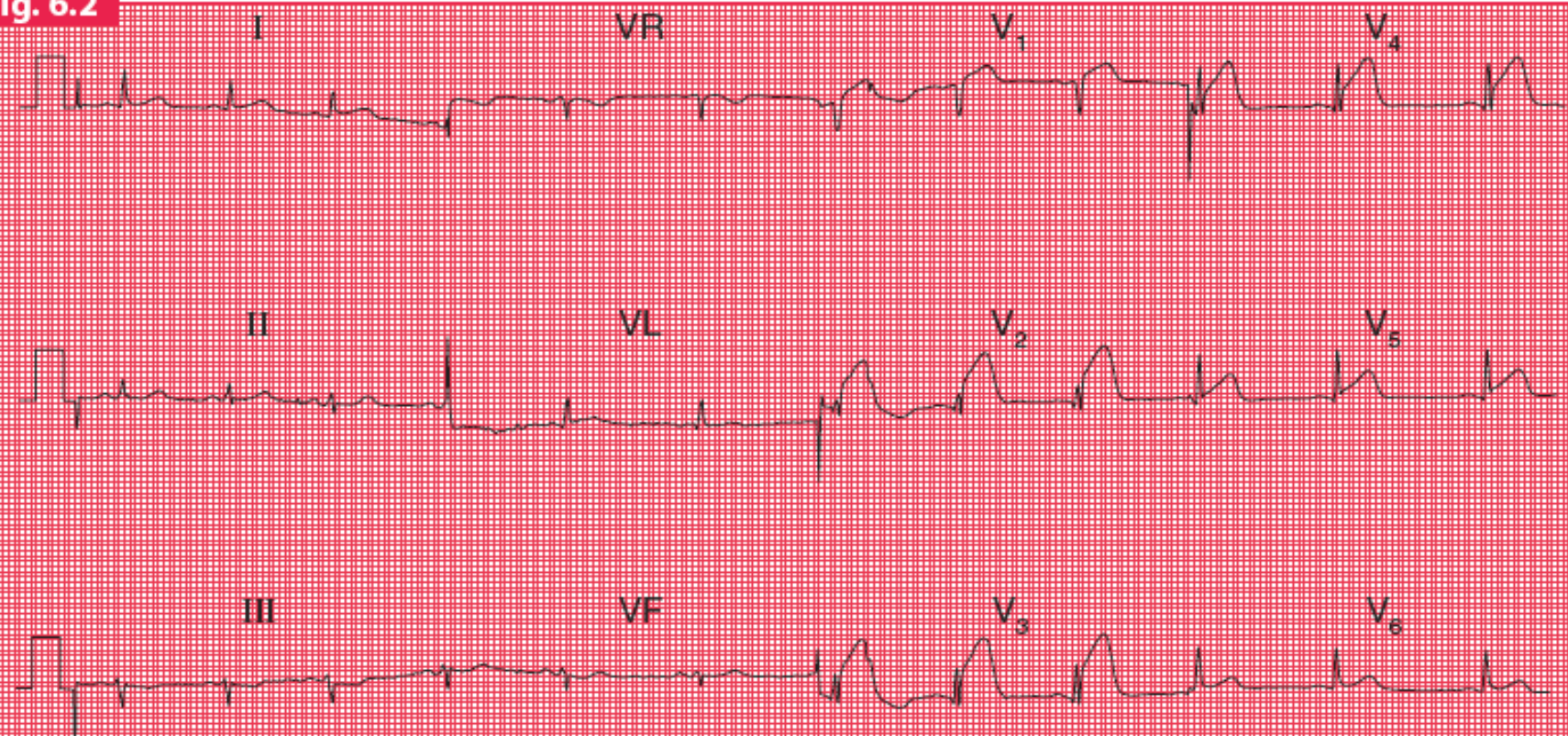
# ECG changes seen in Myocardial infarction (MI) and Angina pectoris

- ECG is very useful for diagnosing MI & Angina pectoris and locating the affected areas.
- One of the earliest sign of MI is ST segment changes & it occurs in the leads corresponding to the part of the heart that is damaged:
  - Leads V1-V4 with anteroseptal wall infarction
  - Lead aVL, I, V5 & V6 with lateral wall infarction
  - Leads II, III and aVF with inferior wall infarction.
- To be considered significant , more than 1 mm of ST segment elevation or depression in at least two contiguous limb leads (e.g. I and VL; III and VF), or more than 2 mm of ST segment elevation or depression in at least two contiguous chest leads



- In case of myocardial infarction, within a day or so, the ST segments return to the baseline.
- Without proper & prompt treatment the T waves in the affected leads become inverted, and Q waves develop within 24 hours. These ECG changes are usually permanent
- In angina ECG changes are noticed while the patient is in pain, once the pain has resolved the ECG returns to normal.
- ST segment changes are very common with angina.
- When the ECG is normal at rest, ST segment changes may be induced by making the patient exercise, this test is called stress ECG

**Fig. 6.2**



### **ST segment elevation in acute anterior ST segment elevation myocardial infarction**

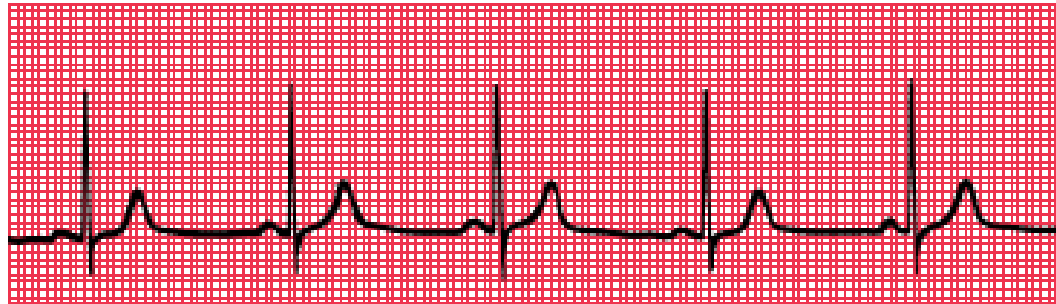
#### **Note**

- Sinus rhythm, rate 75/min
- Normal axis
- Normal QRS complexes
- ST segments elevated in leads V<sub>1</sub>–V<sub>5</sub>
- Normal T waves

**Fig. 4.14**

## Exercise-induced ischaemic changes

Rest:



Exercise:



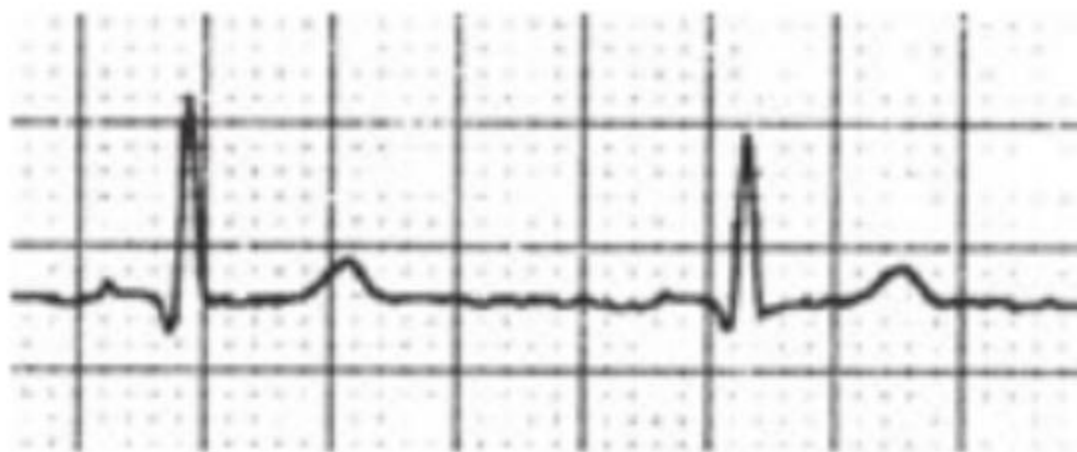### Note

- In the upper (normal) trace, the heart rate is 55/min and the ST segments are isoelectric
- In the lower trace, the heart rate is 125/min and the ST segments are horizontally depressed

# Pathological Q wave

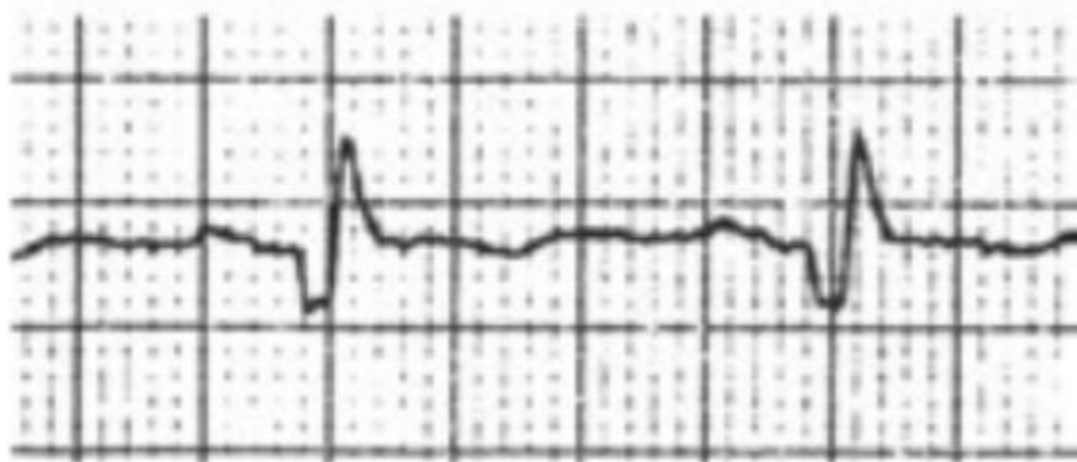- Q waves are considered pathological if:
  - > 0.04 sec
  - > 2 mm deep
- Pathological Q waves usually indicate ongoing or prior myocardial infarction.

A



Normal Q Waves

B



Pathologic Q Waves

