HISTOLOGY

LEC : 1+2

LEC1 : Histology of upper respiratory tract.

☆ Respiratory system is made of ① Conducting ② Respiratory parts.

Conducting: Nose + pharynx + larynx + trachea + Rt. and Lt. main bronchi (primary)

+ Secondary bronchi (Lober bronchi: Branch for each lobe → 3 in Right and 2 in left lung).

+ 10 bronchopulmonary segments on each side (tertiary bronchi).

↳ Each segment is surrounded by Connective tissue and contain a bronchi + blood vessels lymphatics.

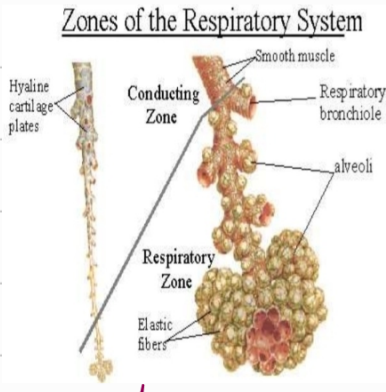

After Bronchi → Bronchioles: 1- Very narrow diameter

2- Different type of epithelium

3- No cartilage

4- Contain spiral helical smooth muscles.

5- Classified to → large conducting bronchioles / → terminal bronchioles

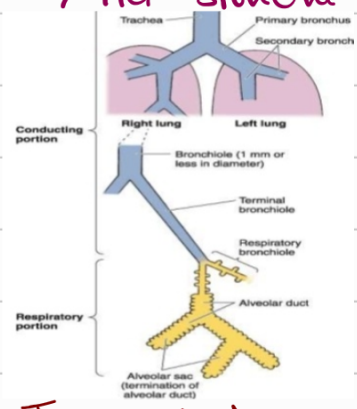

Terminal bronchioles: Imediatly befor respiratory portion.

↳ ① No cartilage ② No glands ③ No goblit cells

↳ Epithilium: Simple Cuboidal with or without Cilia (Clara cells).

↳ Simple cuboidal without Goblit cells.

Respiratory portion: Simple squamous epithelium

↳ Starts as respiratory bronchioles that's narrower than terminal bronchioles.

- Respiratory bronchioles open in alveolar ducts that's surrounded by Alveoli.
- Alveolar duct terminate as Alveolar Sac.
- Alveoli surround the ① Respiratory bronchioles ② Alveolar ducts ③ Alveolar Sacs.
- Each alveolus is surrounded by an network of Capillaries.

- In the begining of the Respiratory portion there will be some Clara Cells.

Conducting portion

→ Functions: ① Conducts ② warms ③ moistures ④ cleans the air

layer 1: Mucosa

Mucosa
- → Lining epithelium
- → lamina propria (No glands or very minimal)
- → Muscularis mucosa

☆ Lining epithelium: pseudostratified Columnar Ciliated with goblit cells
↳ From Nose → toward tertiary bronchioles.
↳ Simple Cuboidal with or without goblit cells terminal bronchioles.

layer 2: Submucosa

Contain Seromucus gland with a duct opens in the lumen

layer 3: Subartive layer

☆ Hyaline Cartilage and Smooth muscles.
↳ For keeping the pathway open for easy passage of air.

In trachea: C-Shaped hyaline cartilage. Absent posteriorly → trachialis Smooth muscles posteriorly. why?

Because posterior to the trachea there is the esophagus: if there were cartilage it may stop the passage of bolus in esophagus.

★ In primary + secondary + tertiary bronchi: plates of cartilage.
- Decrease when going distally.

In 1° it's surrounding the lumen in all directions.
In 2° it's less present
In 3° you may only find 1 or 2 plates

While Smooth muscles is fewer in areas with higher content of cartilage like trachea

- In tertiary bronchi there will be alot of Smooth muscles.
- In bronchioles it's heavy, spiral and helical Surrounding all the lumen.

Layer 4: Adventitia (Connective tissue)

Respiratory portion

☆ Alveoli: The wall is made of 2 types of cells

☆ Type 1: 97%
→ Important for gas exchange.

☆ Type 2: 3% (Cuboidal cells).
→ Function: Secreation of a protein known as Surfactant → decrease surface tension in alveolus → easier inflation.

Befor birth: the levels of Surfactant must be mesured.

☆ When the baby is born the doctor gentely taps baby's back to Stimulate phrenic nerve → Impulses go to respiratory centers in the brain → Motor impulses through phrenic nerve to diaphragm → diaphagm descends downword → lower intrapleural pressure → inspiration of air.

- Surfactant helps lungs to be filled with air, if it was insuficiant → baby won't breath Infant Respiratory Distress Syndrome (IRDS)

Respiratory Membrane

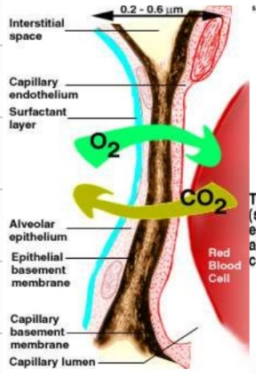

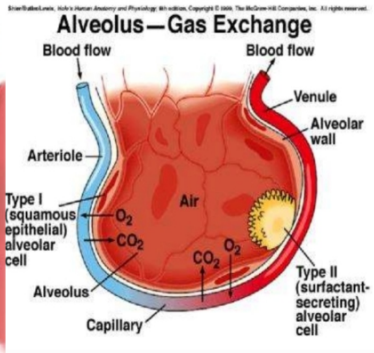

☆ Blood - Air Barier

☆ Composed of :
1. Surfactant
2. Endothelial cell wall
3. Type 1 Alveolar Cell wall
4. Fused basal lamina (from blood capillary and Alveolus)

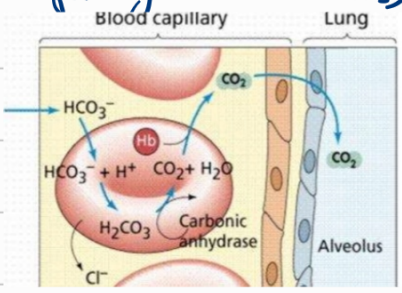

Respiratory Epithelium

Pseudostratified Ciliated Columnar Epithelium with Goblit cells

- Seen under light Microscope
- 300 cilia on it's apical surface.
  - ↳ moves in one direction (outward)
  - ↳ Attatched to basal body

Goblit Cells Secrete Mucus. for moisturing and filteration

- under the basal bodies there are Apical Mitochondria.
  - ↳ Abundant in large numbers
  - ↳ gives energy to cilia for motility

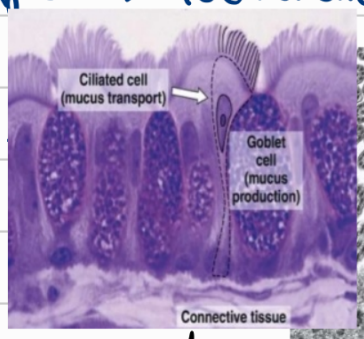

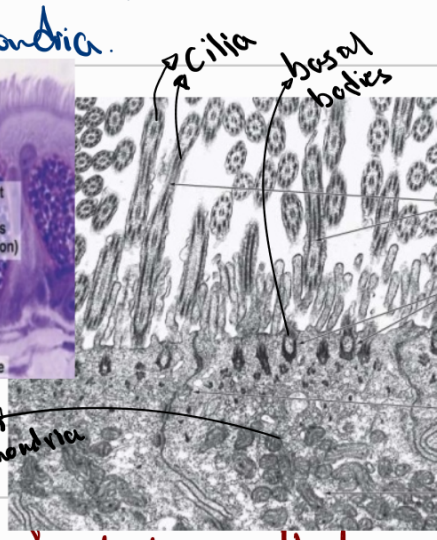

Ciliary Movement

Dynein : protein participate in the ciliary movement. located near the basal bodies.

☆ Smoking leads to the release of high amounts of Nicotine that leads to destruction of Dynein or inhibits it's synthesis → destructed ciliary movement (Immotile cilia syndrom (Kartagner Syndrom)).

Any pathogen enters will persist in the respiratory tract leading to chronic infections.

In males, dynine also helps in sperms motality. Smoking destruct sperms motality → Infertility.

* under Electron Microscope we're able to See other types of cells.

① Basal cells : on the basement membrane and dont reach the Surface.

Reserve cell → high mitotic activity.

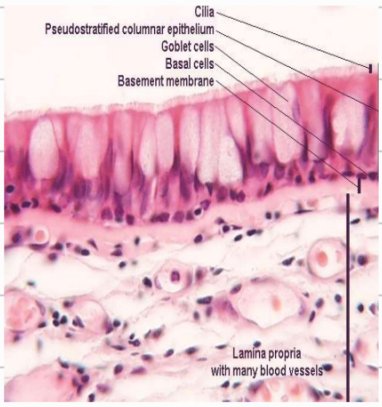

② Brush cells: - Contain microvillie on apical Surface
- Sensory receptors

③ Serous cells: (Granular) Contain Secretory granules.

④ Diffuse neuroendocrine cells. Kulchitsky cells: Regulate secretion of glands

⑤ Goblit cells.

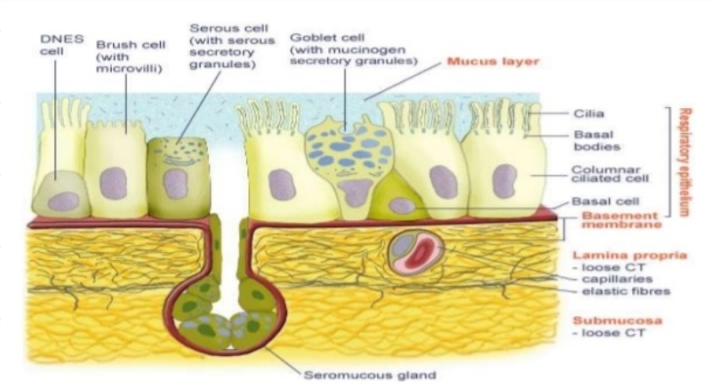

Nasal Cavity

Subdivided into:

① Vestibule

Epithelium: Stratified Squamous Keratinized (like skin)

Contain vibrissae : thick hair for filtration

Contain Sebacious glands

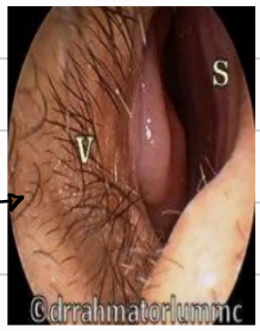

② Respiratory area

- Bellow Superior Conchi and above the vestibule.
- Epithelium : pseudostratified ciliated columnar with goblit cells.
- Submucosa contain plexus of veins.

③ Olfactory region

- Above the Superior Conchi (Roof).
- Epithelium : pseudostratified ciliated columnar with goblit cells
- Contain bipolar cells : one pole contain hairlits
  The other pole have fillament of olfactory nerve.
  → Converts odor into smell impulses → Smell centers
- In the olfactory region Glands are both in lamina propria and Submucosa.

- The glands have ducts toward the mucus surface.
These Glands are Bowman's Gland

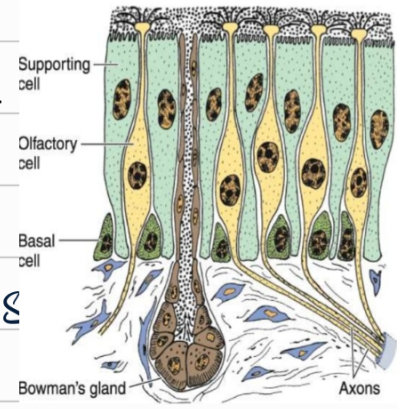

- Contain Supporting (Sustinacular) Columnar cells
- Contain Basal Cells

Nasal Sinuses

- lined by thin mucus that's adherant with the periosteum.
- pseudostratified columnr with few goblit cells.
- and few glands

Structural Changes in the Bronchial Tree

1. Goblit cells : Decrease when going distaly then become absent.
2. Glands : Decrease when going distaly then become absent.
3. Smooth muscles : Increase when going distaly (most prominant in Bronchioles) and in lungs become as batches and replaced by Elastic and Reticular fibers.
4. Elastic and Reticular fibers : present every where but most prominant In lungs between alveoli.
   → Responsible for inflation and deflation.
5. lymphocytes : Scatered everywhere and aggregates and form lymphatic Nodule around bronchioles.

Cough Reflex

Any forign body entering the respiratory tract will induce cough to push it outside

Extra-pulmonary Bronchi:
Are the primary bronchi. (outside the lungs).

Intra pulmonary Bronchi:
Are the secondary and Tertiary (Surrounded by lung tissue).

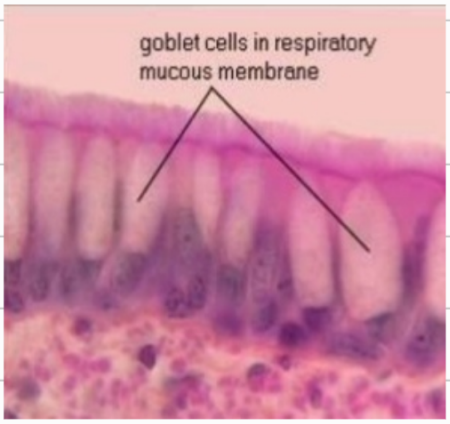

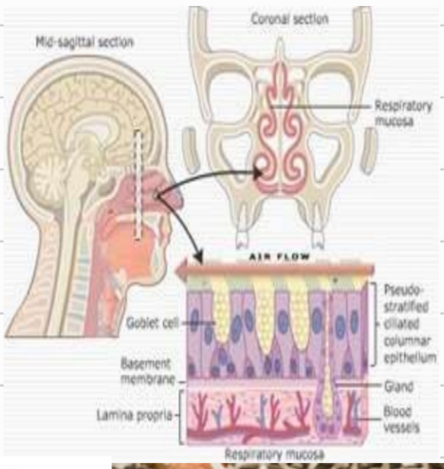

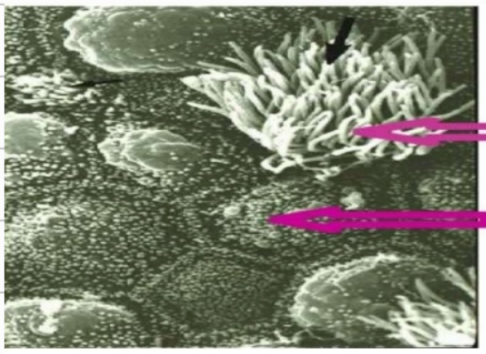

Olfactory cells (bipolar)

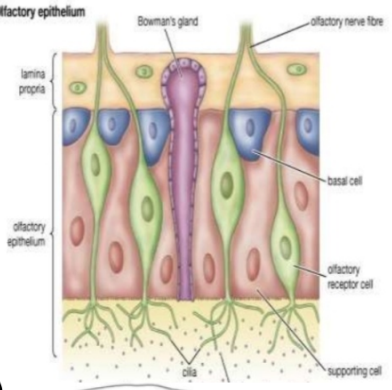

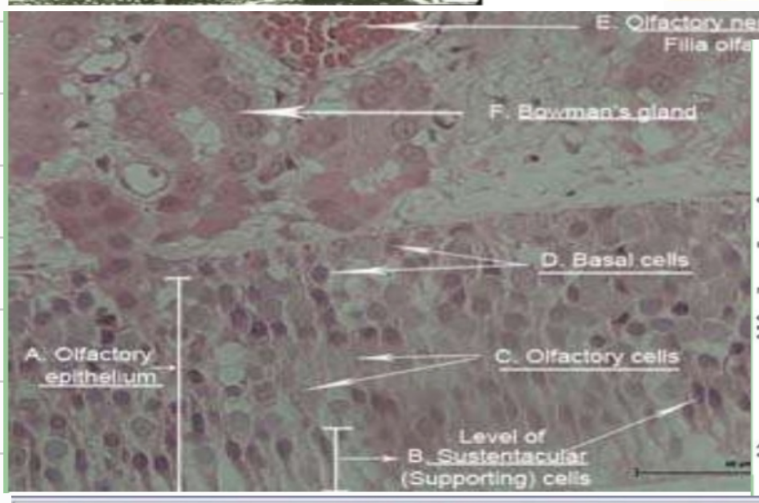

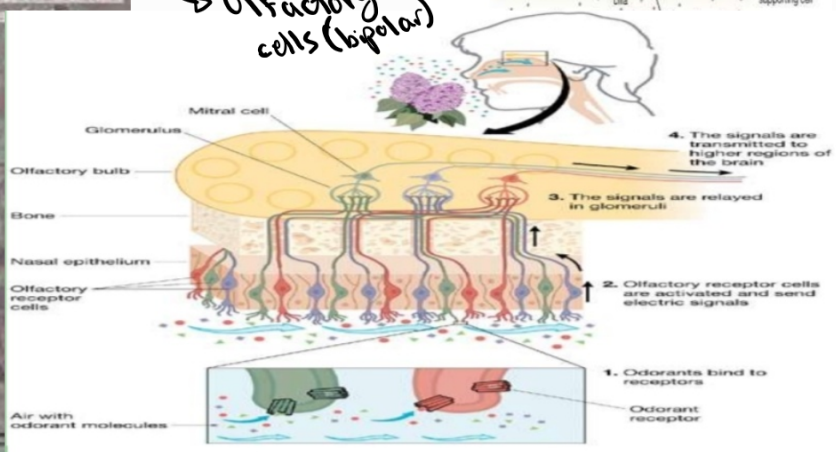

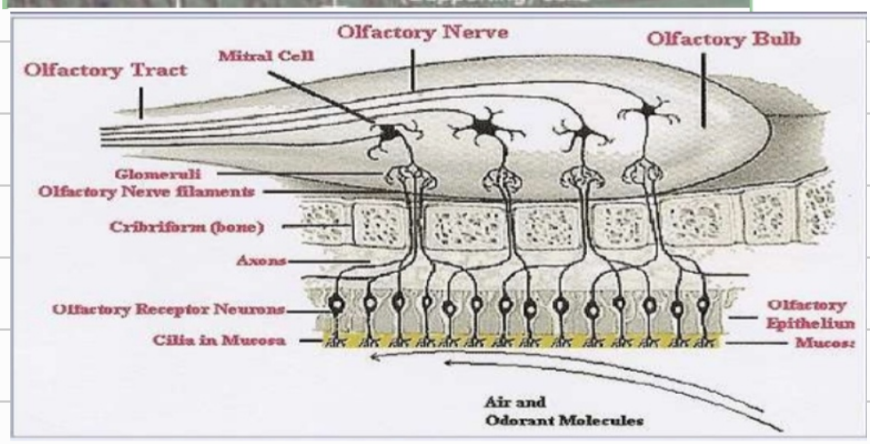

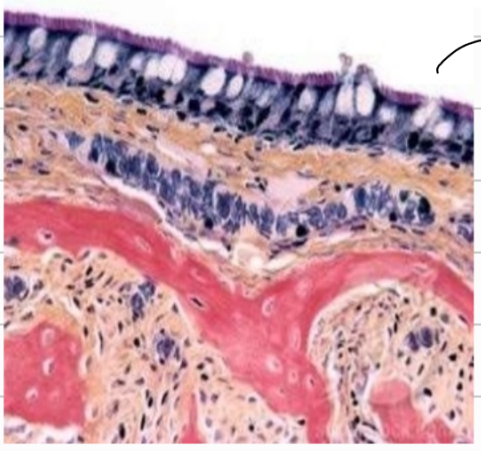

Nasal Sinuses

LEC-2

Lower Respiratory Tract

Bronchioles

- Diameter 5mm → then devides more → larg bronchioles are 1mm.
  → Small are 0.5 mm.

- No Cartilage + No glands + few Goblit cells.
  Clara cells (Simple cuboidal without goblit cells)

☆ Epithelium: Simple columnar epithelium and Simple cuboidal epithelium with Cilia.

☆ Changes in epithelium is gradual.
In larger bronchioles it's pseudostratified ciliated columnar.
Then gradually changes into simple columnar and simple cuboidal.
Then loss the cilia and change to Clara cells.

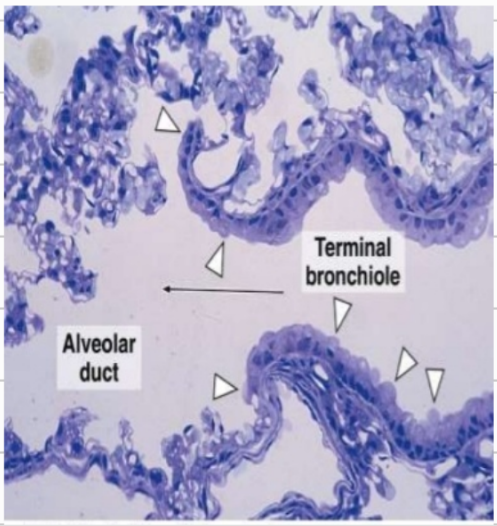

Clara Cells

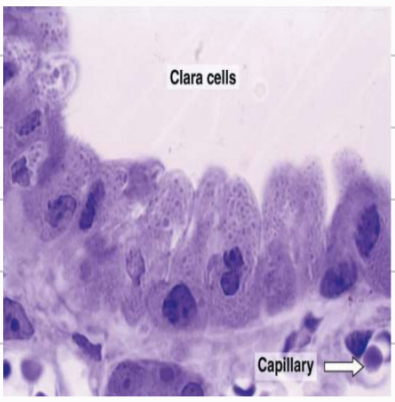

- Contain Secretory granules: 1- Bactericidal
  2- for surfactant
- Contain Neuroepithelial bodies
- Recives Cholenargic nerve endings → Chemoreceptors for changes in O_2 and CO_2.
- Seen in terminal bronchioles and begining of respiratory bronchioles.

Terminal Bronchioles

- Closed bronchiole : Cercular lumen / Rounded
- There are foldings of mucosa because the lamina propria contain smooth muscles and elastic fibers.
- Spiral cercular smooth muscle.
  - ↳ Contraction of these muscles → Asthma

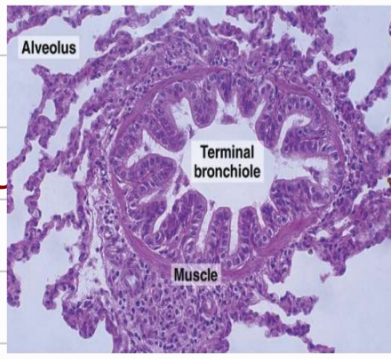

Sympathatic → Relatation of the muscle
Parasympathatic → Contraction
→ In cases of emergencies we may use Adrenaline.

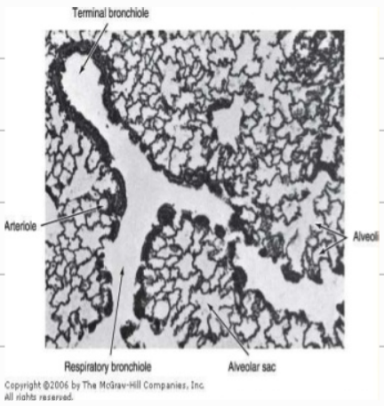

Respiratory Bronchioles

- Opened bronchiole : opens in an alveolar duct
- Lumen is not cercular.
- Epithelium : Simple cuboidal ciliated or non-ciliated (clara).
  when going distaly it become simple squamous epithelium.

- Smooth muscles : Knops and tags of smooth muscles located at the opening of the alveolar duct.
- less folding in mucosa, because of less smooth muscles.

- Between alveoli there are elastic fiber and reticular fibers for inflation and deflation and support for Alveolar duct and Alveoli so it doesn't rupture.
- Alveolar ducts open into Atria that communicate with the alveolar sac.

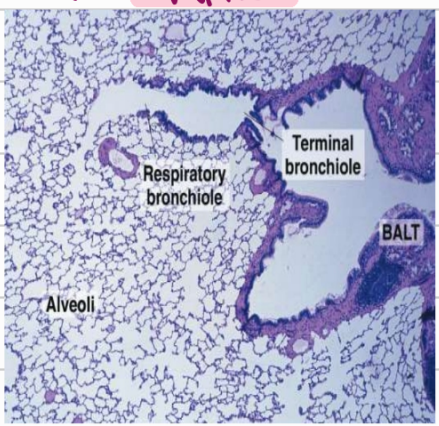

Alveoli

★ About 300 milion Alveoli in lungs.

- Sac like evagination.
- Diameter: 200 um.
- Spongy and soft filled with air and surrounded by elastic fibers

- Between alveoli there are Interalveolar Septum
- The Alveolus membrane is made of two types of cells:
  type 1: 97% and type 2: 3% → type 2 is known as septal cells.
- While in the Interalveolar septum,
  type 1: 8% and type 2: 16% → mainly in the corners between the alveoli
- Endothelial cells present in the septum and the alveolar membrane.
- Interstitium: CT + capillaries. → Leukocytes + macrophages + fibroblasts
- Macrophages: Dust cells
- Between adjacent alveoli there are openings called Alveolar pores for spreading oxygen between the alveoli for equalize the pressure.
  → 10–15 um in diameter.

- Components of Intra alveolar Septum:

★ Make sure that you can differentiate between the Alveolar membrane and intralveolar septum.

1- Cells in interstitium
2- Endothelial cells (capillaries) 30%
3- Fibroblast and Mast cells 36%
4- Macrophages 10%
5- Type I cells 8%
6- Type II cells 16%
7- leukocytes

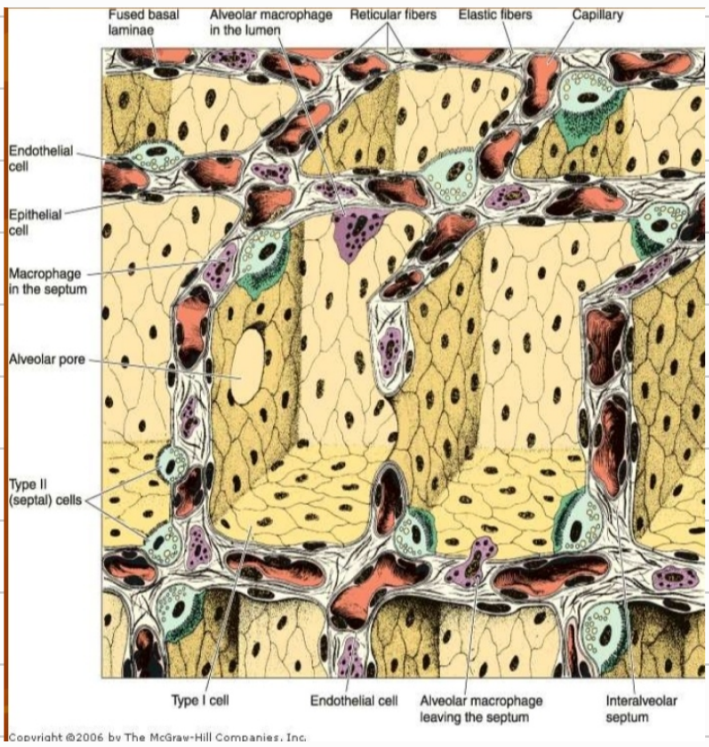

Blood - Air Barrier

* Also known as respiratory membrane.
* Between the cappilary and type 1 Alveolar cells for gas exchang.

layers :
1- Surfactant
2- Cytoplasm of alveolar cells
3- fused basal lamina of the closely oposed Alveolar and Endothelial cells.
4- Cytoplasm of endothelial cells.

Total thickness : 0.1 - 1.5 um.

- Internal Exchang Surface area is approximately 140 m^2.

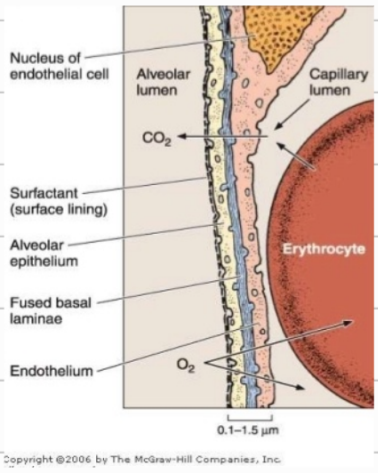

Capillary Endothelial Cells

- Extremely thin
- Confused with type I alveolar epithelial cells (both are simple squamous)
  ↳ under microscope we differentiate endothelial cells by the presence of RBCs.
- Non-finistrated.
- Clusturing of the nuclei and other organelles.
  And the remaniant of cytoplasm is empty to contain O_2.
- Numerous pinocytic vesicles.

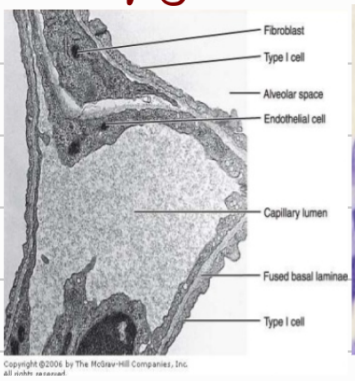

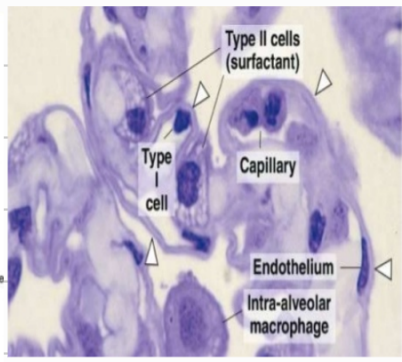

Type I cells.

- Simple squamous epithelium
- 25 nm.
- Cluster of nucleus and organelles and leaving large areas of cytoplasm vertually free.
- Contain pinocytic vesicles.
- There are Dismosomes between type I and type II for occluding junction.

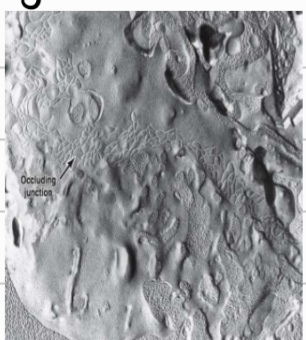

Type II cells

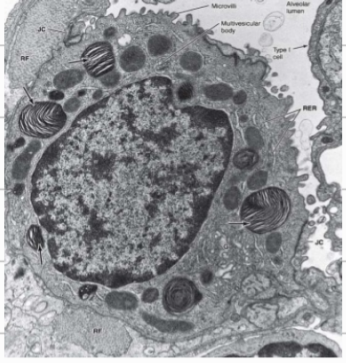

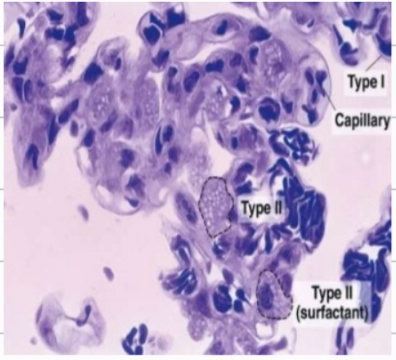

- Cuboidal cells.
- larger than type I
- Secreate surfactant.
- High mitotic activity and able to replace both: type I and II
- Contain lamilar bodies → Contain the surfactant.
  → foamy appearance for the cytoplasm.

Pulmonary Surfactant

- 4 types of proteins A, B, C and D.
- Decrease surface tension + Bactericidal effect
- Form the bronchoalveolar fluid.

Alveolar-Lining Regeneration

- Inhalation of NO_2 destroys type I and II.
- Type II turnover rate is high and is able to give both type I and II.

Lung Macrophages

- Dust cells.
- Seen in lungs and may be seen on the surface of pleura.
- Appear as black dots
- Originate from Monocytes.
- May go throug bronchioles to bronchi then to pharynx. Then undergo expectoration with salivia.
- Huge number exceeds type I cells.

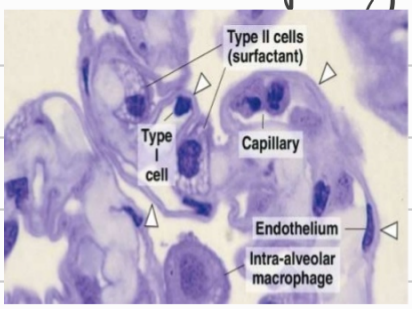

Alveolar (lung) macrophages are more abundant in number than type I alveolar cells.

- **Type I alveolar cells:**
  Cover ~95% of the alveolar surface area, but they are **few in number** (large, flat cells).
- **Alveolar macrophages:**
  Are **numerous**, freely present in the alveolar lumen and septa, and can increase further during inflammation.

So, although type I cells dominate **surface area**, macrophages dominate **cell number**.

Pulmonary lymphatic Vessels of lung

Superficial and deep lymphatic vessels that all go to the hilum (mediastinal lymphnodes) → lymphatic duct in left side and Right lymphatic duct in right side.
→ Begining of brachiocepalic vein on left and Right.

Innervation of lung

lung + visceral pleura
- Sympathatic → bronchodilatation
- parsympathatic → bronchoconstriction

Pleura

- Visceral and parietal
- Contain elastic and reticular fibers
- Innervation like lung sympathatic and parasympathatic.
- Epithelium: Mesothelium (simple squamous epithelium)

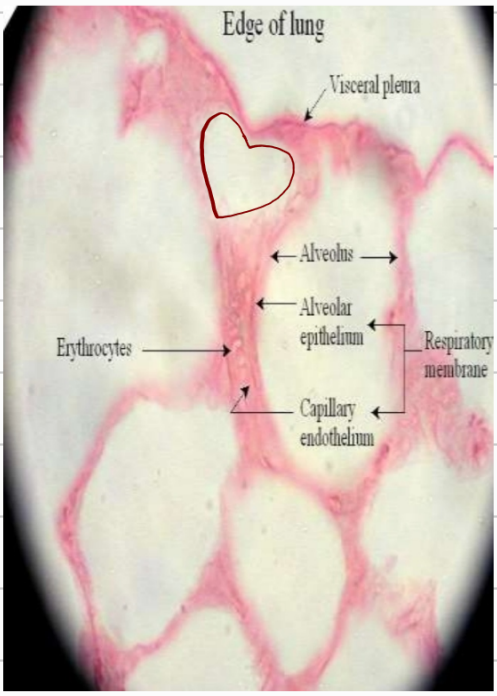

Trachea

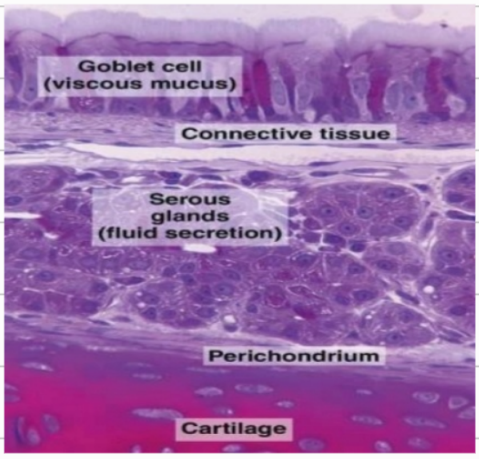

Extra-pulmonary bronchi

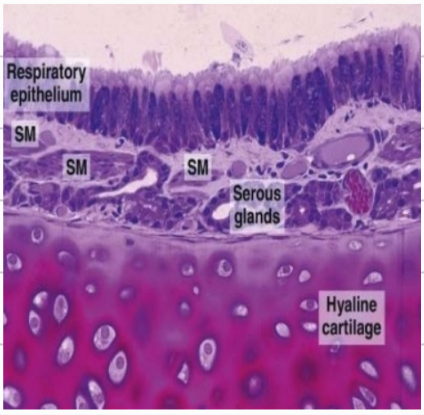

Intrapulmonary bronchi