

---

# Cortical Control of Motor Function-

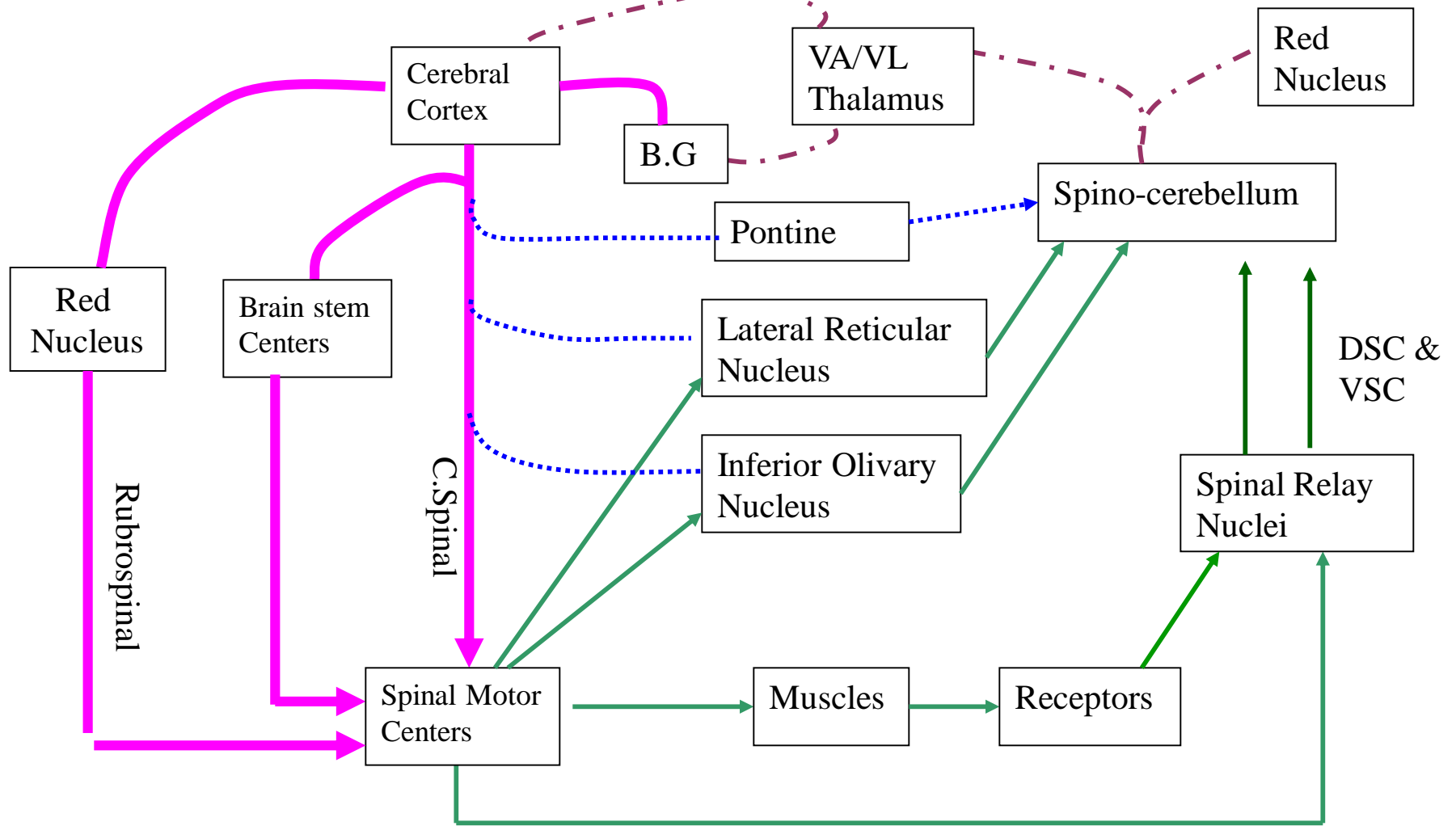
---




Faisal I. Mohammed, MD, PhD

---

# Objectives

- Recognize cerebral cortical motor areas
- Delineate the cortical control of the corticospinal pathways
- Interpret some of the cortical abnormalities



-  Motor Command
-  Feed Back
-  Command Monitor
-  Corrective Command

**Motor System**

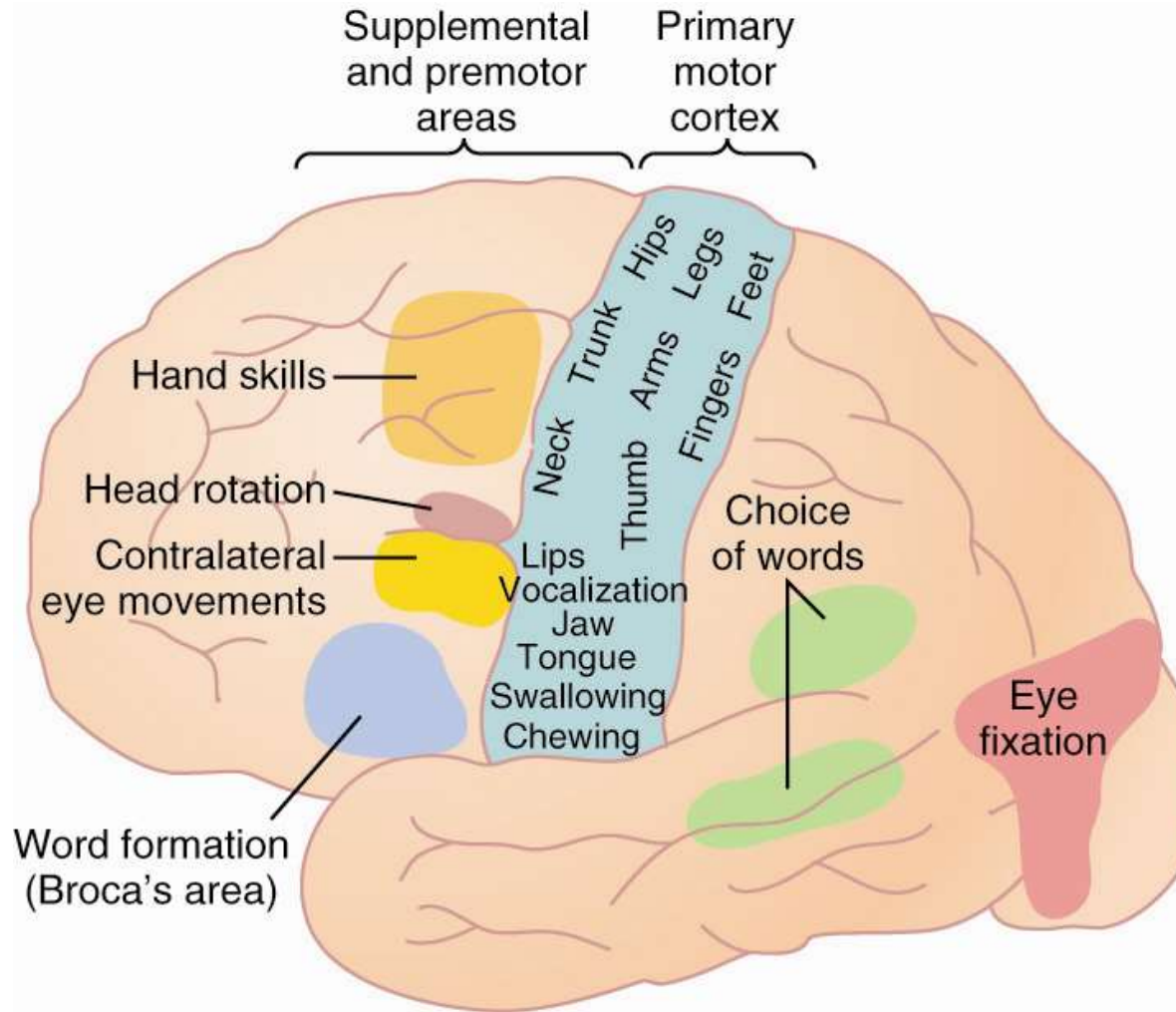
# Motor Cortex

- Divided into 3 sub areas
  - primary motor cortex
    - unequal topographic representation
    - fine motor movement elicited by stimulation
  - premotor area
    - topographical organization similar to primary motor cortex
    - stimulation results in movement of muscle groups to perform a specific task
    - works in concert with other motor areas

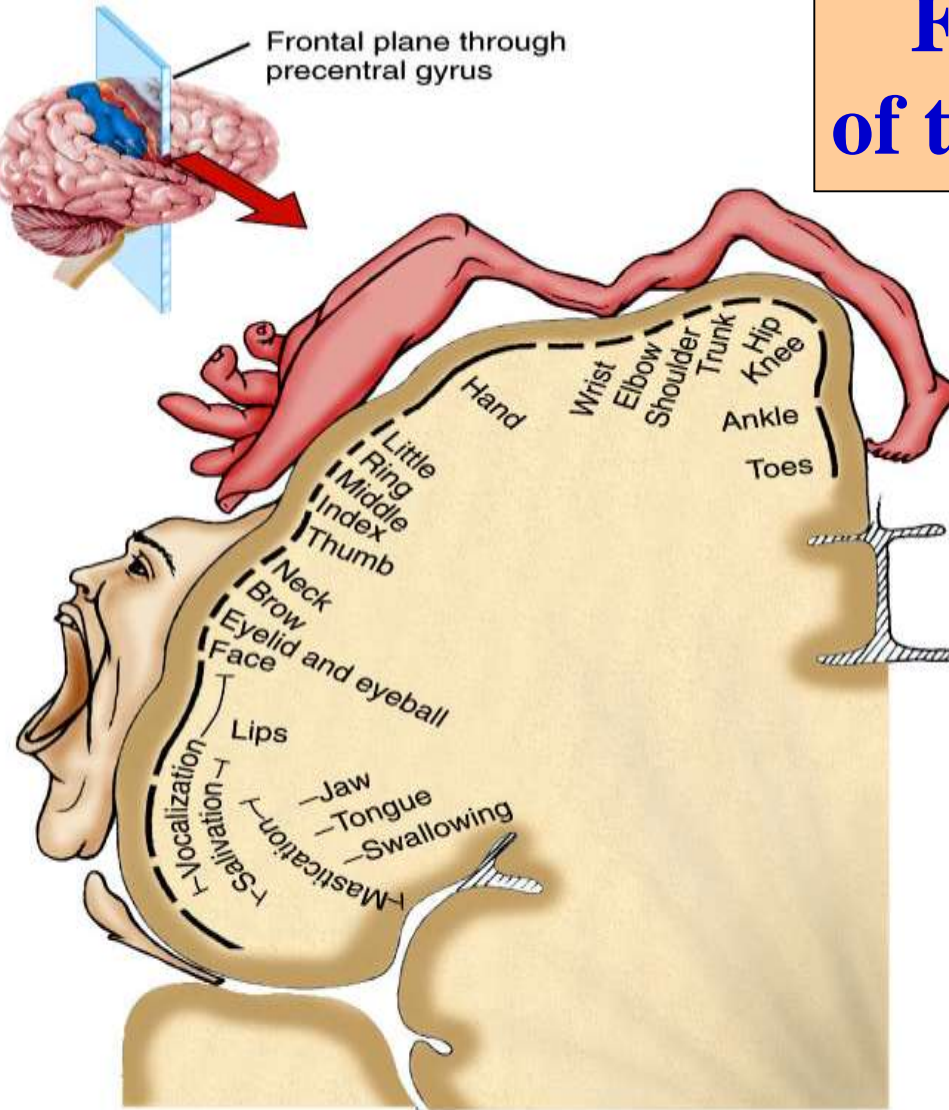
# Motor Cortex (Cont.)

- supplemental motor area
  - topographically organized
  - stimulation often elicits bilateral movements.
  - functions in concert with premotor area to provide attitudinal, fixation or positional movement for the body
  - it provides the background for fine motor control of the arms and hands by premotor and primary motor cortex

# Motor Areas of the Cortex



# Functional organization of the primary Motor Cortex



(b) Frontal section of primary motor area in right cerebral hemisphere

- ❖ Located in the precentral gyrus of the frontal lobe.
- ❖ More cortical area is devoted to those muscles involved in skilled, complex or delicate movements, that have more motor units i.e the cortical representation is proportional to the No of motor units

# Specialized Areas of the Motor Cortex

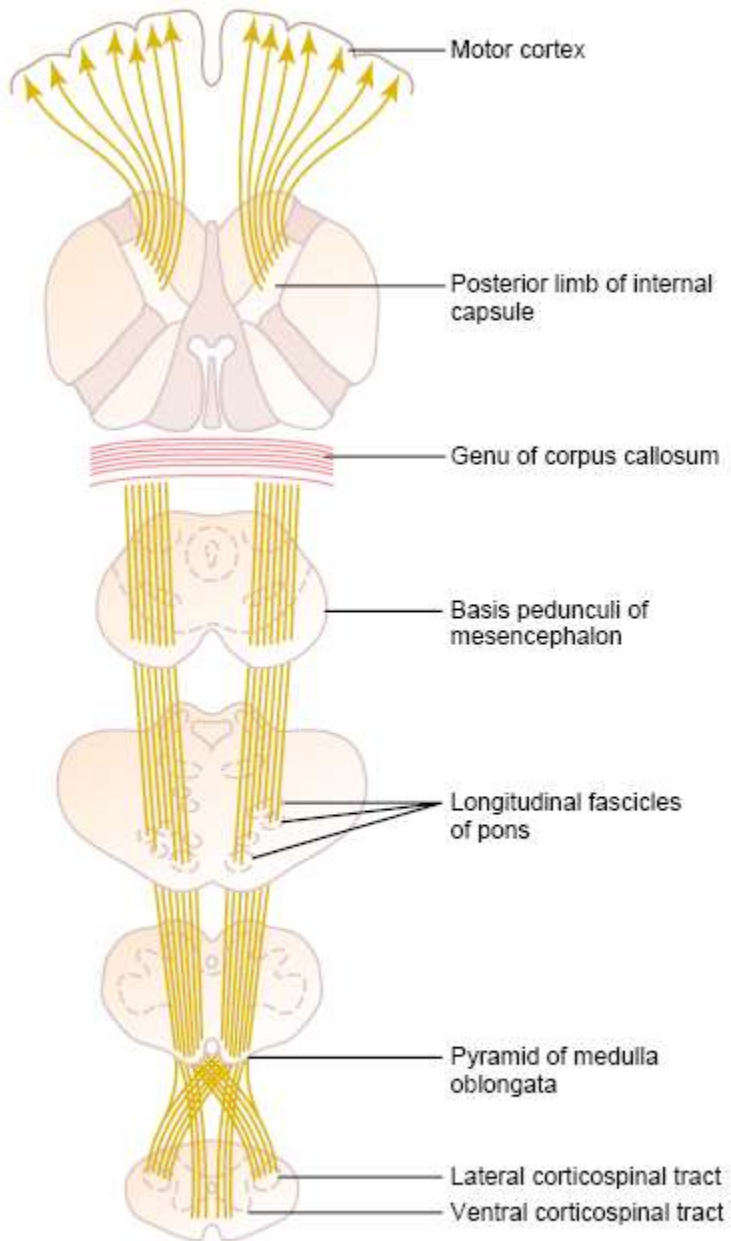
- Broca's area
  - damage causes decreased speech capability
  - closely associated area controls appropriate respiratory function for speech
- eye fixation and head rotation area
  - for coordinated head and eye movements
- hand skills area
  - damage causes *motor apraxia* the inability to perform fine hand movements

# Transmission of Cortical Motor Signals

- Direct pathway
  - corticospinal tract
  - for discrete detailed movement
- Indirect pathway
  - signals to basal ganglia, cerebellum, and brainstem nuclei

# Corticospinal Fibers

- 34,000 Betz cell fibers, make up only about 3% of the total number of fibers
- 97% of the 1 million fibers are small diameter fibers
  - conduct background tonic signals
  - feedback signals from the cortex to control intensity of the various sensory signals to the brain



# Corticospinal pathways

**Figure 55-4**

Pyramidal tract. (Modified from Ranson SW, Clark SL: *Anatomy of the Nervous System*. Philadelphia: WB Saunders, 1959.)

# Other Pathways from the Motor Cortex

- Betz collaterals back to cortex sharpen the boundaries of the excitatory signal
- Fibers to caudate nucleus and putamen of the basal ganglia
- Fibers to the red nucleus, which then sends axons to the cord in the rubrospinal tract
- Reticular substance, vestibular nuclei and pons then to the cerebellum
- Therefore the basal ganglia, brain stem and cerebellum receive a large number of signals from the cortex.

# Incoming Sensory Pathways to Motor Cortex

- Subcortical fibers from adjacent areas of the cortex especially from somatic sensory areas of parietal cortex and visual and auditory cortex.
- Subcortical fibers from opposite hemisphere which pass through *corpus callosum*.
- Somatic sensory fibers from ventrobasal complex of the thalamus (i.e., cutaneous and proprioceptive fibers).

# Incoming Sensory Pathways to Motor Cortex (Cont.)

- Ventrolateral and ventroanterior nuclei of thalamus for coordination of function between motor cortex, basal ganglia, and cerebellum.
- Fibers from the intralaminar nuclei of thalamus (control level of excitability of the motor cortex), some of these may be pain fibers.

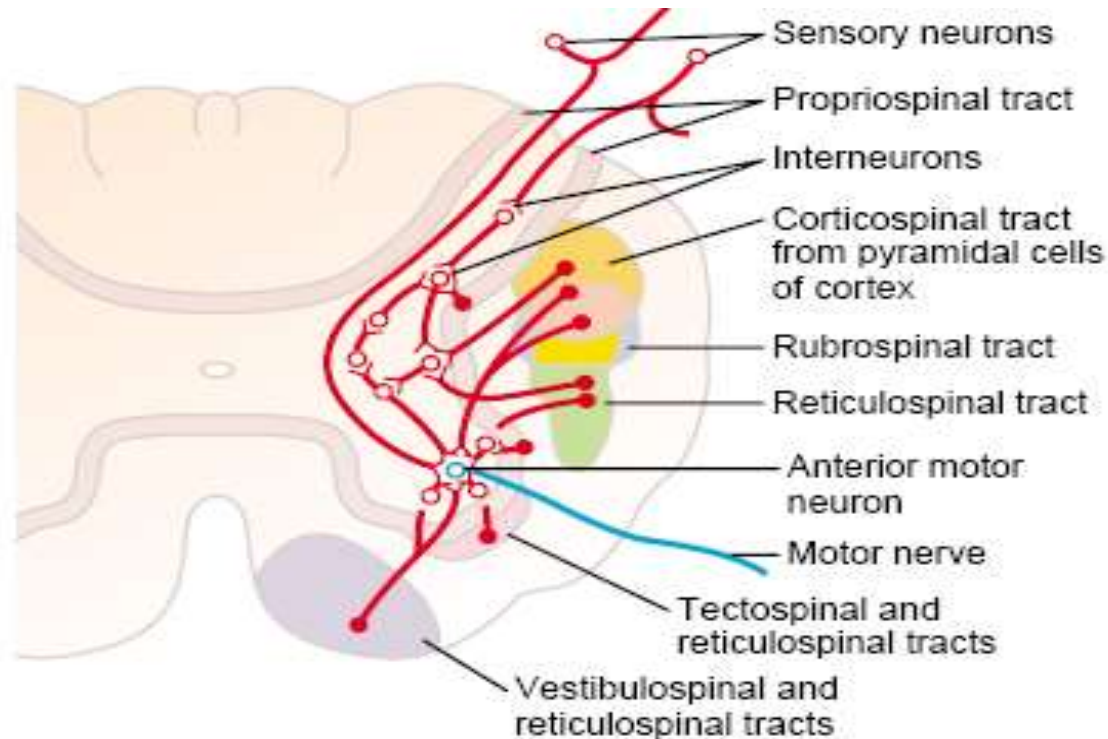
# Sensory Feedback is Important for Motor Control

- Feedback from muscle spindle, tactile receptors, and proprioceptors fine tunes muscle movement.
- Length mismatch in spindle causes auto correction.
- Compression of skin provides sensory feedback to motor cortex on degree of effectiveness of intended action.

# Excitation of Spinal Motor Neurons

- Motor neurons in cortex reside in layer V.
- Excitation of 50-100 giant pyramidal cells is needed to cause muscle contraction.
- Most corticospinal fibers synapse with interneurons.
- Some corticospinal and rubrospinal neurons synapse directly with alpha motor neurons in the spinal cord especially in the cervical enlargement.
- These motor neurons innervate muscles of the fingers and hand.

# Final Common Pathway



**Figure 55-6**

Convergence of different motor control pathways on the anterior motor neurons.

---

# Lesions of the Motor Cortex

- Primary motor cortex - loss of voluntary control of discrete movement of the distal segments of the limbs.
- Basal ganglia - muscle spasticity from loss of inhibitory input from accessory areas of the cortex that inhibit excitatory brainstem motor nuclei.

# Thank You

