



بِسْمِ اللَّهِ الرَّحْمَنِ الرَّحِيمِ

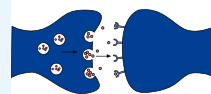


Cerebellar Motor Function

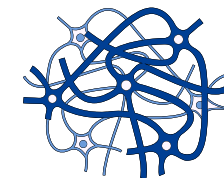
FINAL | Lecture 2

﴿ إِنِّي تَوَكَّلْتُ عَلَى اللَّهِ رَبِّي وَرَبِّكُمْ مَا مِنْ دَابَّةٍ إِلَّا هُوَ آخِذٌ بِنَاصِيَتِهَا إِنَّ رَبِّي عَلَى صِرَاطٍ مُسْتَقِيمٍ ﴾

Written by: Shahed Al-hawawsheh



Reviewed by: Mas Nafoukh



رحلة اليقين مع سورة يس

بِسْمِ اللَّهِ الرَّحْمَنِ الرَّحِيمِ

وَإِذَا قِيلَ لَهُمُ اتَّقُوا مَا بَيْنَ أَيْدِيكُمْ وَمَا خَلْفَكُمْ لَعَلَّكُمْ تُرْحَمُونَ (٤٥) وَمَا تَأْتِيهِمْ مِنْ آيَةٍ مِنْ آيَاتِ رَبِّهِمْ إِلَّا
كَانُوا عَنْهَا مُعْرِضِينَ (٤٦)

{ وَإِذَا قِيلَ لَهُمُ اتَّقُوا مَا بَيْنَ أَيْدِيكُمْ وَمَا خَلْفَكُمْ } أي: من أحوال البرزخ والقيامة، وما في الدنيا من العقوبات { لَعَلَّكُمْ تُرْحَمُونَ } أعرضوا عن ذلك، فلم يرفعوا به رأساً، ولو جاءتهم كل آية.
{ وَمَا تَأْتِيهِمْ مِنْ آيَةٍ مِنْ آيَاتِ رَبِّهِمْ إِلَّا كَانُوا عَنْهَا مُعْرِضِينَ } وفي إضافة الآيات إلى ربهم، دليل على كمالها ووضوحها، لأنه ما أبين من آية من آيات الله، ولا أعظم بياناً وإن من جملة تربية الله لعباده، أن أوصل إليهم الآيات التي يستدلون بها على ما ينفعهم، في دينهم ودنياهم.

The Cerebellum and Overall

Motor Control

Faisal I. Mohammed, MD, PhD

Objectives

- 🧐 Describe cerebellar afferents and efferents
- 🧐 Outline the functional unit of the cerebellum (circuit)

While the neuron is the functional unit of the nervous system, the Purkinje cell with its associated circuitry is considered the functional unit of the cerebellum.

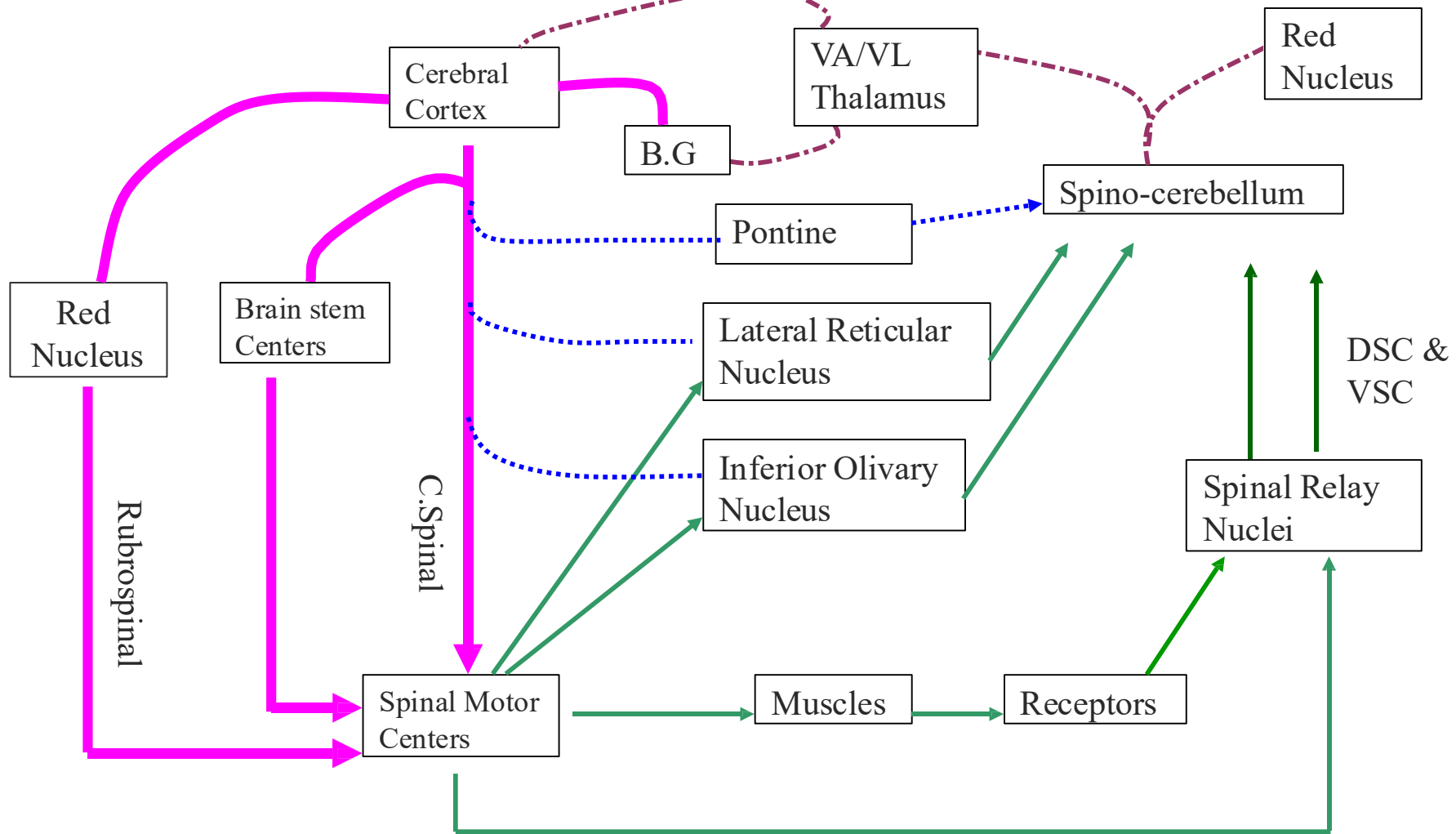
- 🧐 Explain how this unit perform the cerebellar functions
- 🧐 Recognize cerebellar abnormalities





The function of a structure in the CNS is often identified by studying the effects of damage to that structure.

Examples:

Cerebellar damage → disequilibrium → shows its role in balance.

Basal ganglia damage (e.g., in Parkinson's disease) → resting tremor → shows its role in movement control.



-  Motor Command
-  Feed Back
-  Command Monitor
-  Corrective Command

Motor System

Effective motor control requires the integration of four essential components.

1. Motor Command from the Cerebral Cortex

First, the motor command originates from the cerebral cortex, which initiates voluntary movement. Second, this command must be monitored and coordinated.

2. Monitoring of the Motor Command (Cerebellar Role)

The cerebral cortex sends monitoring signals to the cerebellum through fibers that pass via the pons, known as the **corticopontocerebellar pathway**. Within the cerebellum, these signals are analysed and compared with the intended movement. If the movement is stronger or weaker than intended, the cerebellum adjusts the output accordingly to either decrease or increase the motor activity and ensure accurate execution.

3. Feedback from Muscle Spindles

Muscle spindles detect **changes in muscle length** and play an important **predictive role** because they also sense the rate of change in muscle length, which corresponds to velocity. By detecting **velocity**, the nervous system can predict the future position of the limb before the movement is completed. This predictive capability helps determine **how long** it will take to move in a certain direction and allows for smoother and more precise movements. (Velocity= change in length / time)

4. Feedback from Golgi Tendon Organs

Golgi tendon organs provide additional feedback by sensing **changes in muscle tension**, which reflects the force of muscle contraction. Similar to muscle spindles, they also exhibit dynamic responses, meaning they can detect the rate of change in tension. Together, these proprioceptive receptors supply continuous feedback that allows the cerebellum and motor systems to fine-tune movement and maintain coordination.

The Cerebellum (little brain)

- responsible for coordinating muscle activity
- sequences the motor activities. **Normal motor movements should be smooth, coordinated, and accurately directed**
- monitors and makes corrective adjustments in the activities initiated by other parts of the brain
- compares the actual motor movements with the intended movements and makes corrective changes

The **cerebral cortex** NEVER send **precise** motor impulses. Instead, it sends **crude** signals, which are later refined and coordinated by other structures, particularly the **cerebellum**.

➤ Anatomical Parts of the Cerebellum

The cerebellum consists of the **anterior lobe** and **posterior lobe**. In the midline lies the **vermis**, and there is also a separate **flocculonodular lobe**.

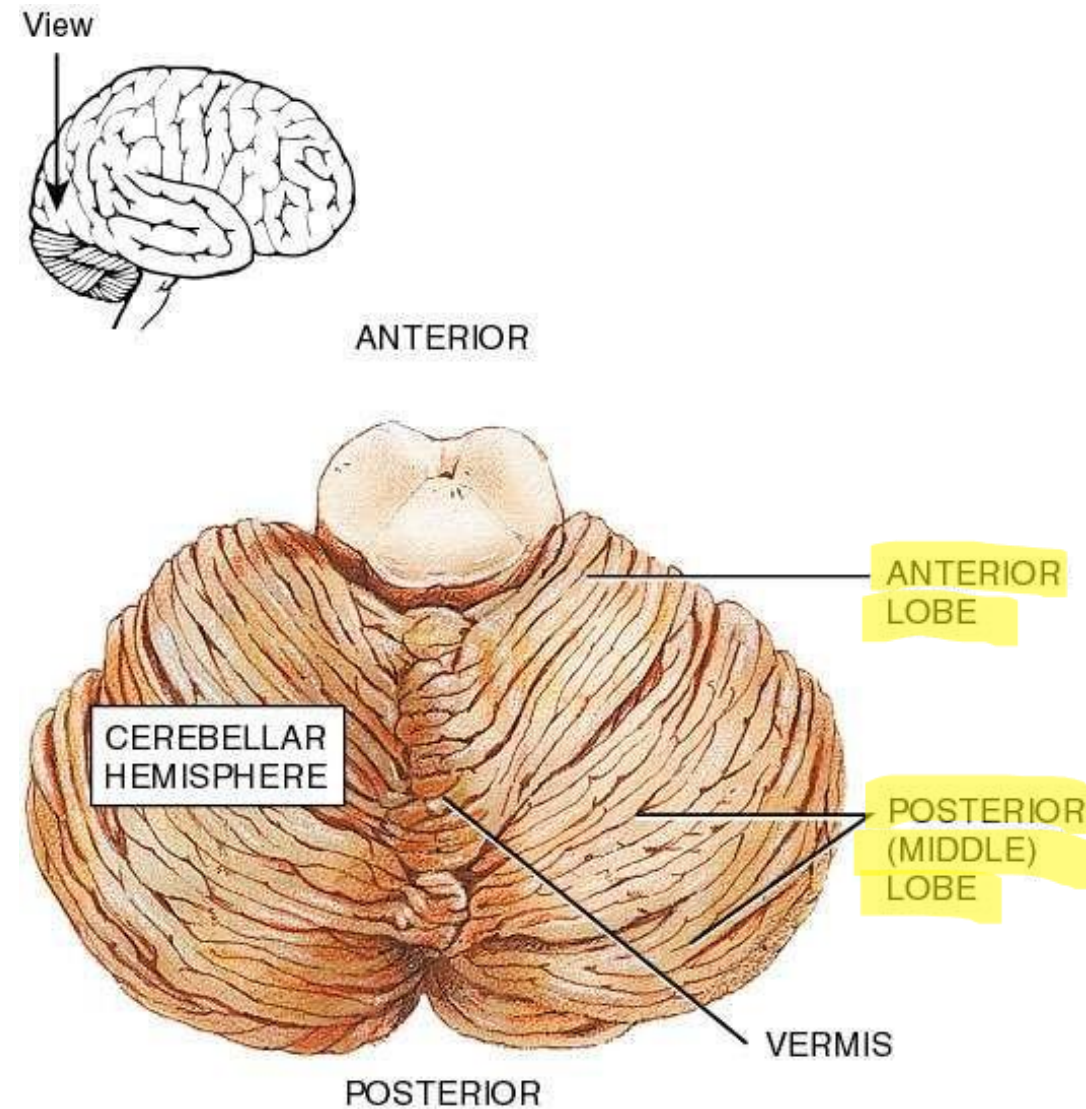
➤ Phylogenetic Division of the Cerebellum

From a phylogenetic perspective, the cerebellum is divided into three parts:

- ✓ **Archicerebellum**: the *flocculonodular lobe with the vermis*; the oldest part, mainly responsible for **balance and equilibrium**, especially important in lower animals. In other organisms it's important for higher grade of activities
- ✓ **Paleocerebellum**: mainly the *anterior lobe*, more developed and involved in **posture and muscle tone**.
- ✓ **Neocerebellum**: mainly the *posterior lobe*, the most developed part, responsible for **coordination of complex movements** in higher animals and humans.

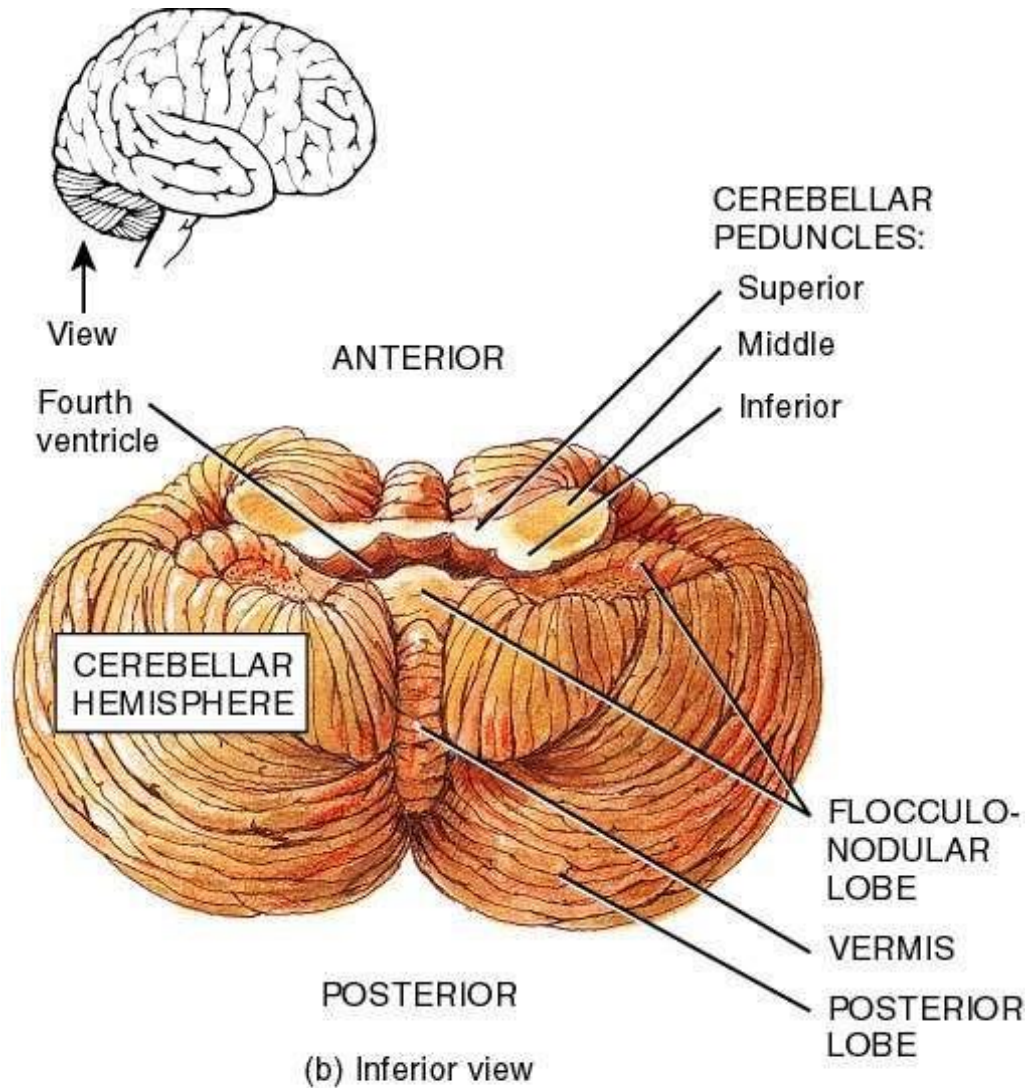
RECALL : The terms paleo and neo are also used in other pathways, such as:

- Paleospinothalamic tract → slow pain (C fibers).
- Neospinothalamic tract → fast pain (A δ fibers).



(a) Superior view

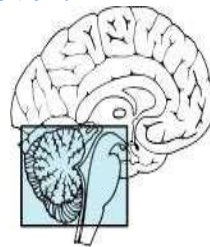
The Cerebellum



The Cerebellum

➤ Location of the Cerebellum

The cerebellum is located in the **posterior cranial fossa**. Anterior to it lies the fourth ventricle, which is filled with cerebrospinal fluid (CSF), followed by the brainstem, which consists of the medulla oblongata, pons, and midbrain.

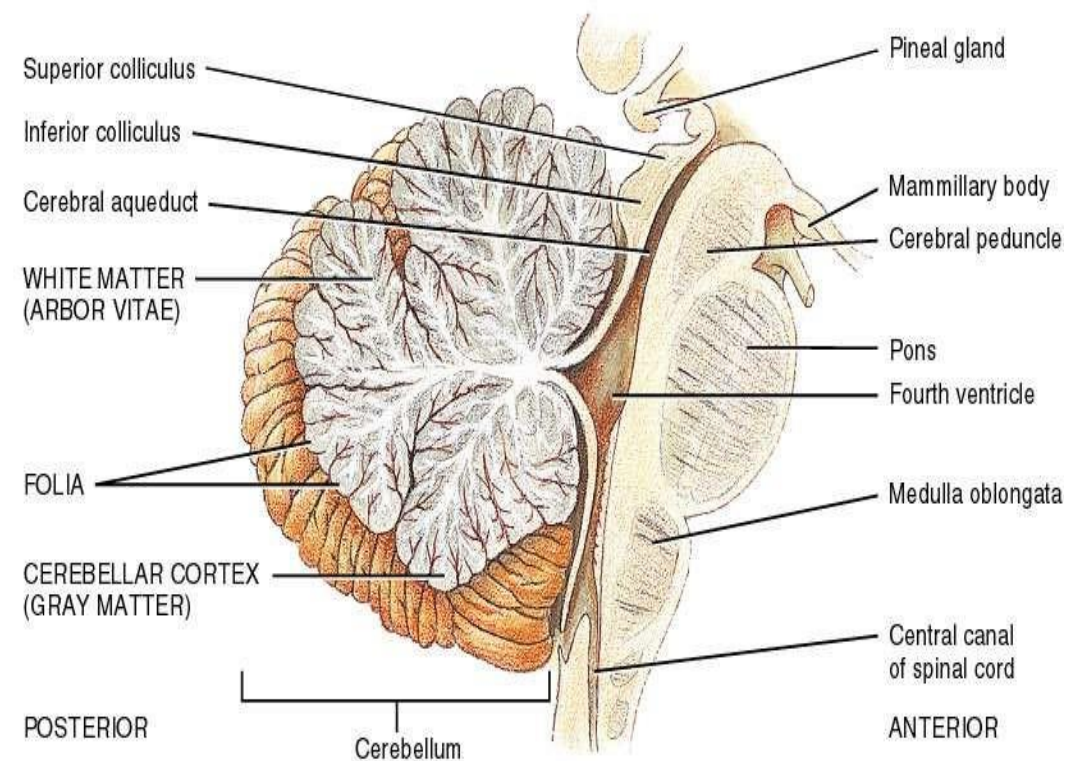


➤ Functions of the Brainstem

In addition to its **motor functions**, the brainstem contains several **vital centers**, including the *vasomotor center*, *cardiac centers*, and *respiratory centers*. It also contains **non-vital centers** such as the *vomiting*, *sneezing*, and *salivation centers*.

➤ Functional Importance of the Cerebellar Position

Because of its **strategic location**, the cerebellum lies close to the **ascending and descending neural pathways**, allowing it to monitor and coordinate signals passing through the brainstem.



(c) Midsagittal section of cerebellum and brain stem

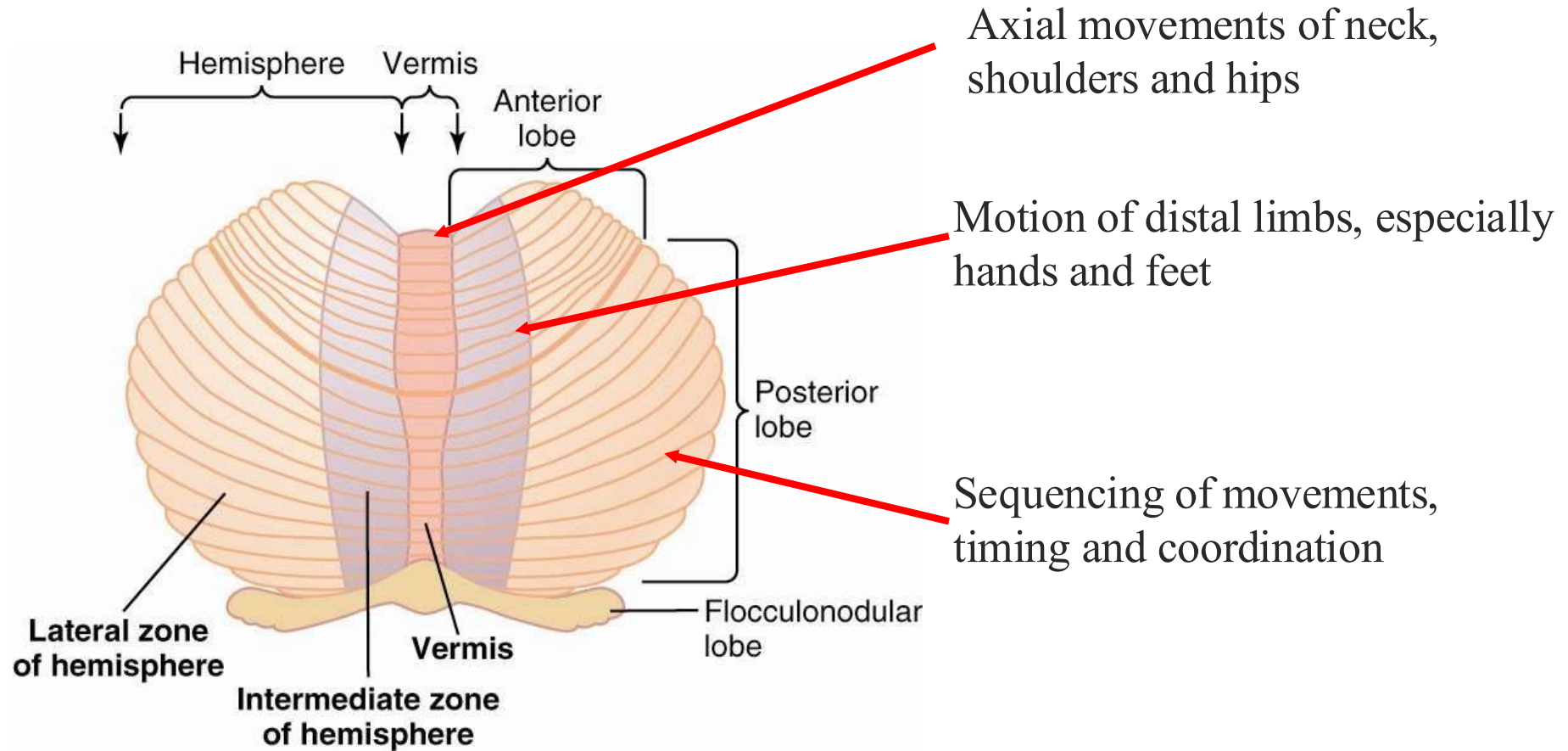
14.08c

Functional Organization of the Cerebellum

- Functionally arranged along the longitudinal axis
- *Vermis*, located at the center, controls axial movements of the neck, shoulders, and hips
- *Intermediate zone* controls motion of distal portions of upper and lower limbs especially the hands and feet
- *Lateral zone* controls sequencing movements of the muscle. Important for **timing** and **coordination** of movement.

More details in the following slides

Functional Organization of the Cerebellum



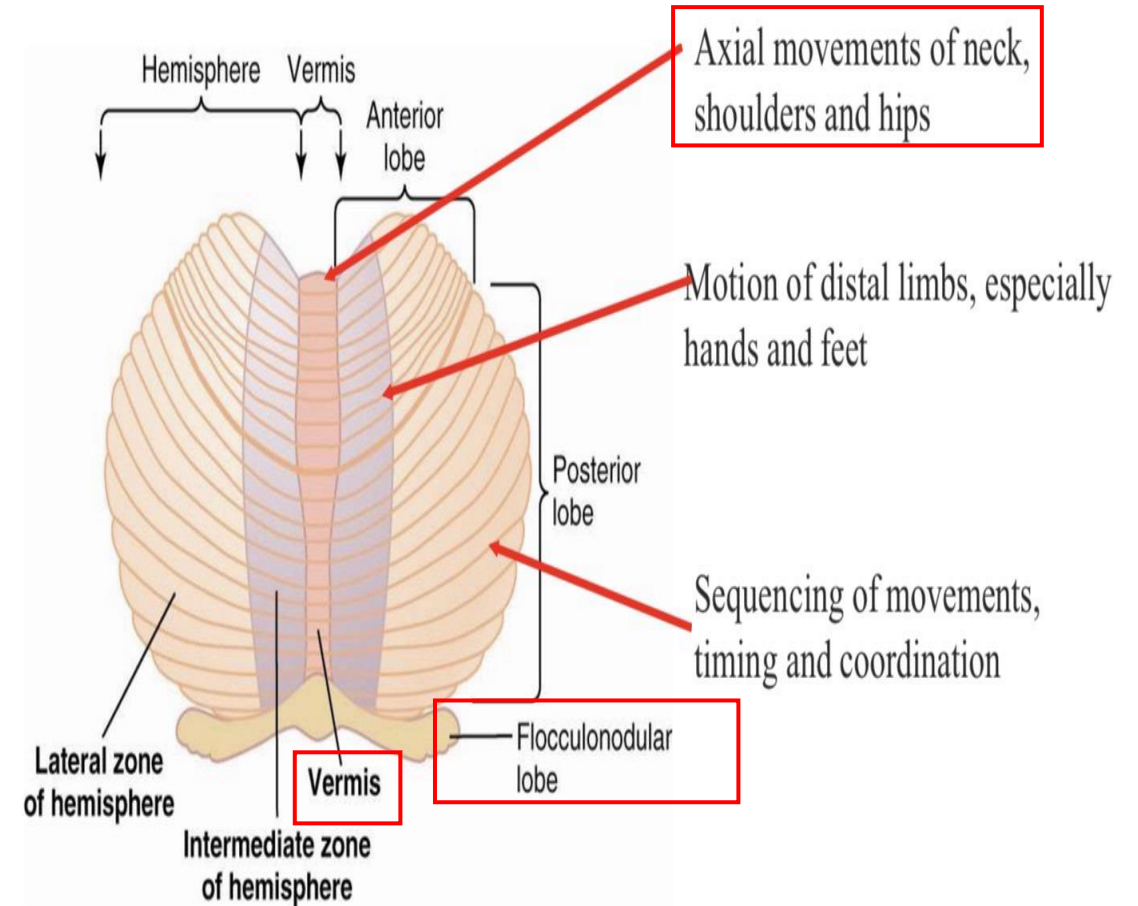
Functional Longitudinal Zones of the Cerebellum

1. Middle Zone

- Vermis
- Flocculonodular Lobe (Vestibulocerebellum)

Connections: Sometimes the flocculonodular lobe is called *vestibulocerebellum* because it is connected to the vestibular system. Receives information from the utricle, saccule, and semicircular canals → flocculonodular lobe → vestibular nuclei, with interconnections via vestibulospinal pathways.

Function: Controls **axial muscles** and large extensors of hip and shoulder girdles, maintaining balance and equilibrium.

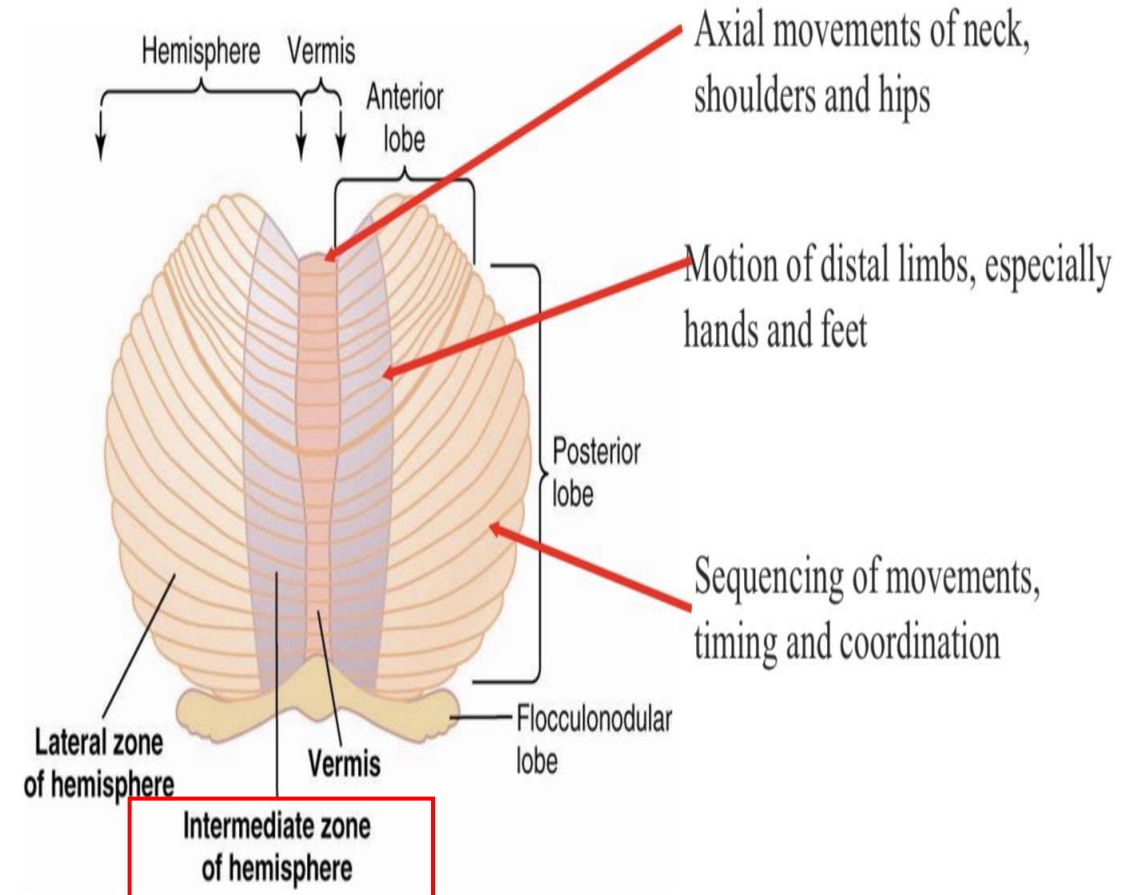


Functional Longitudinal Zones of the Cerebellum

2. Intermediate Zone (Spinocerebellum)

Connections: Located lateral to the vermis and flocculonodular lobe; receives input from the **spinal cord** via **spinocerebellar pathways**.

Function: Coordinates movements of **distal** muscles, particularly hands and feet.



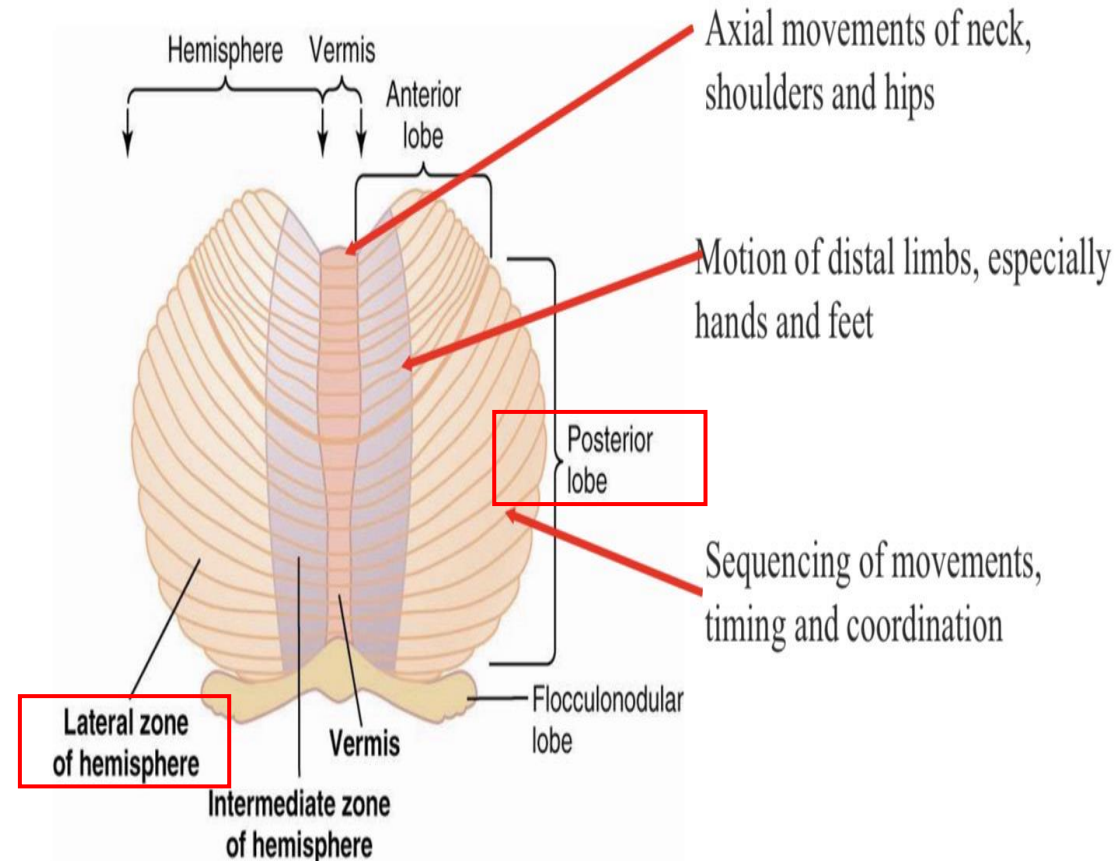
Functional Longitudinal Zones of the Cerebellum

3. Lateral Zone (Corticocerebellum / Cerebrocerebellum)

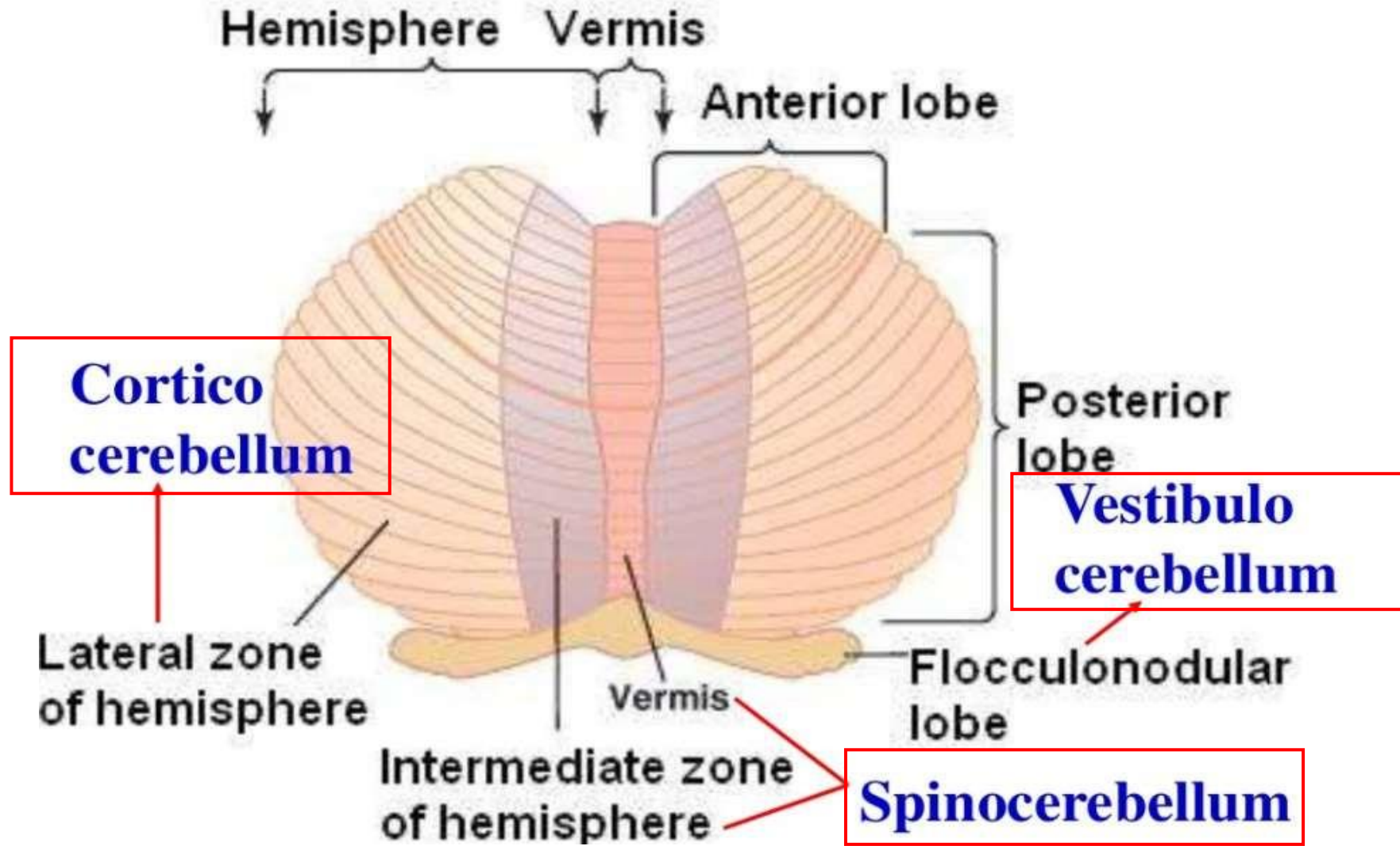
Connections: Most of the posterior lobe; receives input from the **cerebral cortex**, not from the spinal cord.

Function: Does not directly control muscles because it does not receive direct spinal cord motor unit signals. Instead, it is responsible for planning, timing, and coordination of sequential movements via corticocerebellar connections.

For example: When you want to write a word, your brain plans the letters and hand movements, but the lateral zone helps coordinate the movements of the fingers and hand so that the writing is smooth and continuous. It plays an important roles in the body's **rapid** sequential muscular activities that occur one after another within fractions of a second.



Cerebellum



Cerebellar Topographical Representation

Topographic representation is present in any part of CNS, including the cerebellum

In the **sensory cortex**, the **size** of the area representing each body part is proportional to the number of **sensory receptors** in that part.

In the **cerebellum**, the area depends on the number of **motor units**, which consist of a motor neuron and all the muscle fibers it supplies.

These motor units provide feedback about movement, allowing the cerebellum to monitor, adjust, and coordinate muscle activity. To sum up :The cerebellum coordinates movements based on motor feedback, not direct sensory input, ensuring smooth and precise motion.

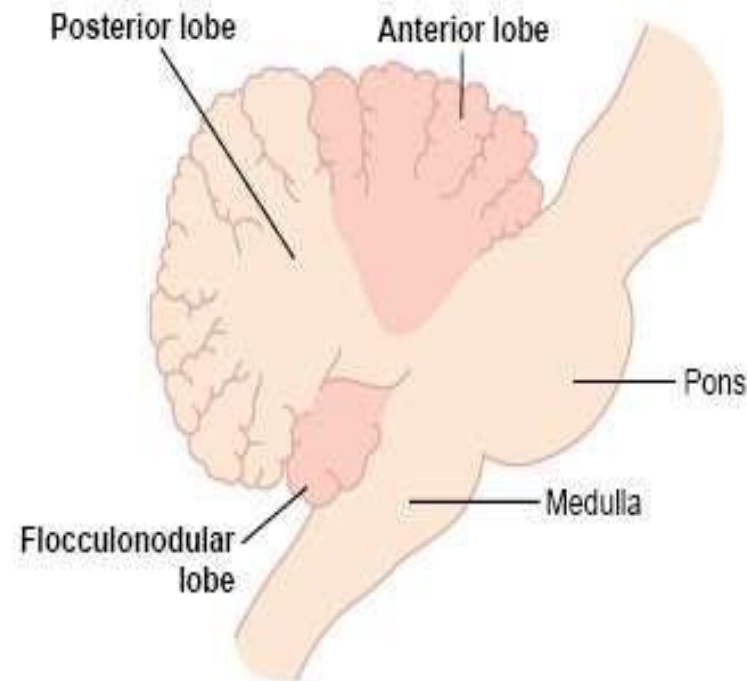
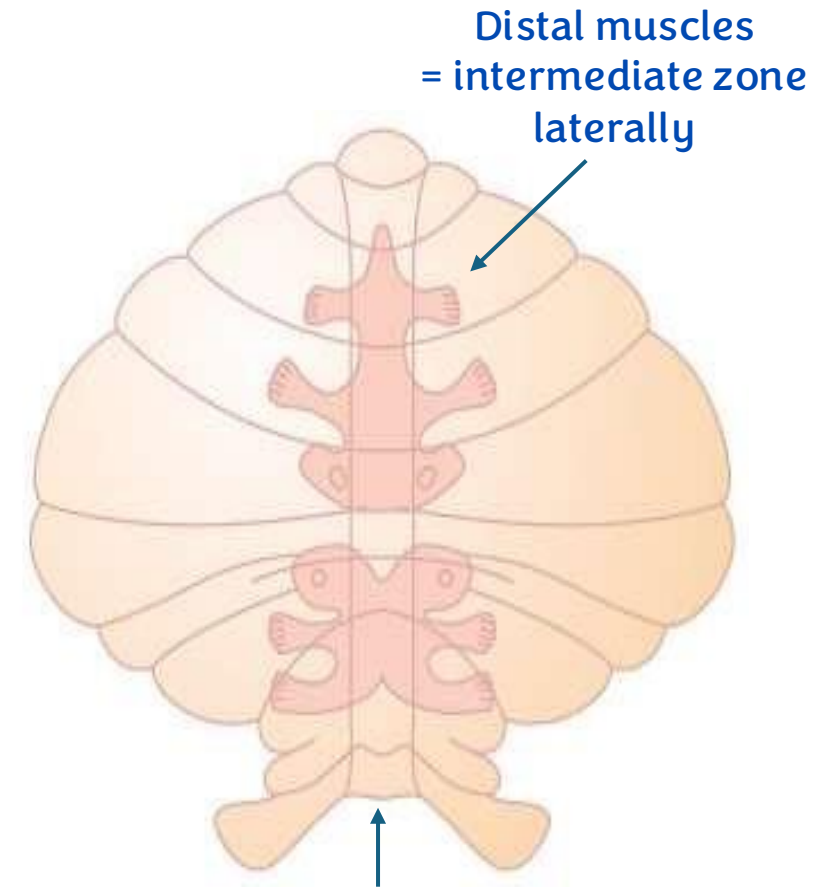


Figure 56-1



Axial muscles, hip and shoulder girdles = Vermis

Afferent Pathways to the Cerebellum 1/2

(Recall corticopontocerebellar fibers monitors the command)

■ From the brain

- *Corticopontocerebellar* pathway from **motor** and **premotor** area, **somatosensory** cortex as well as some pontine nuclei which join this tract. Projects mostly to the **lateral hemispheric** areas.

(Remember that lateral hemispheric areas do not receive information from the spinal cord)

- *olivocerebellar* tract, *vestibulocerebellar* tract, *reticulocerebellar* tract

- These pathways transmit information about intended motion.

Inferior Olive and Superior Olive

Superior Olive (sensory) Recall :

- The superior olive is part of the auditory (hearing) system. Auditory signals travel from the cochlear branch to the cochlear nuclei, cross via the trapezoid body to the superior olive, inferior colliculi → MGN and continue through the auditory pathway toward higher centers.
- The superior olive plays an important role in sound localization. It helps determine whether a sound is coming from the right or left side by comparing:

1. The time difference between when the sound reaches each ear (**time lag**).

2. The difference in sound **intensity** between the two ears.

For example, if a sound comes from the right side, it reaches the right ear slightly earlier and with greater intensity than the left ear.

Inferior Olive (Motor)

- The inferior olive is connected with the cerebellum via the **olivocerebellar tract** and plays an important role in motor coordination and motor learning, sending signals that help the cerebellum refine and adjust movements.

MGN : medial geniculate nucleus

Afferent Pathways to the Cerebellum 2/2

- from the periphery

- *dorsal spinocerebellar tract* - transmits information mostly from **muscles spindle** but also from **Golgi tendon organs**, **large tactile (pacinian corpuscles)**, and **joint receptors**. It is **uncrossed tract (ipsilateral tract)**
 - appraises the brain of the momentary status of muscle contraction (**length**), muscle tension and limb position and forces acting on the body surface
- *ventral spinocerebellar tract* - signals from anterior horn, and interneurons (efference copy) the integrated signal from the final common pathway before it goes to the muscle. It is bilateral tract
 - transmits information on which signals have arrived at the cord

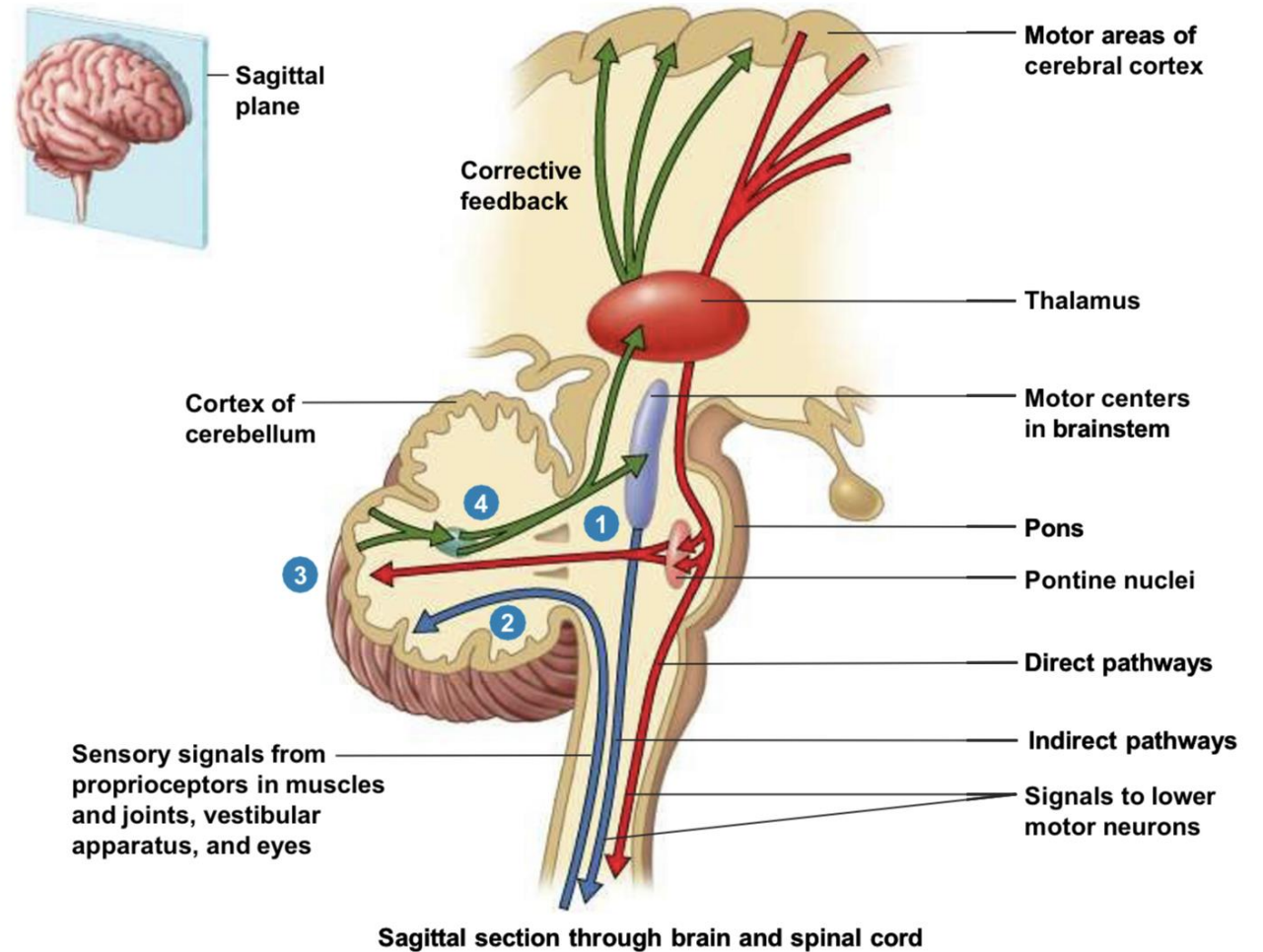
check next slide...

Ventral Spinocerebellar Tract

- The ventral spinocerebellar tract does **not** originate from sensory receptors. Instead, it arises from neurons that are closely related to the **α -motor neuron**, which is responsible for sending motor signals to the muscles.
- The **α -motor neuron receives synaptic inputs from** several descending pathways, including: Corticospinal tract, Vestibulospinal tract, Reticulospinal tract, Inputs from pontine and medullary centers.
- Each synapse produces either an excitatory postsynaptic potential (**EPSP**) or an inhibitory postsynaptic potential (**IPSP**). These inputs are summed together (**summation**) in the motor neuron, producing a final integrated signal (**grand potential**) that is **sent to the muscle to cause contraction**.
At the same time, the **ventral spinocerebellar tract sends a copy (efference copy)** of this grand potential to the **cerebellum**.
- This allows the cerebellum to receive information about:
 - The intended movement (from brain)
 - The force and length of the muscle (from dorsal spinocerebellar tract)
 - The motor signal being sent to the muscle (from ventral spinocerebellar tract)
- The cerebellum then **compares these different inputs** to help coordinate and adjust movement. Importantly, the ventral spinocerebellar tract **transmits information about the motor signal itself, not the actual muscle contraction**.

Strategic Location of the Cerebellum

- The cerebellum lies behind the brainstem, giving it a strategic position to monitor many neural pathways.
- It receives proprioceptive sensory input from muscles and joints through the **dorsal spinocerebellar tract**, and motor information from the cerebral cortex via the **corticopontocerebellar tract**.
- After processing, the cerebellum sends **corrective signals** to the **cerebral cortex** through the **thalamus**. It is also related to the **reticular formation**, which gives rise to the **reticulospinal tract** that influences spinal motor activity.



Spinocerebellar tracts – summary

Dorsal (Posterior) Spinocerebellar Tract

Origin: Proprioceptors in muscles and joints

Second-order neurons: Clarke's nucleus (you don't have to memorize)

Course: Ascends ipsilaterally in the spinal cord.

Function: Carries unconscious proprioception about muscle length and position.

Ventral (Anterior) Spinocerebellar Tract

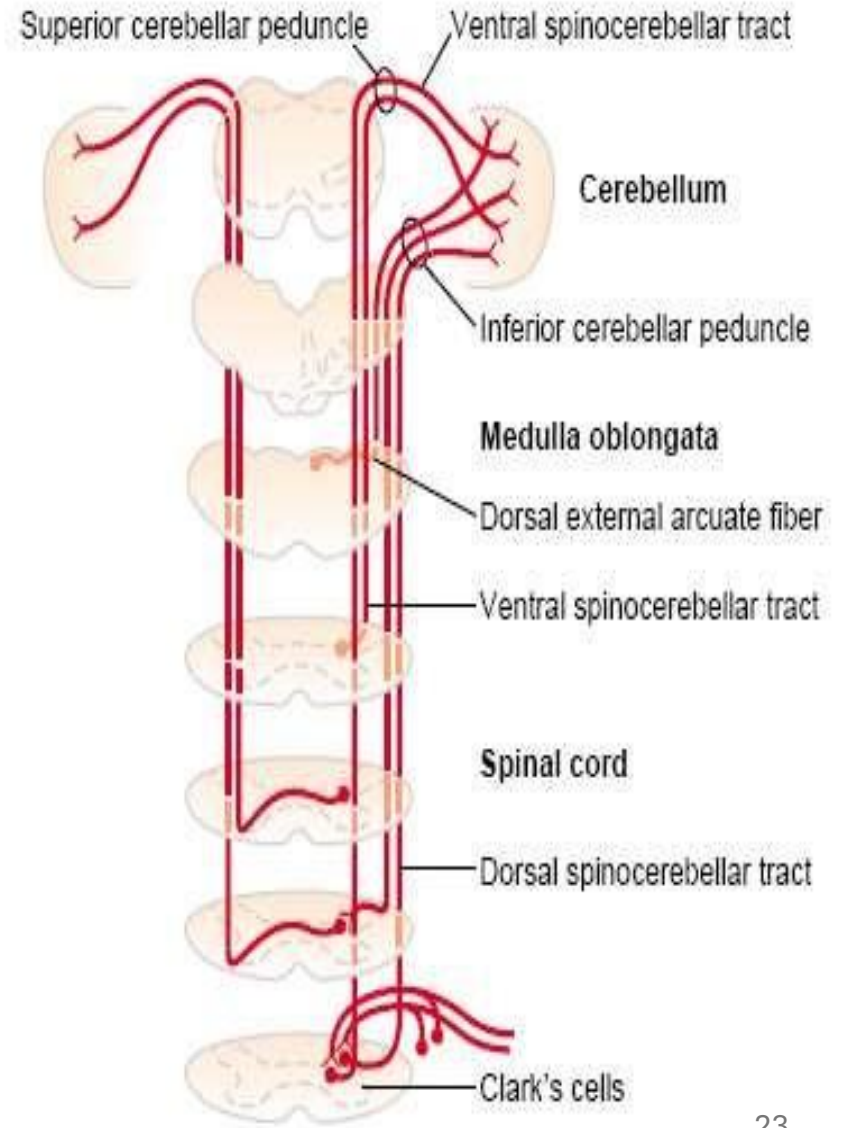
Origin: Neurons in the spinal cord related to α -motor neuron activity.

Information carried: A copy of the motor signal going to the muscles.

Course: Fibers cross in the spinal cord, ascend to the brainstem.

(bilateral tract)

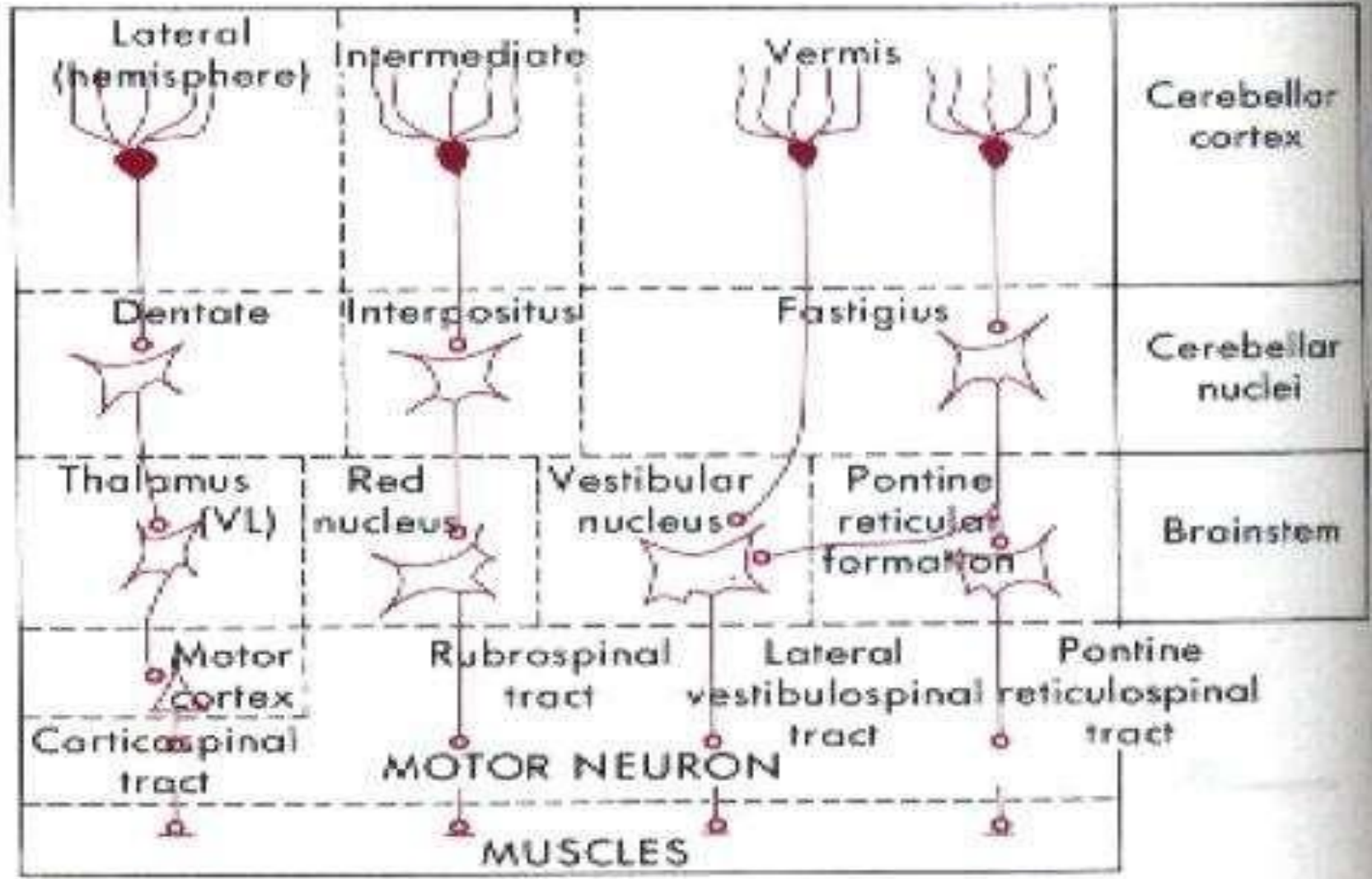
Function: Provides the cerebellum with information about the motor commands sent to the muscles for comparison and coordination.



Efferent Pathways from the Cerebellum

- All efferents go out from deep cerebellar nuclei
- Vermis— (fastigial nucleus) fastigioreticular tract and from cerebellar cortex directly to lateral vestibular nuclei. (i.e. vestibular nuclei are functionally deep cerebellar nuclei)
 - equilibrium control
- Intermediate zone— (interpositus nucleus = Globos and Emboliform)
Interpositorubral tract, fine voluntary movements of distal muscles
- Lateral hemisphere— (dentate nucleus) dentatothalamocortical tract
 - coordinates agonist and antagonist muscle contractions

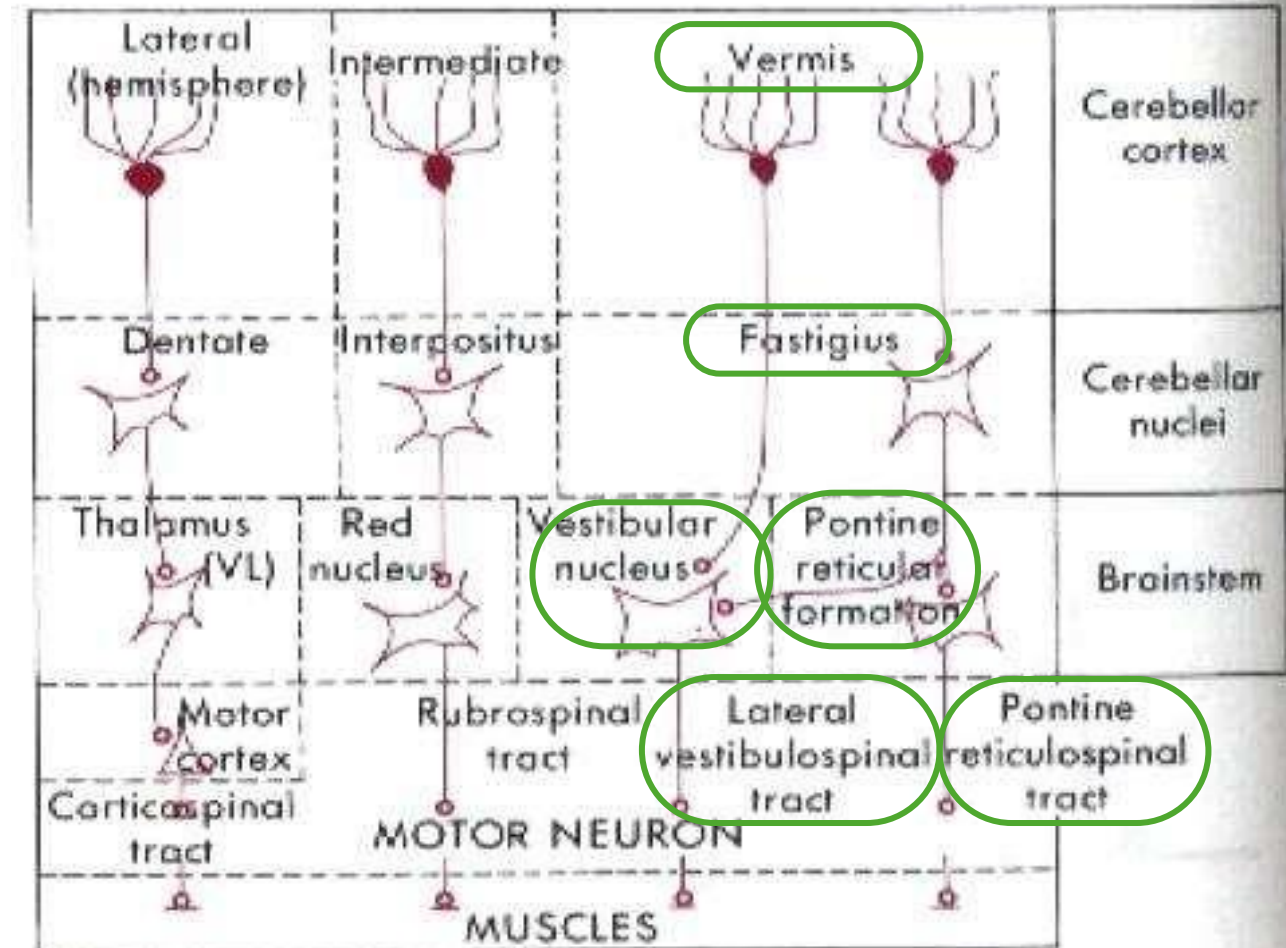
Efferents of the cerebellum



Efferents of the cerebellum

Vermis

- Efferent fibers from cerebellar cortex in the **vermis** pass to the **fastigial nucleus**, one of the deep cerebellar nuclei. From the fastigial nucleus, signals are transmitted to the **pontine reticular formation**, which then sends output to the **axial muscles** of the neck, shoulder, and hip girdles through the **pontine reticulospinal tract**.
- In some cases, fibers from the **vermis** project directly to the **vestibular nuclei** **without** passing through the fastigial nucleus and the signal continues to the muscles through the lateral vestibulospinal tract.
- Therefore, the vestibular nuclei functionally work as a deep cerebellar nucleus but not anatomically.



Efferents of the cerebellum

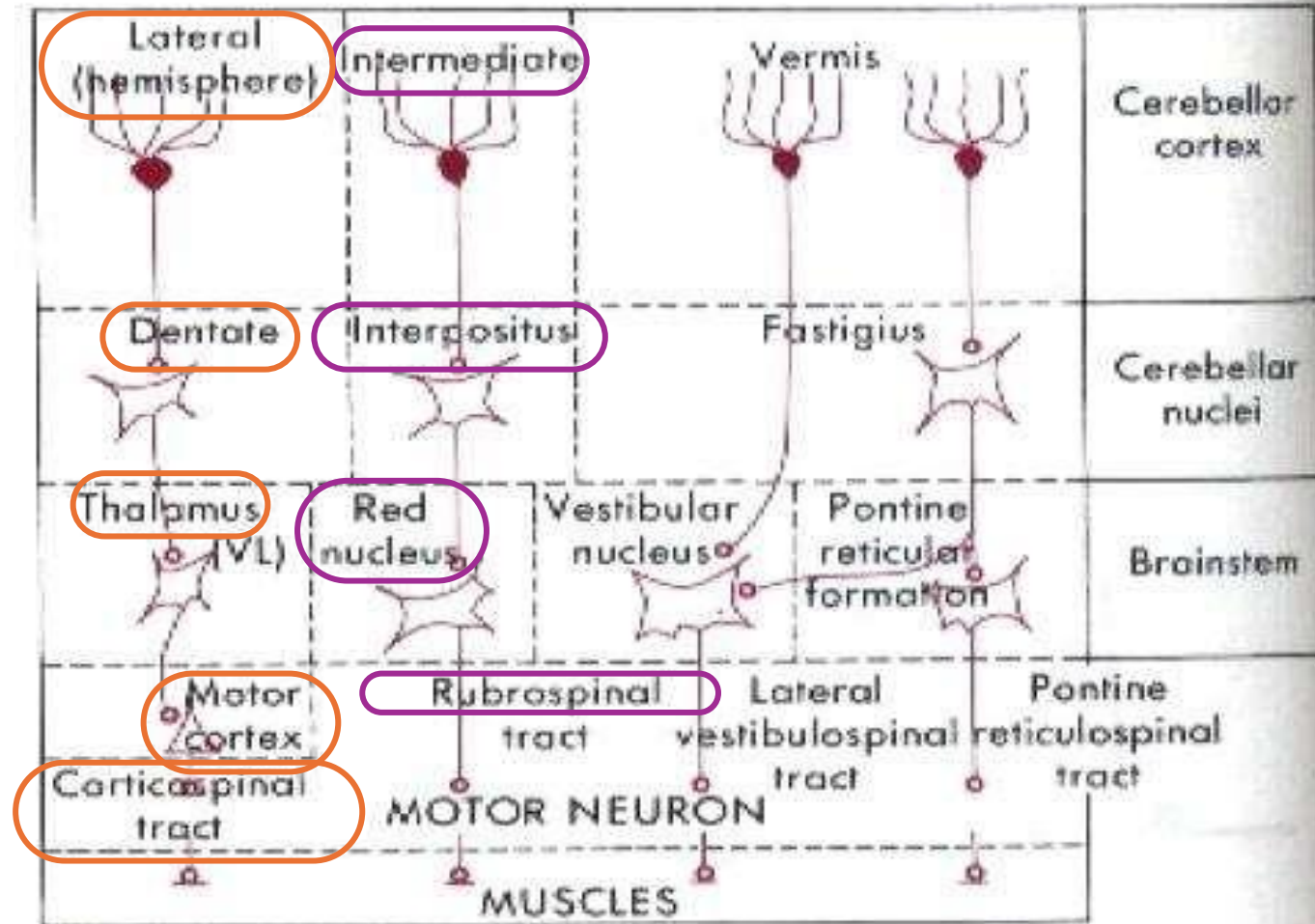
➤ **Intermediate zone:**

Fibers go to the **Interpositus nucleus** (Globose+Emboliform).

Fibers go from interpositus nucleus to the **red nucleus**, then to large flexors through the **Rubrospinal tract**.

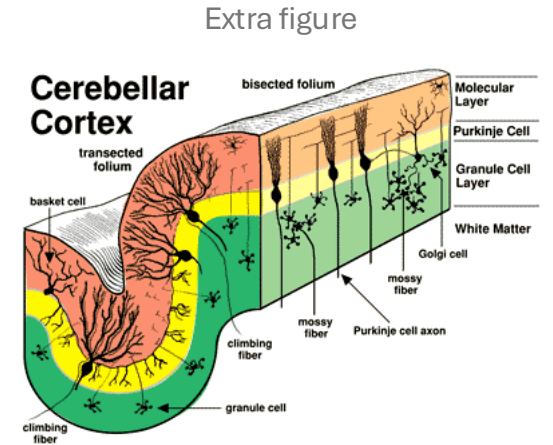
➤ **Lateral zone:**


Signal From the **Dentate nucleus** goes to the **thalamus** (VA,VL), then to the **motor cortex**, from the cortex the signal goes to the spinal cord through the **corticospinal tract** as a **corrected command**.



Neuronal Organization of the Cerebellar Cortex

- The cerebellar cortex is organized in three layers
 - molecular cell layer (outer layer)
 - Purkinje cell layer (middle layer)
 - granular cell layer (inner layer)
- output from the cerebellum comes from a deep nuclear cell layer (gray matter) located below these layers of cortex





**PHYSIOLOGY
QUIZ
LECTURE 2**

اللهم إن عمر عطية في ذمتك وحبل جوارك، فقه من فتنة القبر وعذاب النار،
أنت أهل الوفاء والحق، فاغفر له وارحمه إنك أنت الغفور الرحيم.

عيد فطر سعيد

تقبّل الله منّا و منكم صالح الأعمال

وكلّ عام وأنتم بخير !

Scan the QR code or click it for FEEDBACK



Corrections from previous versions:

Versions	Slide # and Place of Error	Before Correction	After Correction
V0 → V1			
V1 → V2			