

**The University Of Jordan
Faculty Of Medicine**



Male genital system

By

Dr.Ahmed Salman

Associate Professor of Anatomy

Learning Objectives

1. Identify External and Internal male organs.
2. Discusses different scrotal layers.
3. Know different content of the scrotum.
4. Learn anatomy of the penis.
5. Identify structure of prostate.
6. Know the course and relation of vas deferens .
7. Enumerate blood , nerve supply and lymphatic drainage of External male genitalia

Male External Genital Organs

1. Scrotum
2. Testis
3. Epididymis
4. Spermatic cord
5. Penis

The scrotum

The scrotum is a cutaneous pouch

Contents :

Testis, epididymis and lower part of the spermatic cord (of both sides).

Layers of scrotum

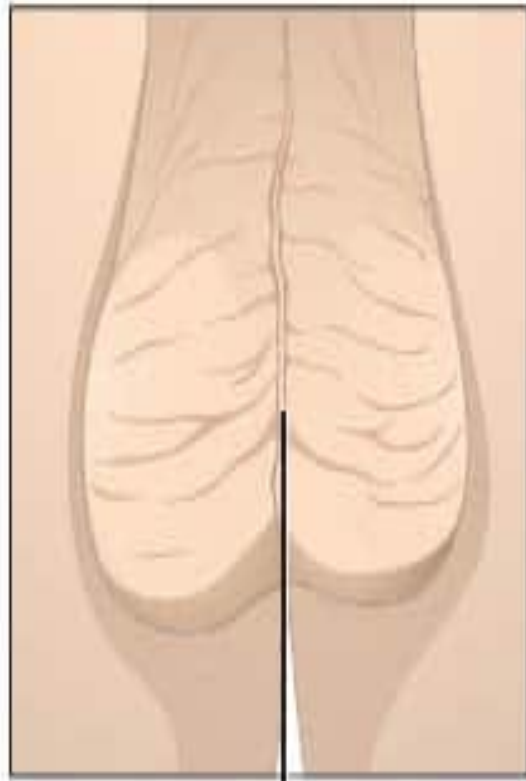
Skin :-

The skin of the scrotum is pigmented, rugose and is marked by a longitudinal median raphe.

Superficial fascia of the scrotum:-

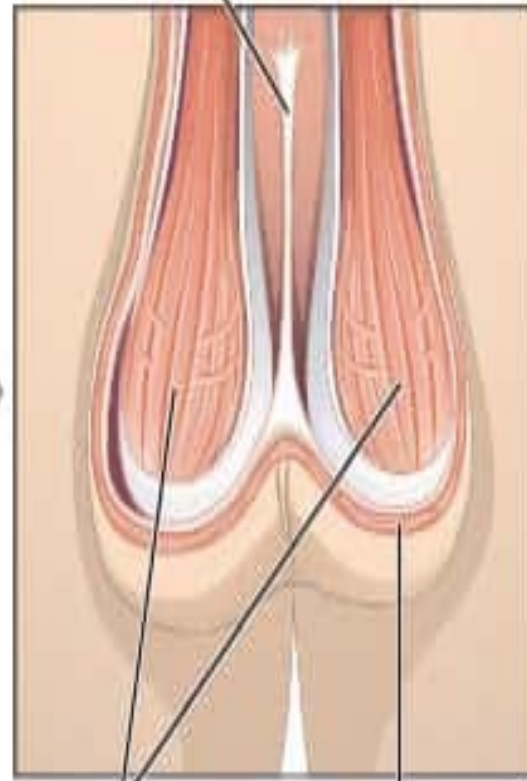
- The **fatty layer** is absent (to assist heat loss) and is replaced by the subcutaneous involuntary muscle fibers called dartos muscle .The muscle aids heat regulation of testis and scrotum.
- The **deep membranous** layer of the scrotum is called Colles' fascia. It is continuous superiorly with Scarpa's fascia of the anterior abdominal wall

External view of scrotum



Raphe

Muscle layer

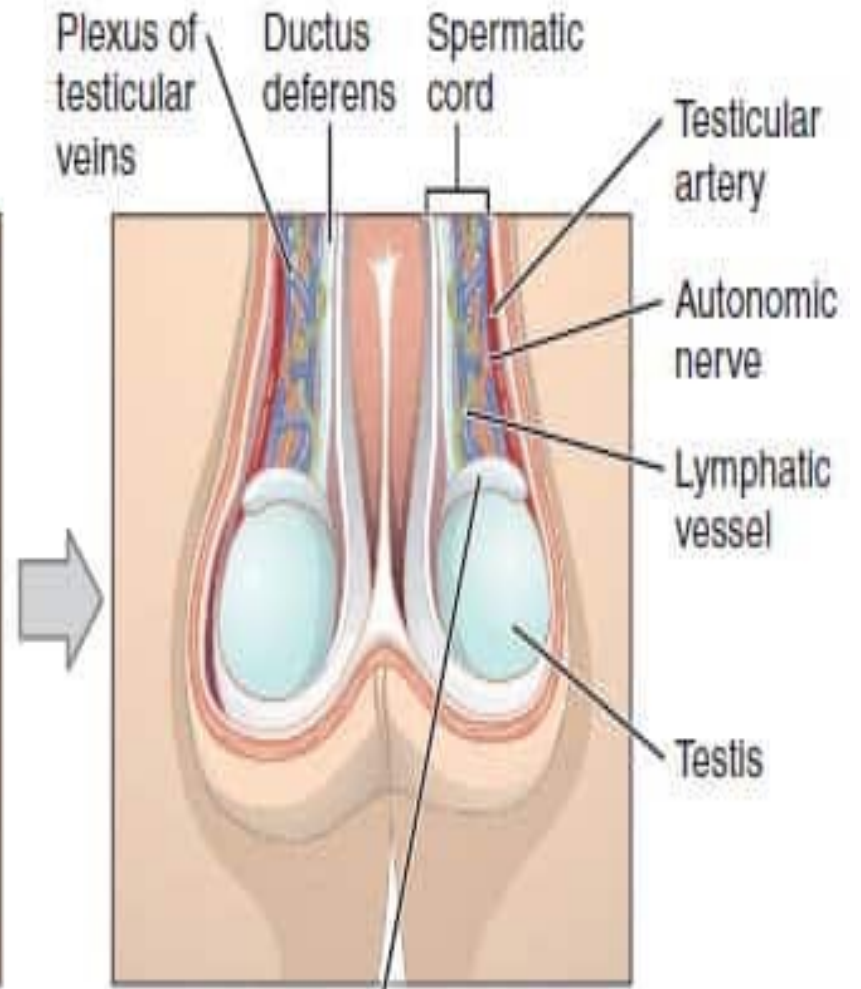


Scrotal septum

Cremaster muscles

Dartos muscles

Deep tissues



Plexus of testicular veins

Ductus deferens

Spermatic cord

Testicular artery

Autonomic nerve

Lymphatic vessel

Testis

Epididymis

Dartos muscle

- ❑ Smooth muscle of the fat-free subcutaneous tissue of the scrotum (dartos fascia), which inserts into the skin, assisting testicular elevation as it produces contraction of the skin of the scrotum.
- ❑ It is supplied by **sympathetic nerve** fibres reaching it through the genital branch of the genitofemoral nerve

Cremaster muscle

- ❑ Is formed by the lowermost fascicles of the internal oblique muscle arising from the inguinal ligament
- ❑ The cremaster muscle reflexively draws the testis superiorly in the scrotum, particularly in response to cold.
- ❑ In a warm environment, the cremaster relaxes and the testis descends in the scrotum
- ❑ It is supplied by **genital branch** of the genitofemoral nerve

Cremasteric Reflex :

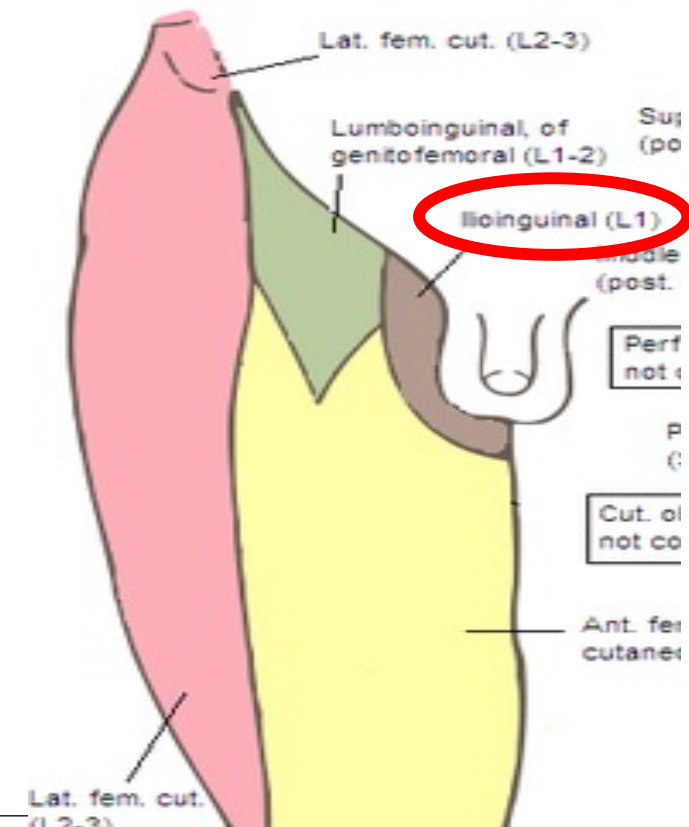
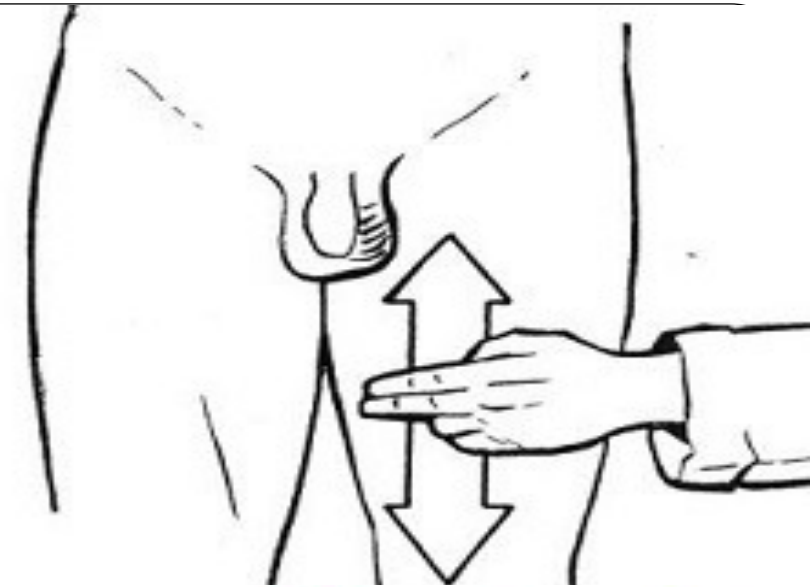
Contraction of the cremaster muscle is caused by lightly stroking the skin on the medial aspect of the superior part of the thigh leads to rapid elevation of the testis on the same side

Afferent:

Ilioinguinal nerve

Efferent :

Genital branch of the genitofemoral nerve



Layers of scrotum

Layers of the scrotum

Skin

Superficial fascia

Replaced by Dartos muscle

Deep membranous layer (Fascia of Colles)

External spermatic fascia

Cremastric muscle and fascia

Internal spermatic fascia

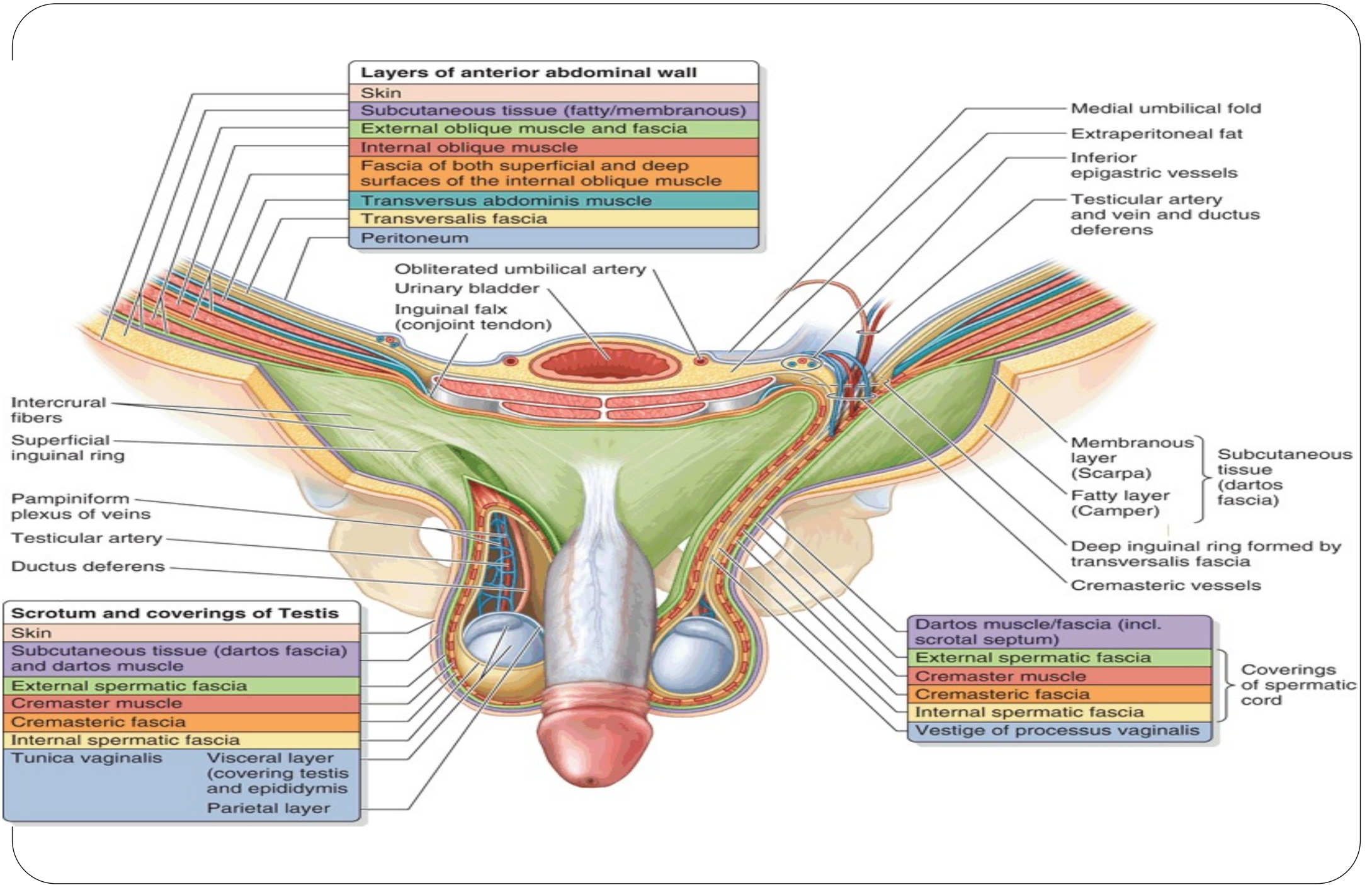
Loose connective tissue

Tunica vaginalis around the testis

READ ONLY

A comparison between layers of scrotum and that of anterior abdominal wall

Layers of the anterior abdominal wall	Layers of the scrotum
Skin	Skin
Superficial fascia Superficial fatty layer Deep membranous layer (Scarpa's fascia)	Superficial fascia Replaced by Dartos muscle Deep membranous layer (Fascia of Colles)
External oblique muscle	External spermatic fascia
Internal oblique muscle	Cremastric muscle and fascia
Transversus abdominis	<i>No corresponding layer</i>
Transversus fascia	Internal spermatic fascia
Extraperitoneal tissue	Loose connective tissue
Peritoneum	Tunica vaginalis around the testis



Layers of anterior abdominal wall	
Skin	
Subcutaneous tissue (fatty/membranous)	
External oblique muscle and fascia	
Internal oblique muscle	
Fascia of both superficial and deep surfaces of the internal oblique muscle	
Transversus abdominis muscle	
Transversalis fascia	
Peritoneum	

Obliterated umbilical artery
 Urinary bladder
 Inguinal falx (conjoint tendon)

Medial umbilical fold
 Extraperitoneal fat
 Inferior epigastric vessels
 Testicular artery and vein and ductus deferens

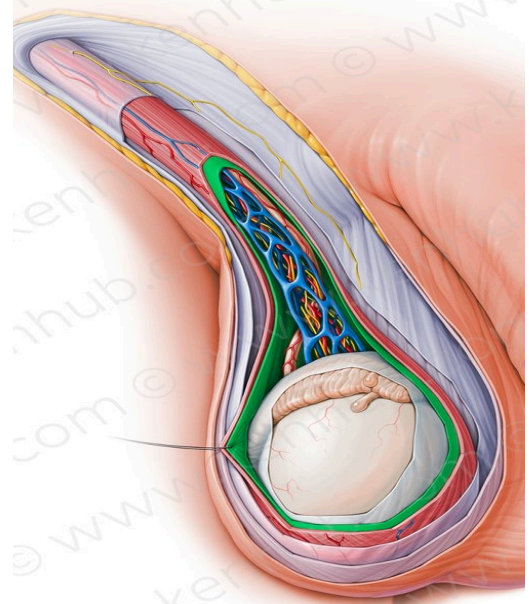
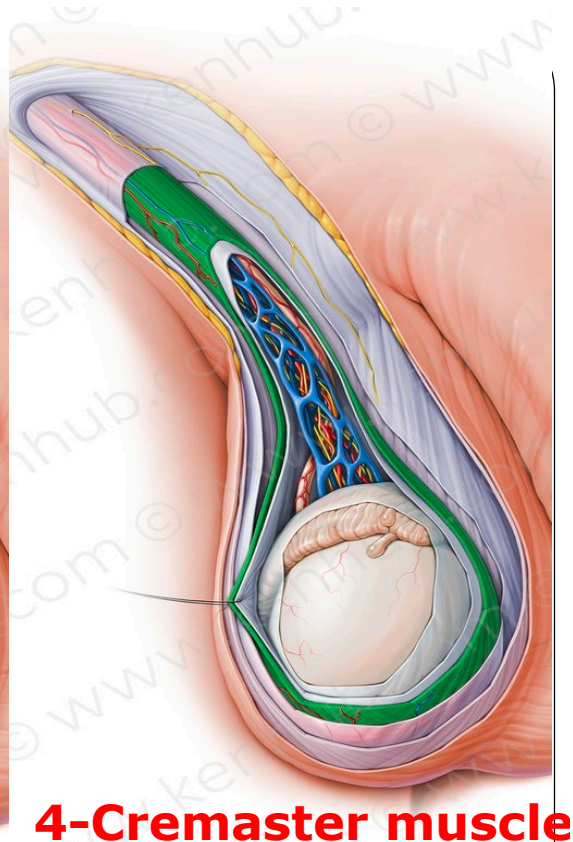
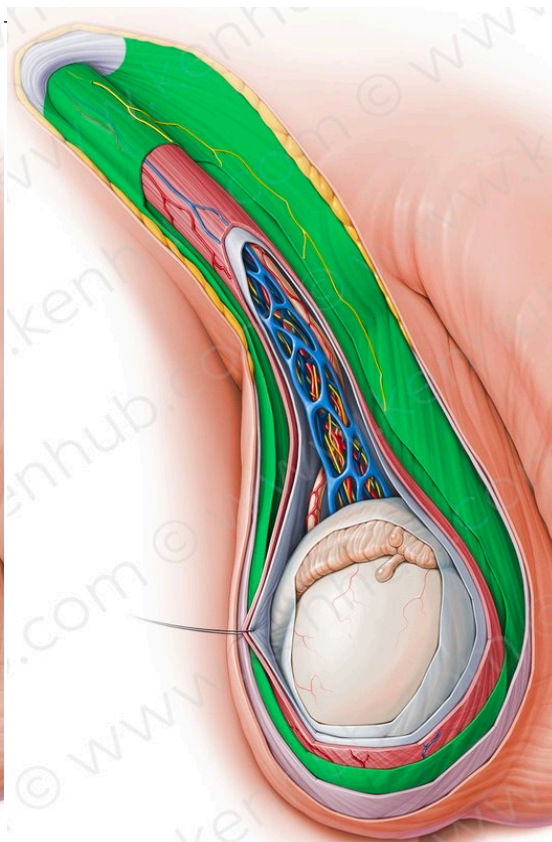
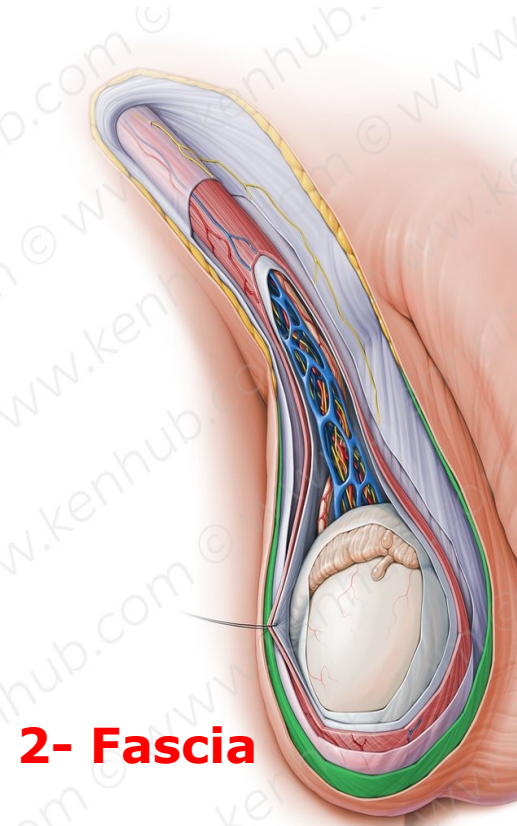
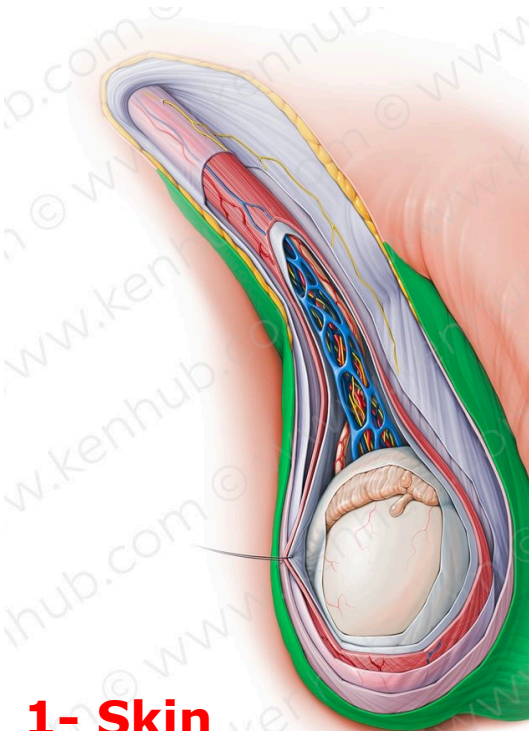
Intercrural fibers
 Superficial inguinal ring
 Pampiniform plexus of veins
 Testicular artery
 Ductus deferens

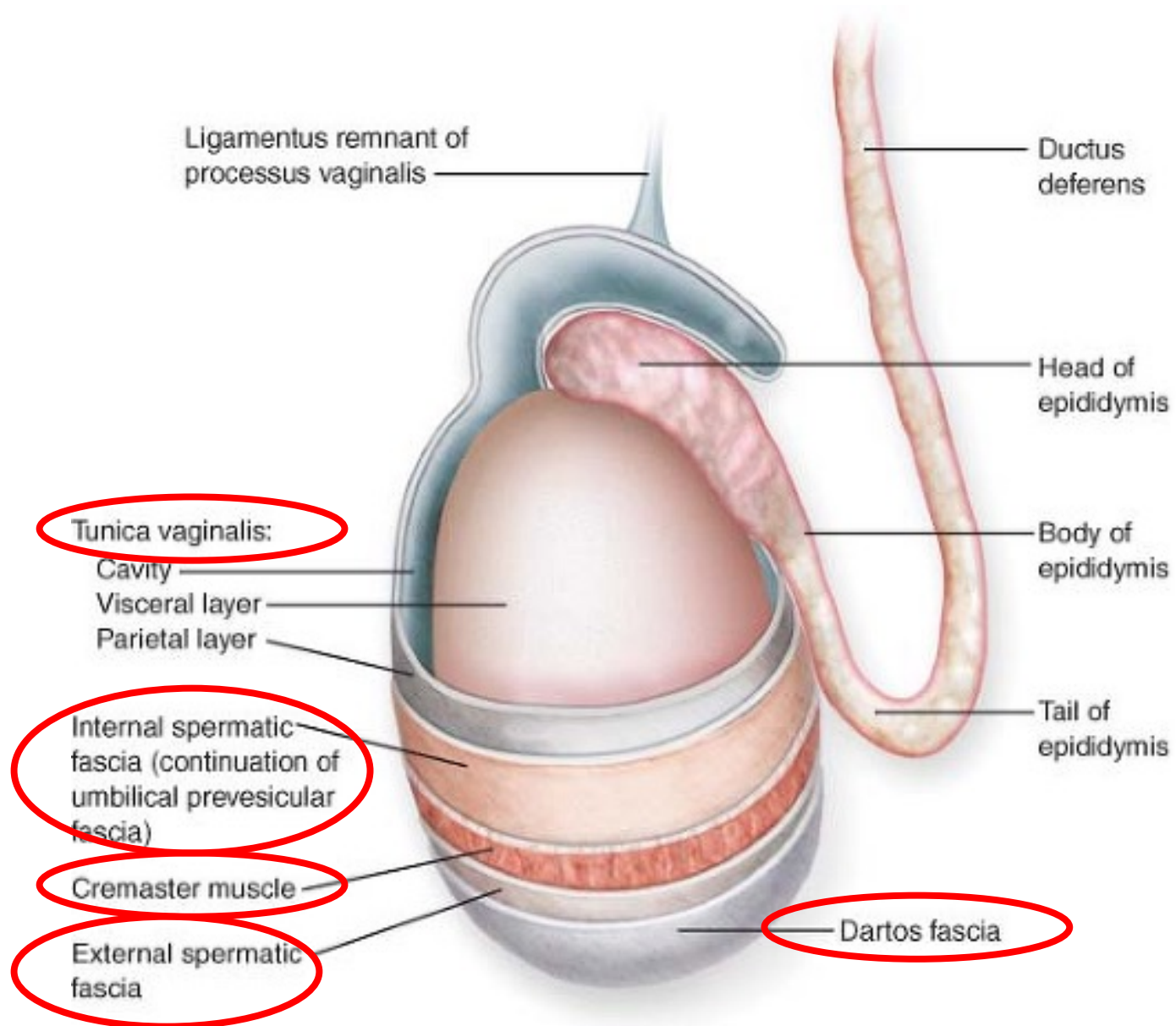
Membranous layer (Scarpa)
 Fatty layer (Camper)
 Deep inguinal ring formed by transversalis fascia
 Cremasteric vessels

Scrotum and coverings of Testis	
Skin	
Subcutaneous tissue (dartos fascia) and dartos muscle	
External spermatic fascia	
Cremaster muscle	
Cremasteric fascia	
Internal spermatic fascia	
Tunica vaginalis	Visceral layer (covering testis and epididymis)
	Parietal layer

Dartos muscle/fascia (incl. scrotal septum)
External spermatic fascia
Cremaster muscle
Cremasteric fascia
Internal spermatic fascia
Vestige of processus vaginalis

Coverings of spermatic cord





Blood supply :-

- ❖ Cremastic branch of the **inferior epigastric artery**
- ❖ Superficial and deep external pudendal branches of **femoral artery**
- ❖ Scrotal branches of **internal pudendal artery**.

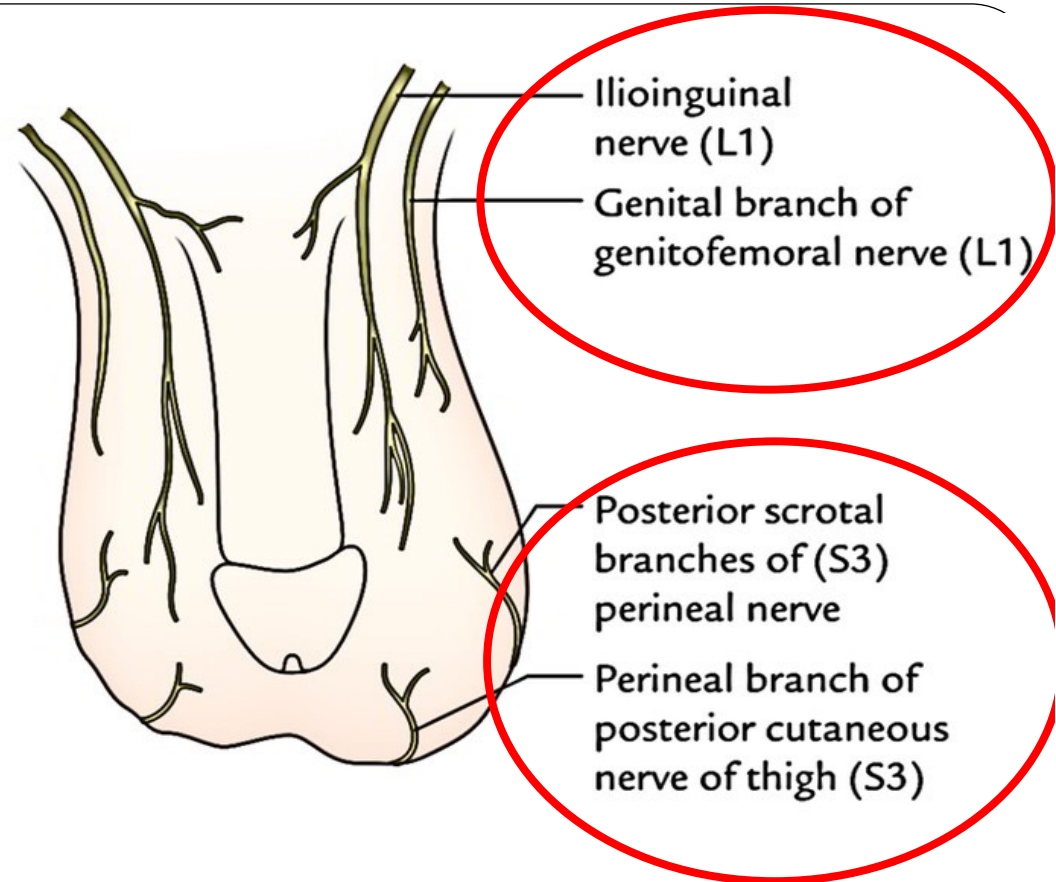
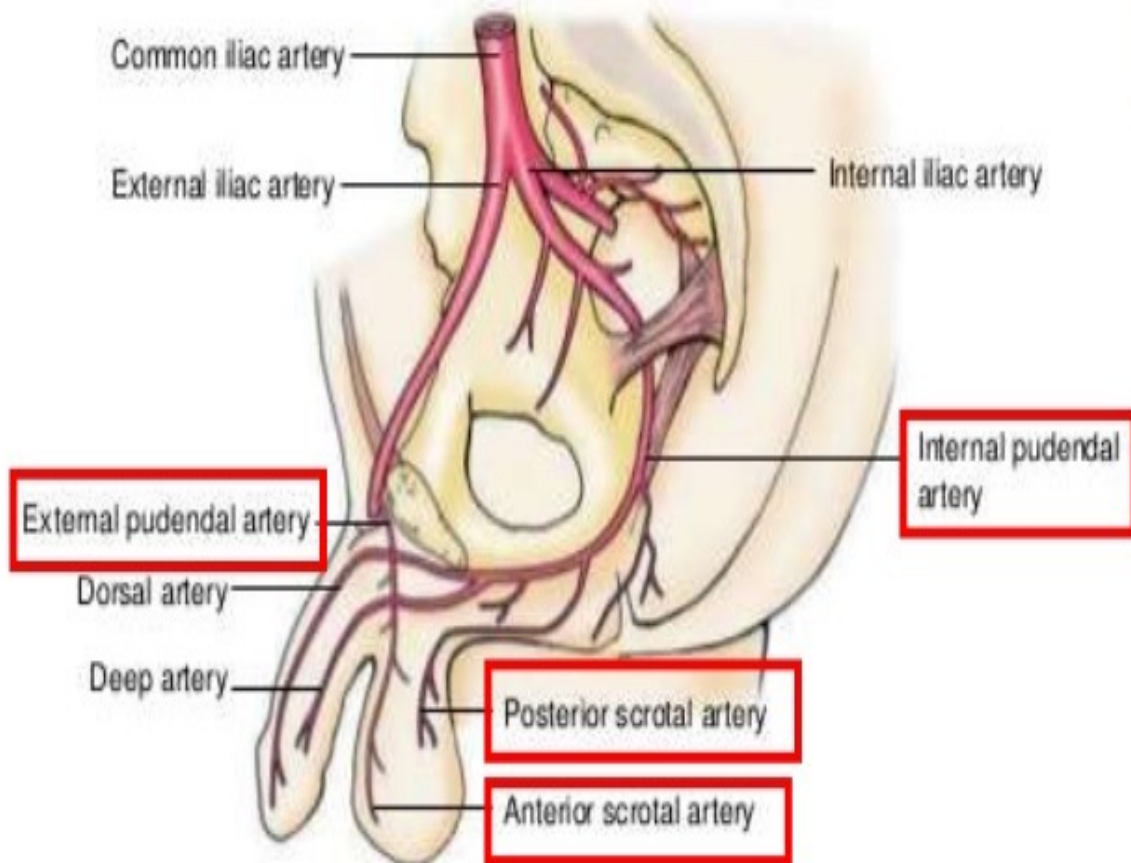
Nerve supply :-

- Anterior 1/3: Ilioinguinal nerve (L1 dermatome) + genital branch of genitofemoral N.
- Posterior 2/3: Scrotal branches of pudendal nerve and posterior cutaneous nerve of the thigh (S3 dermatome).

Lymphatic drainage :-

Superficial inguinal lymph nodes.

Blood supply of scrotum:



Testis

- Testis is the male primary sex organ, suspended in the scrotum by the spermatic cord.
- The testis develops at the upper part of posterior abdominal wall, then descends into scrotum

Testis has 2 poles, (the upper and lower), **2 borders**, (anterior and posterior), and **2 surfaces**, (medial and lateral).

The epididymis (which is a long-coiled duct) forms a cap at the upper pole of the testis, descending lateral to the posterior border towards its lower pole.

Coverings (tunics) of the testis : From outside inwards

1. Tunica vaginalis: It is the lower part of the processus vaginalis of the peritoneum.

It is invaginated by the testis from behind

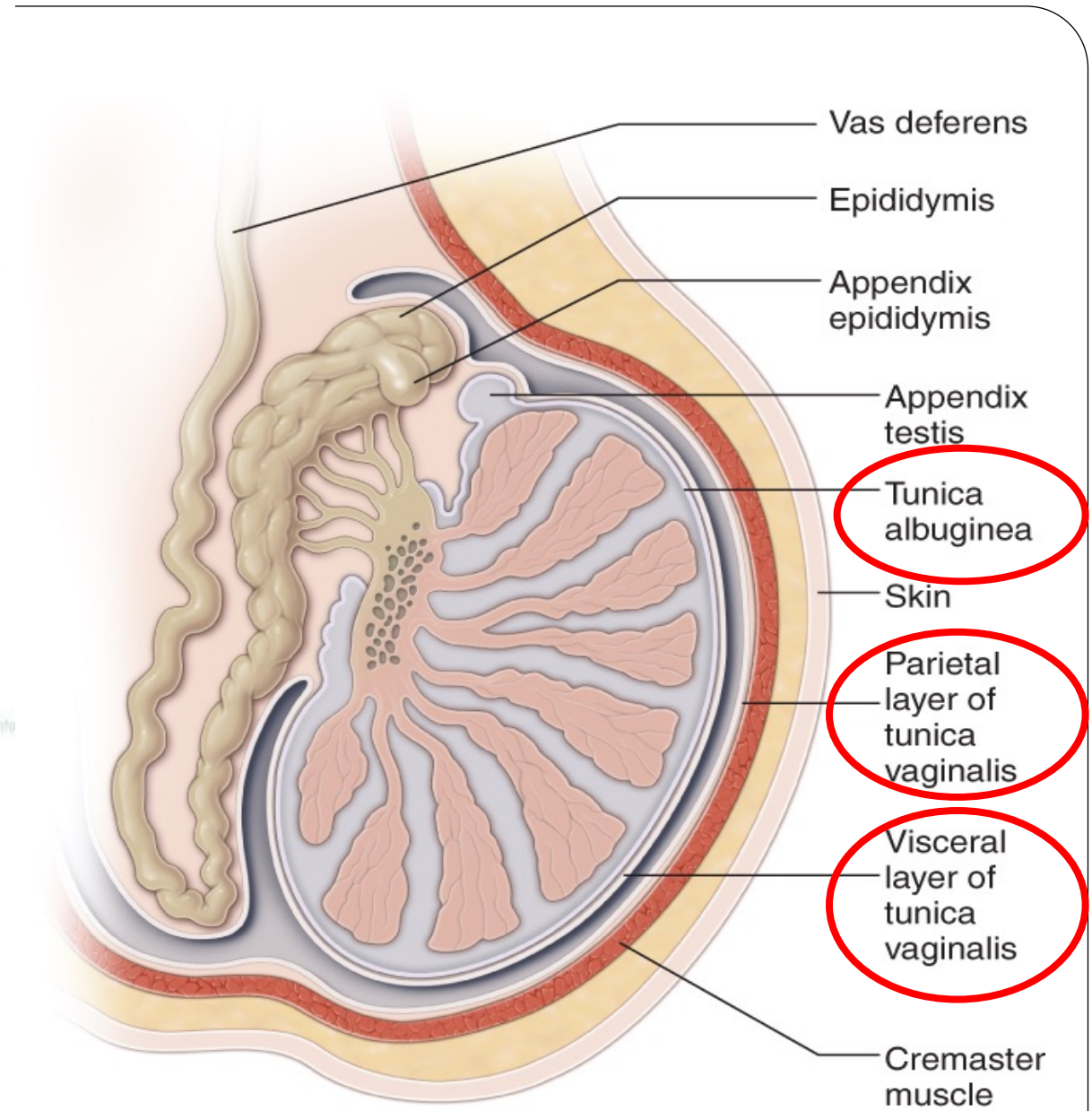
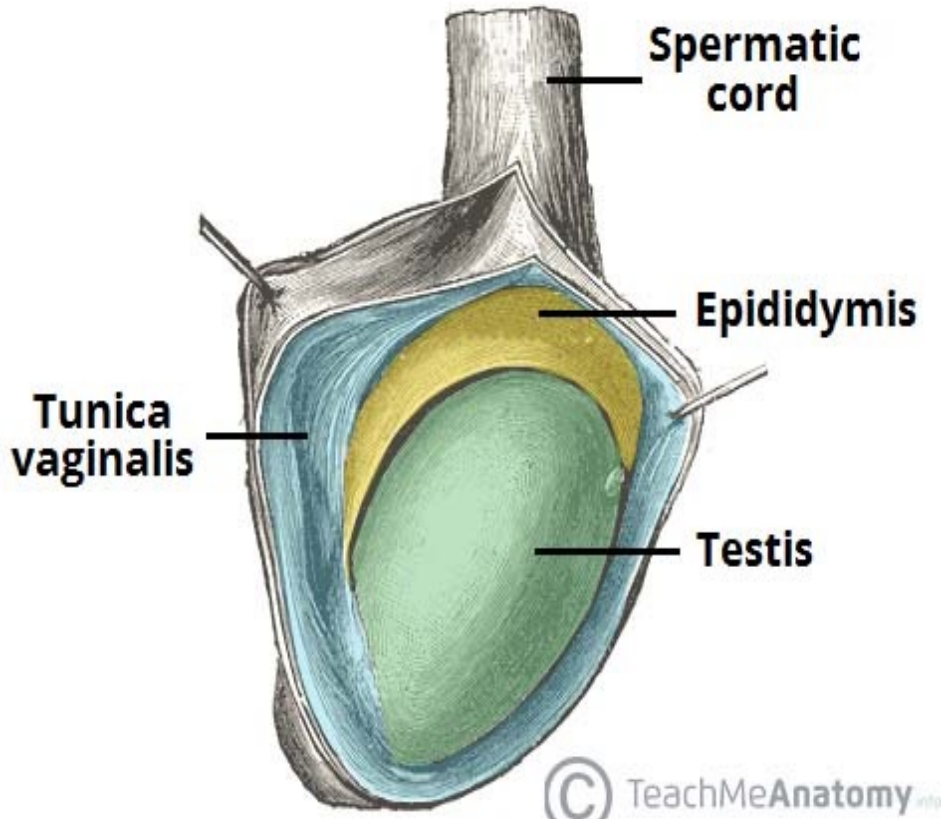
It has parietal and visceral layers with a cavity in between .

The tunica vaginalis covers the whole testis except its posterior border.

Sinus of epididymis is that part of the cavity of tunica vaginalis which extends between lateral side of testis and the epididymis .

2. Tunica albuginea: It is the tough white fibrous coat which covers the testis all around.

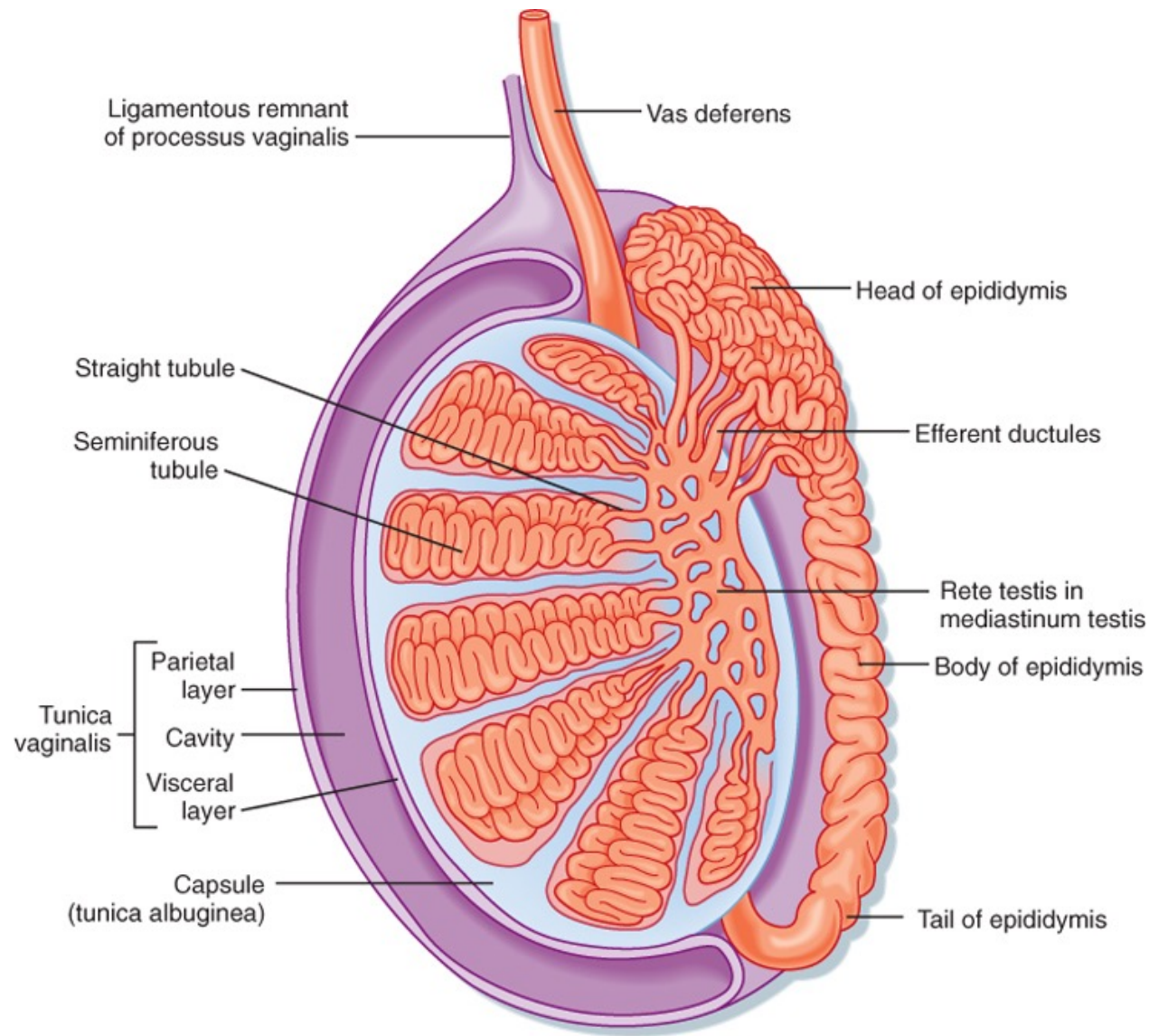
3. Tunica vasculosa: It is formed of vascularized connective tissue, deep to the tunica albuginea and extends between the lobules of the testis

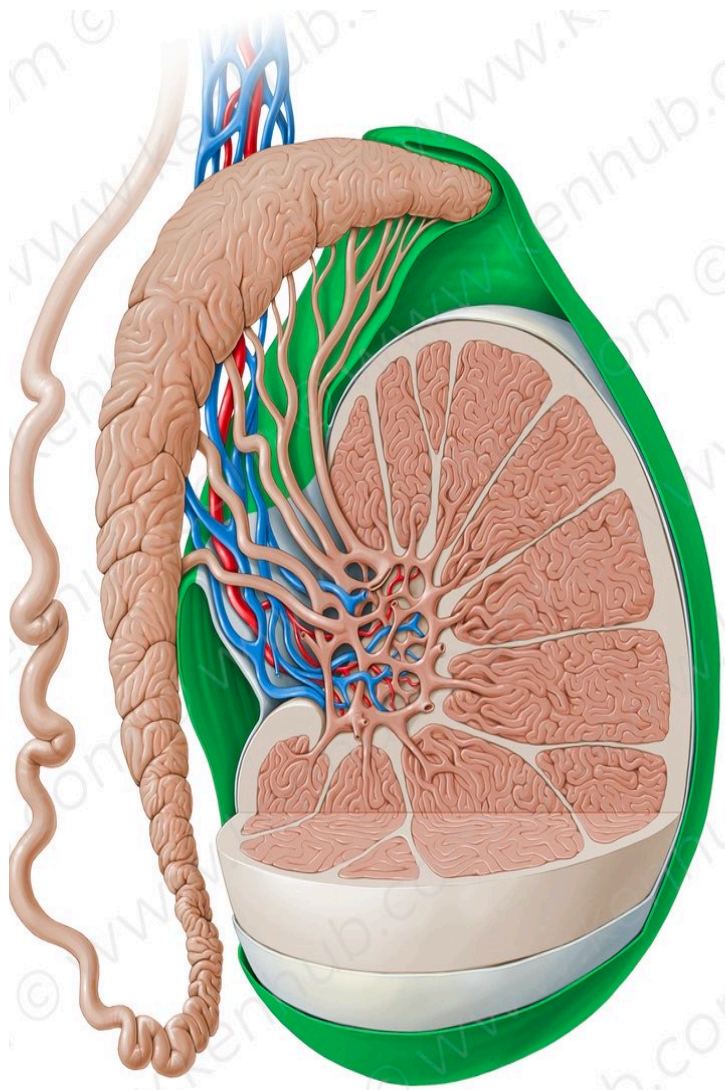


Source: Ma OJ, Mateer JR, Reardon RF, Joing SA: *Ma and Mateer's Emergency Ultrasound, Third Edition*: www.accessemergencymedicine.com
 Copyright © The McGraw-Hill Companies, Inc. All rights reserved.

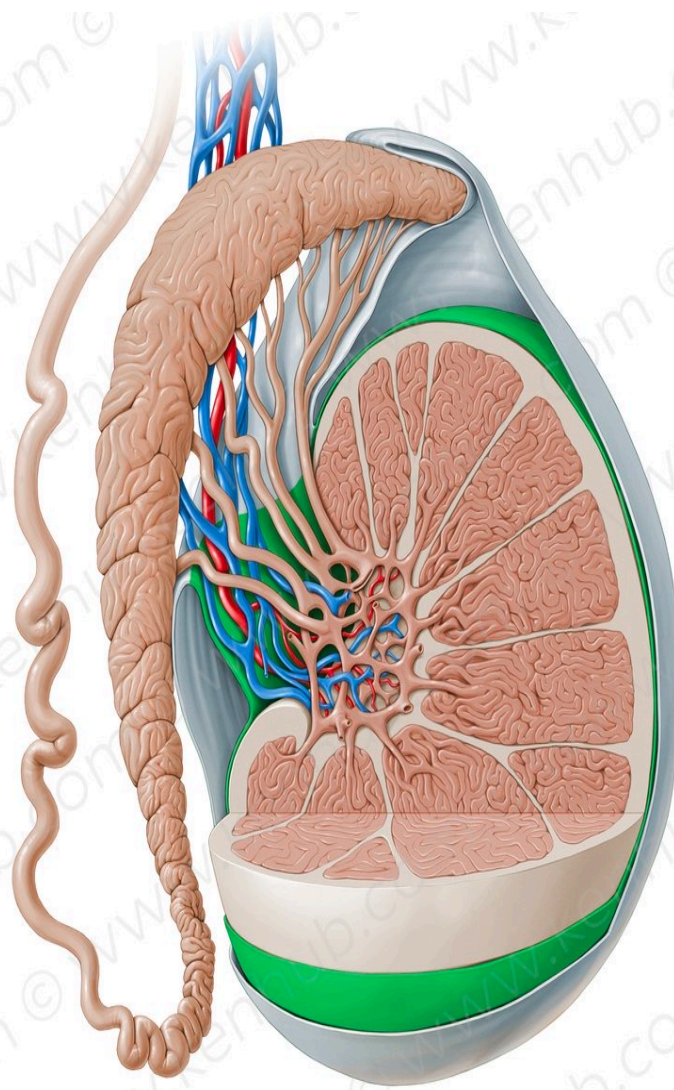
Structure of the testis

- The postero-superior part of tunica albuginea is thickened to form the ***mediastinum testis***.
- Numerous septa pass from the mediastinum to the inner surface of the rest of tunica albuginea dividing the testis into 200-300 lobules.
- Each lobule contains 2-3 seminiferous tubules with ***interstitial cells of Leydig*** in between the tubules.
- Near the mediastinum testis, the seminiferous tubules join to form 20-30 ***straight tubules***, which enter the mediastinum anastomosing with each other to form a network of tubules called "***rete testis***"
- The rete testis gives rise to 12-20 ***efferent ductules*** which emerge from the upper pole of the testis to form head of epididymis .

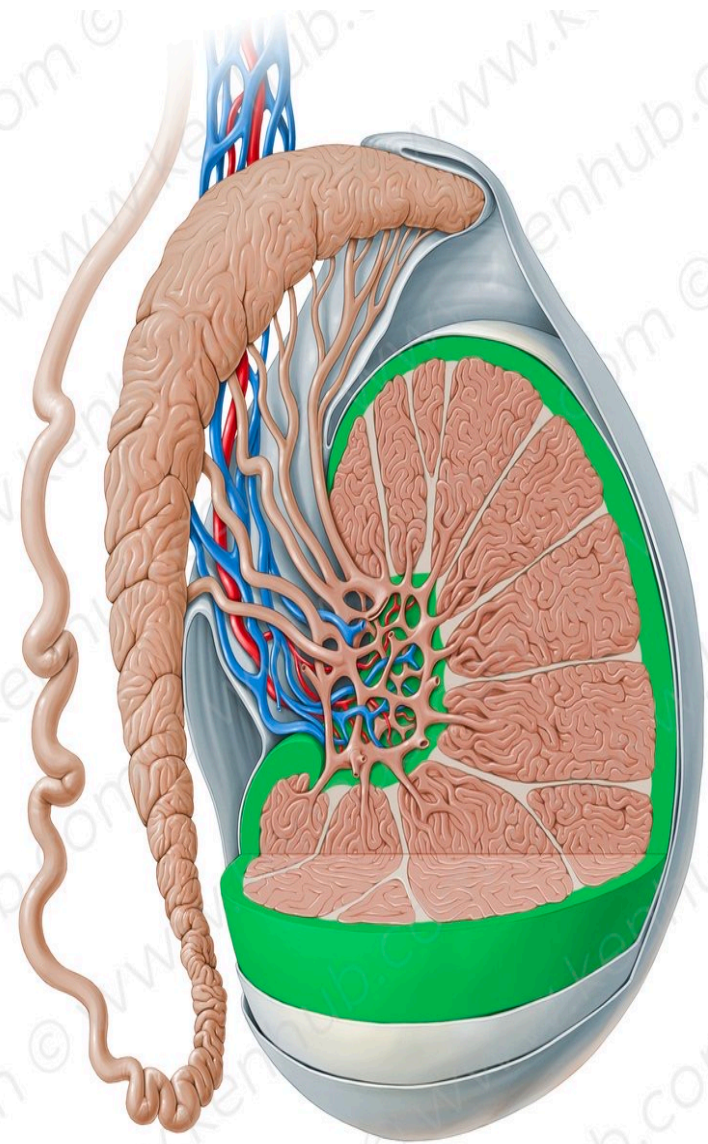




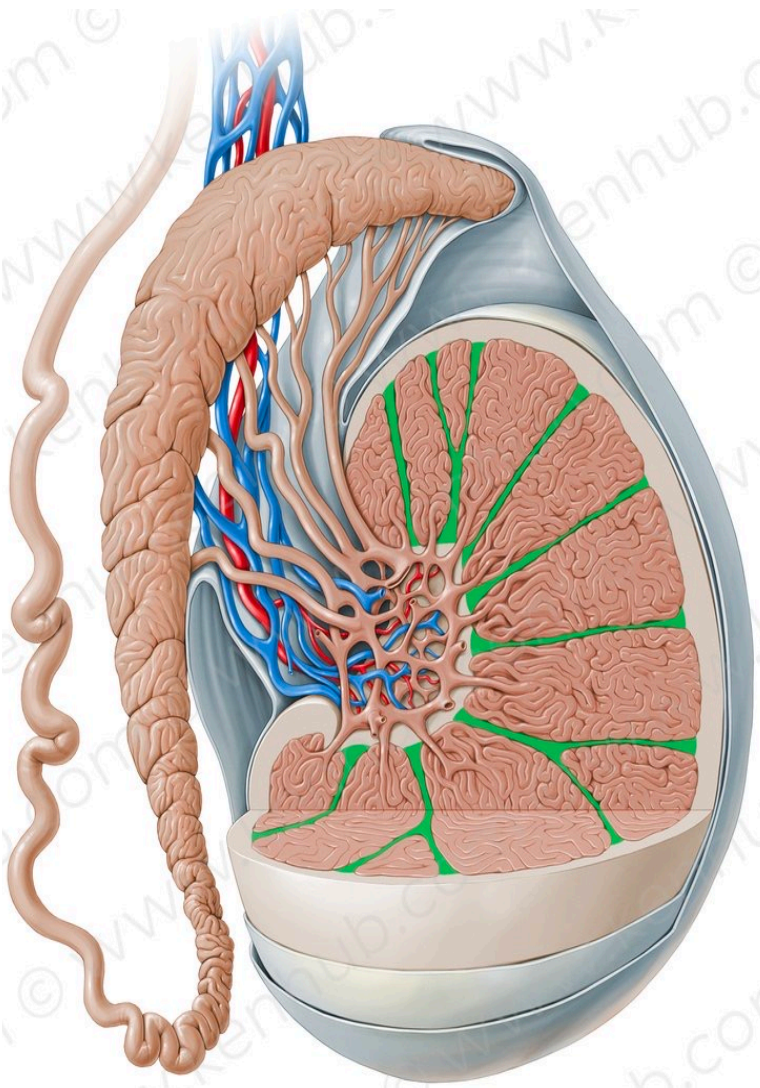
Parietal layer of tunica vaginalis



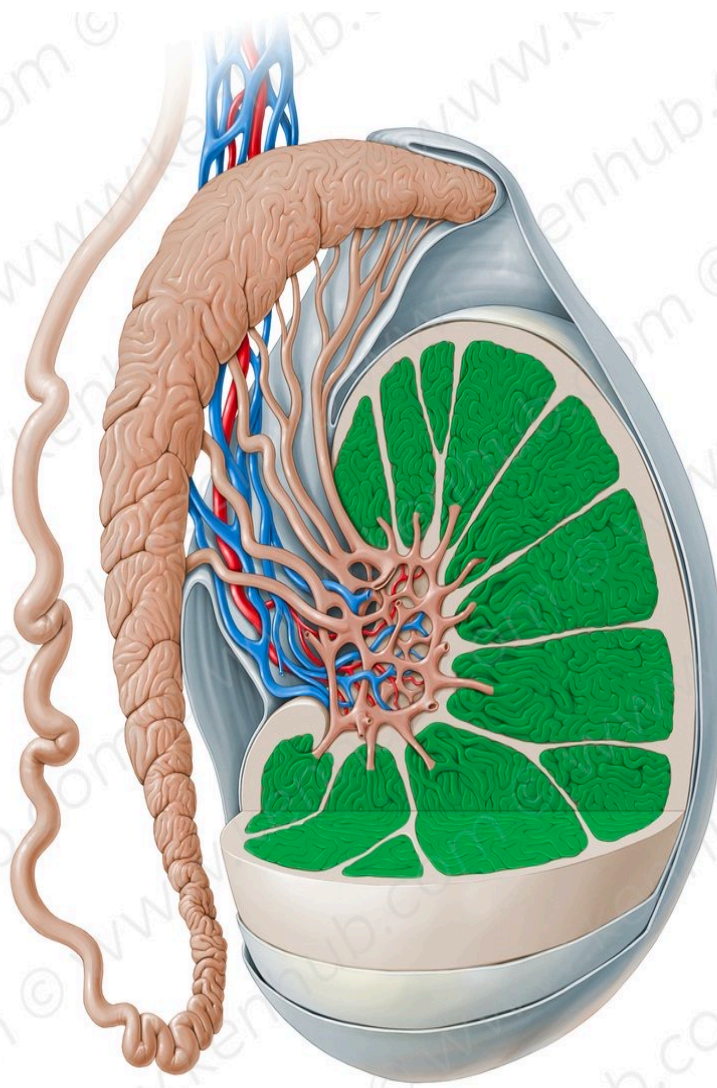
Visceral layer of tunica vaginalis



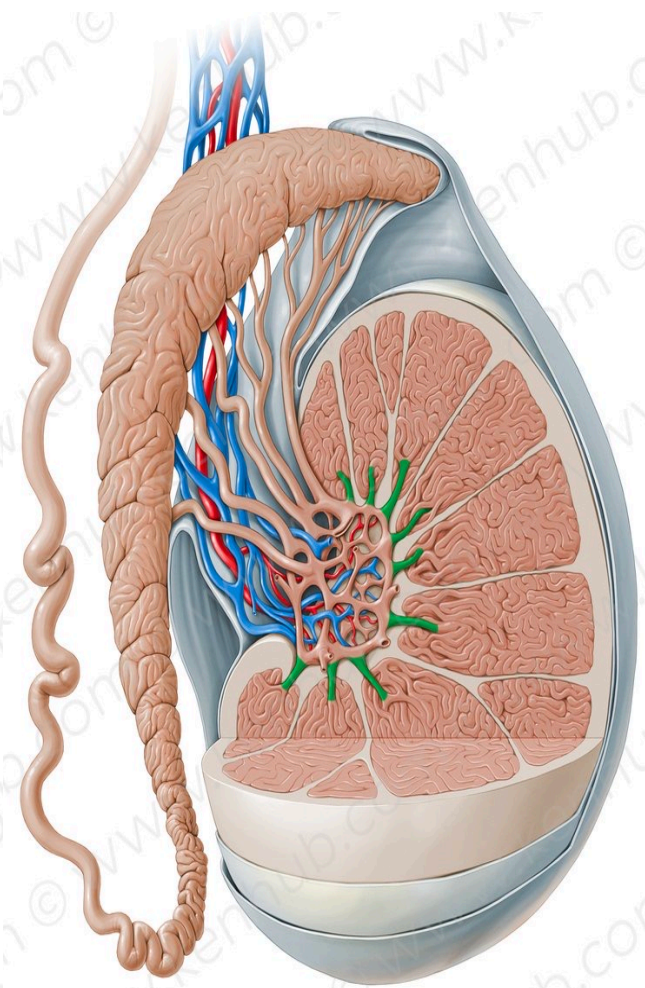
Tunica albuginea of testis



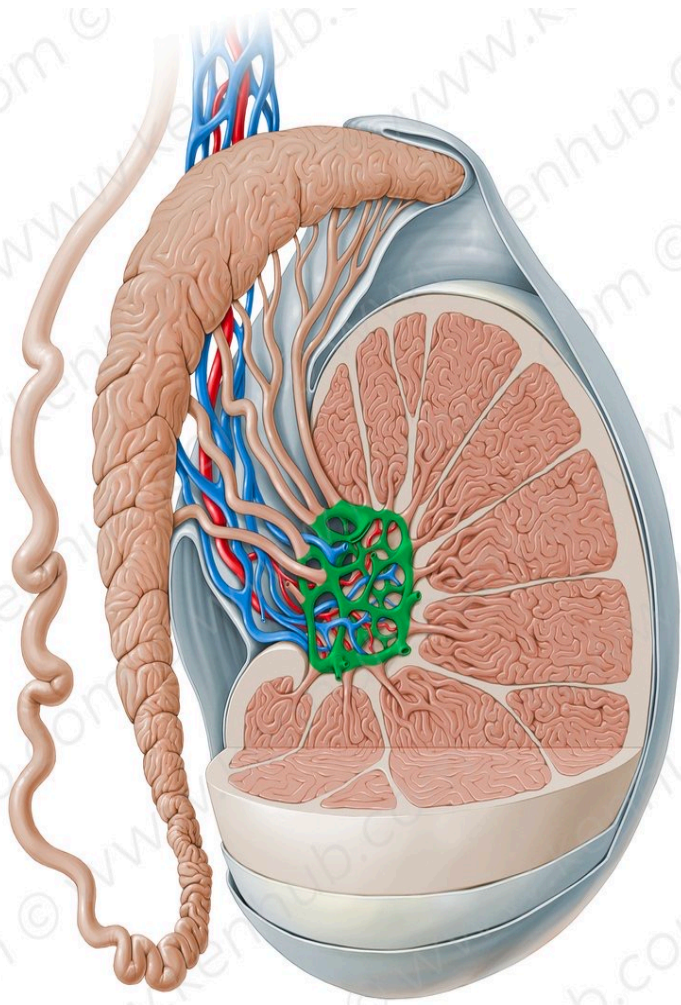
Septae



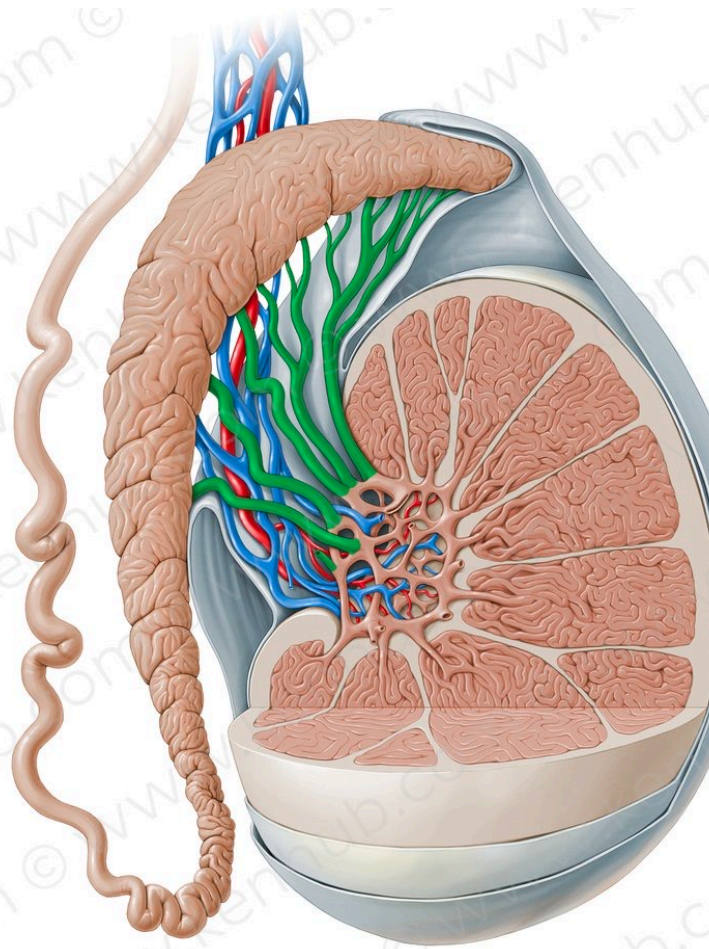
**Convoluted
seminiferous
tubules**



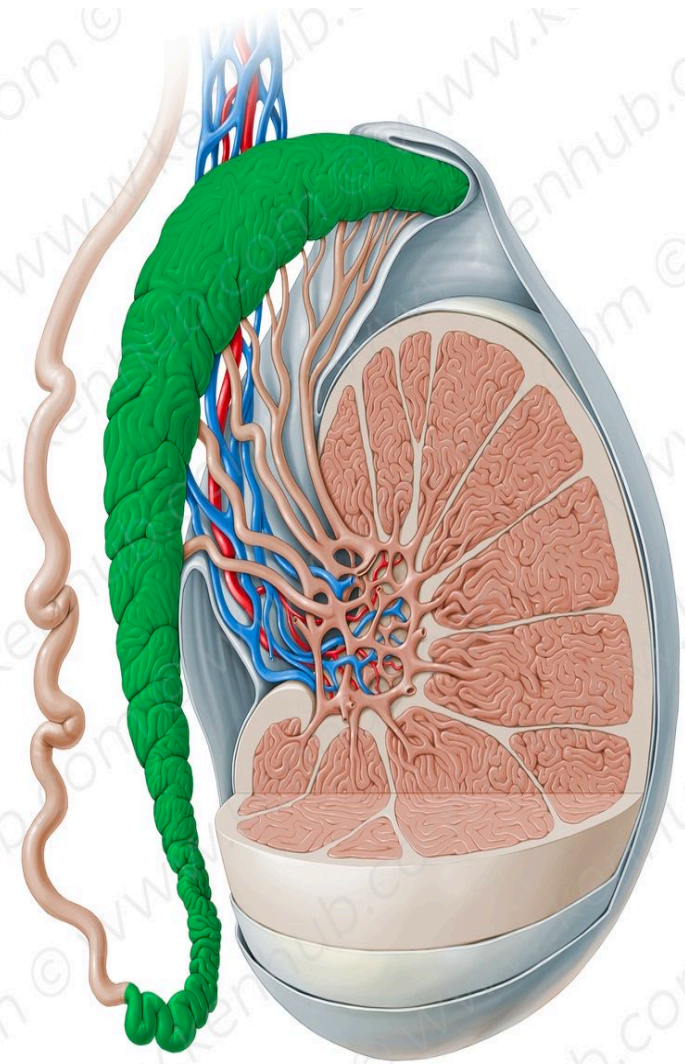
**Straight
seminiferous
tubules**



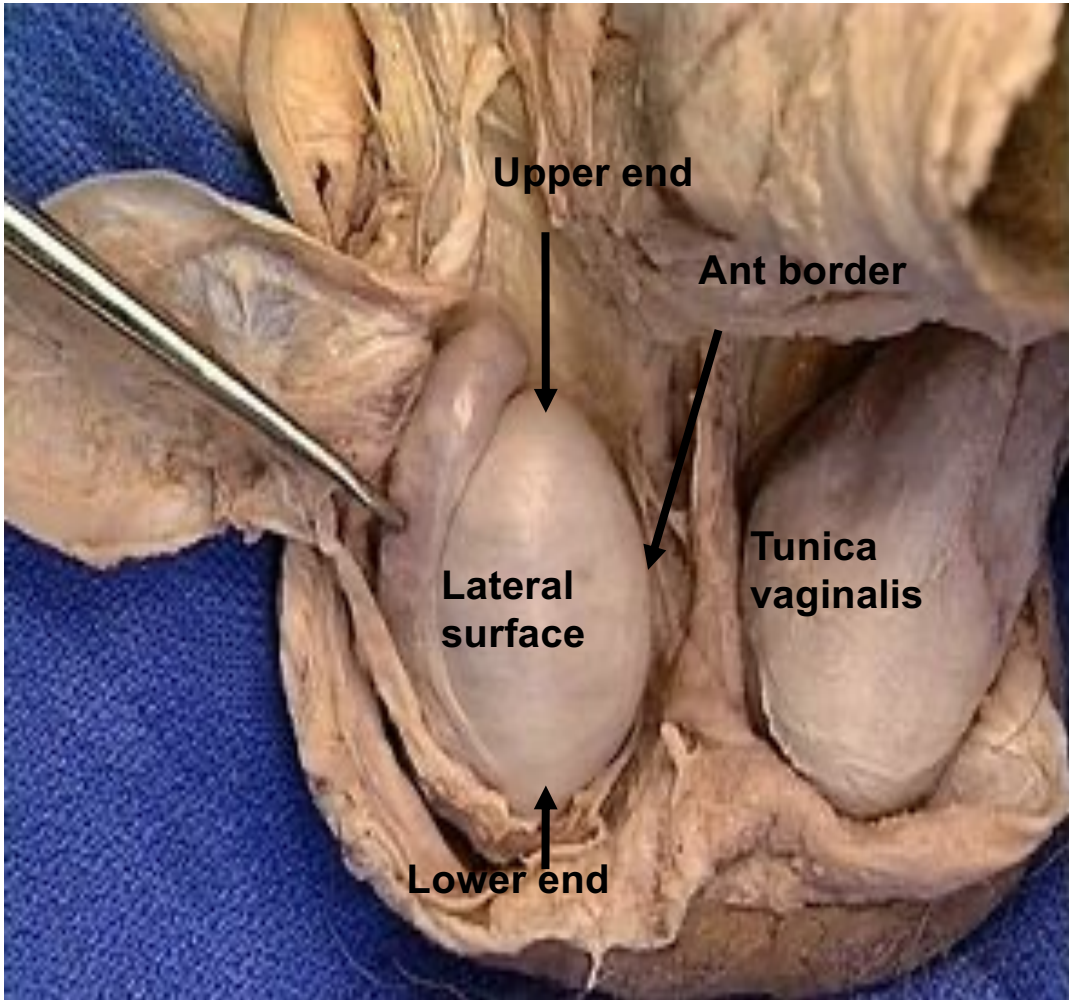
Rete testis



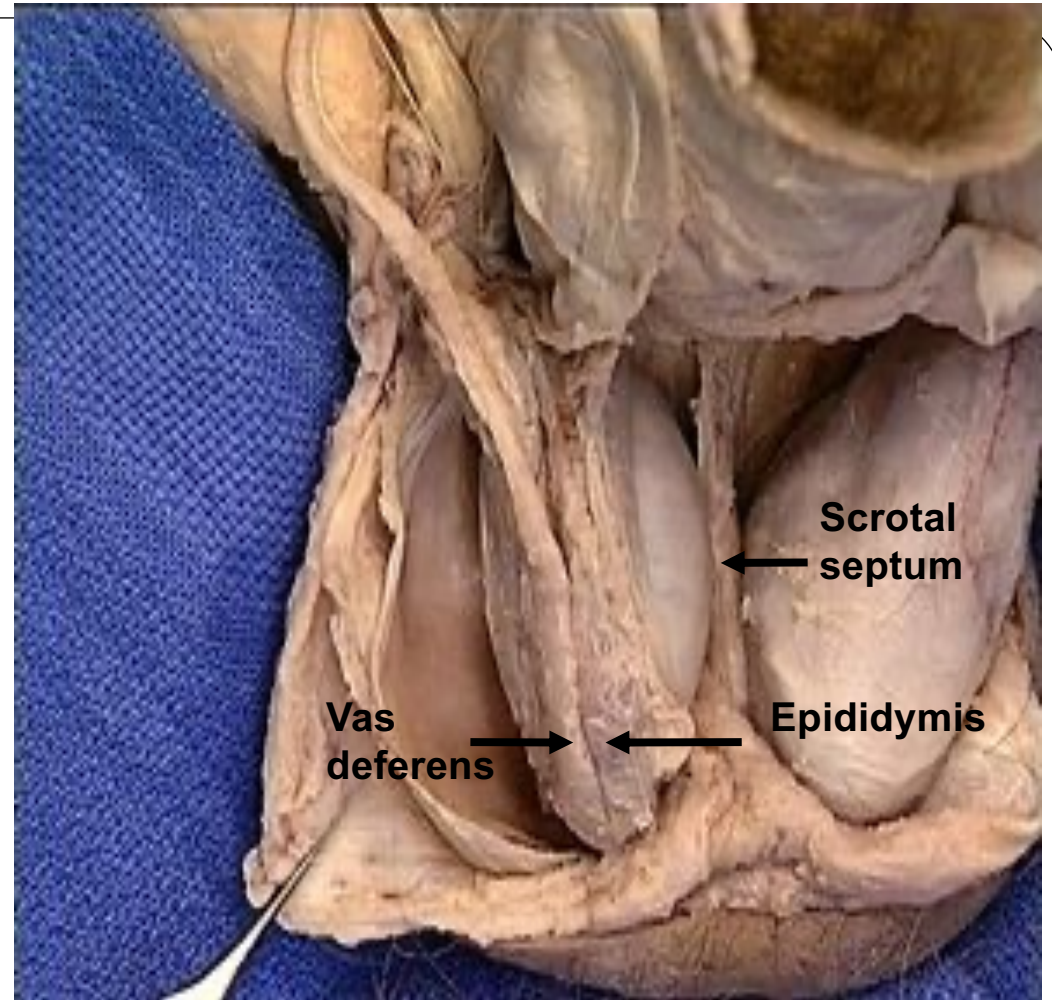
Efferent ductules



Epididymis



Lateral view of right testis



Posterior view of right testis

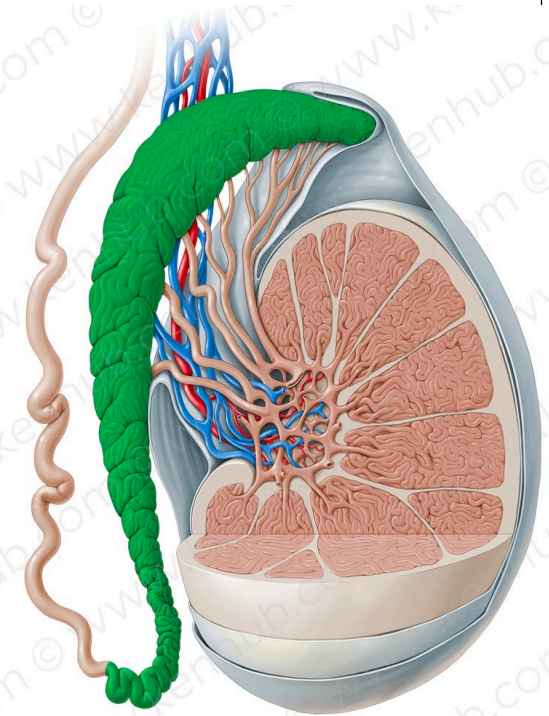
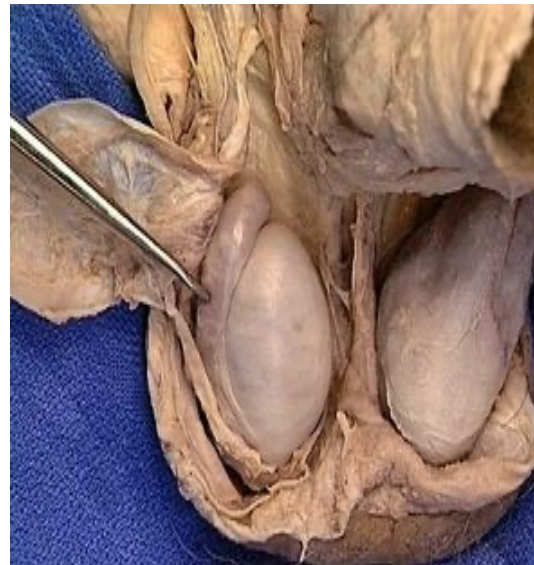The epididymis

It is the highly coiled comma shaped tube which is attached to the postero-lateral aspect of the testis. It may act as a reservoir for sperms.

Length: In the comma shaped coiled form it is about 1.5 inches long. When it is uncoiled, it measures about 6 meters in length. **(READ ONLY)**

It has 3 parts

- **Head:** forms a cap at upper pole of the testis, to which is connected by efferent ductules. These ductules form head of the epididymis
- **Body:** is the intermediate part and is made up of the single coiled tube
- **Tail:** is the lower end of the tube and it continues as vas deferens which ascends medial to the epididymis.

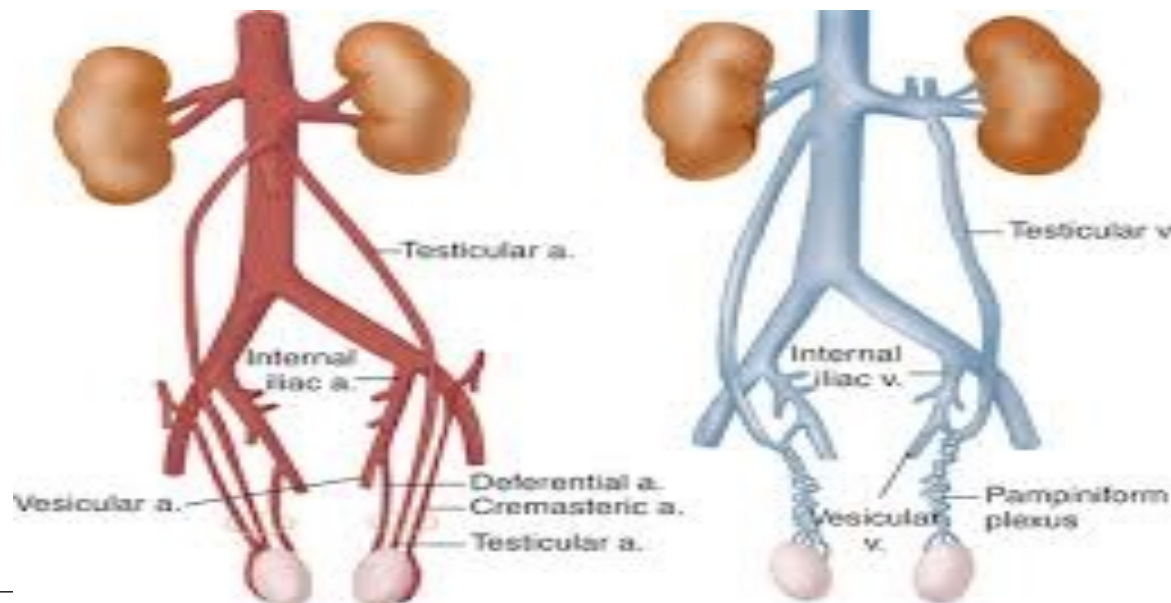


Arterial blood supply of the testis and epididymis

- ✓ By testicular artery, a branch of abdominal aorta at L2 vertebra.
- ✓ It descends on the posterior abdominal wall to reach the deep inguinal ring where it runs in the spermatic cord in the inguinal canal.
- ✓ It supplies epididymis and enters the testis
- ✓ It anastomoses with cremasteric artery and artery of the vas .

Venous drainage

- ✓ Venous blood from testis and epididymis drain into the pampiniform plexus.
- ✓ It surrounds and accompanies the testicular artery up to the superficial inguinal ring.
- ✓ In the inguinal canal, it gives rise to a single testicular vein.
- ✓ The **right** vein ends in the inferior vena cava and the **left** one ends in left renal vein.



Varicocele

➤ A varicocele is a condition in which the veins of the pampiniform plexus are elongated and dilated.

➤ It is a common disorder in adolescents and young adults

➤ It is more common occurring on **the left side because** :

1-The right testicular vein joins the low-pressure inferior vena cava (by acute angle)

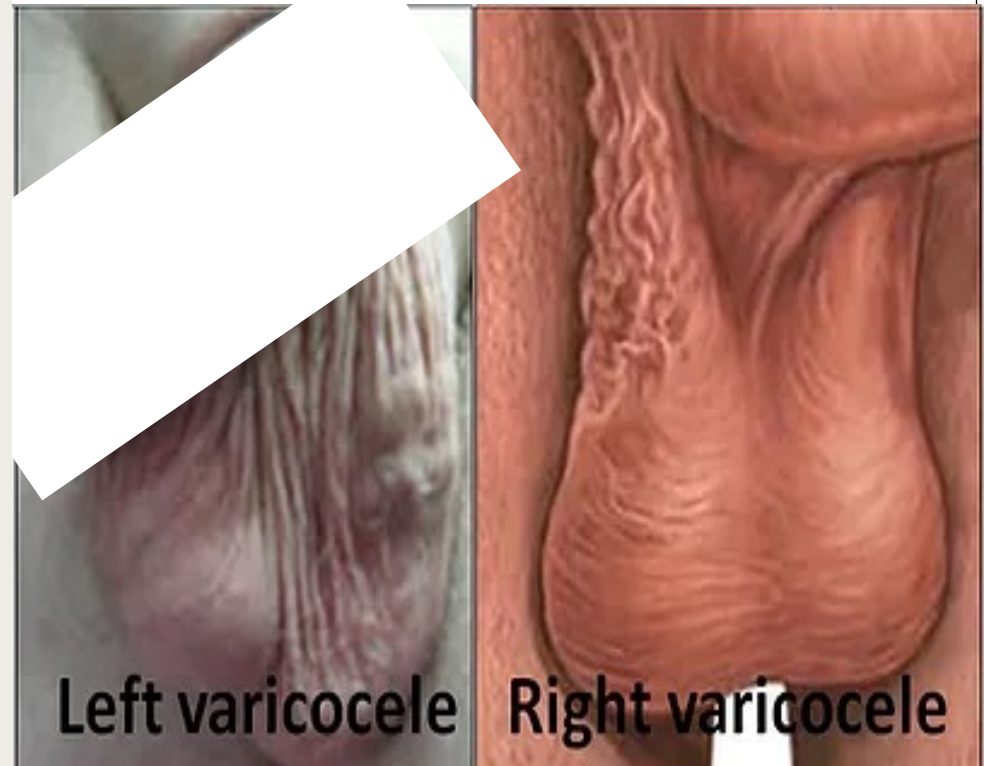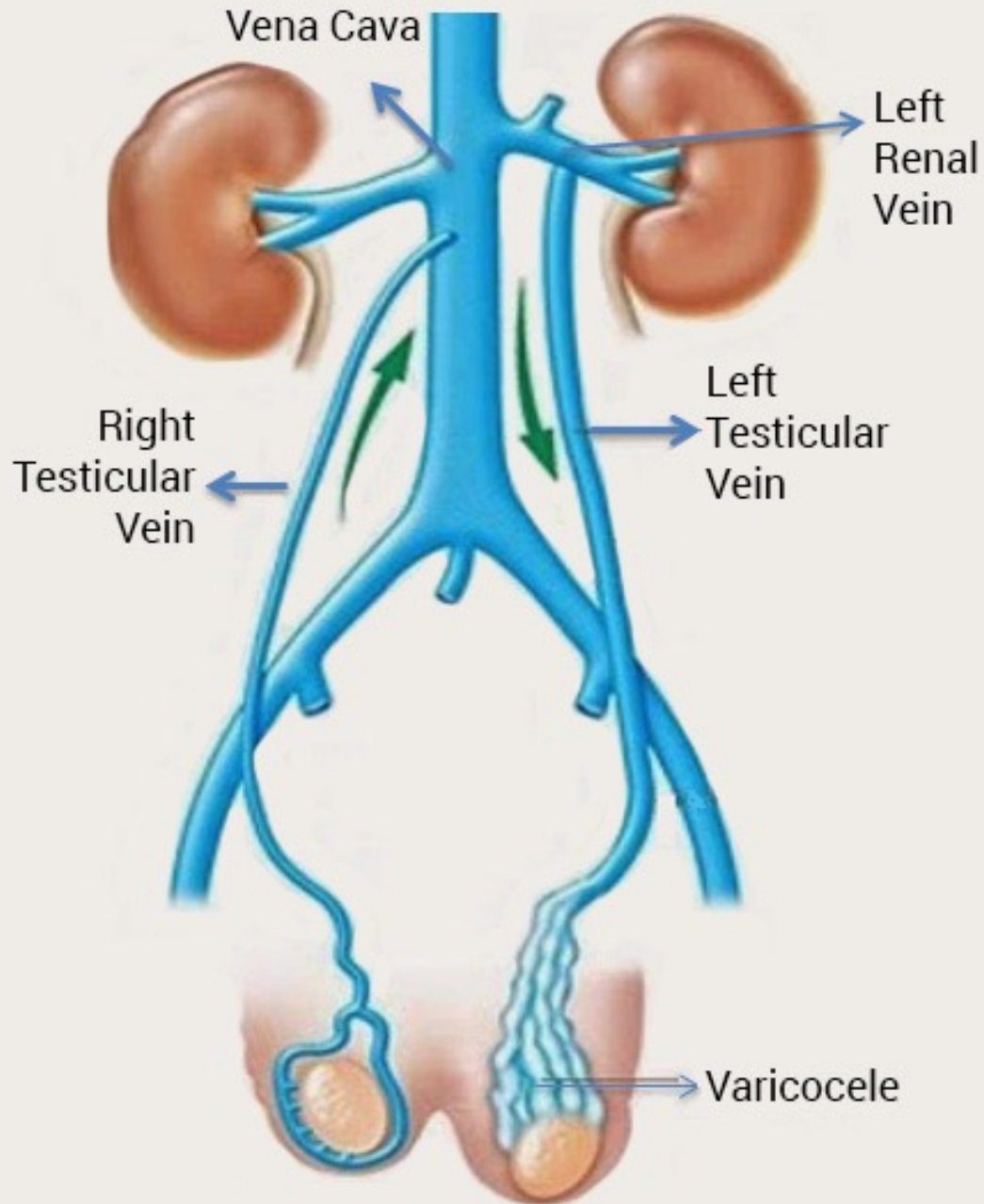
The left vein joins the left renal vein, in which the venous pressure is higher (by right angle)

2- The Left side drained by left renal vein which receive left suprarenal vein contains adrenaline and noradrenaline which causing vasoconstriction of Left testicular vein

3- The left renal vein is compressed between aorta and superior mesenteric artery

4- Left testicular vein may be compressed by heavy left colon

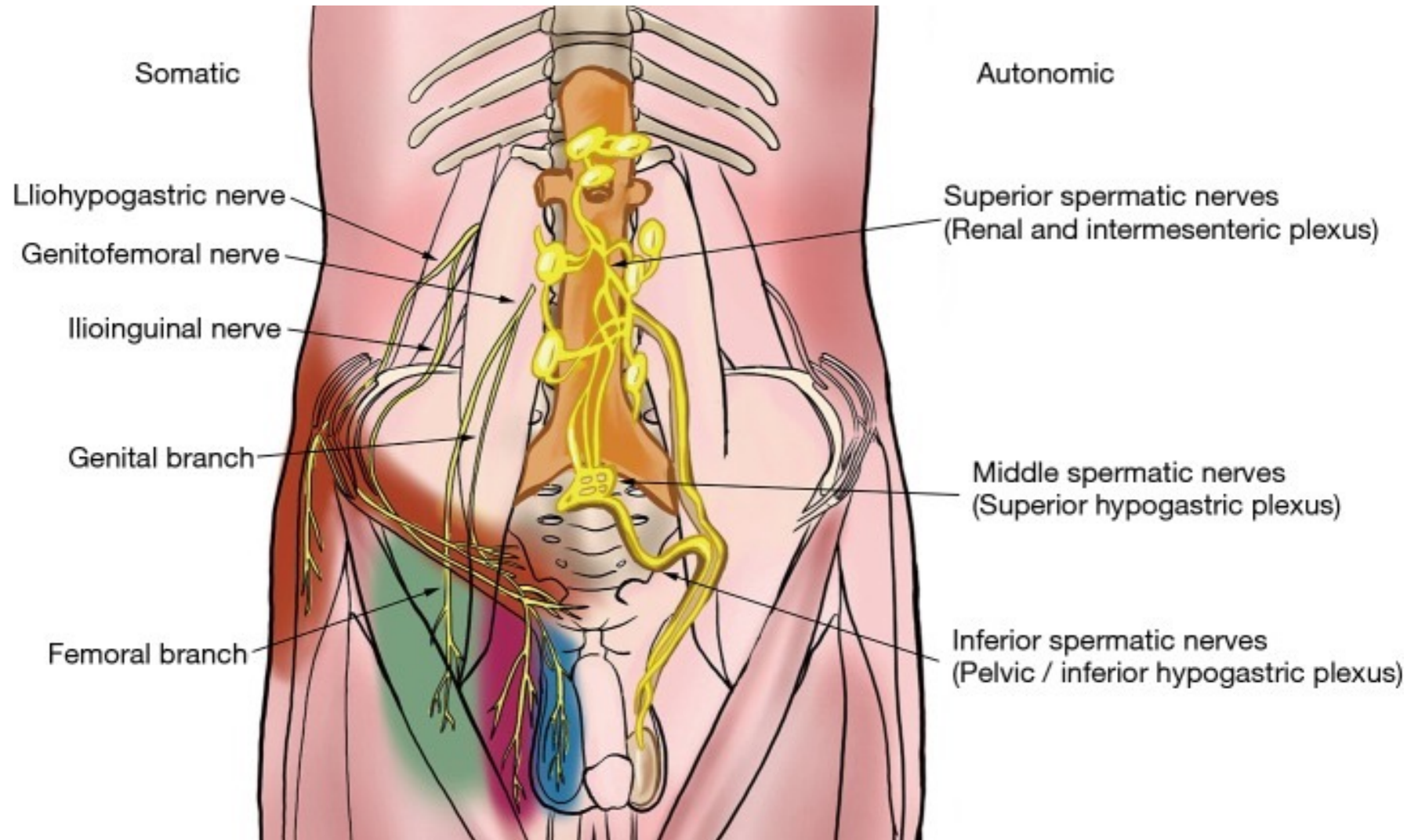
5-The left testis is lower than right one with elongated left testicular vein



Nerve supply

<https://www.ncbi.nlm.nih.gov/pmc/articles/PMC5503924/>.

Lymphatic drainage : Into lateral aortic lymph nodes.



Nerve supply of the testis

Superior spermatic nerves :

Composed of fibers from the **renal and intermesenteric plexus** follow the **testicular artery** to the testis.

This association between the intestinal (intermesenteric) and testicular nerves may explain the “**kick in the stomach**” feeling accompanying testicular injury.

Middle spermatic nerves arise from the **superior hypogastric plexus**, pass to the mid-ureter and travel alongside the vas deferens to join the **spermatic cord**.

The ureteral proximity may explain pain radiation to the scrotum of an obstructing ureteral stone.

Inferior spermatic nerves :

Originate from **inferior hypogastric plexus** , and join the middle spermatic nerves at the prostate-vesical junction.

Some afferent and efferent fibers decussate to the contralateral pelvic plexus

Somatic

Autonomic

Iliohypogastric nerve

Genitofemoral nerve

Ilioinguinal nerve

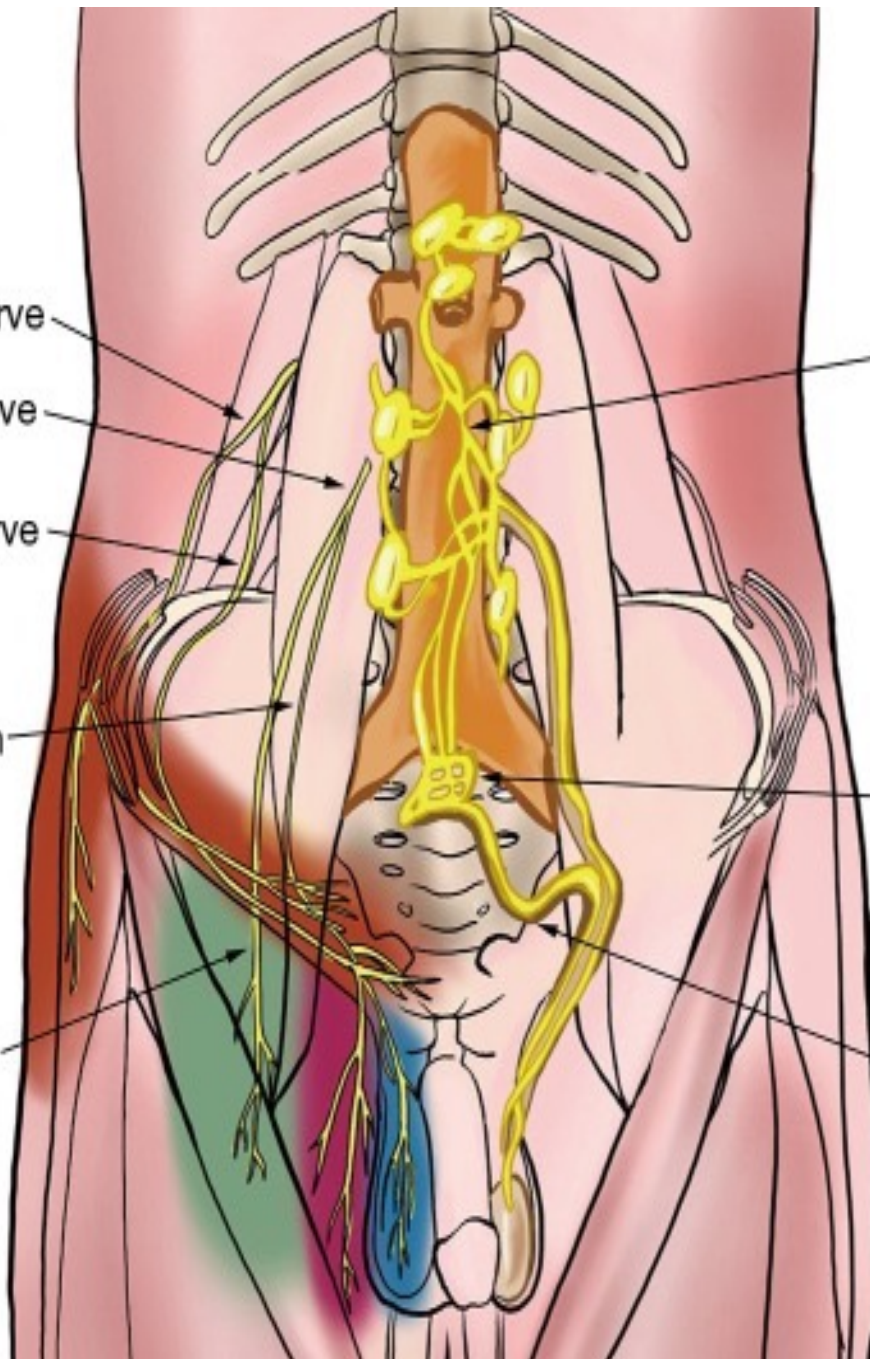
Genital branch

Femoral branch

Superior spermatic nerves
(Renal and intermesenteric plexus)

Middle spermatic nerves
(Superior hypogastric plexus)

Inferior spermatic nerves
(Pelvic / inferior hypogastric plexus)



Thermoregulation of the testis

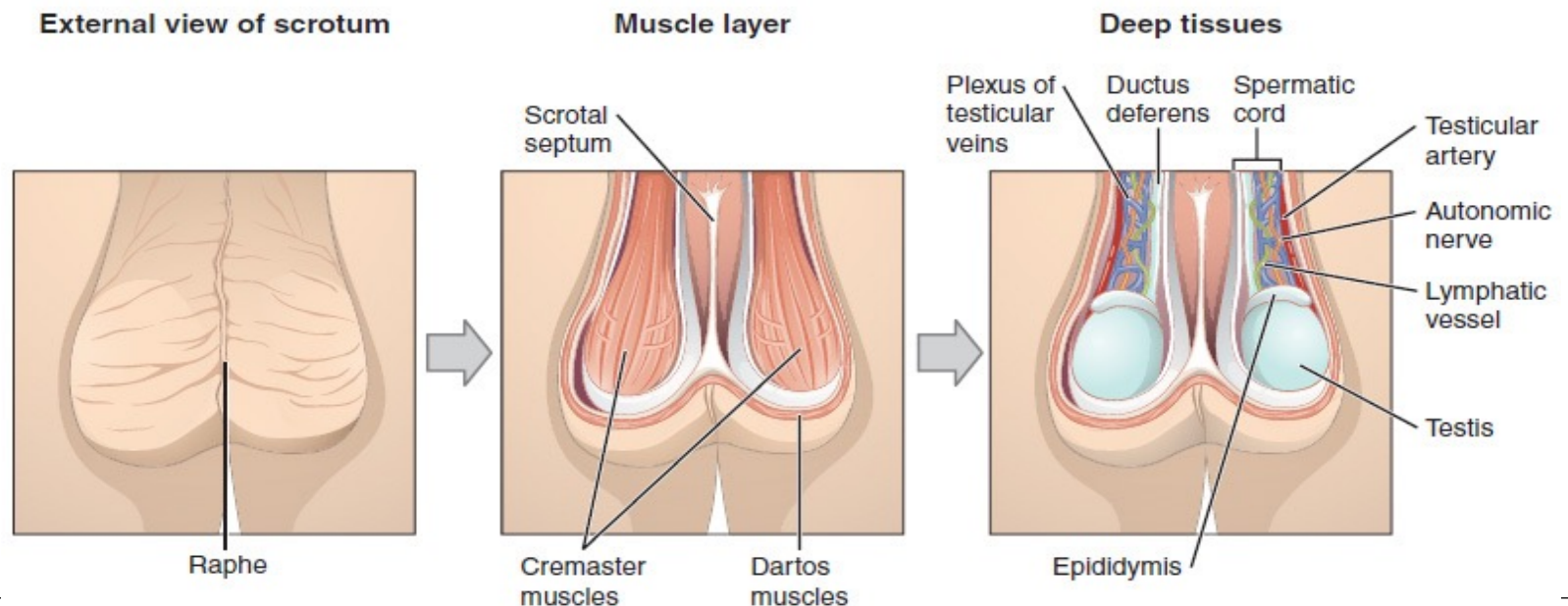
The process of spermatogenesis needs a temperature 2-3°C below the body temperature. This is achieved through the following 3 mechanisms;

1. Cutaneous mechanism; The scrotal skin is very vascular and rich in sweat glands.

- Fat is absent in its subcutaneous tissue, all aid heat loss.

2. Muscular mechanism: Includes 2 muscles, dartos and cremastic. In cold cremastic muscle elevates the testis near the body, so preventing heat loss. In warm weather, the opposite effects are obtained.

3. Vascular mechanism: The pampiniform plexus aids heat loss by radiation, so helps to maintain low temperature around the testis.



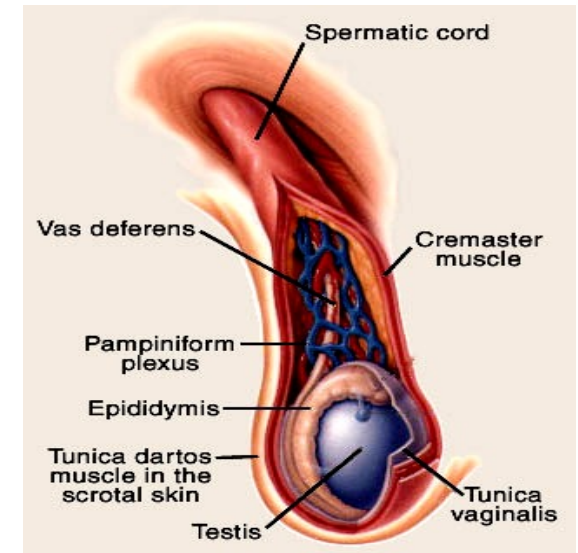
The spermatic cord

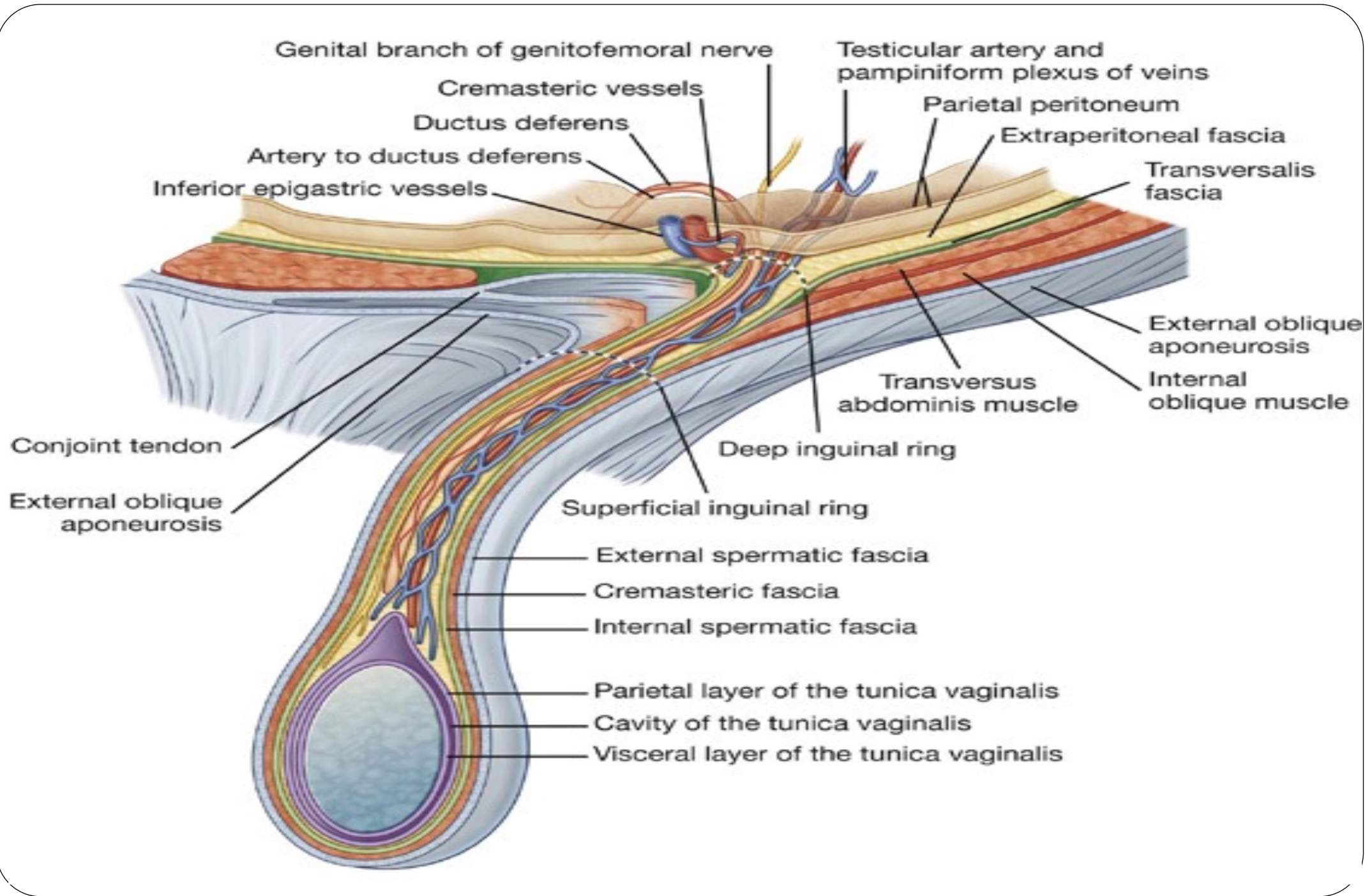
It is a group of structures which meet at deep inguinal ring and traverse the inguinal canal down to posterior border of the testis.

Coverings: The spermatic cord is invested by 3 coverings; *internal spermatic fascia, cremasteric muscle and fascia, and external spermatic fascia* .

Constituents of the spermatic cord (A, V, N, L)

1. Testicular **A**rtery (from aorta)
2. Cremasteric **A**rtery (from inferior epigastric artery)
3. **A**rtery of the vas (from the inferior vesical artery)
4. **V**as deferens
5. Pampiniform **v**enous plexus
6. **V**estige of processus vaginalis.
7. Genital branch of genitofemoral **N**erve,
8. **S**ympathetic plexus around the testicular artery and artery of the vas
9. **L**ymphatics of testis and epididymis ascending to lateral aortic lymph nodes and Loose areolar tissue.





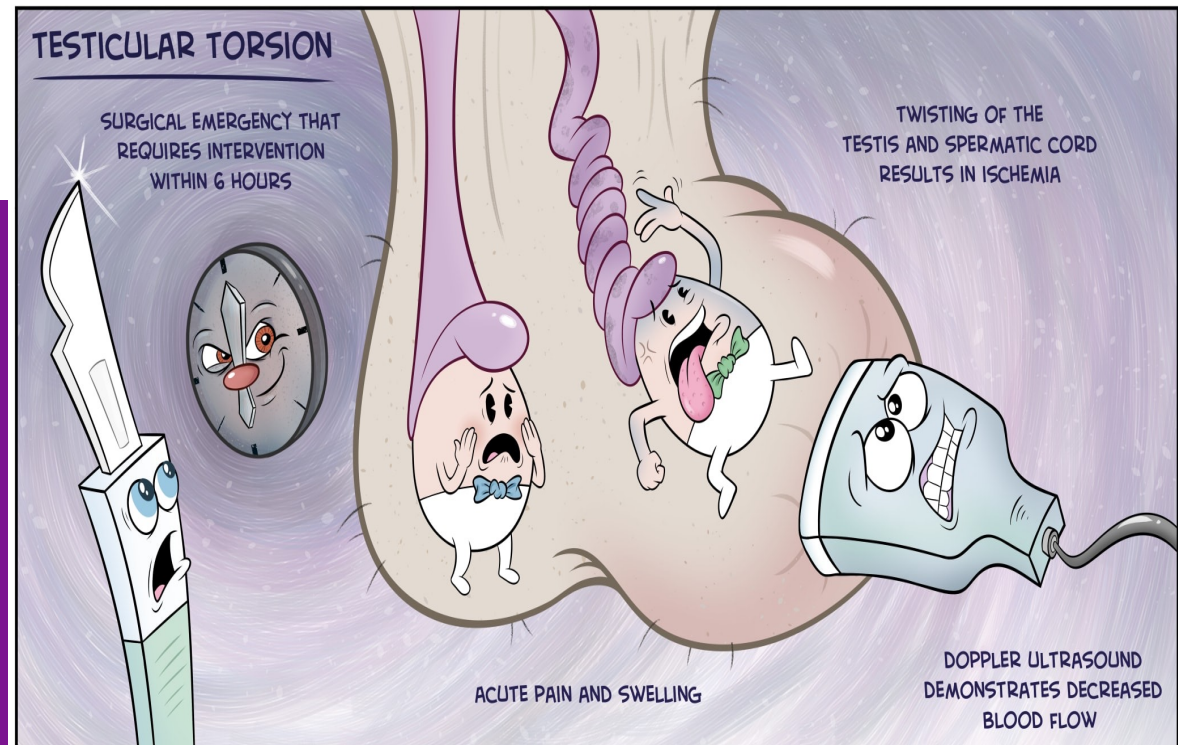
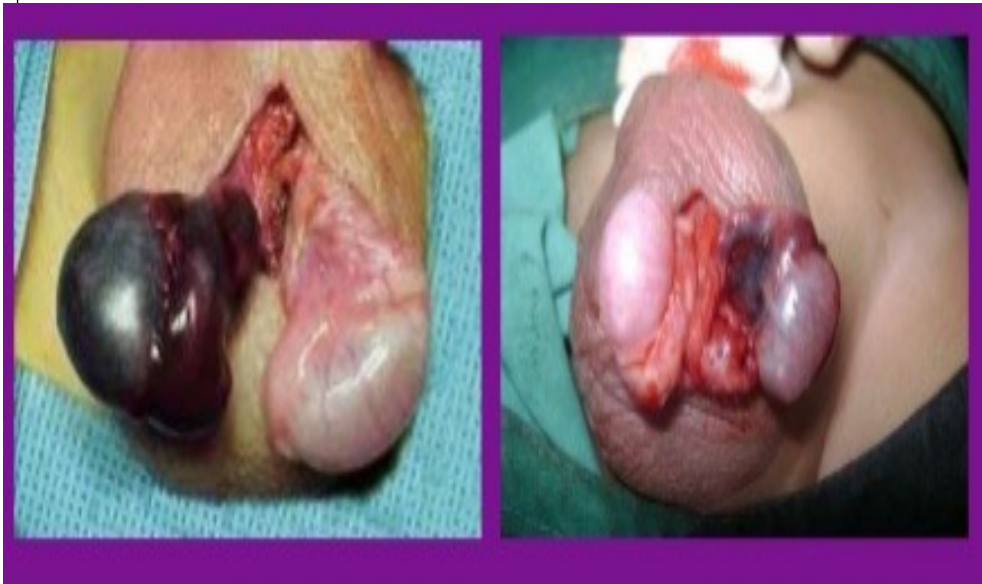Torsion of the Testis

Torsion of the testis is a rotation of the testis around the spermatic cord .

It is often associated with an excessively large tunica vaginalis.

The patient complains from severe pain.

It is an emergency case , the testicular artery may be occluded, followed by necrosis of the testis.

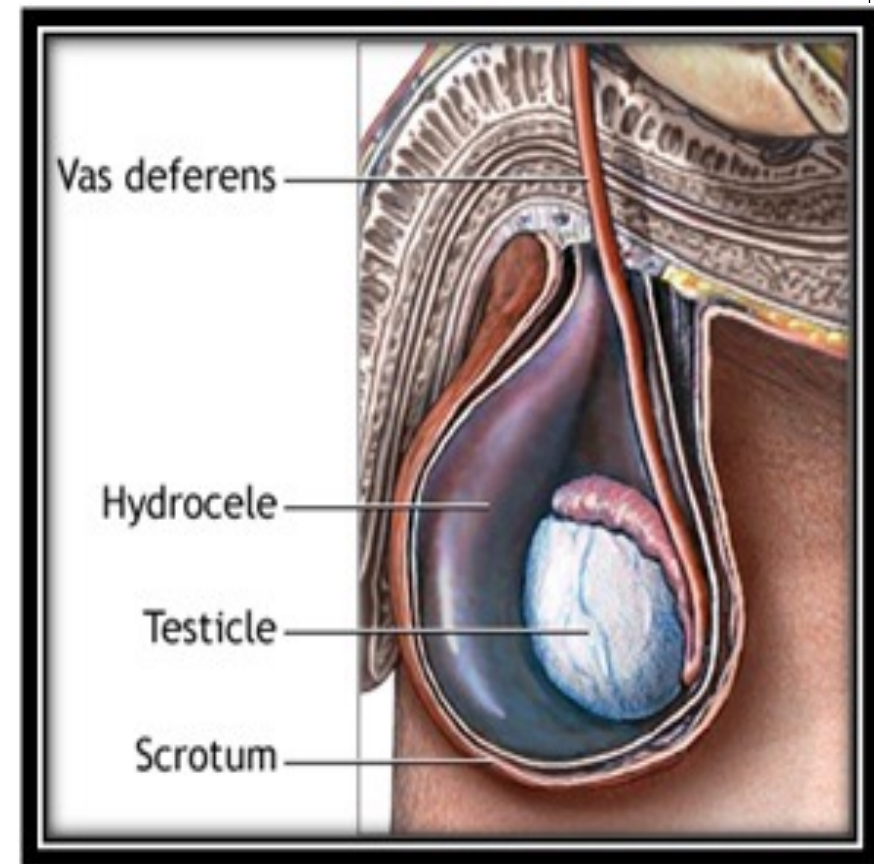
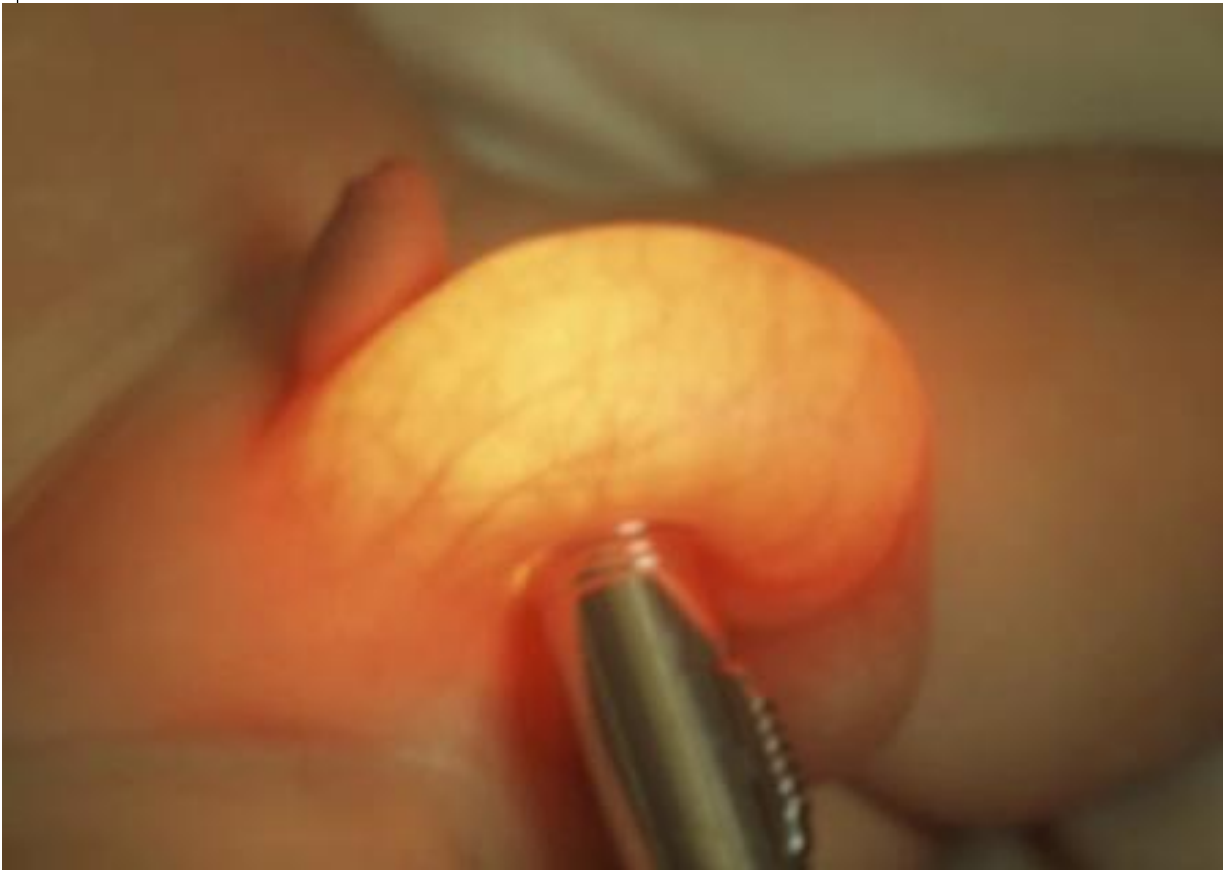


Hydrocele

It is an accumulation of fluid within the tunica vaginalis.

Haematocele

It is an accumulation of blood within the tunica vaginalis.



Thank You!



**The University Of Jordan
Faculty Of Medicine**



Male genital system Part II

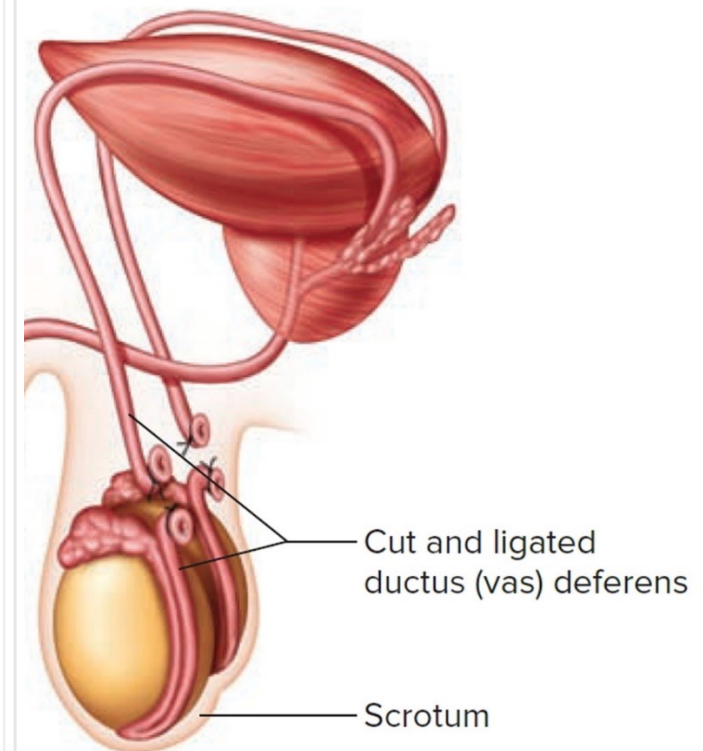
By

Dr.Ahmed Salman

Associate Professor of Anatomy

Ductus Deferens (Vas Deferens)

- It is thick walled muscular tube which springs from the lower end of the epididymis
- It ends behind the base of the bladder, by joining the duct of the seminal vesicle to form the ejaculatory duct



Function : transmit the spermatozoa from the epididymis to the ejaculatory duct, which in turn opens in the prostatic urethra.

READ ONLY

Length : about 45 cm, the same length of the following :

a. Thoracic duct

b. Spinal cord

c. Adult femur

d. The distance from the incisor teeth to the cardiac end of the stomach.

Course and Relations of the Vas :

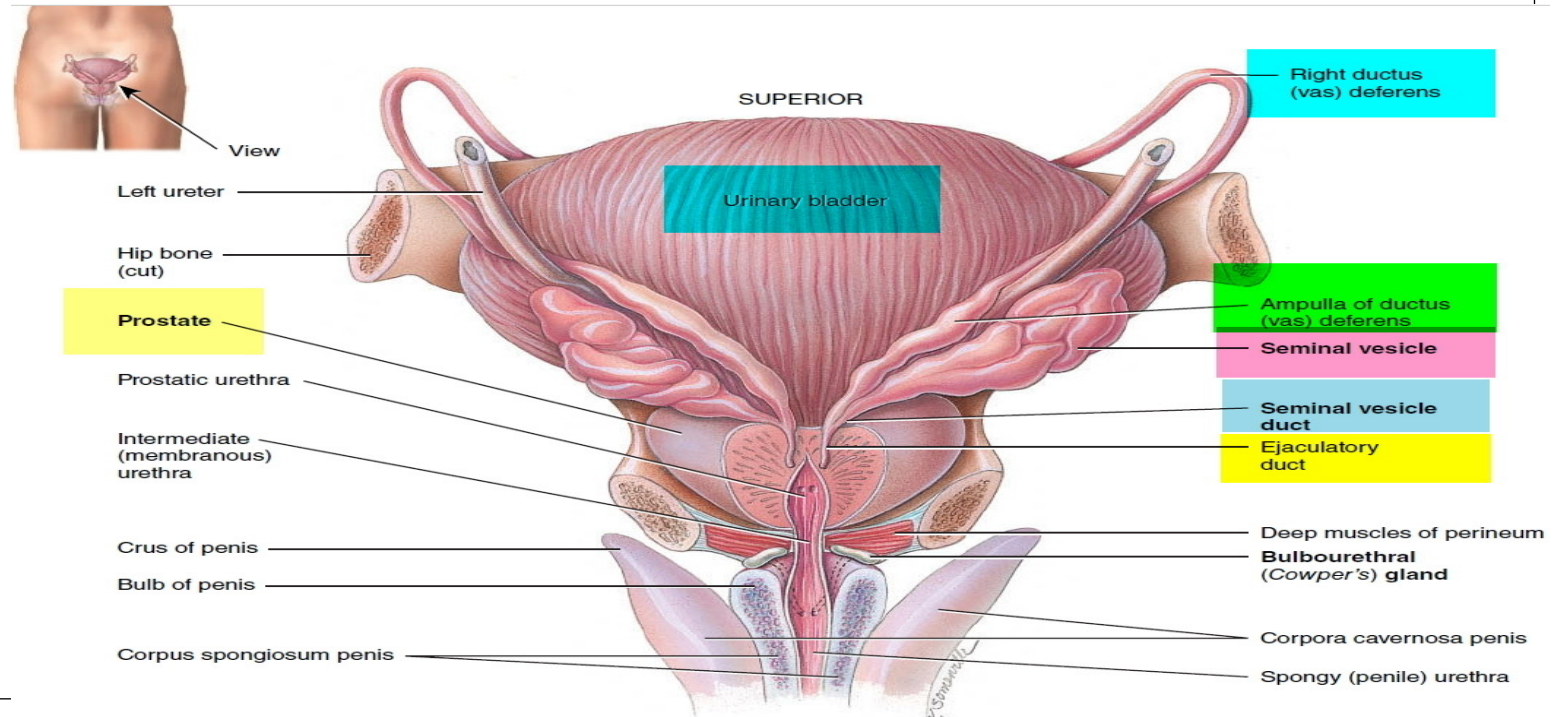
Its distal part lies in the scrotum and inguinal canal, its proximal part runs in the pelvis.

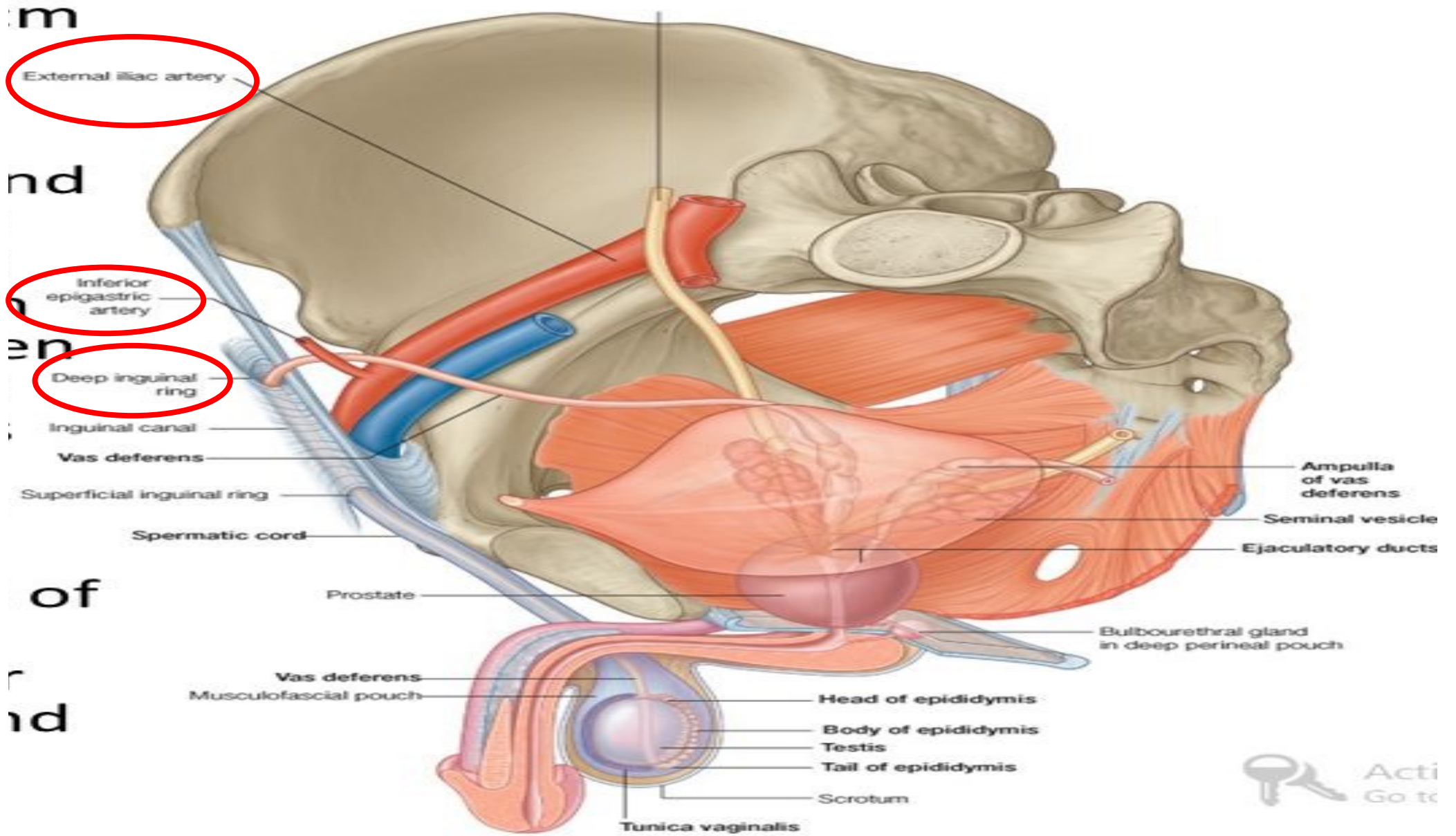
A. Of its distal part in the scrotum and inguinal canal:

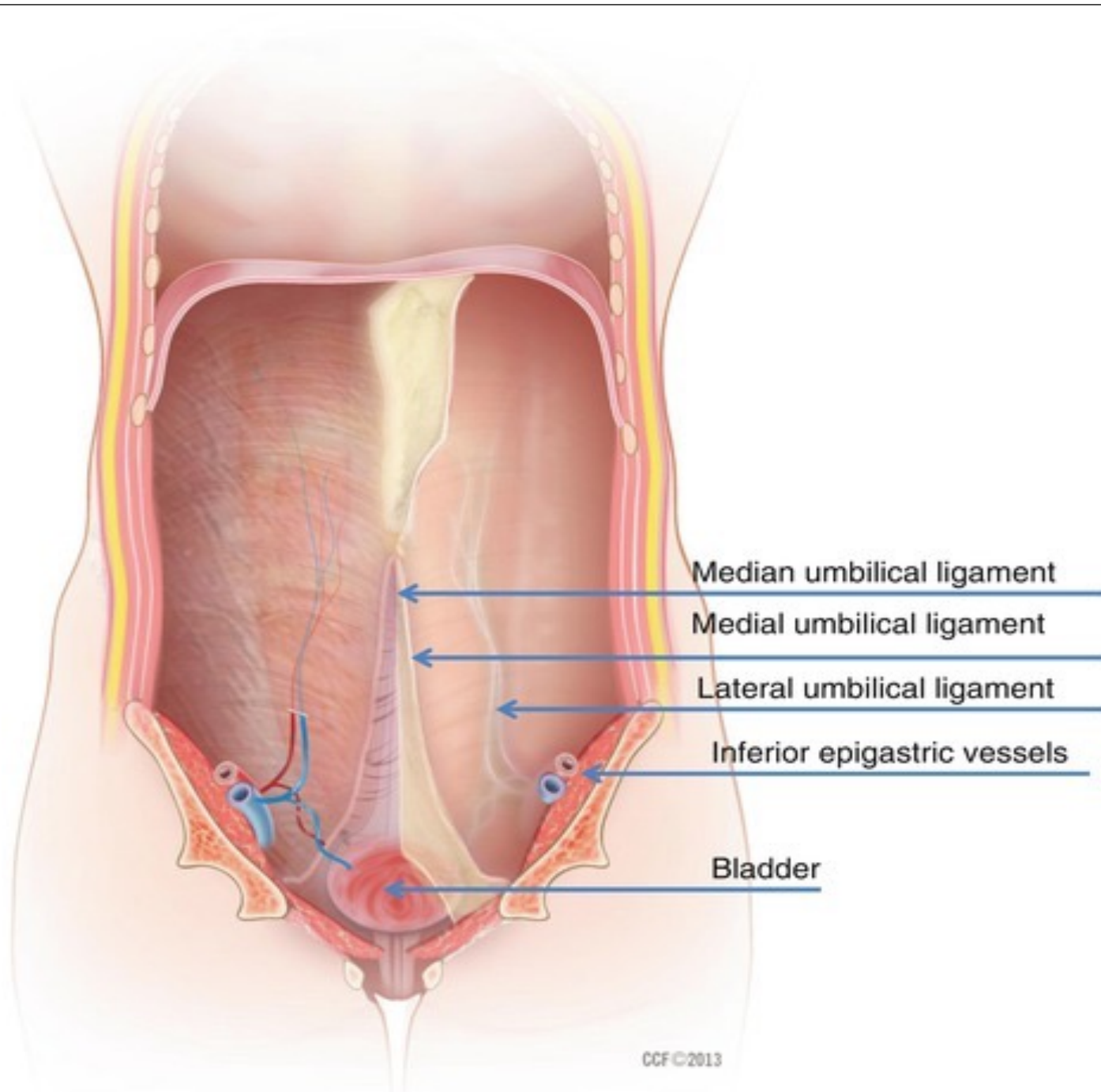
- ❖ From the tail of the epididymis, it ascends along the posterior aspect of the testis, medial to the epididymis.
- ❖ Then, it ascends in the posterior part of the spermatic cord to traverse the inguinal canal.
- ❖ At the deep inguinal ring, it leaves the cord and curves around the lateral side of the **inferior epigastric artery** to enter the pelvis.

B. Of its proximal part (in the pelvis) :

- ❖ The vas descends posteriorly external to the peritoneum, crossing these structures in the side wall of the pelvis :- external iliac vessels, obliterated umbilical artery, obturator nerve and obturator vessels.
- ❖ Then, it turns medially and crosses the **ureter** near the superolateral angle of the base of the bladder .
- ❖ Behind the bladder base, it runs superior to, then medial to the seminal vesicle and expands to form ampulla of the vas, below which it narrows to join the duct of the seminal vesicle to form the ejaculatory duct .







Median umbilical ligament

Medial umbilical ligament

Lateral umbilical ligament

Inferior epigastric vessels

Bladder

Vessels of the Vas:

- ❖ Artery of the vas is derived from inferior vesical artery.
- ❖ It runs in the spermatic cord and anastomoses with the testicular artery.

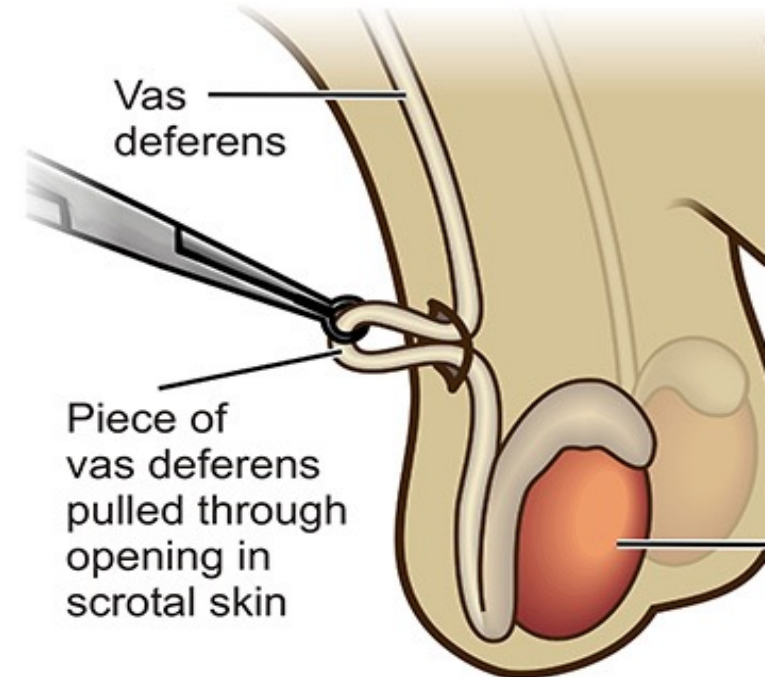
Veins : join the vesical venous plexus.

Nerves : are derived from prostatic nerve plexus which comes from the inferior hypogastric plexus.

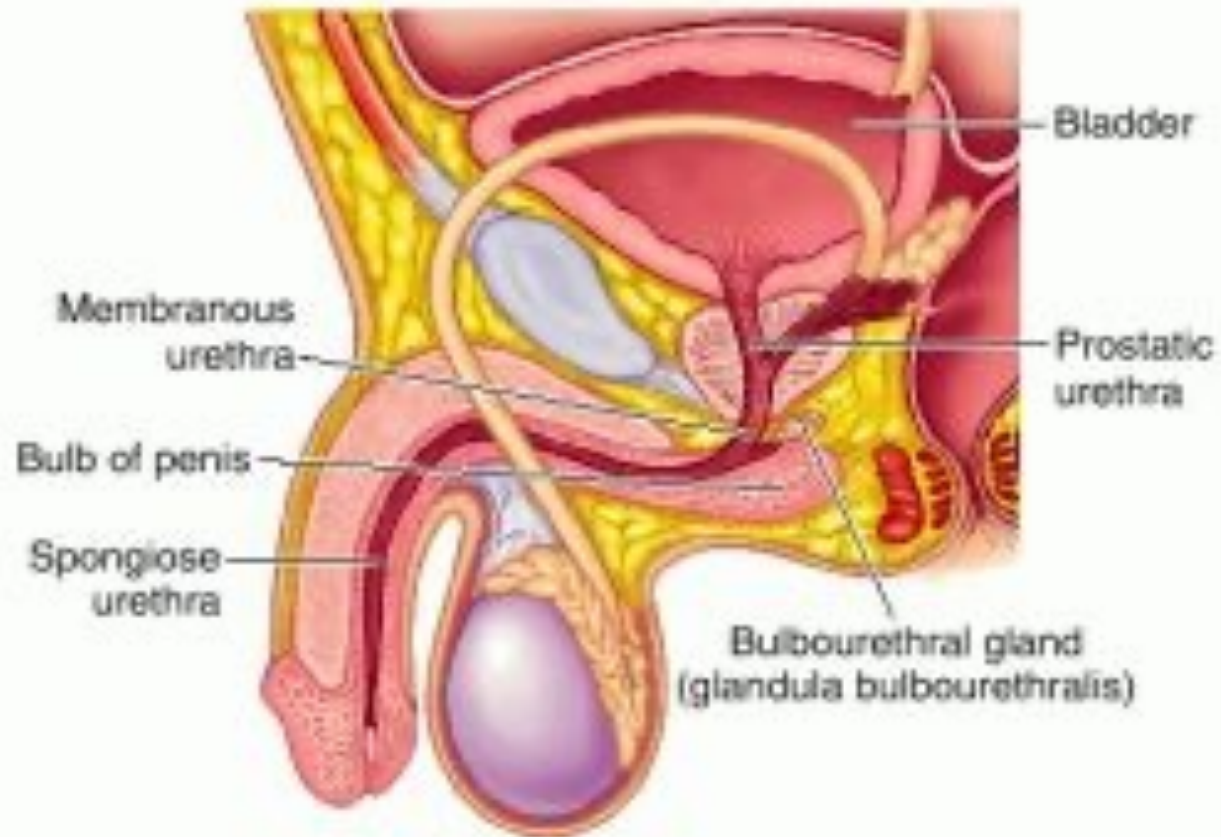
Fibers are mainly sympathetic for the process of ejaculation.



Applied Anatomy: bilateral vasectomy is a common operation for male sterilization



Seminal vesicles, Ejaculatory ducts and Bulbourethral glands



Seminal Vesicles

It is a sacculated tube, about 5 cm long.

Site and relations : it lies behind base of the bladder and has the following relations;

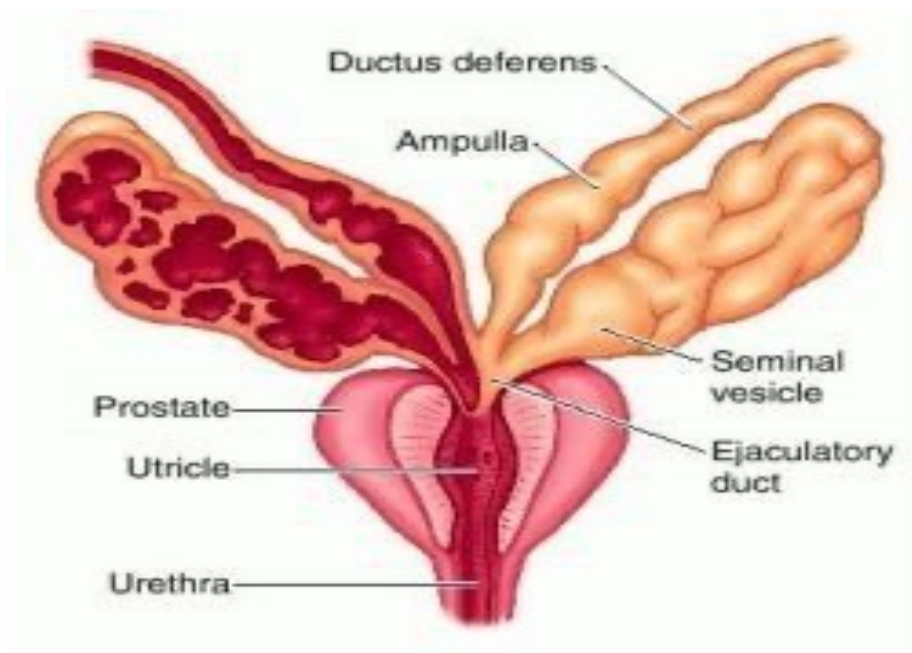
Anteriorly : Base of the bladder.

Posteriorly : Rectum and rectovesical fascia.

Superiorly : Its upper end is covered by peritoneum of rectovesical pouch and related to the vas deferens.

Medially : ampulla of the vas.

Termination : inferiorly, it narrows into a small duct which joins the vas to form ejaculatory duct.



Arterial supply : from inferior vesical and middle rectal arteries.

Veins : to vesical venous plexus.

Nerves: from prostatic nerve plexus (mainly sympathetic).

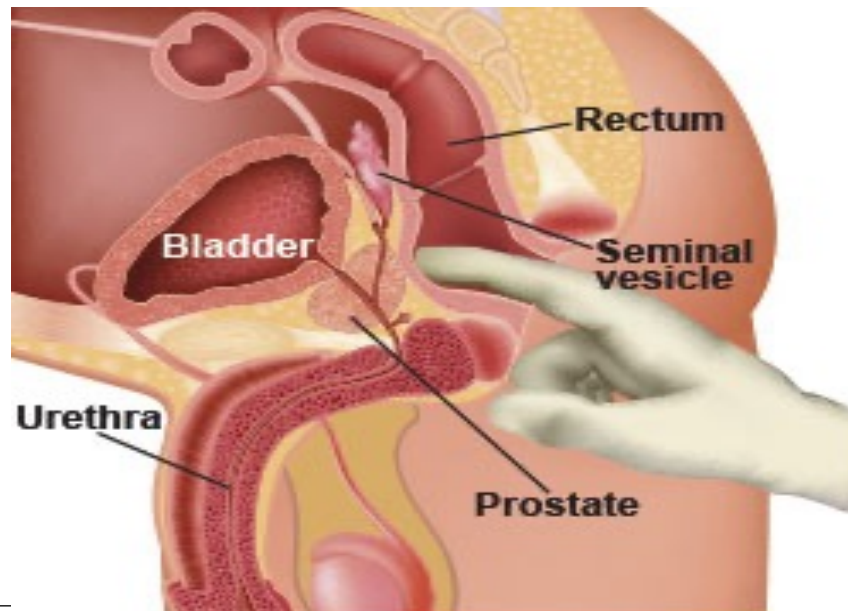
Functions :

- ❑ the seminal vesicle produces an alkaline secretion rich in fructose and mucus.
- ❑ The secretion is added to the spermatozoa in ejaculation.



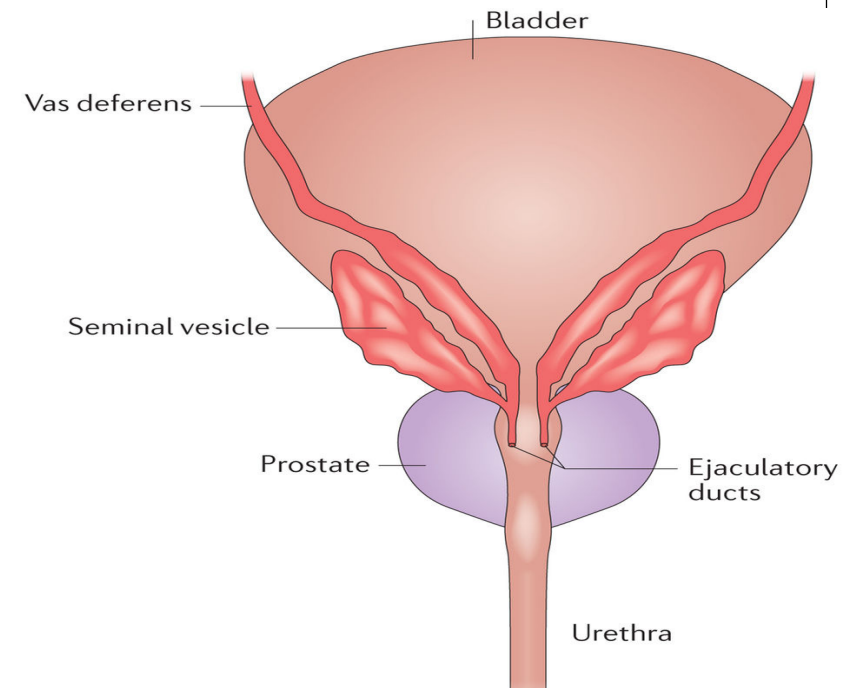
Applied Anatomy :

- ✓ The seminal vesicles when enlarged, could be felt on rectal examination.
- ✓ Abscess in the seminal vesicle may rupture into the peritoneal cavity.



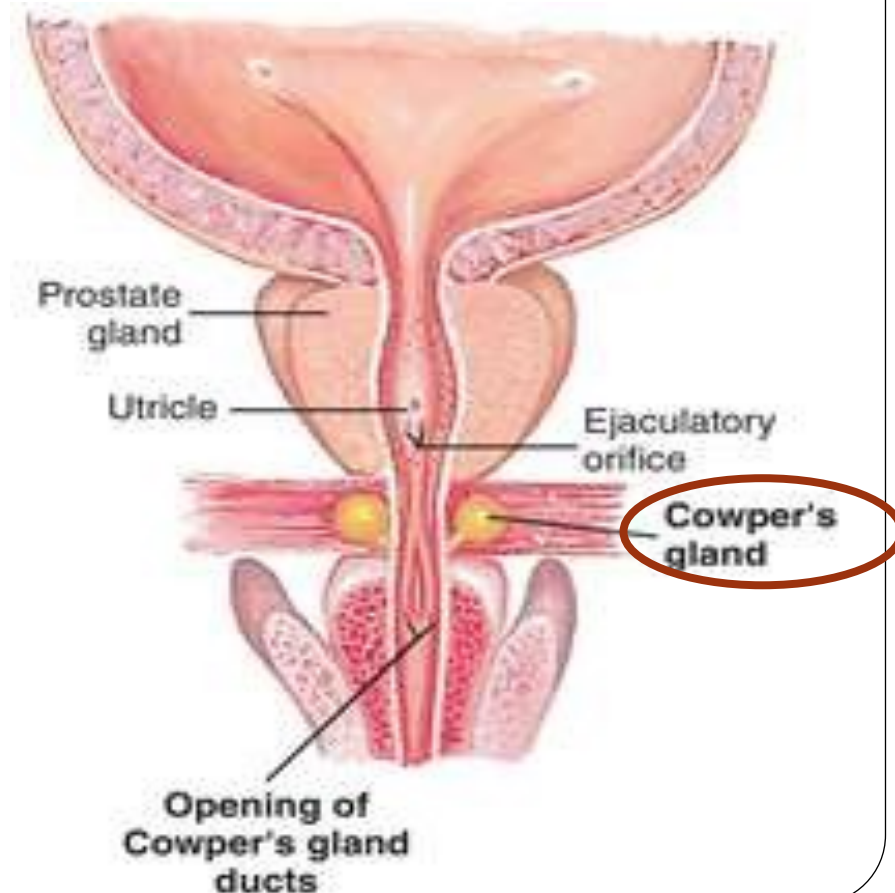
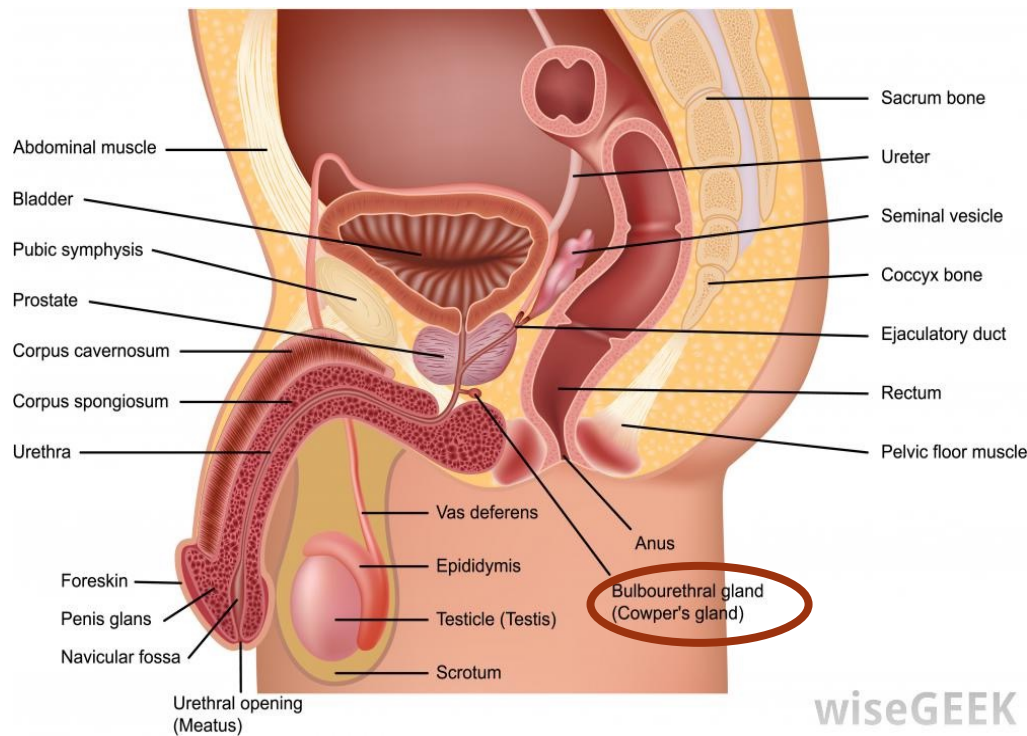
Ejaculatory Ducts :

- Each is about 2 cm long, formed by union of the ductus deferens and the duct of the seminal vesicle.
- The two ducts run antero-inferiorly between median and posterior lobes of the prostate along the sides of the prostatic utricle to open on the seminal colliculus of the prostatic urethra.



Bulbourethral Glands :

- These small glands lie lateral to the membranous urethra in the **deep perineal pouch**
- Each gives rise to a long duct (3 cm) which pierces the perineal membrane to open on the floor of the spongy part of the urethra.
- **Blood supply:** by artery of the bulb of the penis.
It is innervated by prostatic nerve plexus
- **Function :** It secretes an alkaline mucous secretion known as pre-ejaculate.



A 65 years old Male patient, complains from frequent micturition and weak urine stream.

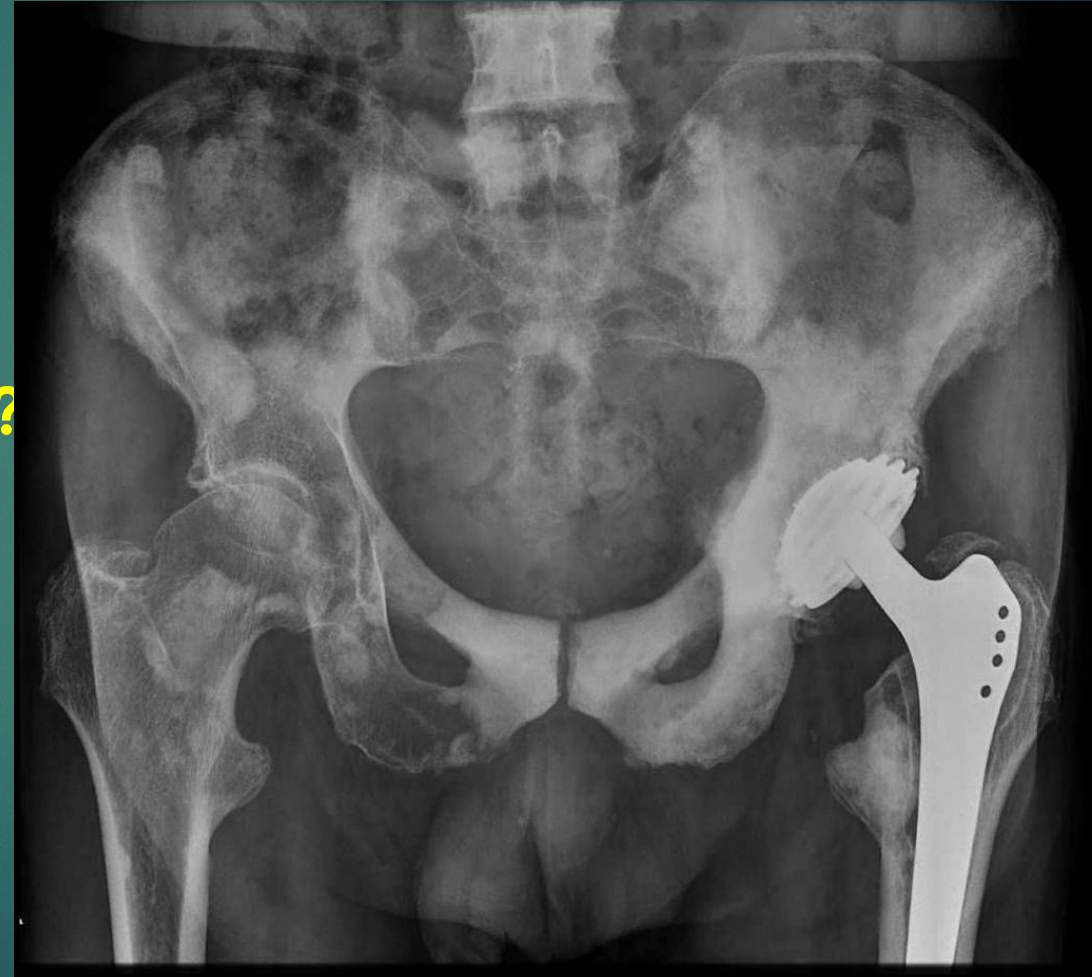Urine analysis :

Pus cells : 30-40 / HPF

Red blood cells : 10-20 /HPF

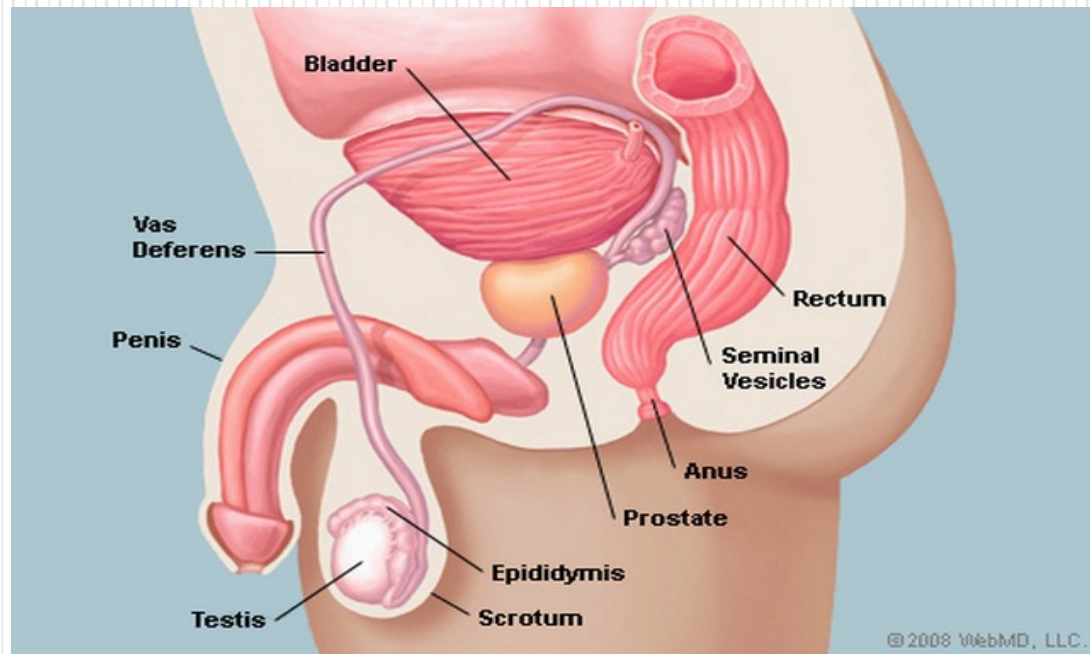
Pelvic X ray

What is your provisional diagnosis?



The Prostate

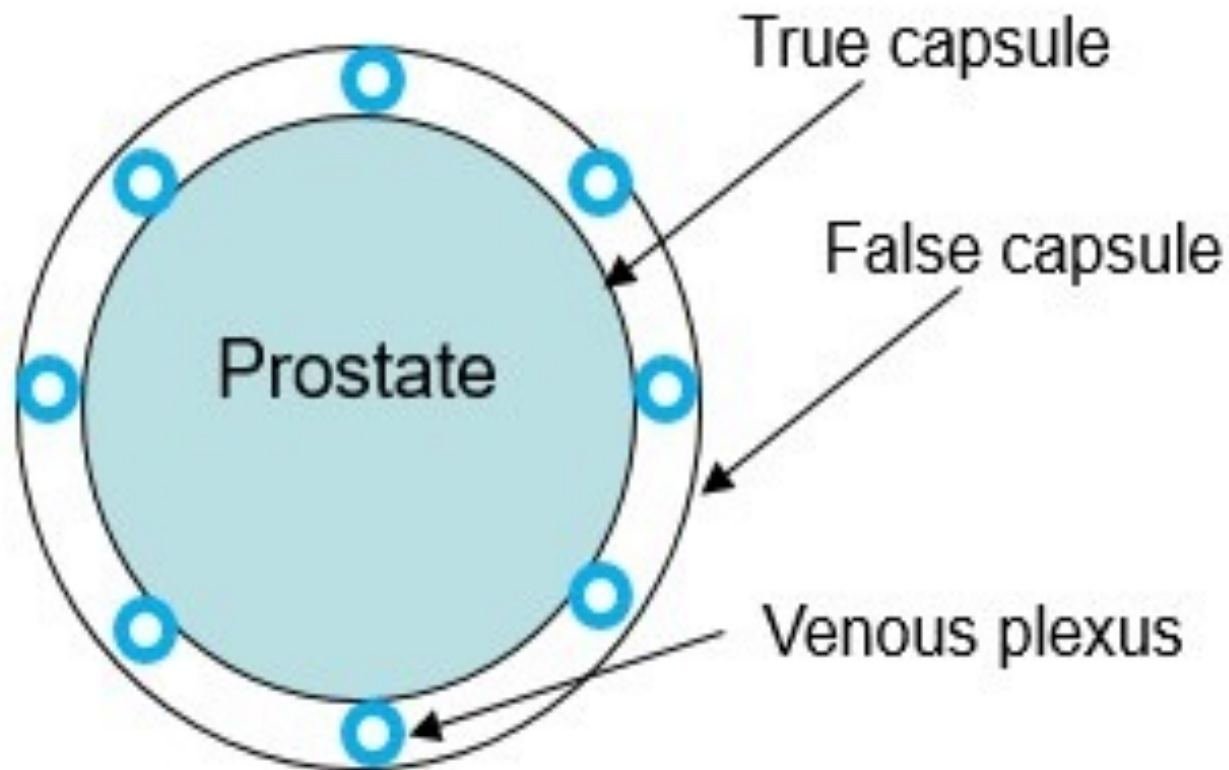
It is an accessory gland of male reproductive system, which surrounds the prostatic urethra



Site : it lies in the lower part of the lesser pelvis behind the inferior border of the pubic symphysis in front of the rectum, below neck of the bladder.

The prostatic capsules:

1. Inner true capsule : It is fibromuscular in structure.
 2. Outer false capsule (prostatic sheath): it is a condensed visceral pelvic fascia.
- Between the two capsules, lies the prostatic venous plexus.



Shape and Description:

It simulates an inverted cone which has a base (directed superiorly); an apex (directed inferiorly), four surfaces: anterior, posterior, and two inferolateral surfaces.

1- Base of the prostate :

- It is directed upwards, separated from the bladder by a groove contains part of the prostatic venous plexus.
- It is pierced by the urethra.

2- Apex of the prostate:

- Is directed downwards
- It rests on the perineal membrane (floor of the deep perineal pouch).
- The urethra emerges from the prostate anterosuperior to the apex.

3-Anterior surface:

- It is convex and lies behind the lower part of the symphysis pubis.
- Its upper part is connected to the pubic bodies by puboprostatic ligaments.
- The urethra emerges from this surface a little above and in front of the apex of the gland.

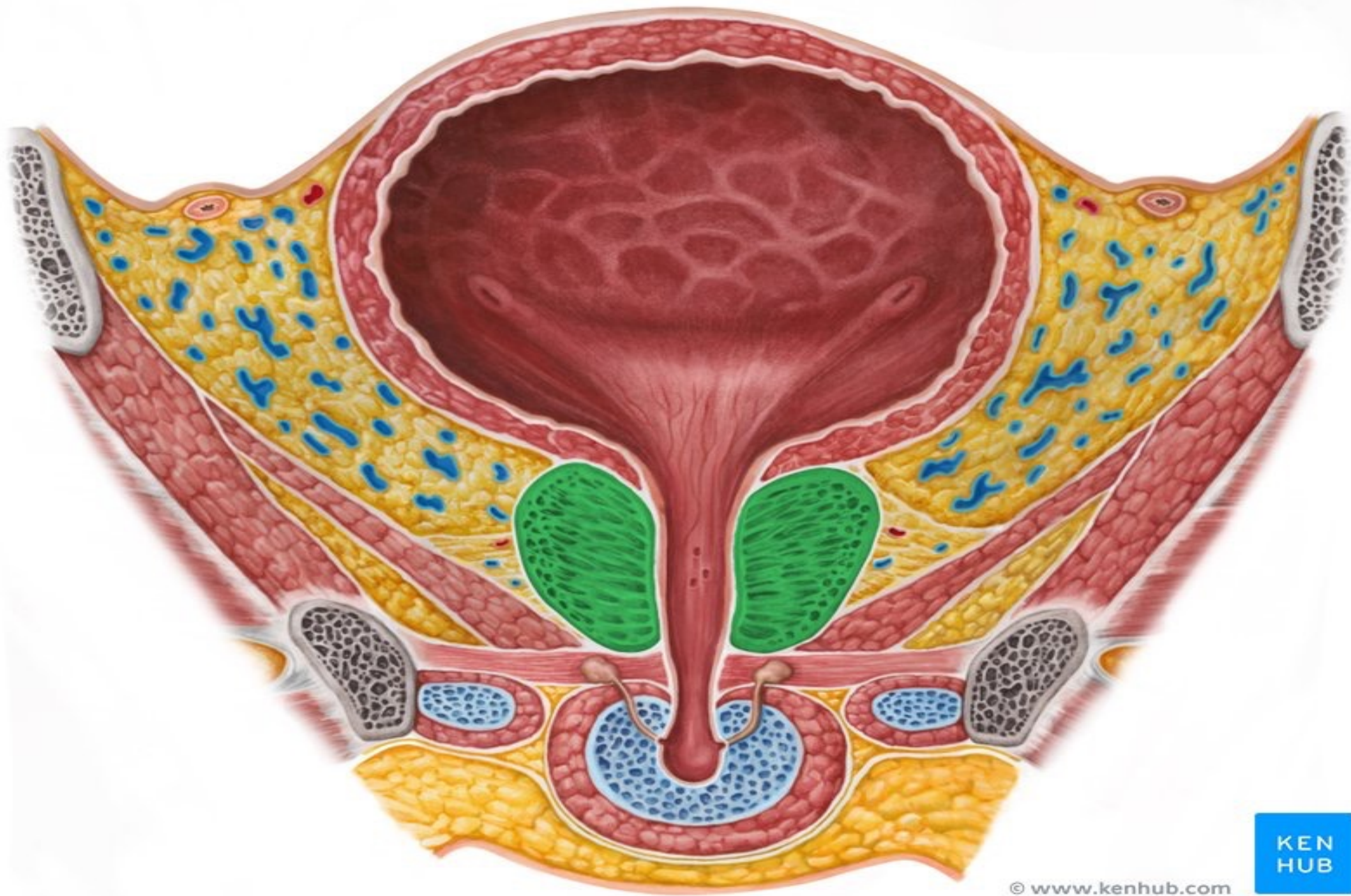
4- Posterior surface:

- It is nearly flat and is related to ampulla of the rectum separated from it by rectovesical fascia (fascia of Denonvilliers)
- The prostate is easily palpated by a finger in the rectum
- Near its upper border, this surface is pierced by the two ejaculatory ducts.

5- Right and left inferolateral surfaces:

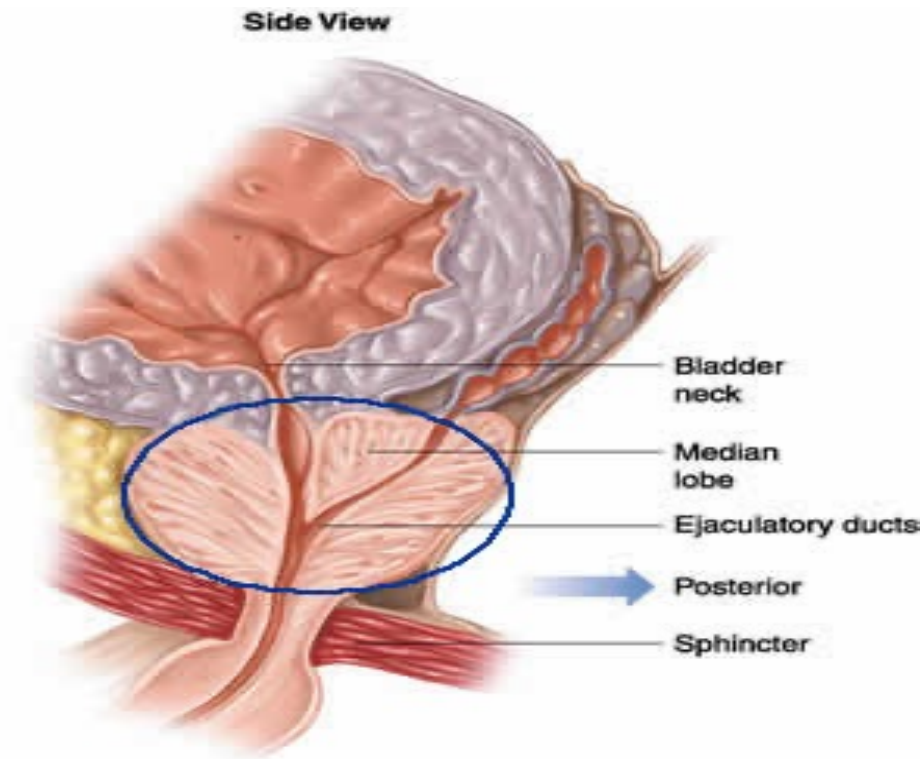
- Are convex and related to levator prostatae parts of levator ani muscle.

N.B Fascia of Denonvilliers is attached above to the floor of rectovesical pouch and below to the perineal body).



Structures that traverse the prostate :

- ❖ Prostatic urethra.
- ❖ The two ejaculatory ducts descend anteroinferiorly to open in the prostatic urethra
- ❖ The gland contains the utricle.



Lobes of the prostate:

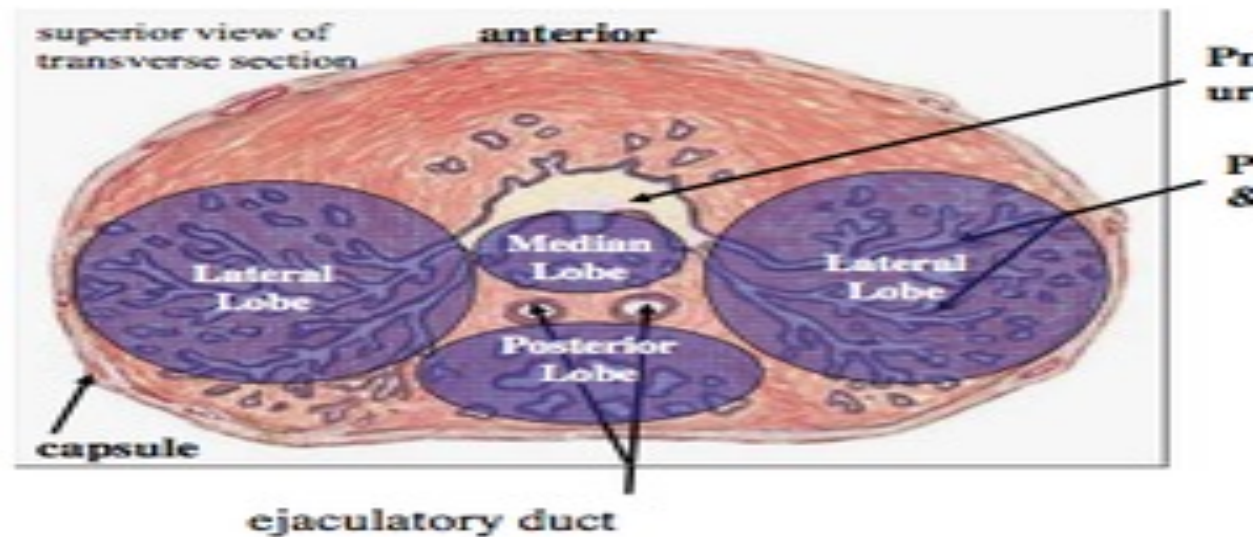
By means of the prostatic urethra and the two ejaculatory ducts, the prostate is divided into five lobes;

Anterior lobe (isthmus): lies in front of the prostatic urethra.

It consists a fibromuscular tissue with little glandular tissue.

Right and left lateral lobes : one on each of the prostatic urethra.

They are the usual sites for the senile enlargement of the prostate.



Posterior lobe : lies behind the prostatic urethra, but below the two ejaculatory ducts.

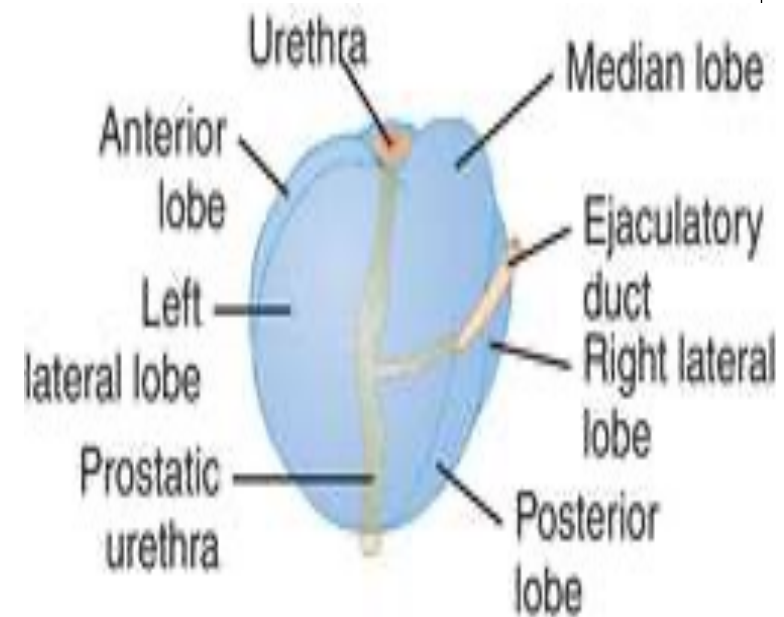
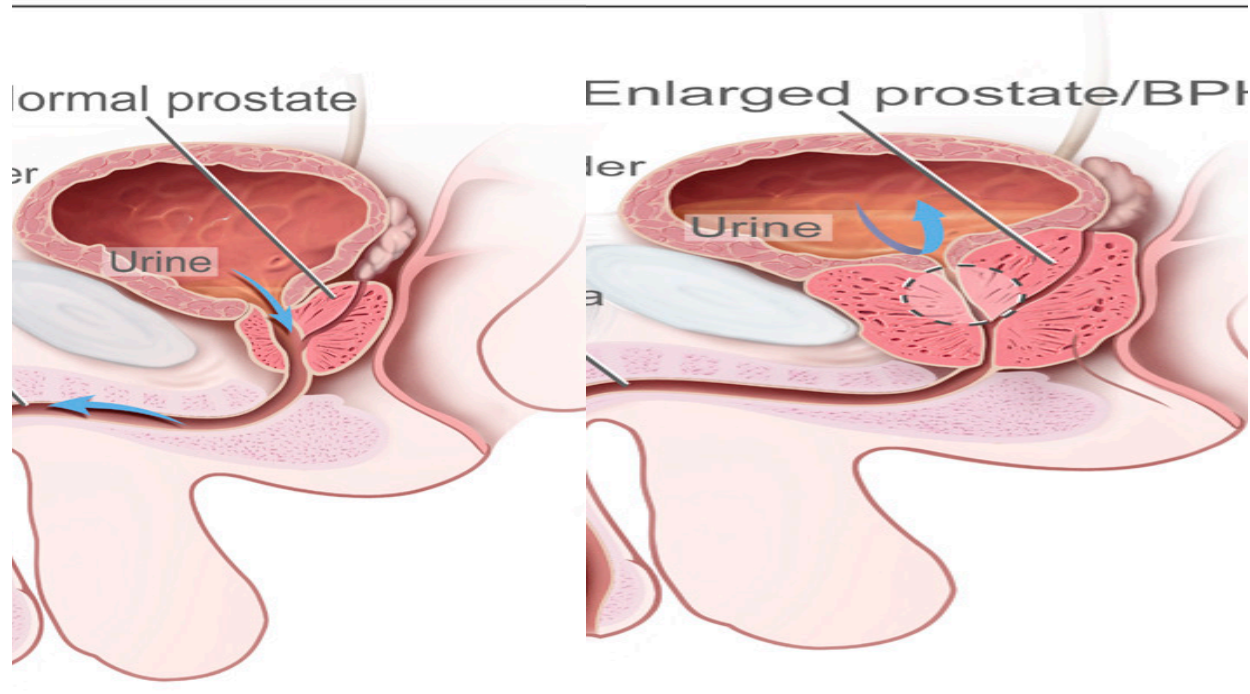
It is the usual site for cancer prostate.

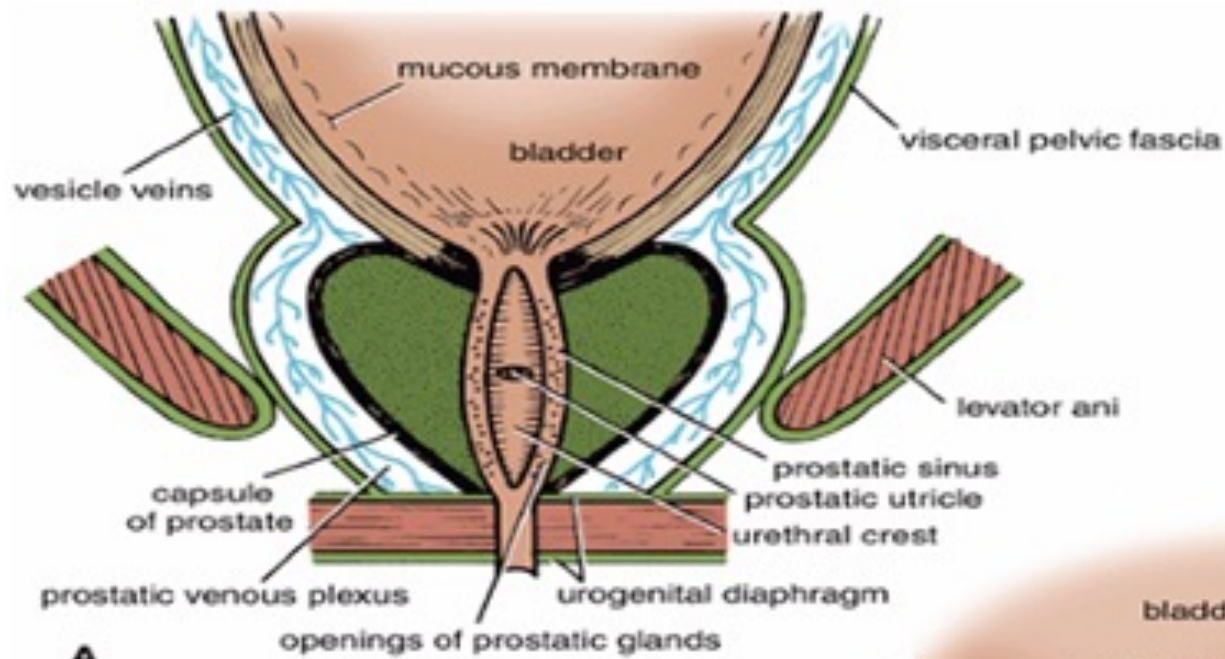
Median lobe: Lies between the upper part of prostatic urethra and the two ejaculatory ducts.

After middle age, it produces uvula vesicae, in the lower part of the bladder trigone

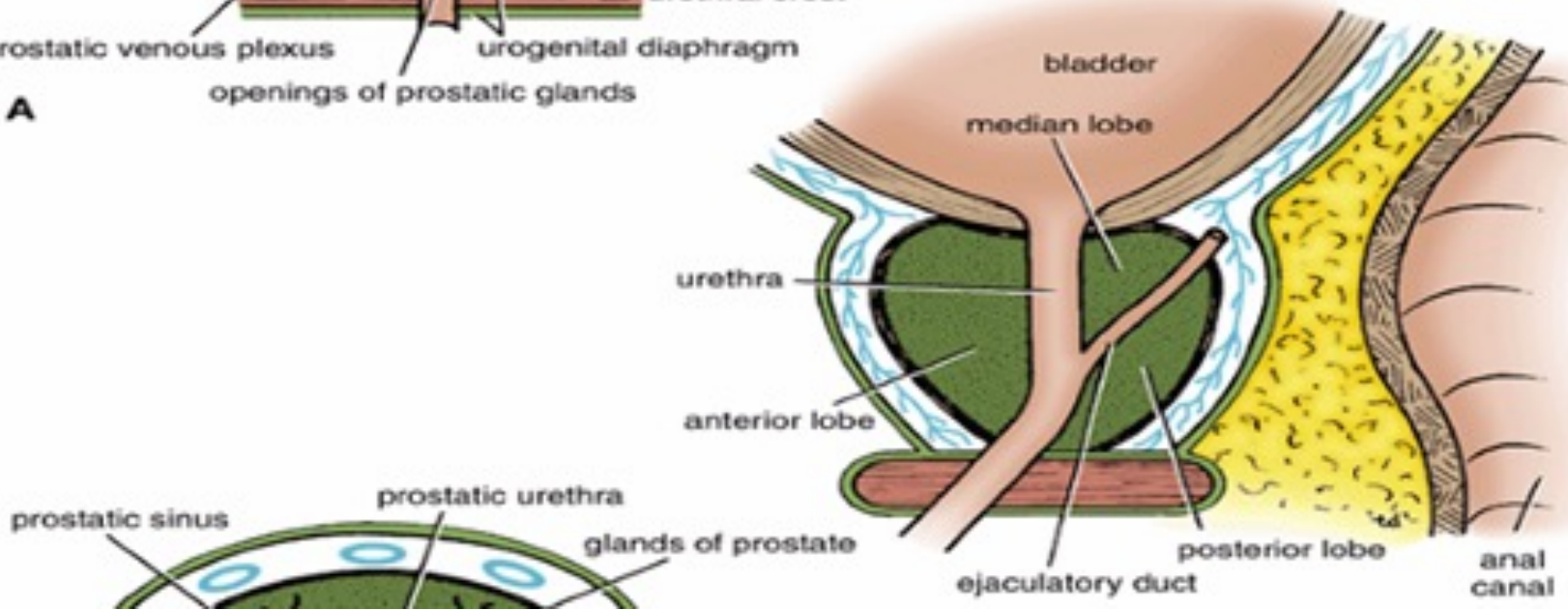
It is also a common site for senile enlargement of the prostate. (BPH)

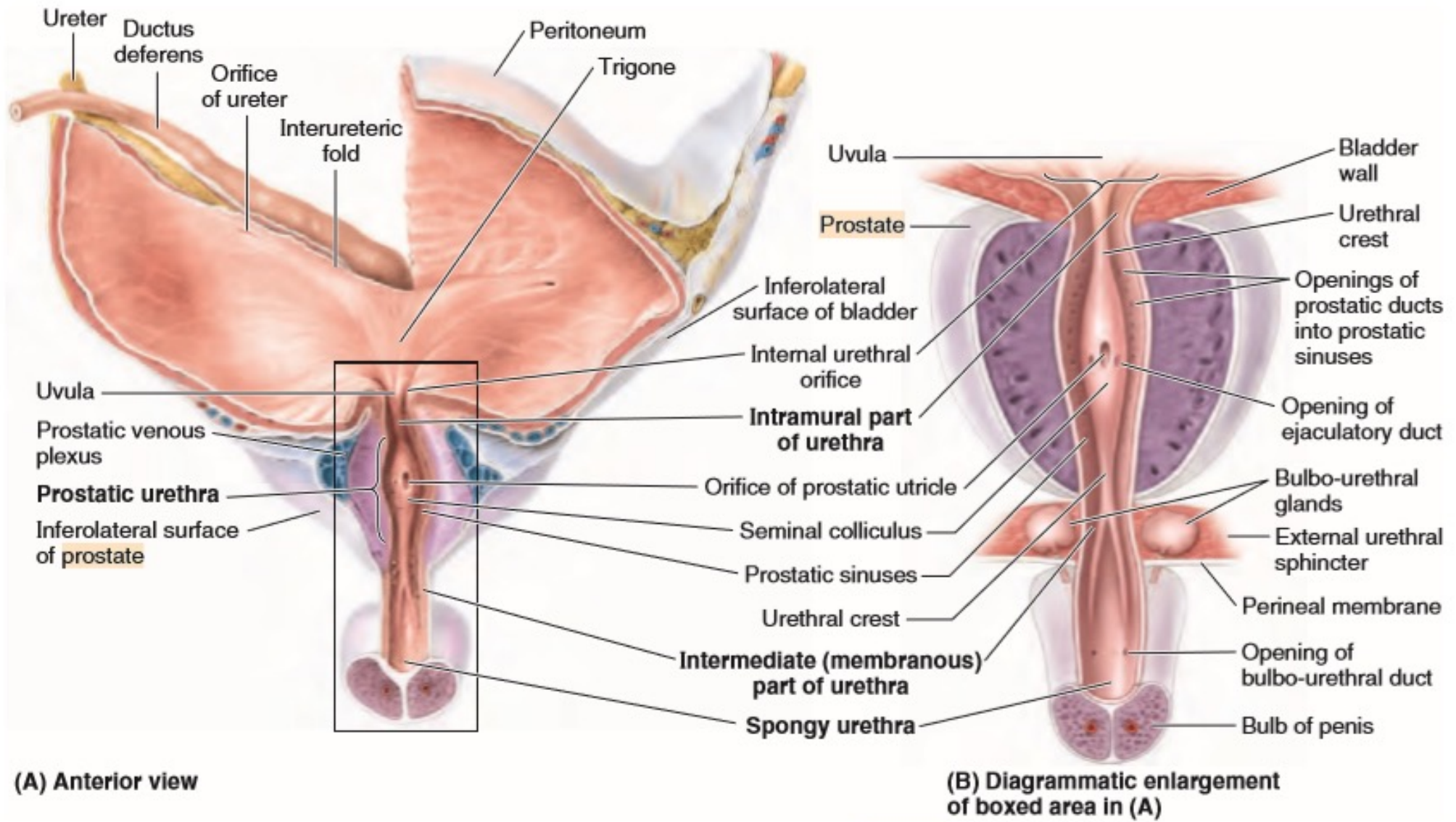
The uvula vesicae may obstruct the flow of urine at the internal urethral meatus.

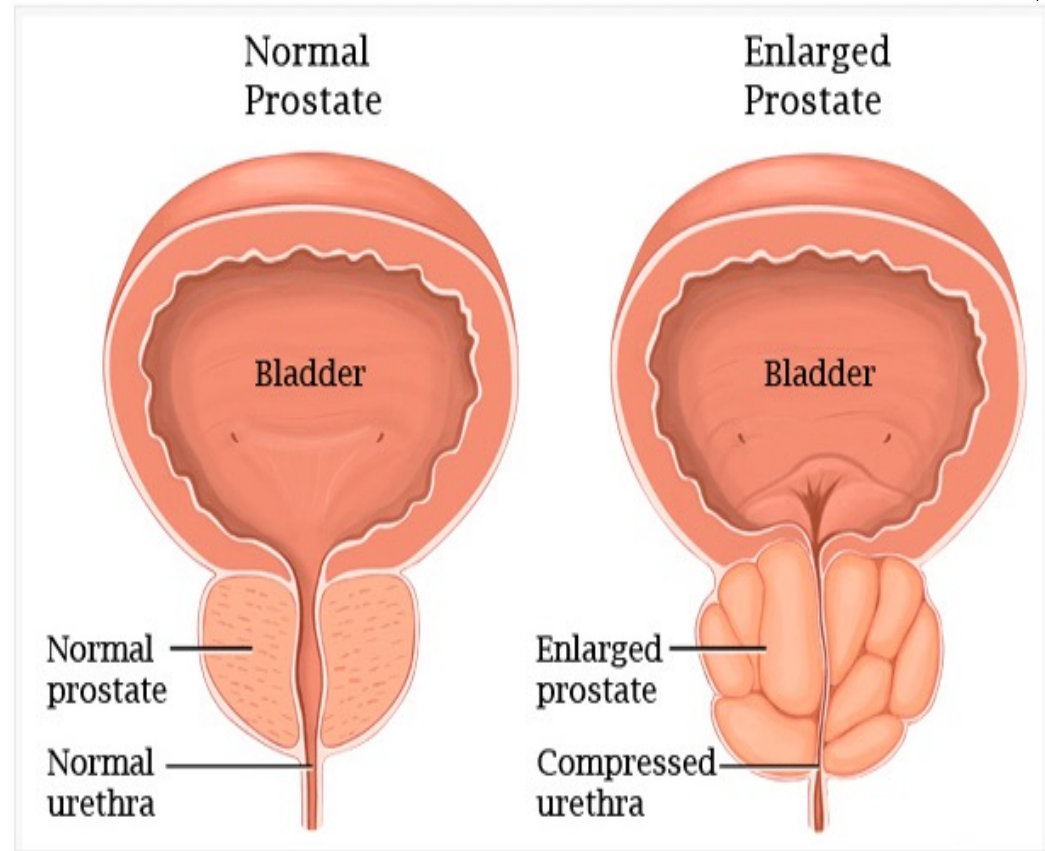
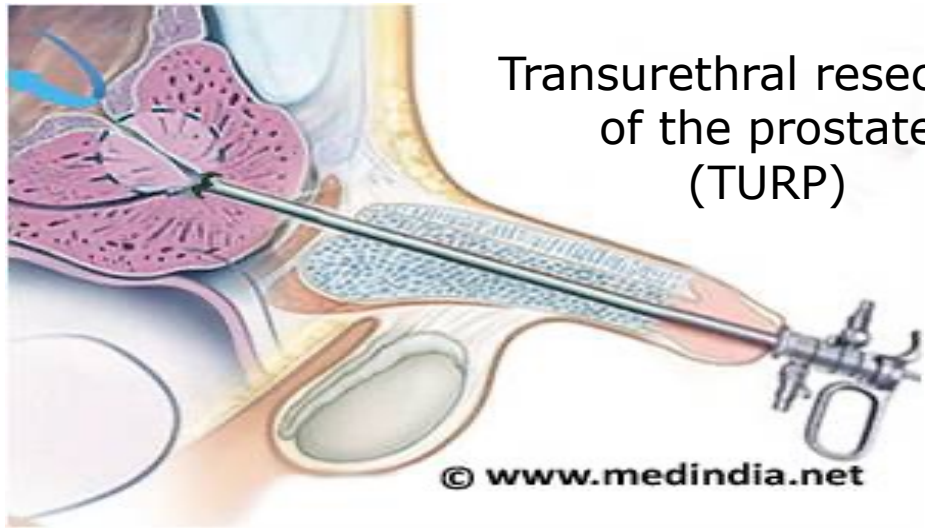
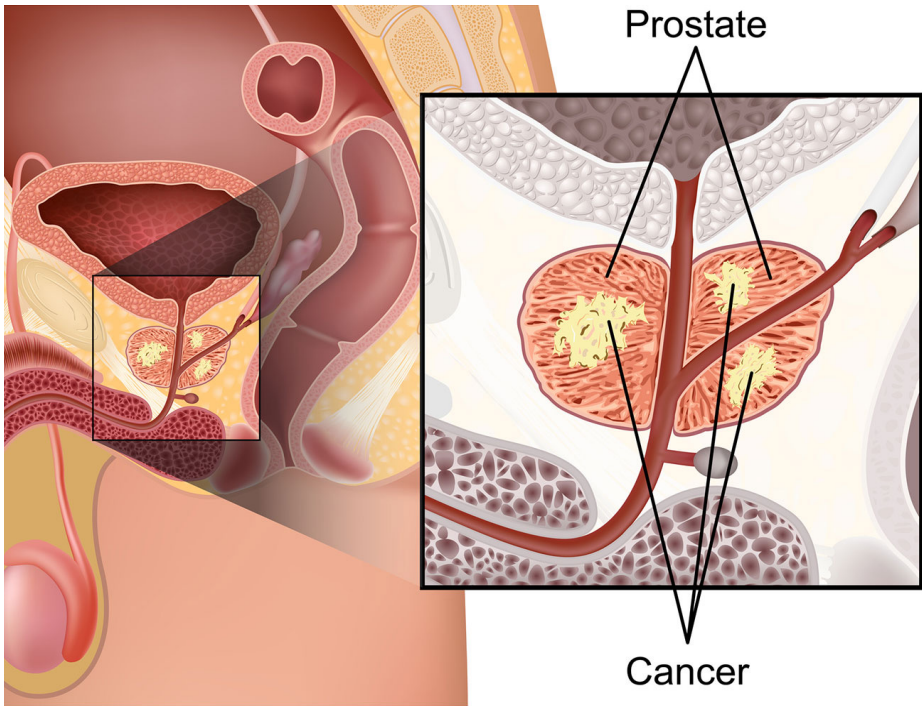


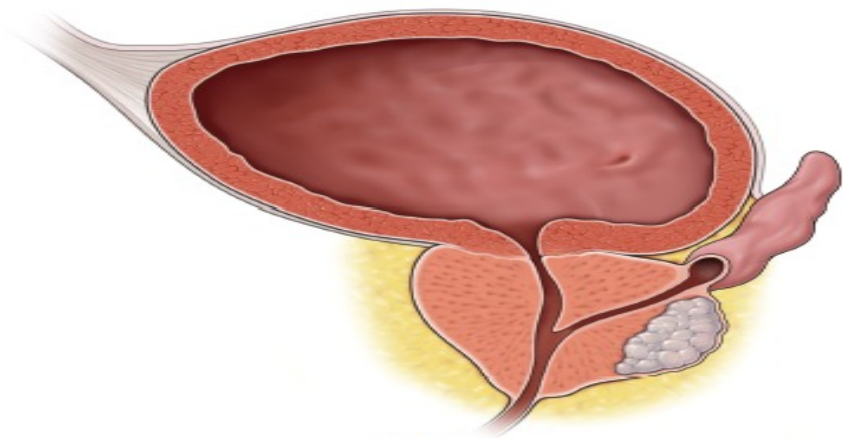


A

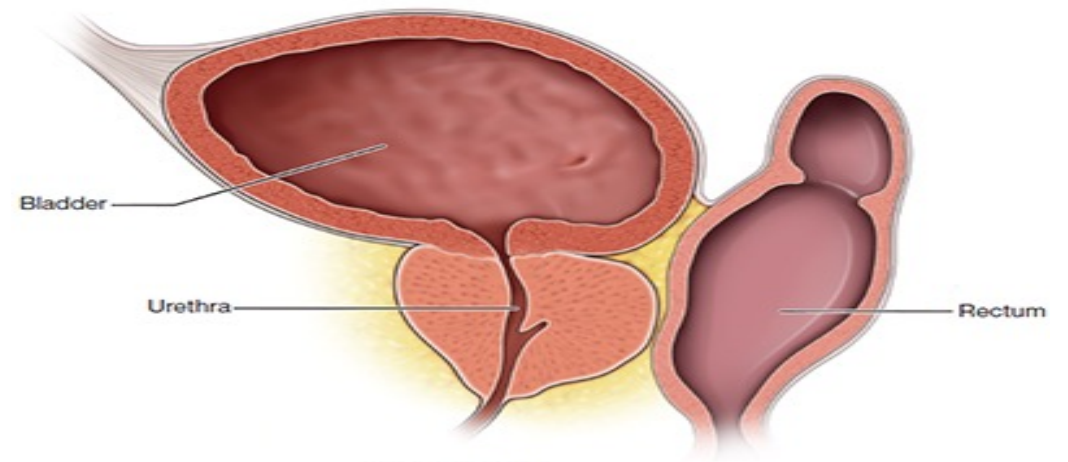








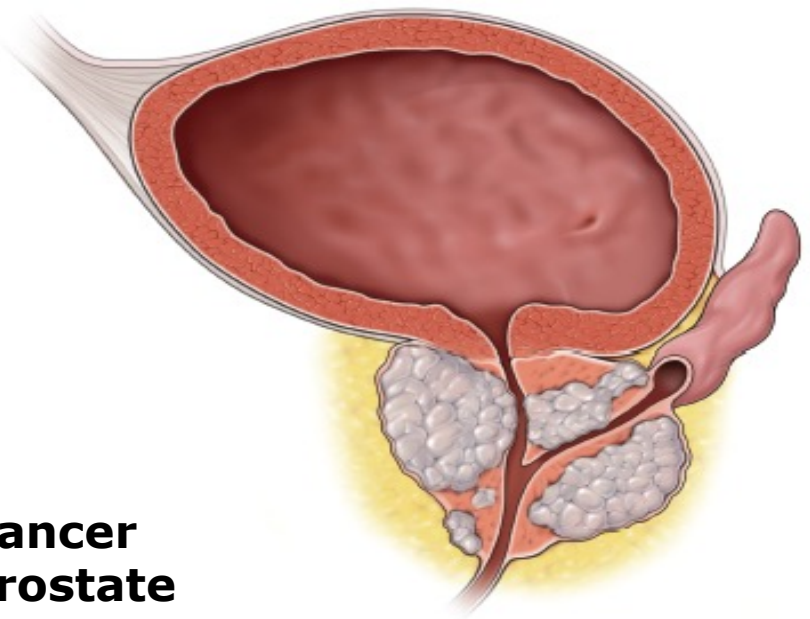
Prostate cancer



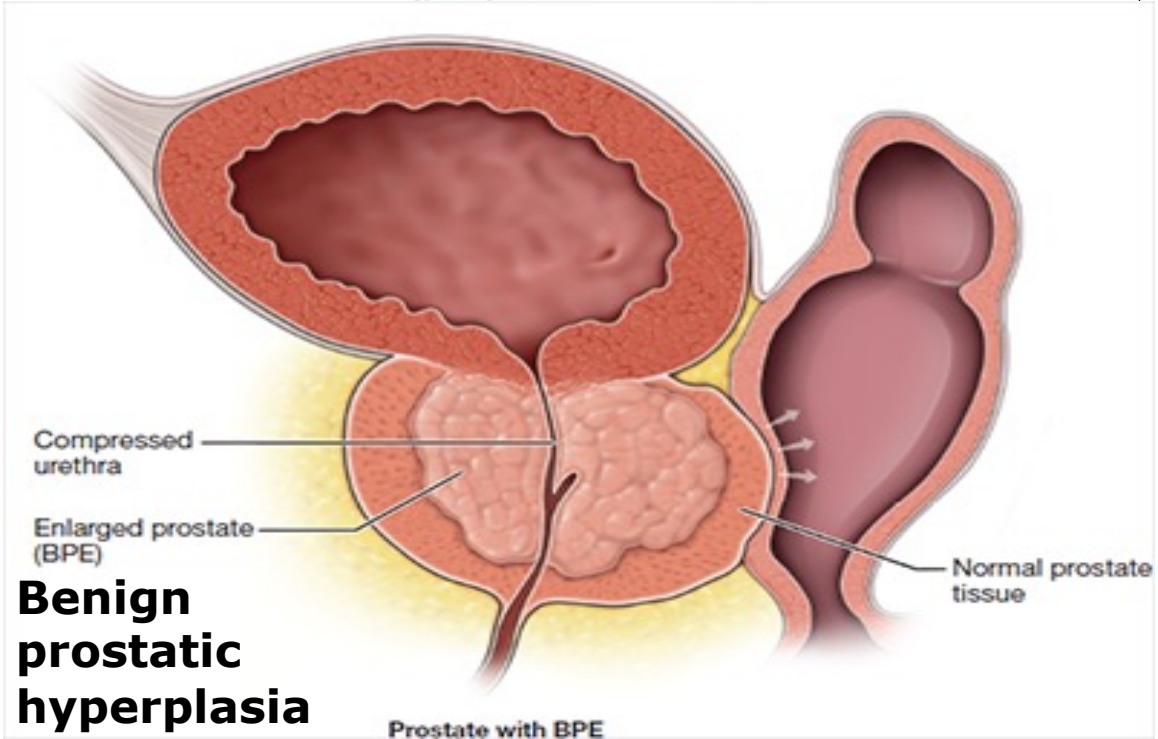
Bladder

Urethra

Rectum



Advanced prostate cancer



Compressed urethra

Enlarged prostate (BPE)

Normal prostate tissue

Benign prostatic hyperplasia


Prostate with BPE

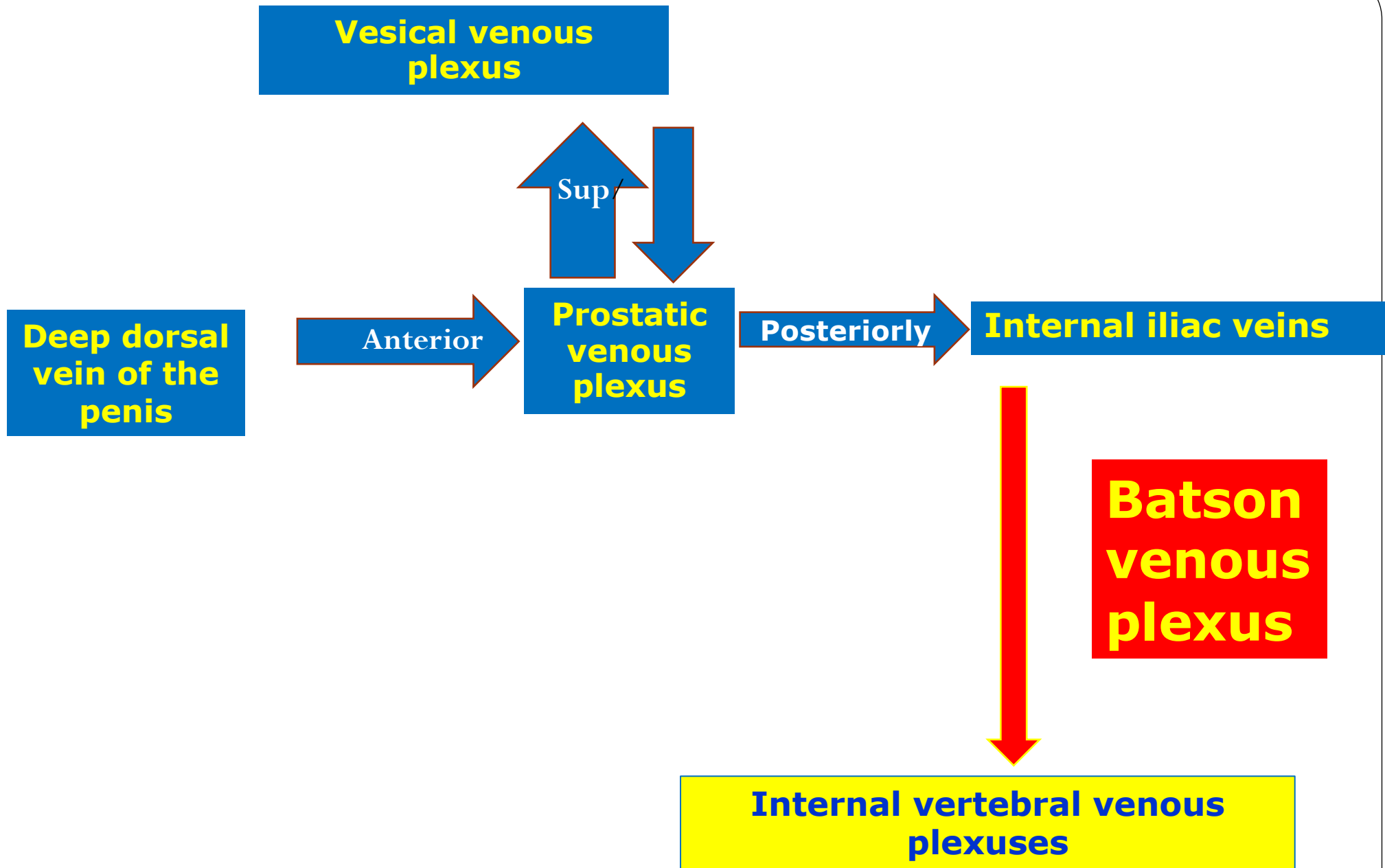
Cancer prostate

Blood Supply of the Prostate:

Arteries are derived from inferior vesical and middle rectal arteries.

Venous drainage : the veins form the prostatic venous plexus which has the following features :

- ❖ It is embedded between the two capsules of the prostate.
 - ❖ It is present only in front and sides of the gland
 - ❖ Superiorly, it is continuous with the vesical venous plexus.
 - ❖ Anteriorly : it receives the deep dorsal vein of penis.
-  Posterolaterally : the plexus is drained to the internal iliac veins which in turn communicates with the internal vertebral venous plexuses by the Batson venous plexus.
- These veins are valveless and responsible for spread of cancer prostate to lumbar vertebrae

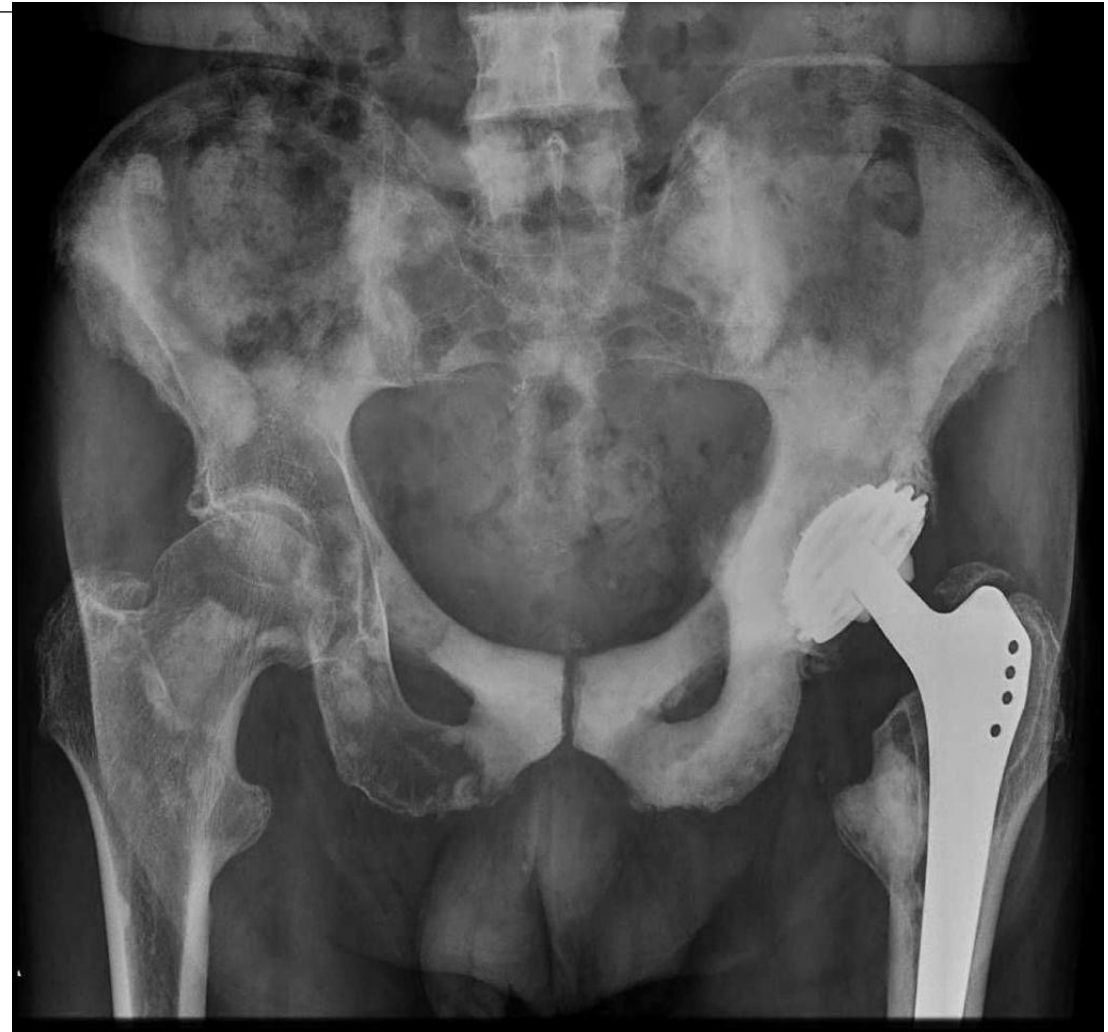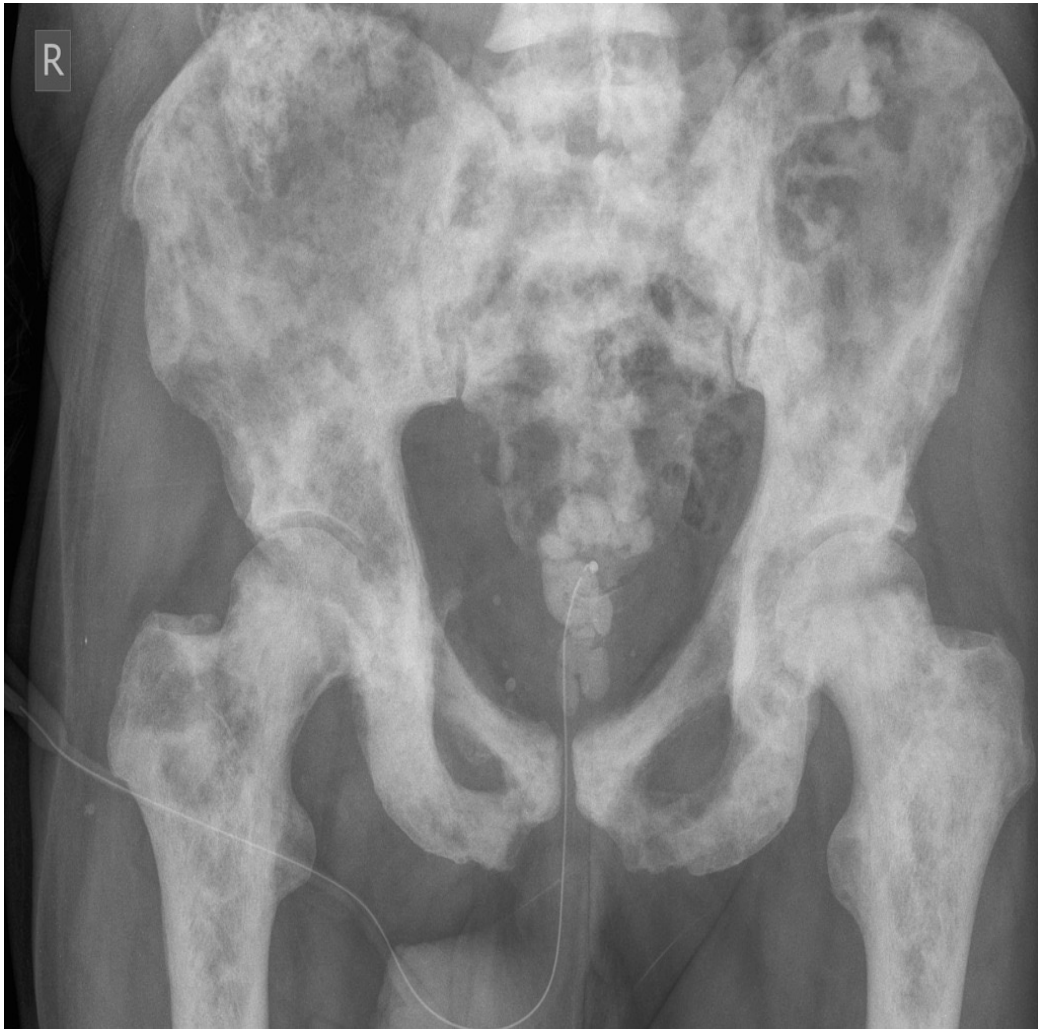


Lymphatic Drainage: to internal, external iliac lymph nodes.

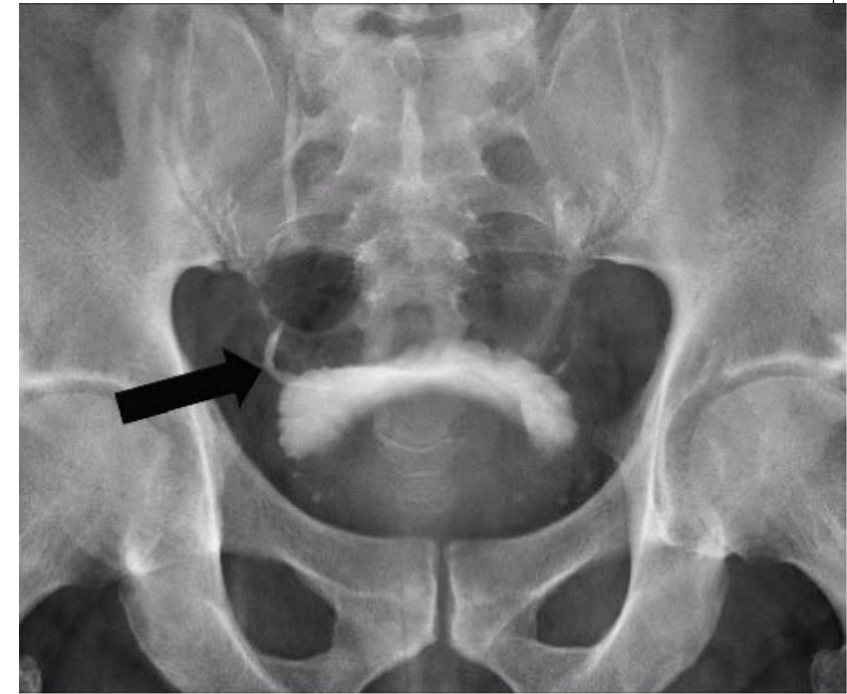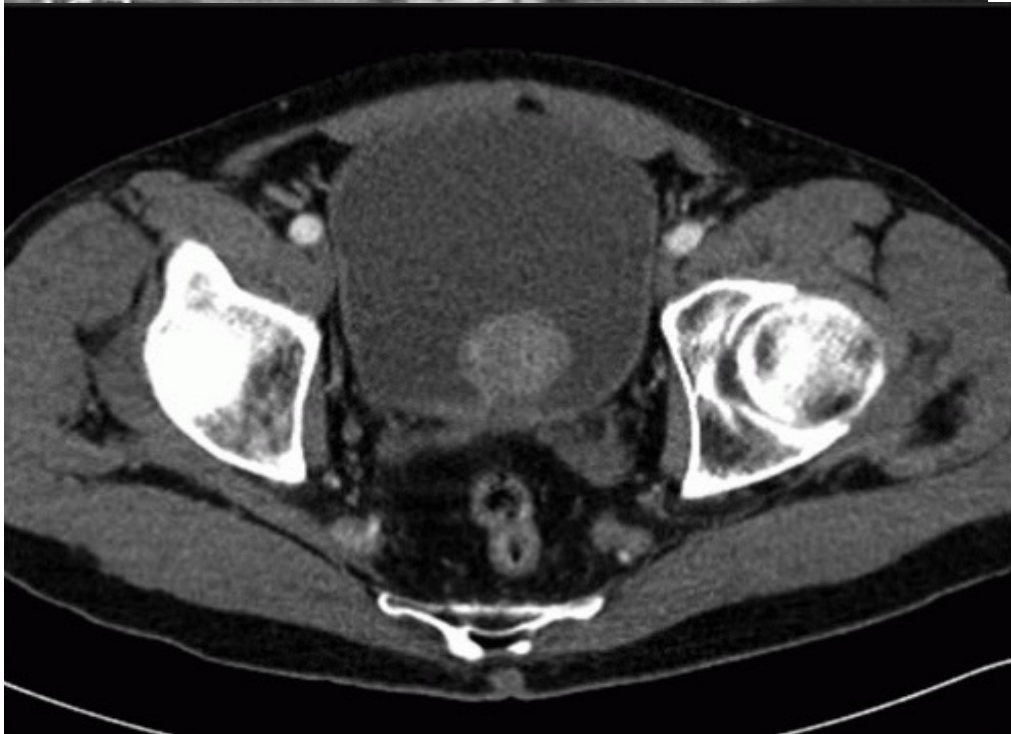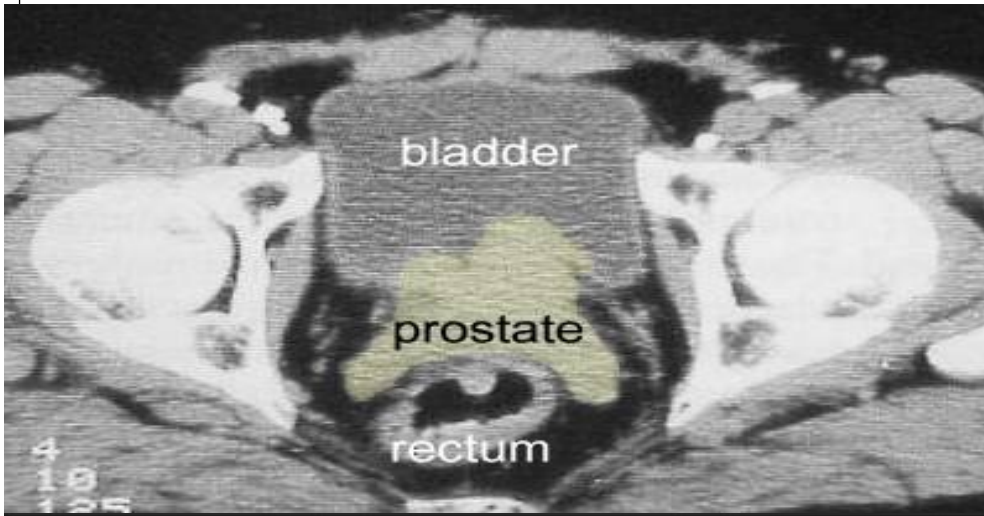
Nerve Supply: by prostatic nerve plexus derived from the inferior hypogastric plexus.



Acid phosphatase and Prostate-Specific Antigen (PSA) are markedly elevated in prostatic diseases especially carcinoma

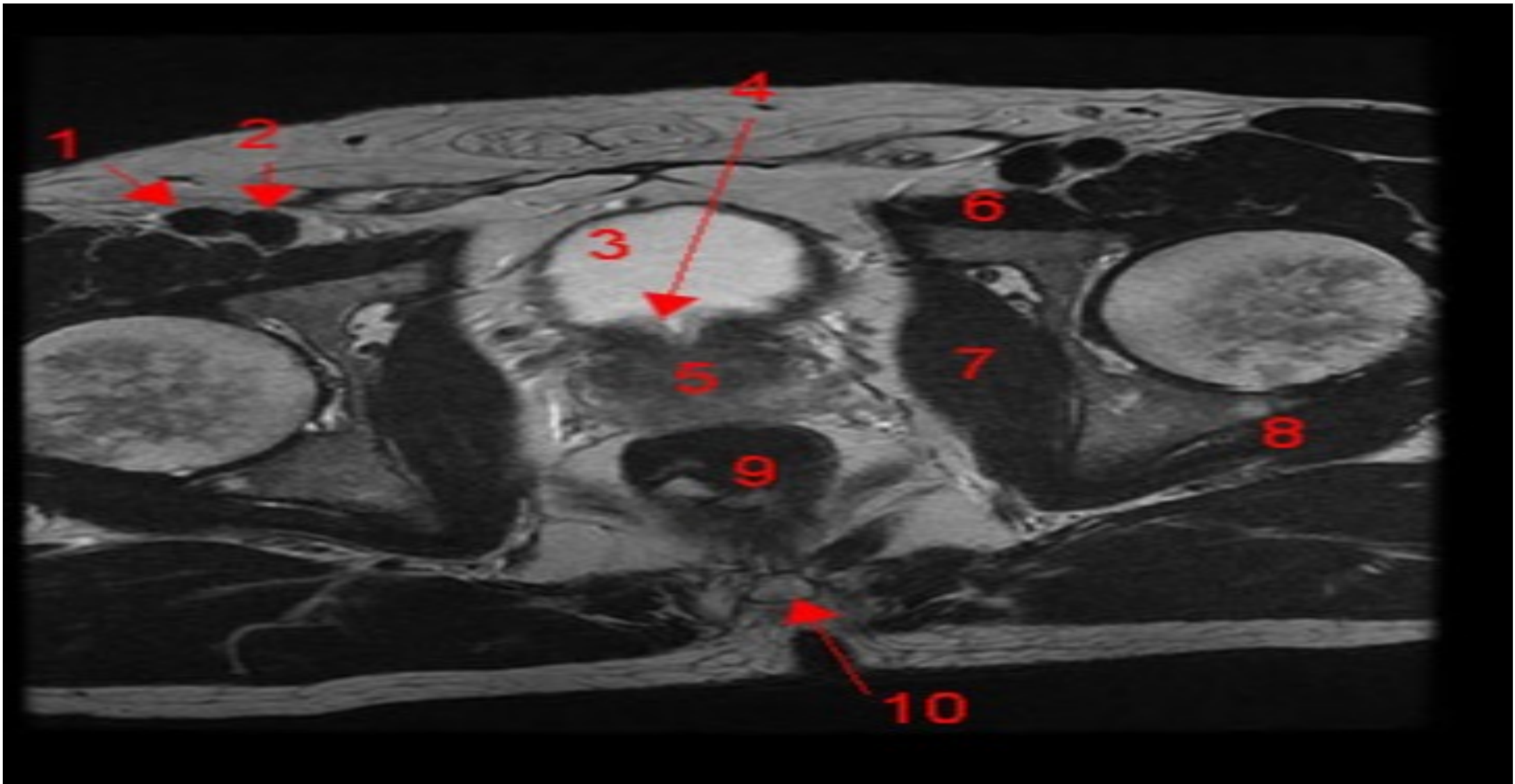


Bone metastases



BPH. The enlarged prostate indents and elevates the bladder floor.

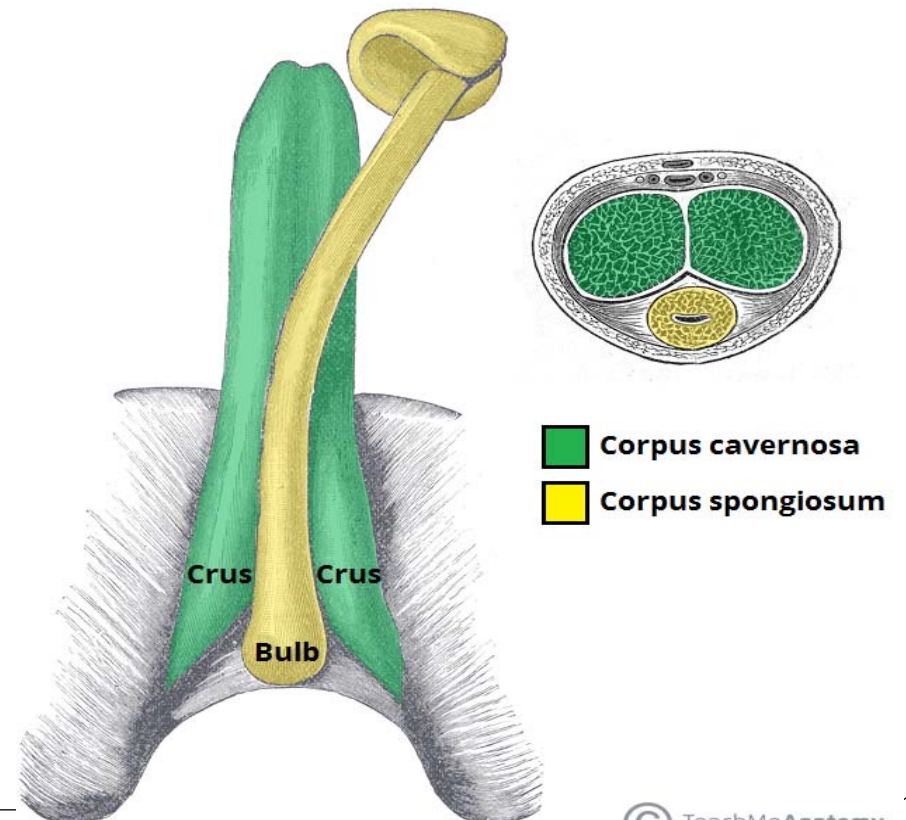
CT :Median lobe. This enlarged portion of the prostate produces a polypoid midline mass in the bladder lumen.



1, femoral a. 2, femoral v. 3, bladder 4, bladder neck 5, prostate 6, pectineus m.
7, obturator internus m. 8, gemellus (superior, inferior) m. 9, rectum 10, coccyx

Penis

- ❖ It has a root (or attached portion) and a shaft (or free portion).
- ❖ The root is formed of 3 parts; two crura (right and left) and bulb of penis, all are present in the superficial perineal pouch of perineum .
- ❖ The **bulb** is covered on its outer surface by the **bulbospongiosus** muscles
- ❖ The shaft is formed of 3 columns of erectile tissue; two corpora cavernosa (right and left) and a median corpus spongiosum.
- ❖ Each **crus** is attached to the side of the pubic arch and is covered on its outer surface by the **ischiocavernosus** muscle.



The shaft of the penis

The body of the penis is essentially composed of three cylinders of erectile tissue enclosed in a tubular sheath of fascia (Buck's fascia).

A- The two corpora cavernosa:-

- They lie dorsally side by side in the shaft of penis.
- The corpora cavernosa contain many irregular cavernous spaces which become filled by blood during erection.
- Each is firmly surrounded by fibrous tissue called tunica albuginea which also sends a median septum between the two .
- Followed distally, the corpora cavernosa end in pointed projections within the glans penis .
- Followed proximally (towards the root of the penis), the two corpora cavernosa diverge from each and continue as the crus penis, which becomes firmly attached to the ischio pubic ramus

B- The corpus spongiosum

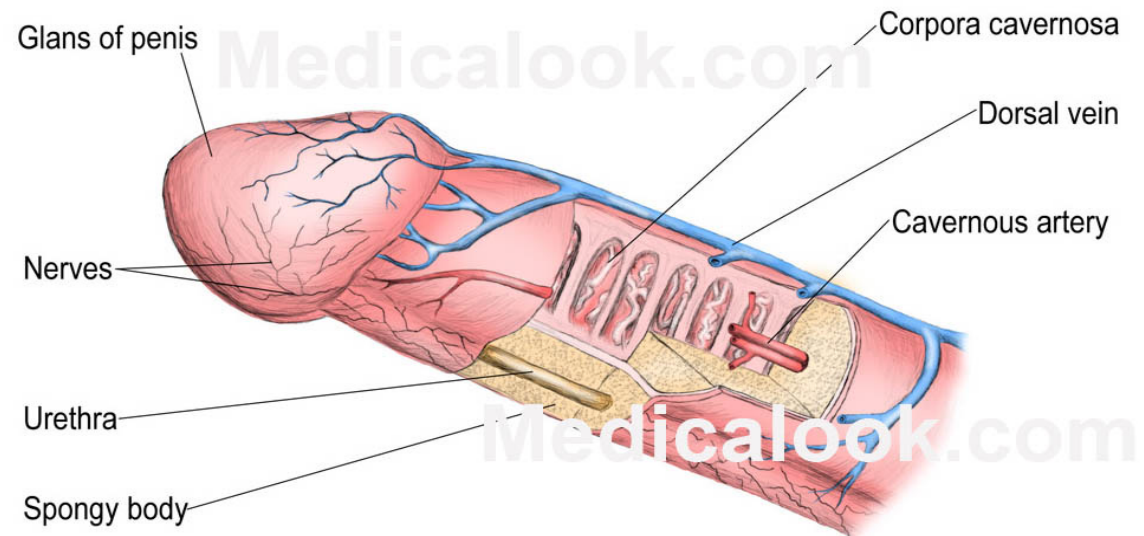
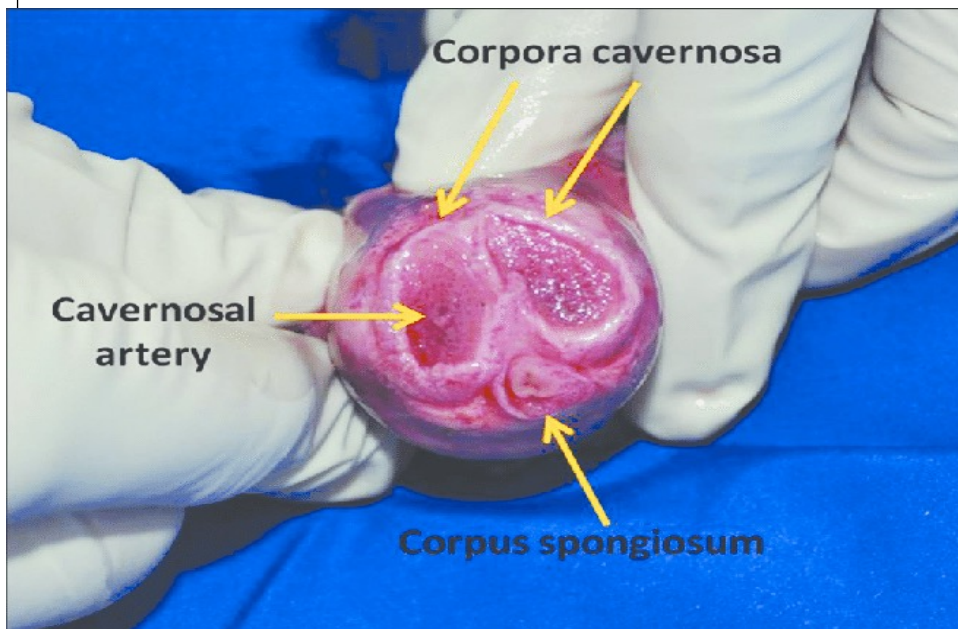
It is median and lies in the ventral surface of the two corpora cavernosa.

It is also surrounded by a separate sheath of tunica albuginea

Followed distally, it forms glans penis ,The base of the glans penis is called the corona glandis

Followed proximally (towards the root of the penis), it forms bulb of penis which is attached to the perineal membrane.

The corpus spongiosum is traversed by the penile part of the urethra. It also contains cavernous tissue capable of erection.



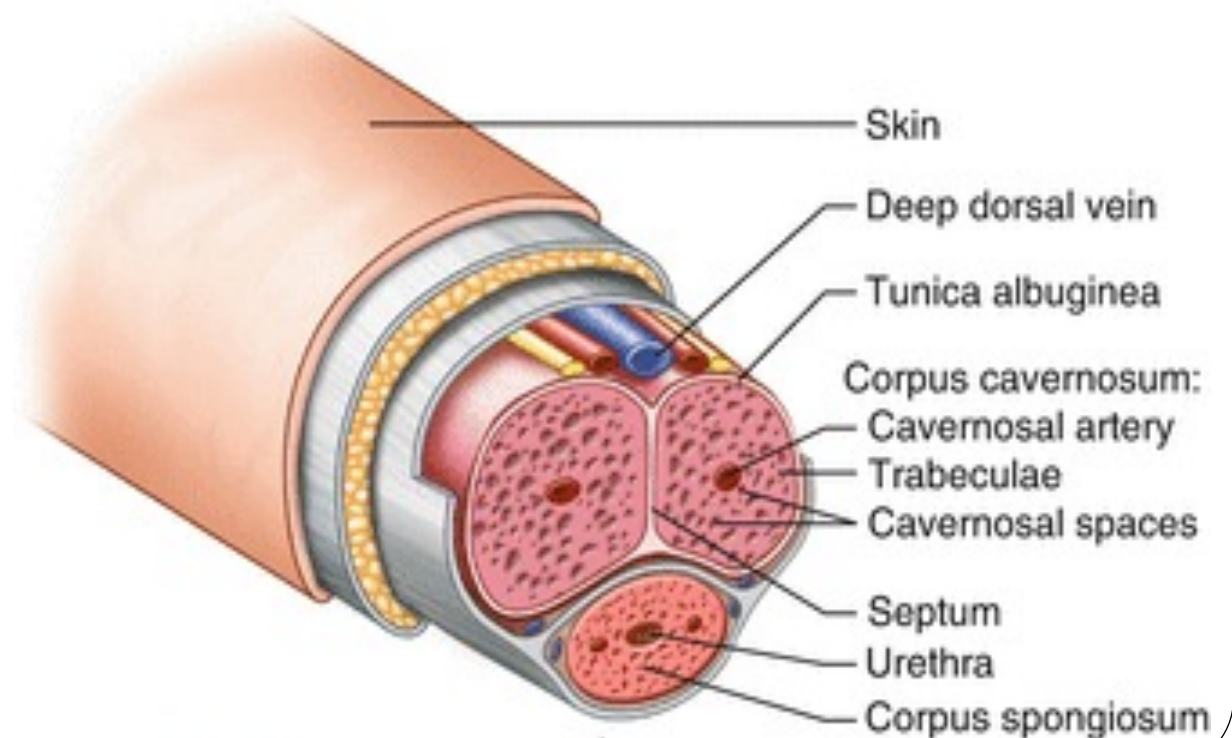
The skin of the penis

Followed distally, the skin forms a loose fold called the prepuce or foreskin which covers the glans.

The deep layer of this fold is attached to the coronary sulcus of the glans by frenulum followed proximally.

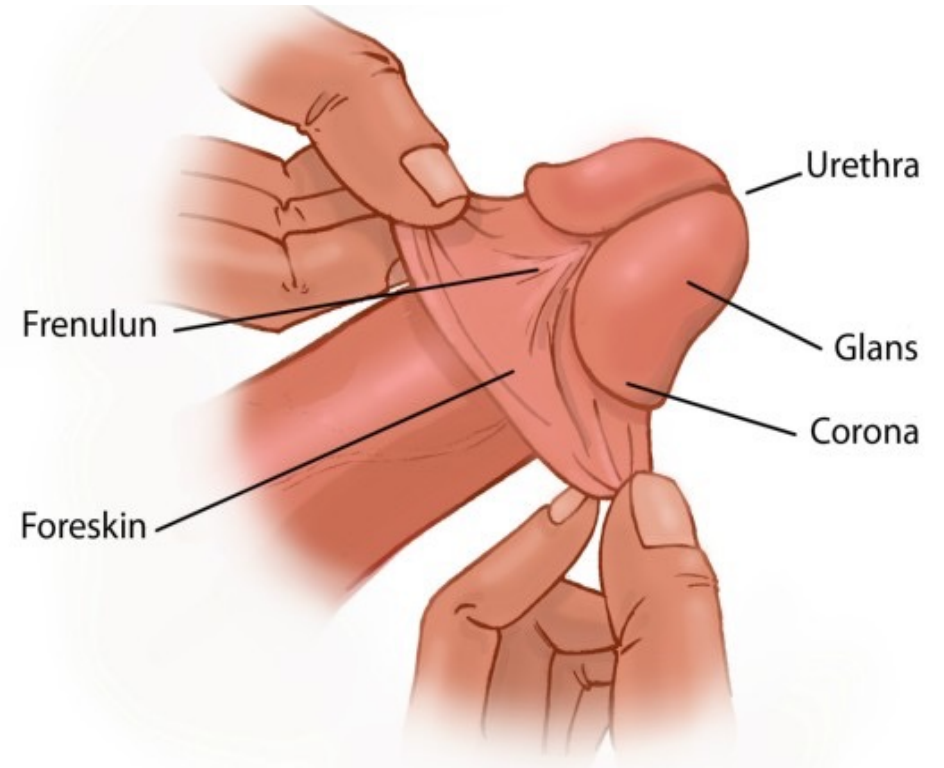
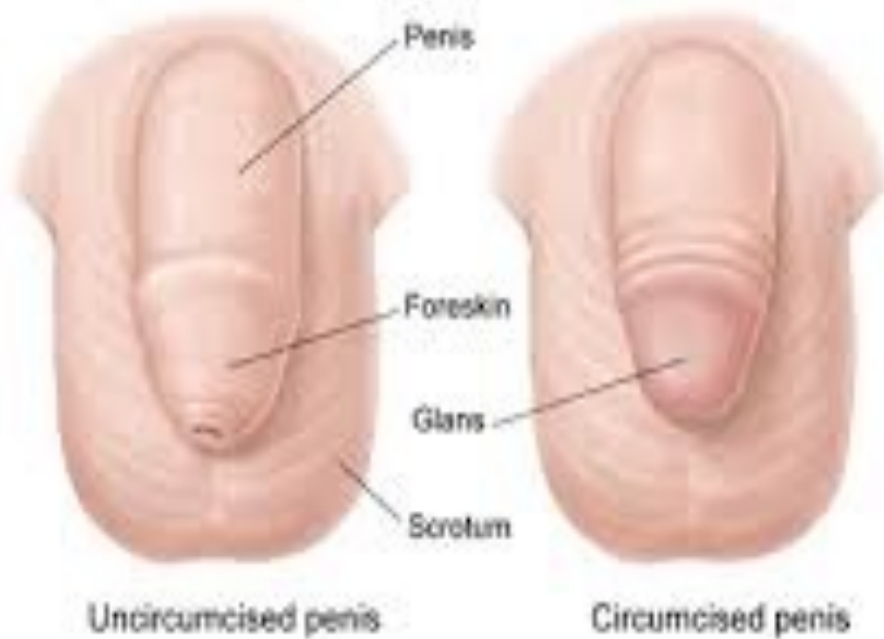The fascia of the penis

The superficial penile fascia is devoid of fat (like the scrotum) but rich in loose connective tissue to allow free movement of skin over the shaft of penis.



Circumcision

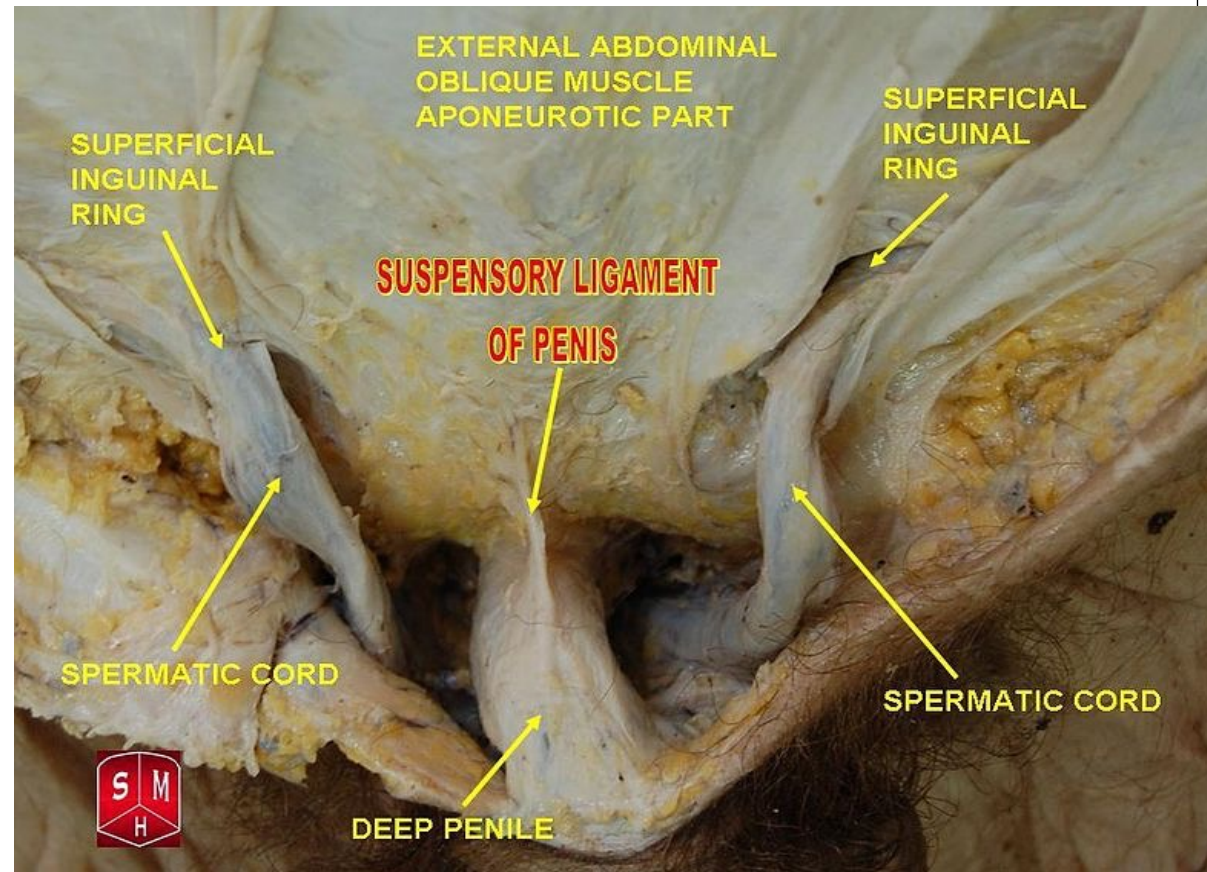
is the operation of removing the greater part of the prepuce, or foreskin.

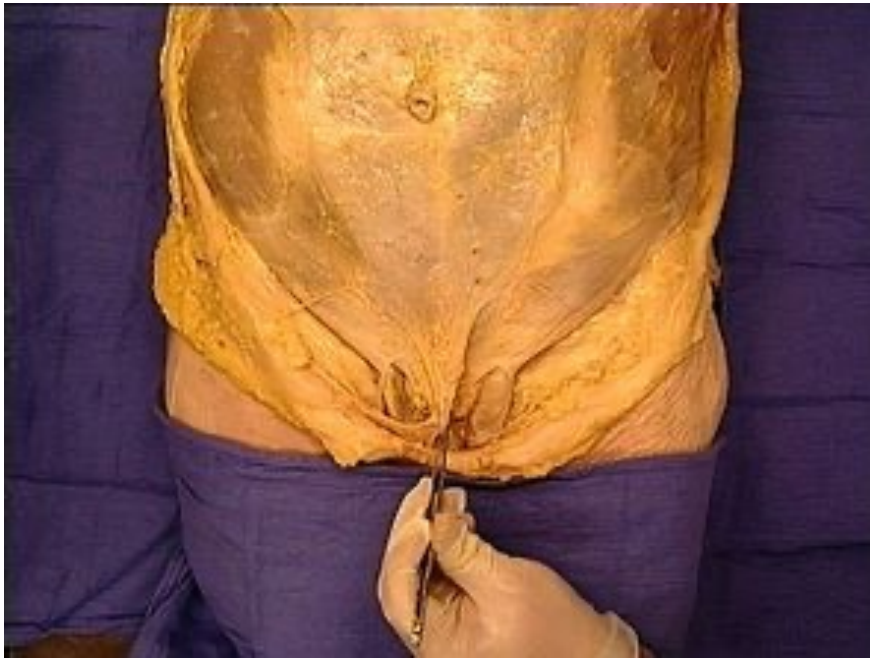

The ligaments of the penis

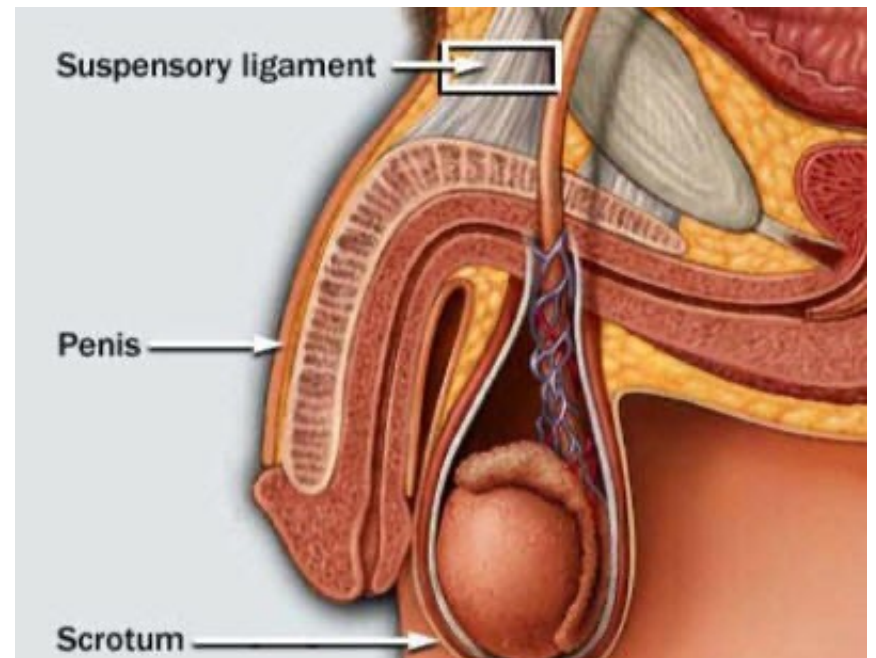
Fundiform ligament: arise from the lower part of the linea alba, its fibers split to surround the proximal part of the penile shaft to insert into the midline raphe of the scrotum.

Suspensory ligament: (deep to the fundiform ligament), extends from the symphysis pubis and blends below with fascia penis.





Fundiform ligament



Suspensory ligament

Arteries of the penis

All are branches of internal pudendal artery and all are paired (right and left).

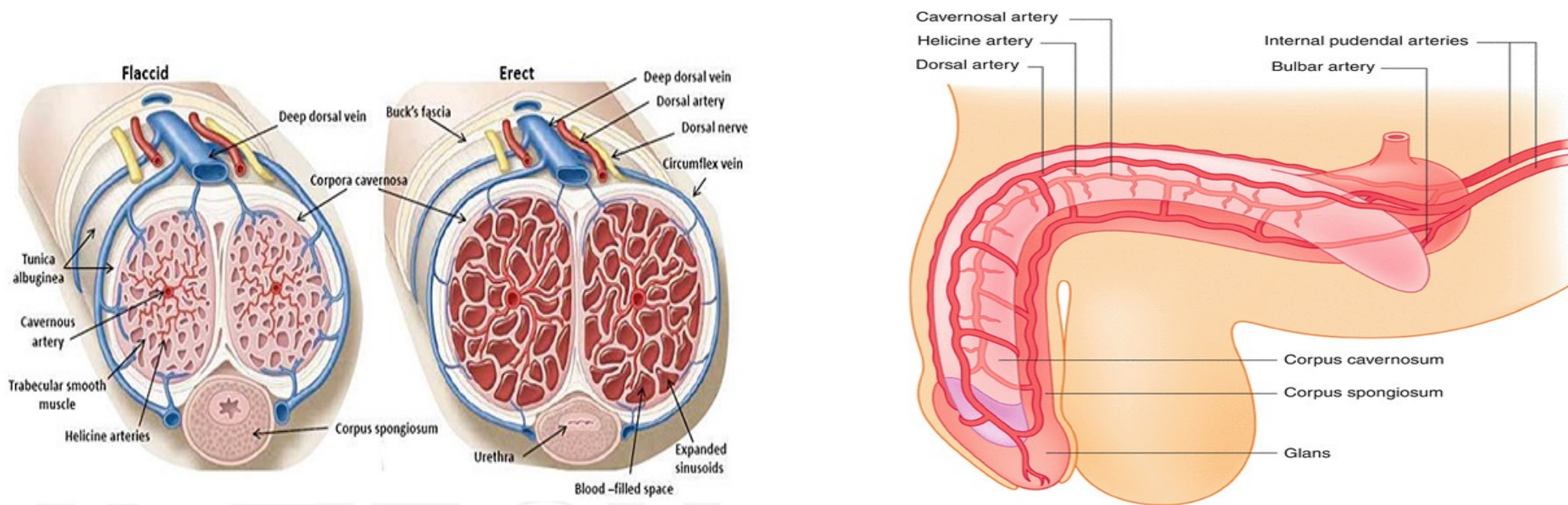
- **Dorsal artery** of the penis supplies the skin, fascia, and glans .
- **Deep artery** of the penis supplies the corpus cavernous with convoluted helicine arteries
- **Artery of the bulb** supplies the corpus spongiosum and glans penis

Venous drainage

By 2 dorsal veins which are superficial and deep;

1 . Superficial dorsal vein (superficial to the fascia penis); divides into right and left .Each ends in the corresponding superficial external pudendal vein.

2. Deep dorsal vein of the penis (deep to fascia penis), passes below symphysis pubis to terminate in prostatic venous plexus.



Lymph drainage

From the penis into **superficial inguinal lymph nodes** (with the scrotum).

From glans penis, lymphatics drain **directly** to gland of **Cloquet** in the femoral canal.

Nerves of the penis

1. Dorsal nerve of the penis (sensory), is a branch of pudendal nerve, runs **lateral** to the dorsal artery of the penis

2. Cavernous nerves (autonomic) arise from the inferior hypogastric plexus
,Parasympathetic fibers (S2,3,4) produce vasodilatation & erection of penis

Thank You!

