

**The University Of Jordan
Faculty Of Medicine**



Anatomy of the pelvis

By

Dr. Ahmed Salman

Associate Professor of Anatomy & embryology

Learning Objectives

1. Bony pelvis, its joints and ligaments
2. Pelvic Diameters
3. Muscles of Pelvis
4. Blood Supply Of pelvis
5. Nerve Supply Of the Pelvis
6. Lymph Drainage of the Pelvis
7. Peritoneum of Pelvis

1- Bony pelvis, its joints and ligaments

The bony pelvis is formed of 4 bones :

Right and left hip bones, the sacrum, and coccyx.

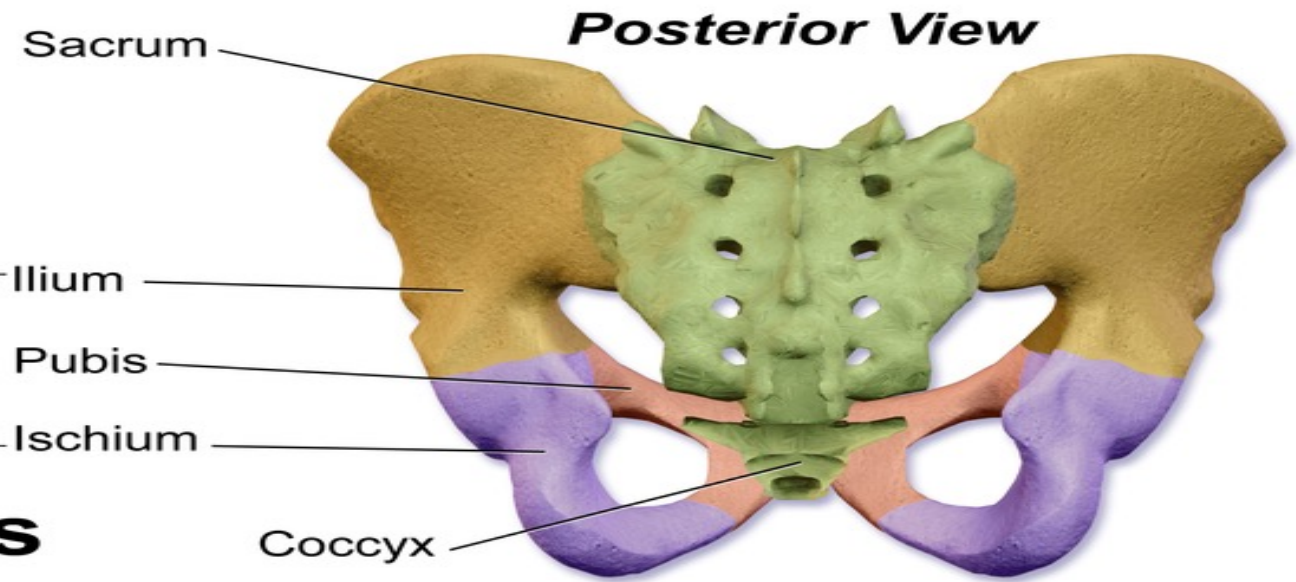
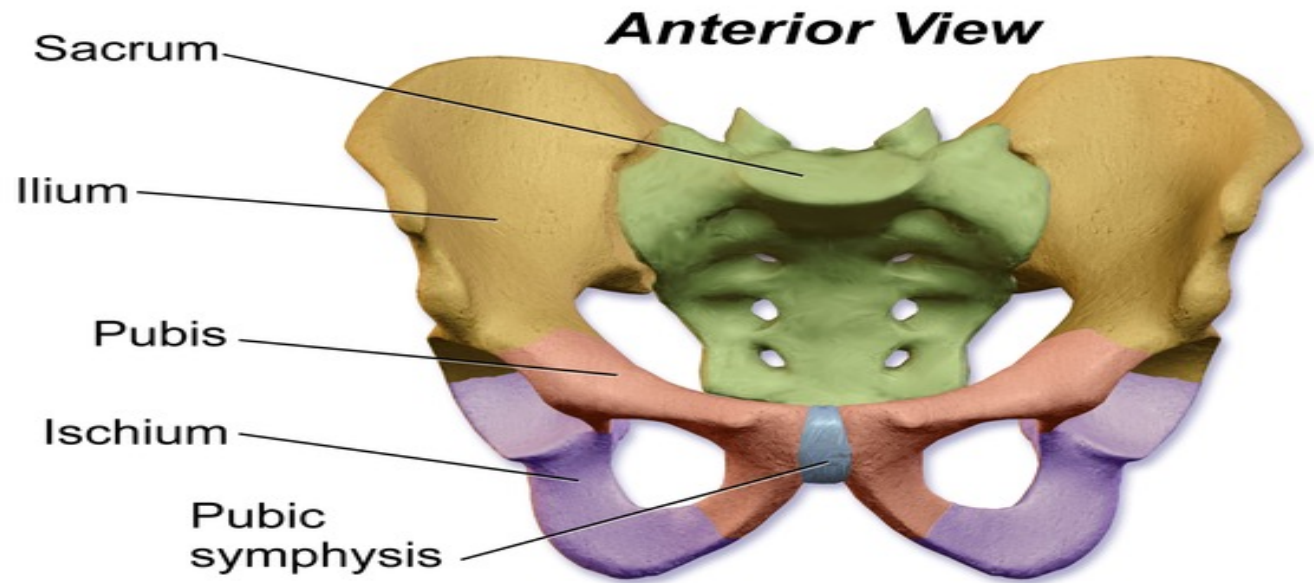
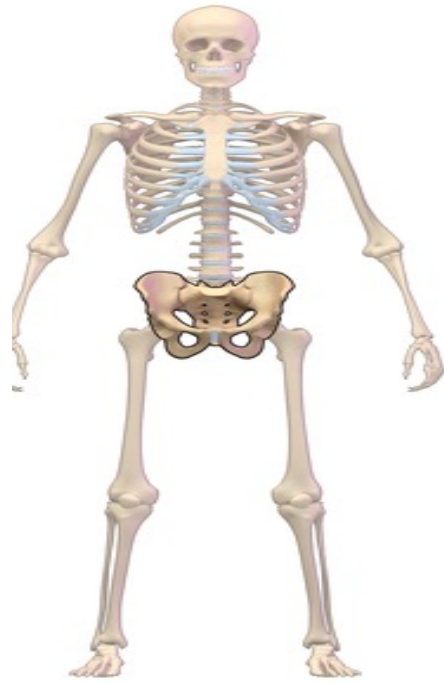They are united by 4 joints:

2 Sacro-iliac joints (plane synovial)

Symphysis pubis and sacrococcygal joints (cartilaginous joints).

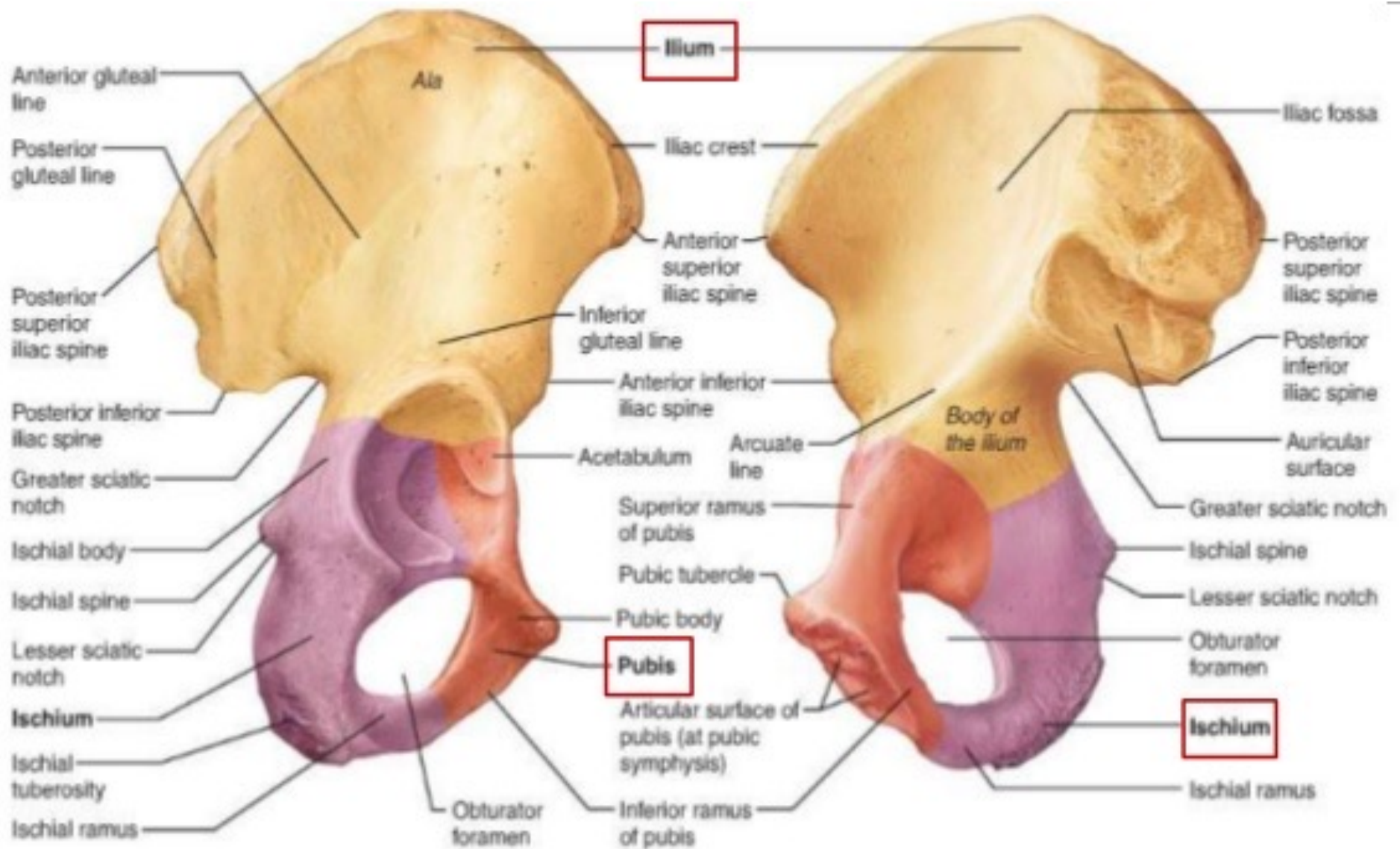
The pelvis is supported by 4 Ligament

Iliolumbar, lumbosacral, sacrotuberous, and sacrospinous ligaments .



- Hip bone
- Ilium
 - Pubis
 - Ischium

The Pelvis



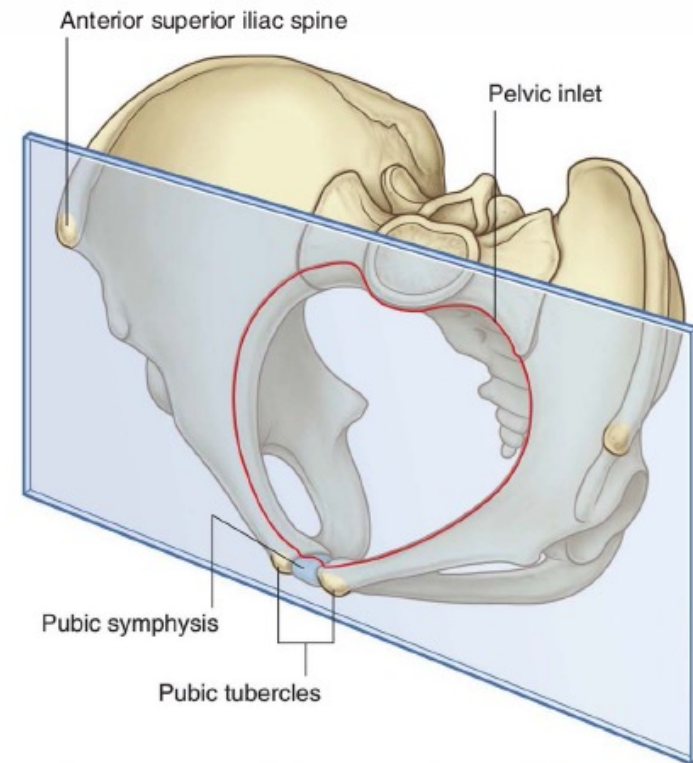
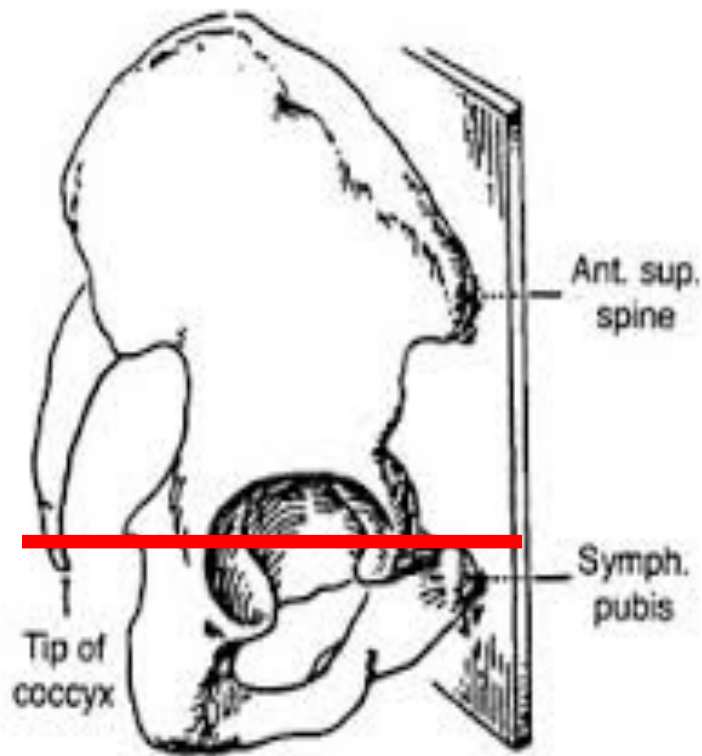
(a) Lateral view, right hip bone

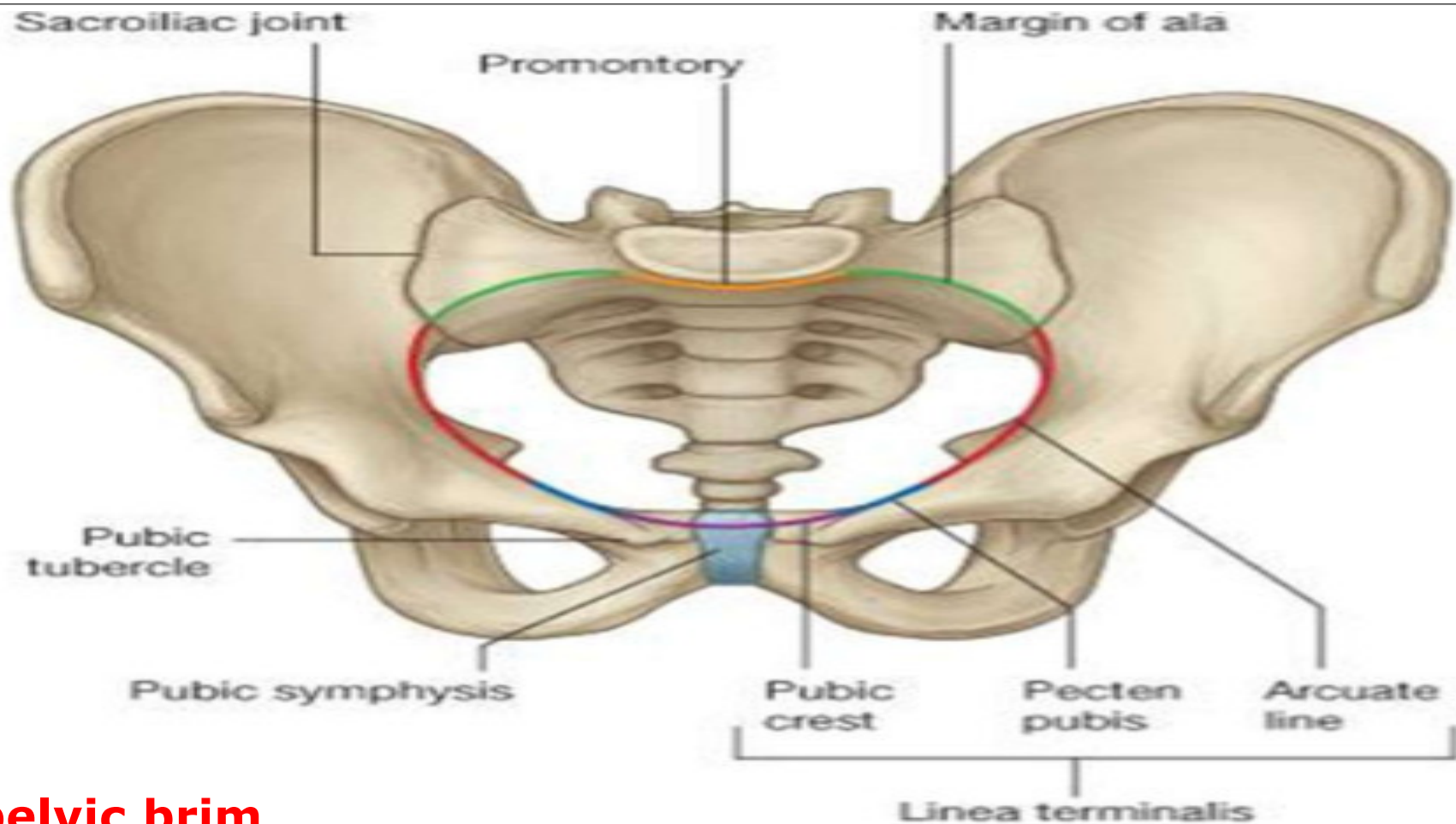
(b) Medial view, right hip bone

Normal position of the pelvis

In erect posture, the pelvis lies with the anterior superior iliac spine and pubic tubercles in the same vertical plane

The ischial spine and upper border of symphysis pubis in the same horizontal plan.





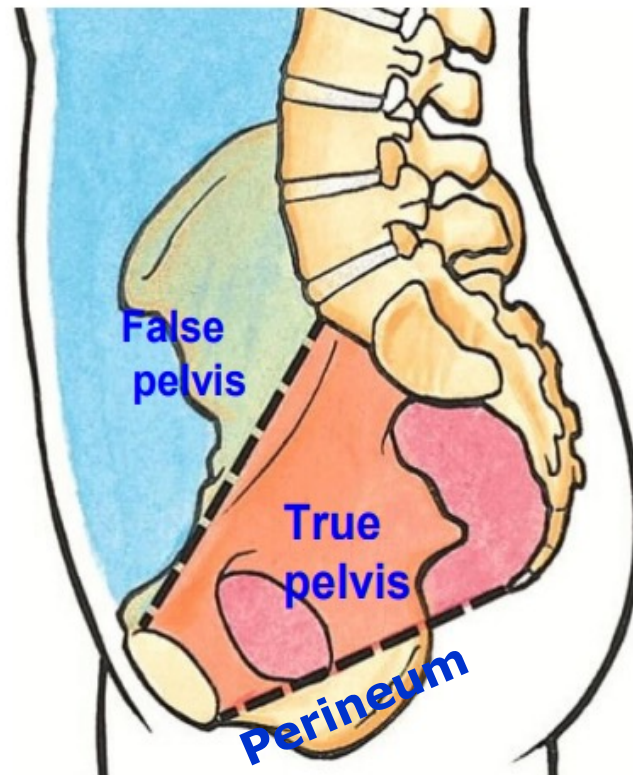
The pelvic brim

An oblique plane extends from the sacral promontory to the upper margin of symphysis pubis.

Pelvis

Greater Pelvis (False Pelvis)

Anterosuperior to pelvic brim
It is a part of the abdomen



Lesser Pelvis (True pelvis)

Posteriorinferior to pelvic brim
The term pelvis means the lesser pelvis

Pelvis
ABOVE By pelvic diaphragm

Perineum
BELOW By pelvic diaphragm

True Pelvis

```
graph TD; TP[True Pelvis] --- A[A-Inlet]; TP --- B[B- Outlet]; TP --- C[C- Cavity];
```

A-Inlet

B- Outlet

C- Cavity

A- Pelvic inlet (pelvic Brim):

□ Shape:

Male : Triangular or heart-shaped

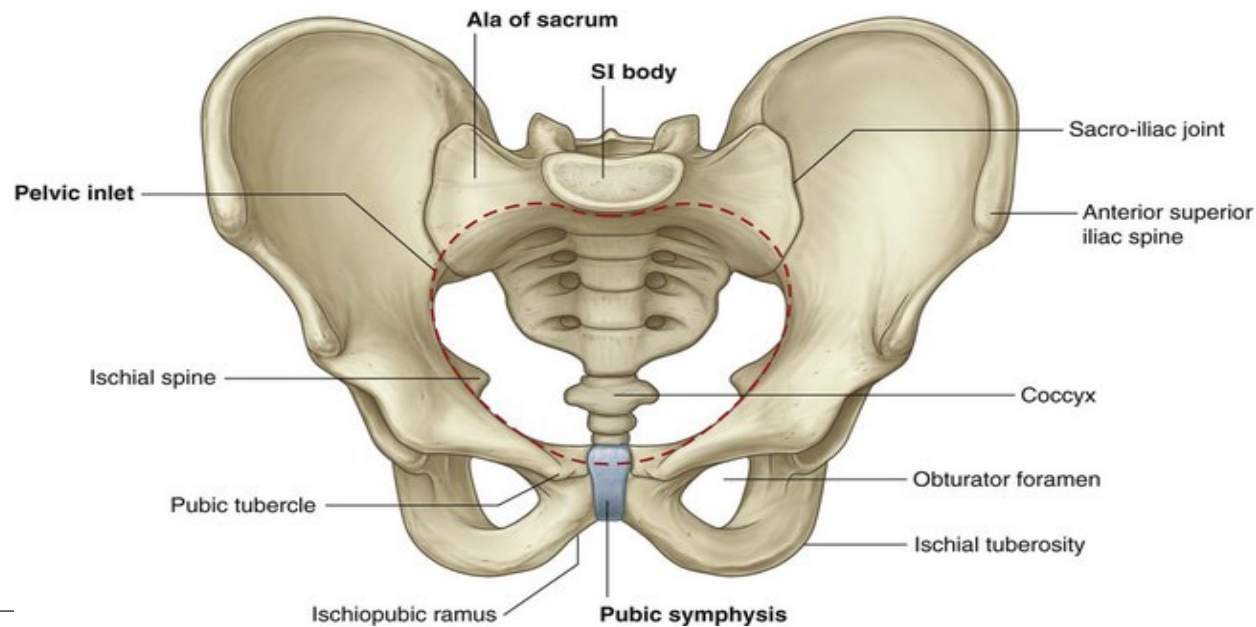
Females : Transversely oval

□ Formation:

Anteriorly : Symphysis pubis

Posteriorly : Sacral promontory

On either sides : Ala of sacrum , arcuate line, pectineal line, pubic crest



□ Diameters :

Anteroposterior diameter:

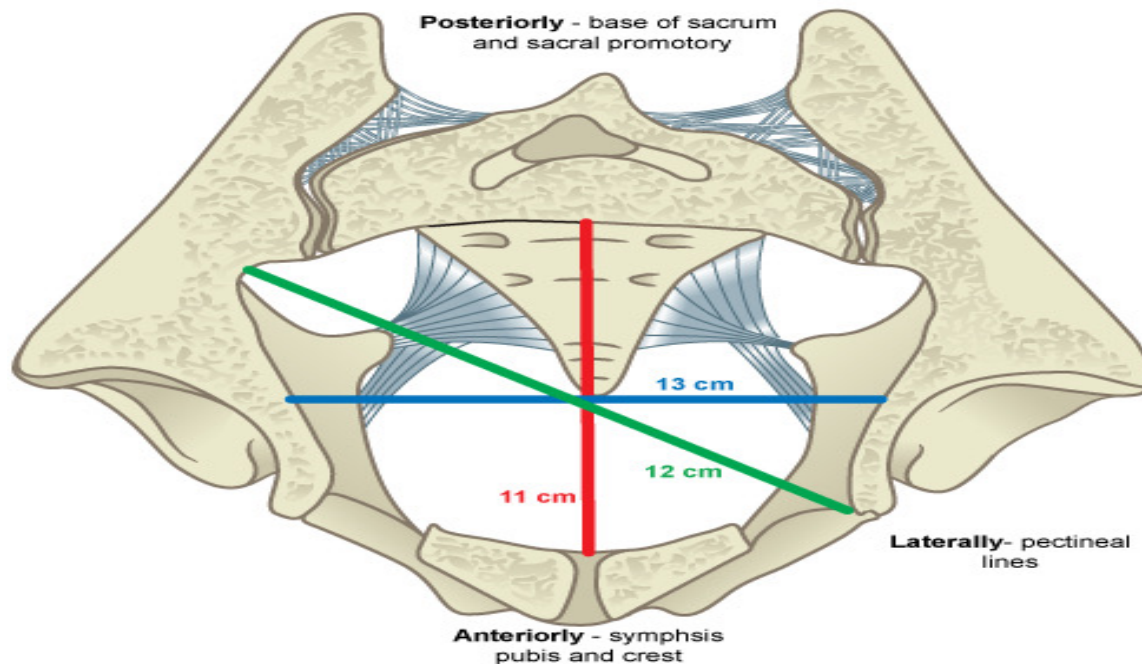
From sacral promontory to upper border of symphysis pubis (4 niches).

Oblique diameter:

From the sacro-iliac joint to the opposite iliopubic eminence (4.5 inches).

Transverse diameter:

Between the 2 arcuate lines (5 inches). **It is the widest diameter.**



B- Pelvic Outlet :

□ Formation:

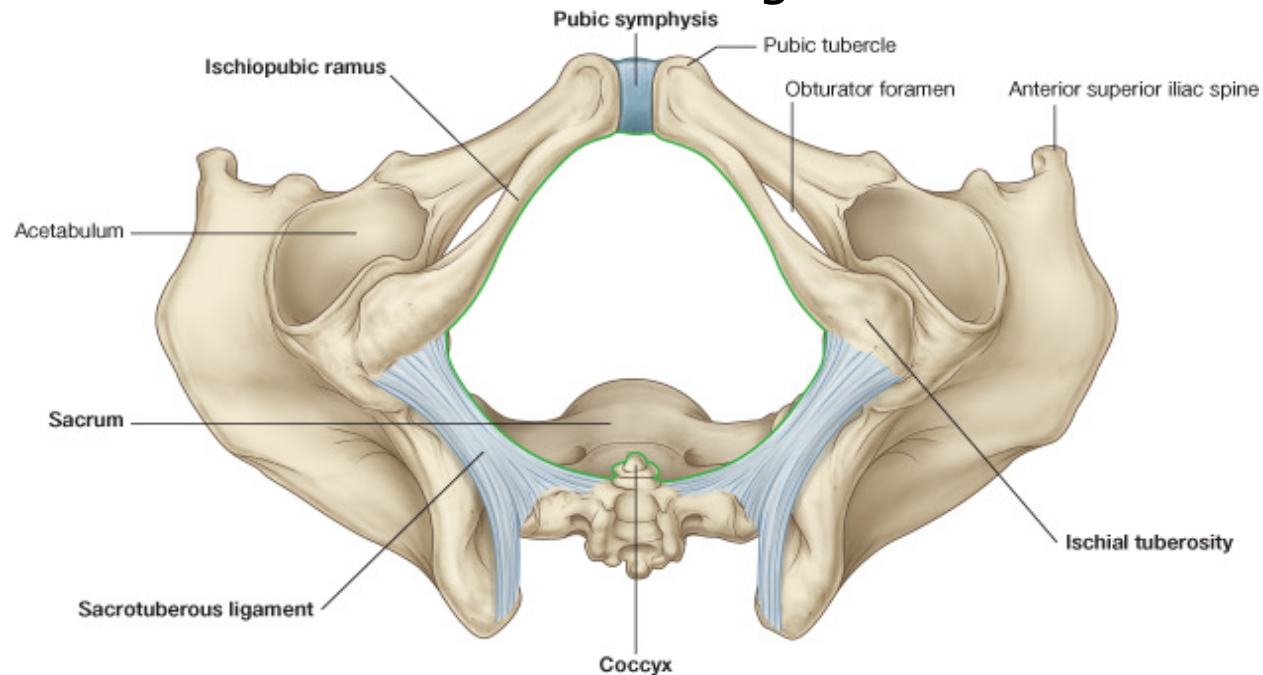
Anteriorly: Pubic Arch.

Posteriorly : Coccyx.

Lateral angles : Ischial tuberosities.

Anterolateral sides : Ischiopubic rami

Posterolateral sides : Sacrotuberous ligaments



□ Diameters :

Anteroposterior diameter:

Between the coccyx and lower border symphysis pubis (5 inches).

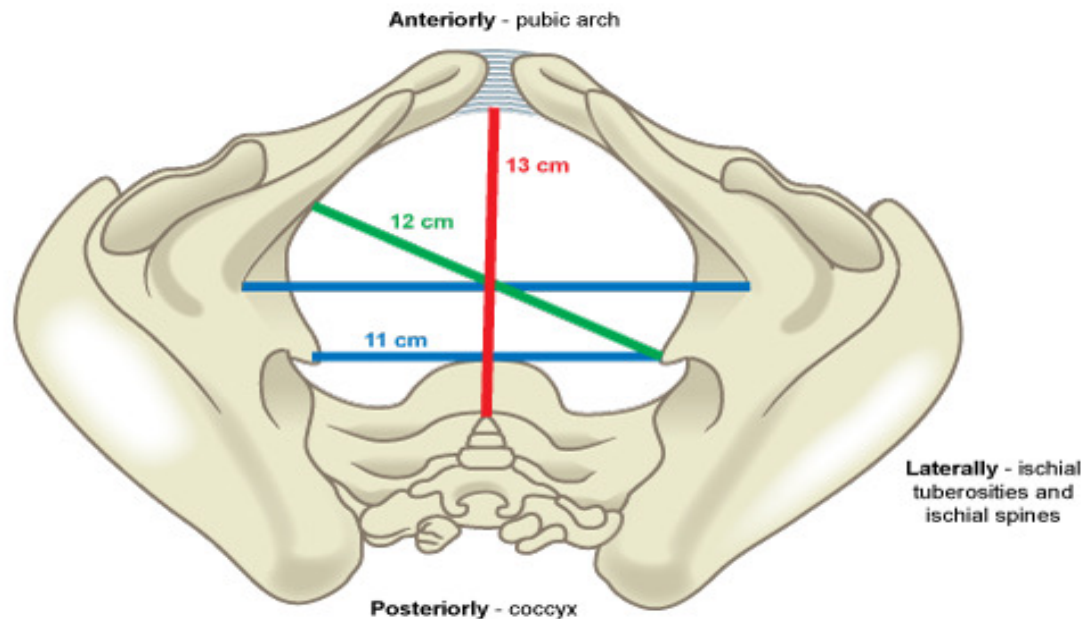
It is the **widest diameter** at the outlet.

Oblique diameter :

From the midpoint of the sacrotuberous ligament to junction of the pubic and ischial rami of the opposite side (4.5 inches).

Transverse diameter :

Between the 2 ischial tuberosities (4 inches).



C- Pelvic Cavity

Anterior wall :

Is short (2 inches) Formed by bodies of pubic bones and symphysis pubis.

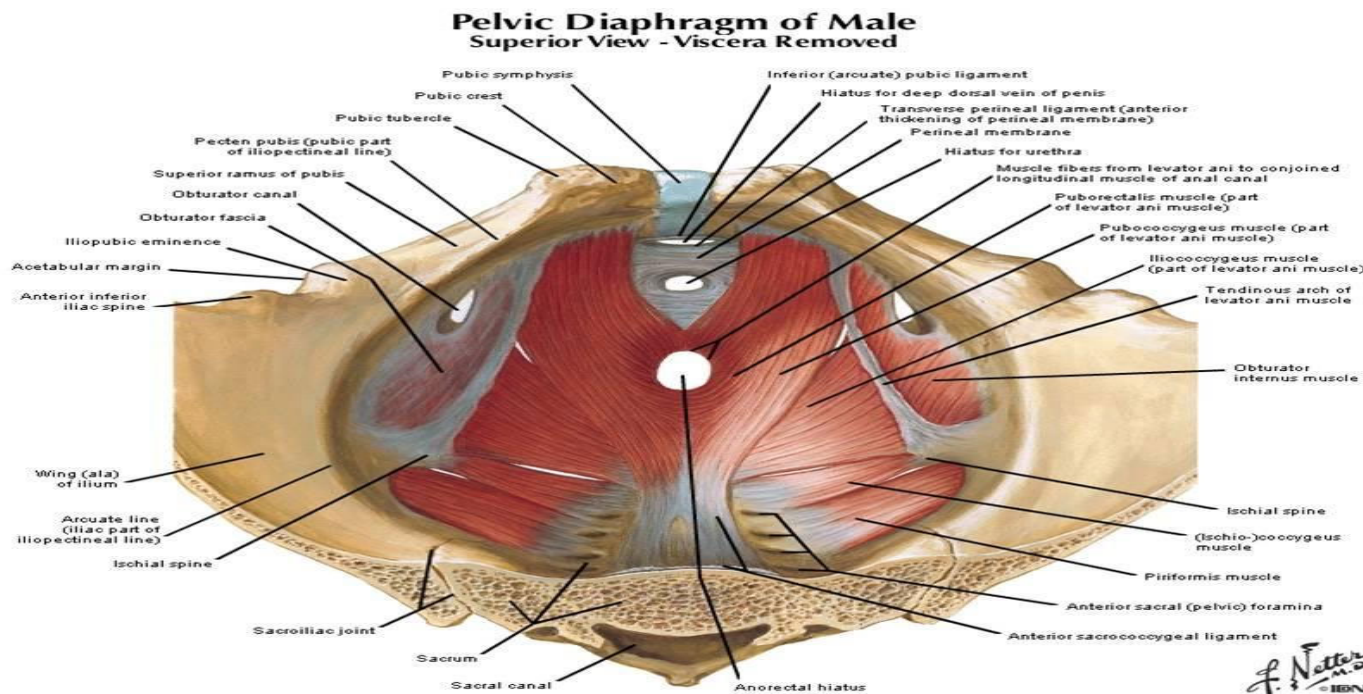
Posterior wall :

Is long (6 inches), Formed of the sacrum and coccyx

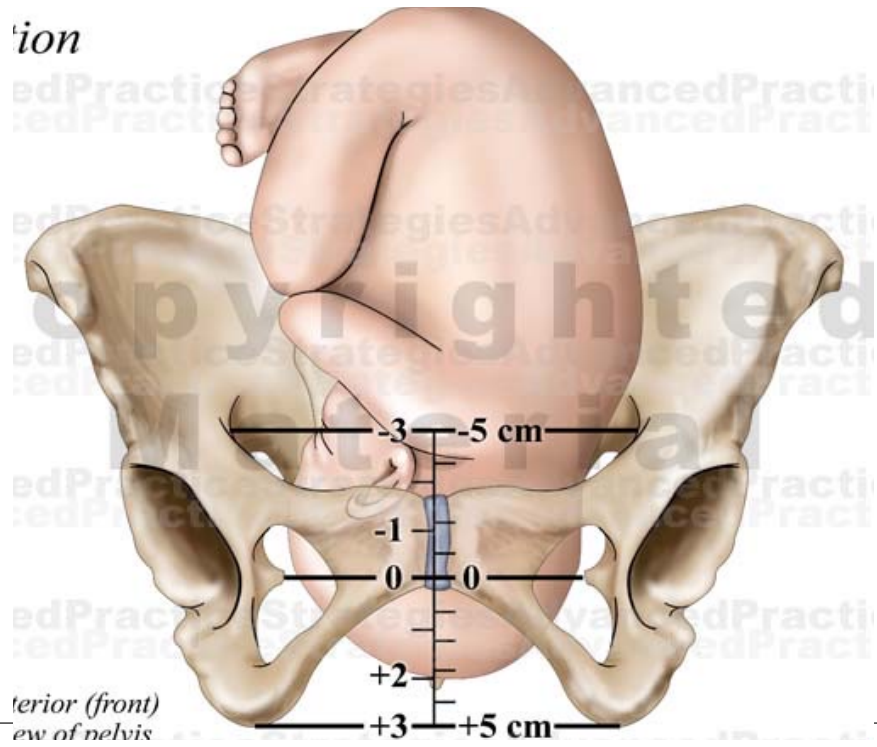
Lateral walls:

Pelvic surface of parts of pubis, ischium and ilium.

Subdivisions: By pelvic diaphragm (levator ani and coccygeus muscles), It divided into pelvis above and perineum below.



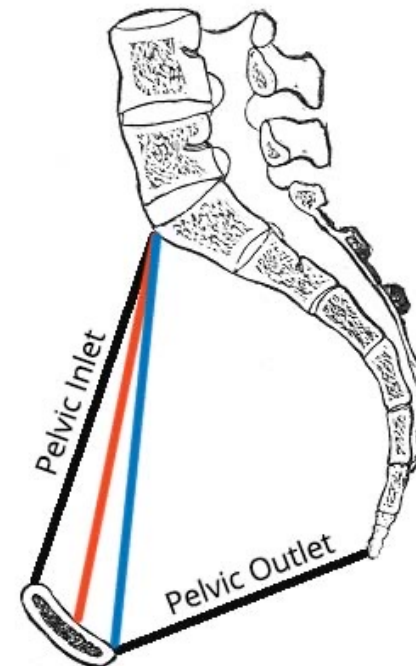
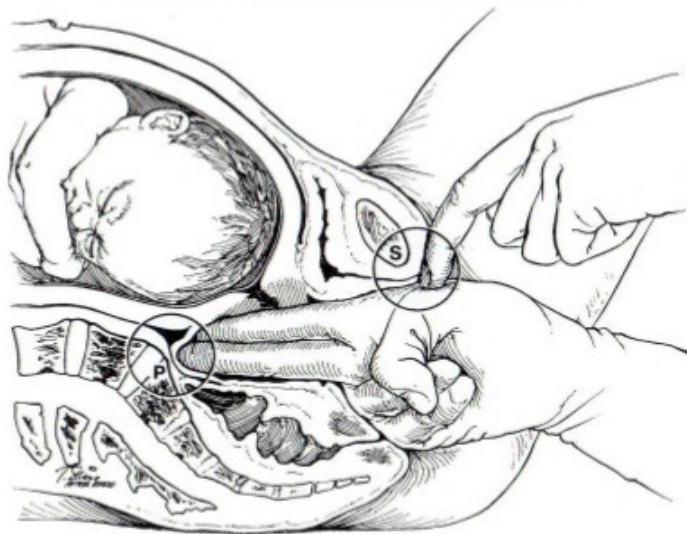
	Anteroposterior diameter	Oblique diameter	Transverse diameter
Inlet	4	4 1/2	5
Mid-cavity	4 1/2	4 1/2	4 1/2
Outlet	5	4 1/2	4



Diagonal conjugate : It is the distance between promontory of sacrum and the lower border of the symphysis pubis. Shorter diagonal conjugate indicates contracted pelvis.

Obstetric conjugate: between promontory of sacrum and most bulging point on the back of symphysis pubis. It is less than Diagonal conjugate by 1.5 to 2 cm

Vaginal Examination to Determine Diagonal Conjugate



- Obstetric Conjugate
- Diagonal Conjugate

Obstetric Conjugate = Subtracts 1.5 – 2.0 cm from Diagonal Conjugate

In the clinic

Pelvic measurements in obstetrics

Transverse and sagittal measurements of a woman's pelvic inlet and outlet can help in predicting the likelihood of a successful vaginal delivery. These measurements include:

- the sagittal inlet (between the promontory and the top of the pubic symphysis),
- the maximum transverse diameter of the inlet,
- the bispinous outlet (the distance between ischial spines), and
- the sagittal outlet (the distance between the tip of the coccyx and the inferior margin of the pubic symphysis).

These measurements can be obtained using magnetic resonance imaging, which carries no radiation risk for the fetus or mother (Fig. 5.33).

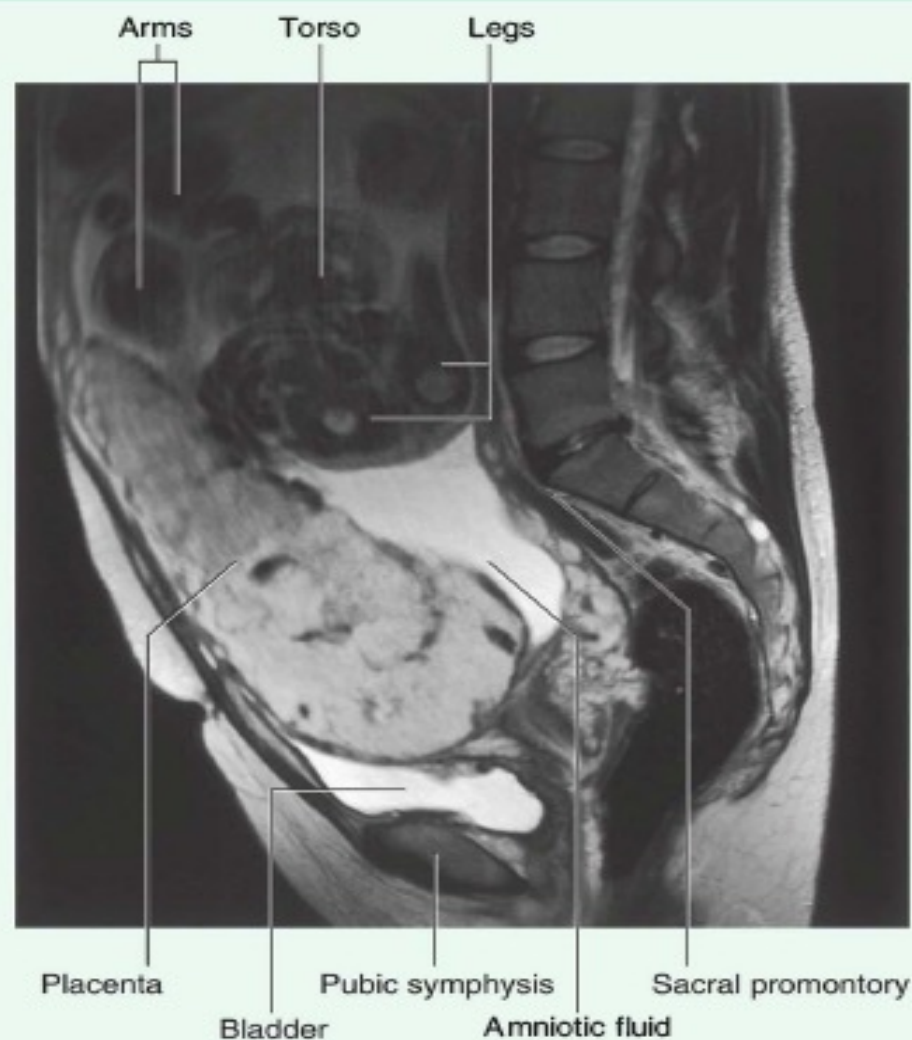
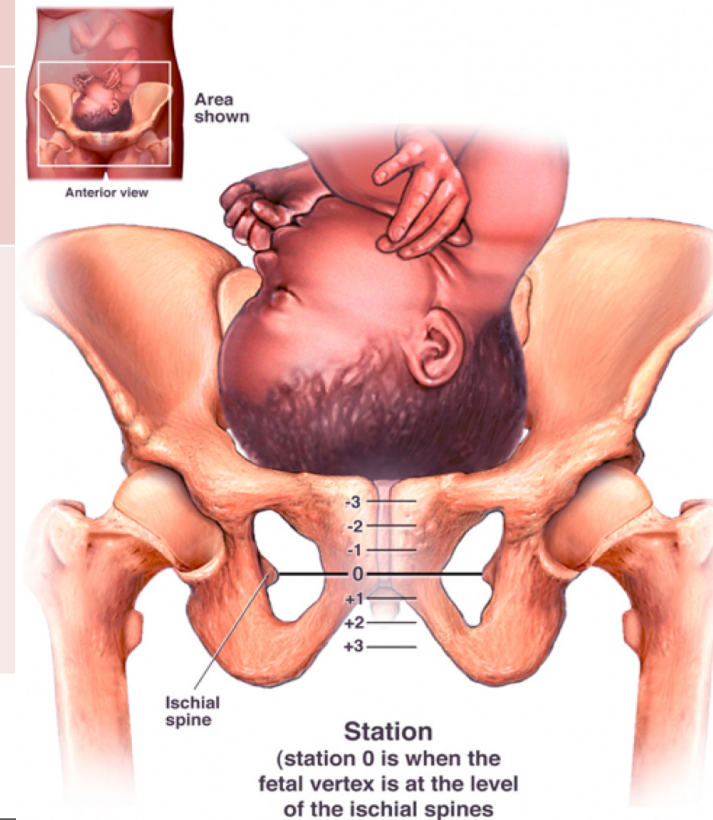


Fig. 5.33 Sagittal T2-weighted magnetic resonance image of the lower abdomen and pelvis of a pregnant woman.

Fetal head stations

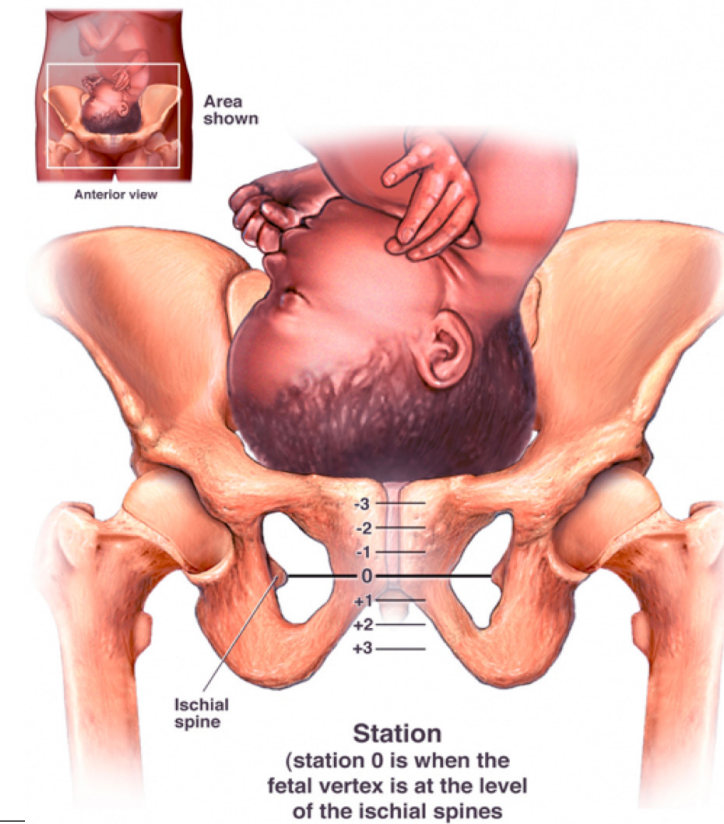
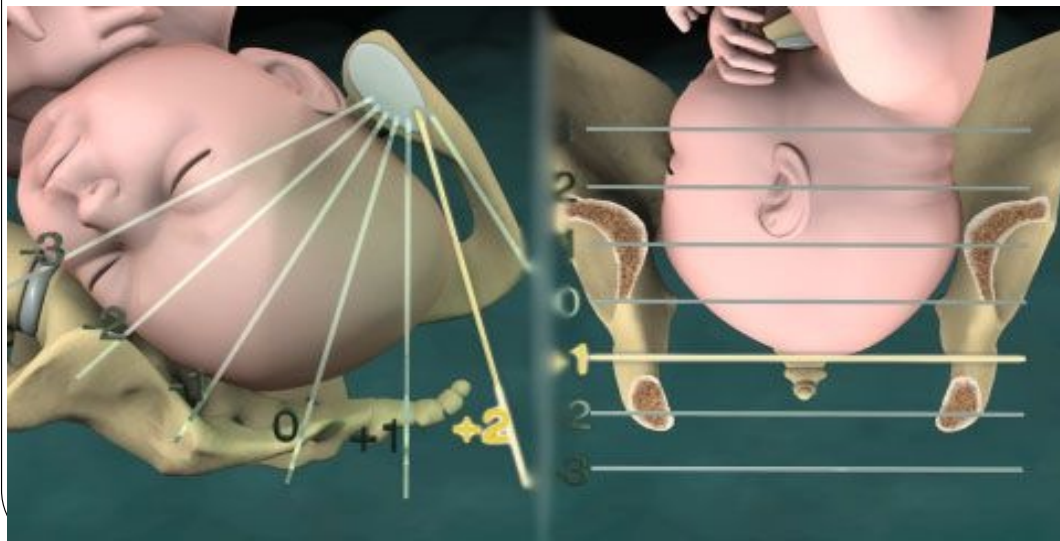
	Head position	Bony landmark
-2	Fixed to pelvic inlet	Above ischial spines
-1	Small segment of fetal head in pelvic inlet	
0	Large segment of fetal head in pelvic inlet	At ischial spines
+1	Fetal head in plane of greatest dimension	Below ischial spines (head visible at the introitus).
+2	Fetal head in plane of least dimension	
+3	Fetal head in the pelvic outlet	

**Read Only
See next slide**



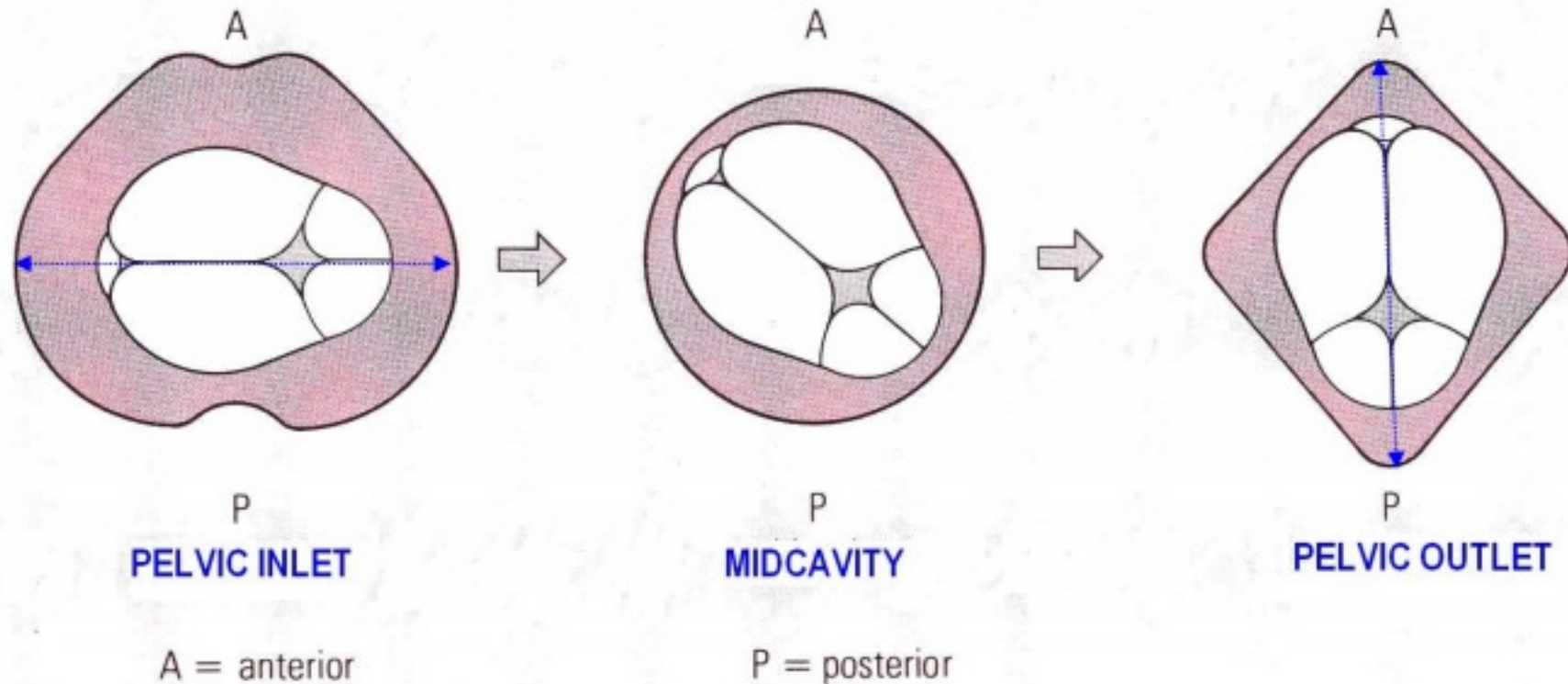
Fetal head stations

	Bony landmark
-2	Above ischial spines
-1	
0	At ischial spines
+1	Below ischial spines (head visible at the introitus).
+2	
+3	



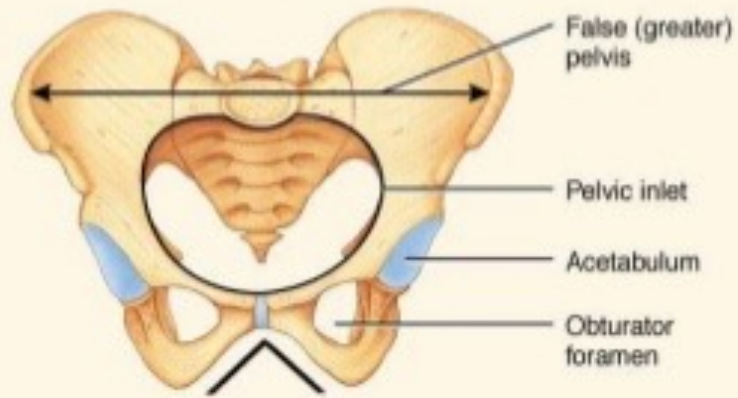
Rotation of head during labour

- Widest diameter of pelvic canal changes from **transverse diameter** at **pelvic inlet** to **Anterior posterior** diameter at **pelvic outlet**
- To obtain best fit of fetal head, the longest diameter of the fetal head passes through the widest diameter of the pelvis.
- Therefore the head must rotate during labour

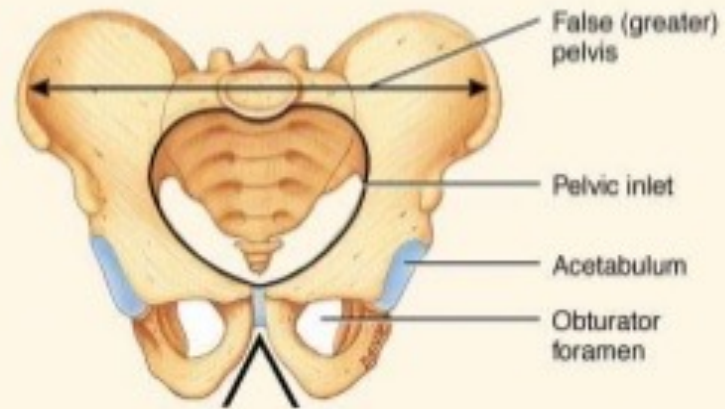


Sex Differentiation in the Pelvis

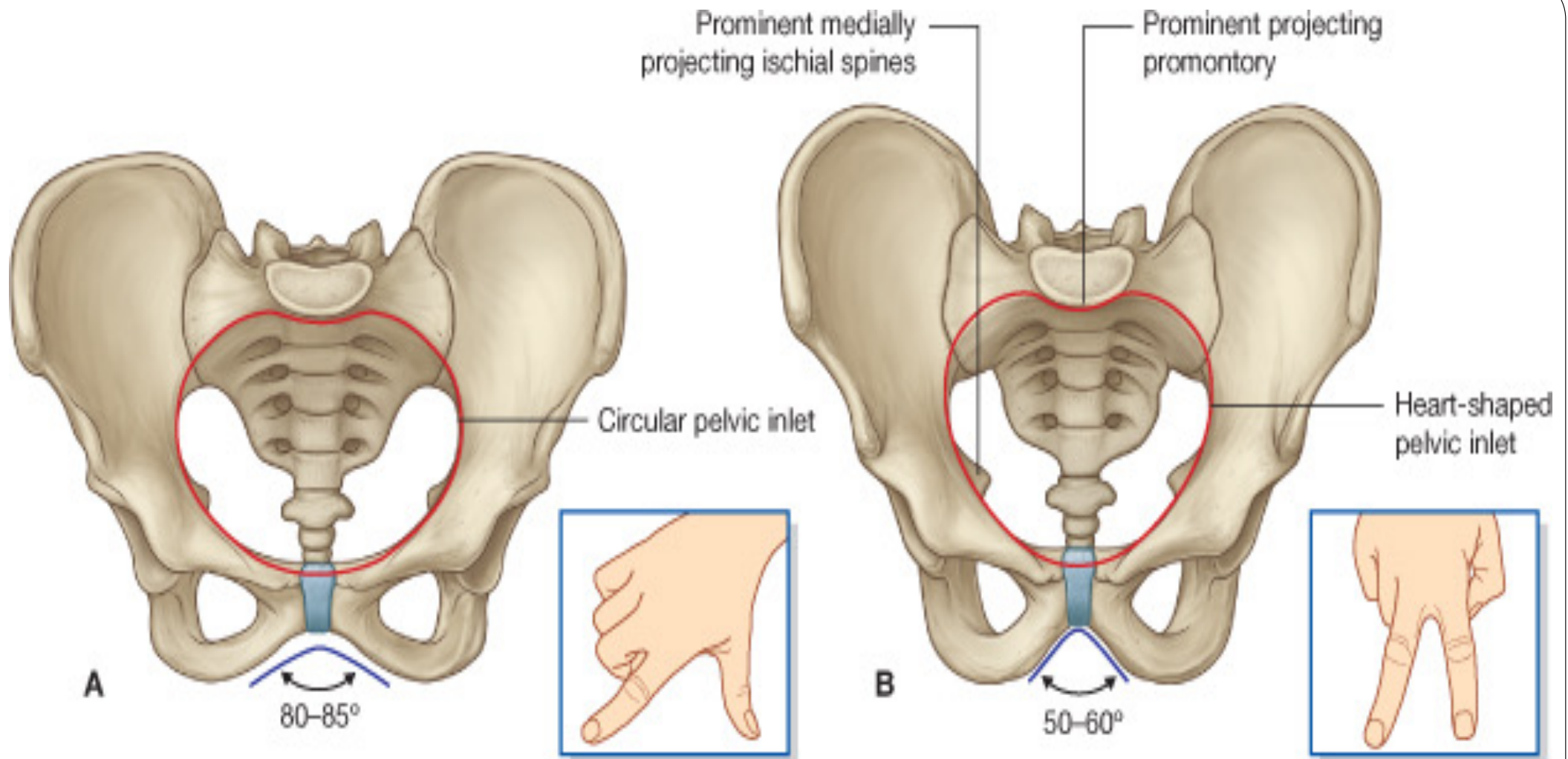
		Female	Male
1	Inlet		
2	Cavity		
3	Outlet		
4	Subpubic angle		
5	Ischial tuberosities		
6	Sacrum		
7	Side of pubic arch		



Pubic arch (wider)



Pubic arch (narrower)



Types of Female pelvis

Gynaecoid pelvis:

it is the typical female pelvis previously described.

Android pelvis:

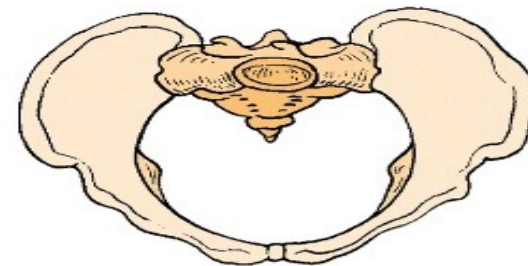
it is the female pelvis with some male features.

Anthropoid pelvis:

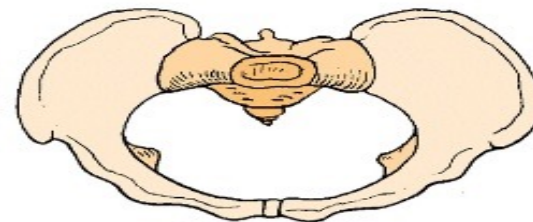
it simulates the pelvis of apes. It has **Small transverse diameter** and long anteroposterior diameter.

Platypelloid pelvis:

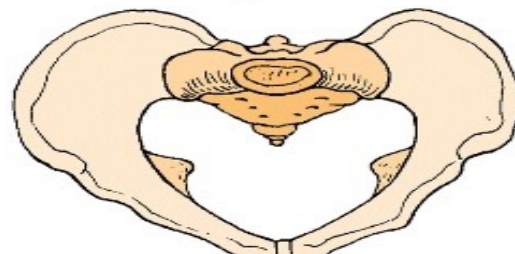
it is a flat pelvis in which the inlet has **Larger transverse diameter** much than the anteroposterior diameter.



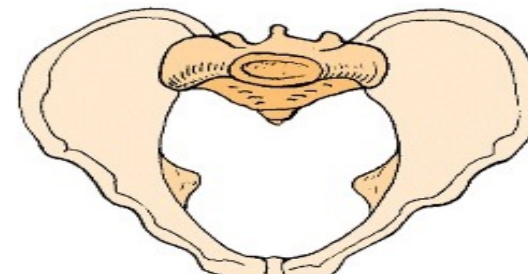
Gynecoid



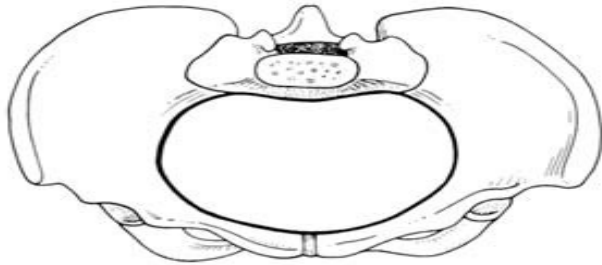Platypelloid



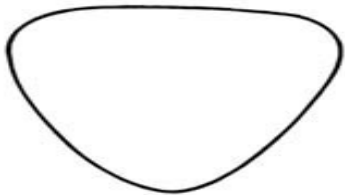
Android



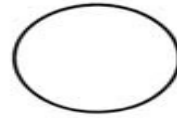
Anthropoid



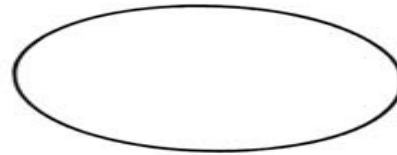
(a) Gynaecoid




(c) Android



(b) Generally contracted



(d) Platypelloid



(f) Anthropoid

Gynaecoid pelvis:

Normal

Android pelvis:

Like Male

Anthropoid pelvis:

Like apes. Small transverse diameter

Platypelloid pelvis:

It is a flat pelvis Larger transverse diameter

Fracture Pelvis

If the pelvis breaks at any one point, the fracture will be stable and no displacement will occur.

If two breaks occur in the pelvis the fracture will be unstable and displacement will occur

Coccydynia : is common and is usually caused by direct trauma to the coccyx, as in falling down a flight of concrete steps.

Complications of Pelvic Fractures

- Injury to Male urethra and urinary bladder
- Rectum rarely damaged
- Bleeding from blood vessels injury
- Injury to nerves especially sciatic nerve in fracture include greater sciatic notch



2-Joints and ligaments Of The Pelvis

1) Pubic Symphysis:

It is a secondary cartilaginous joint between the two pubic bones.

READ ONLY

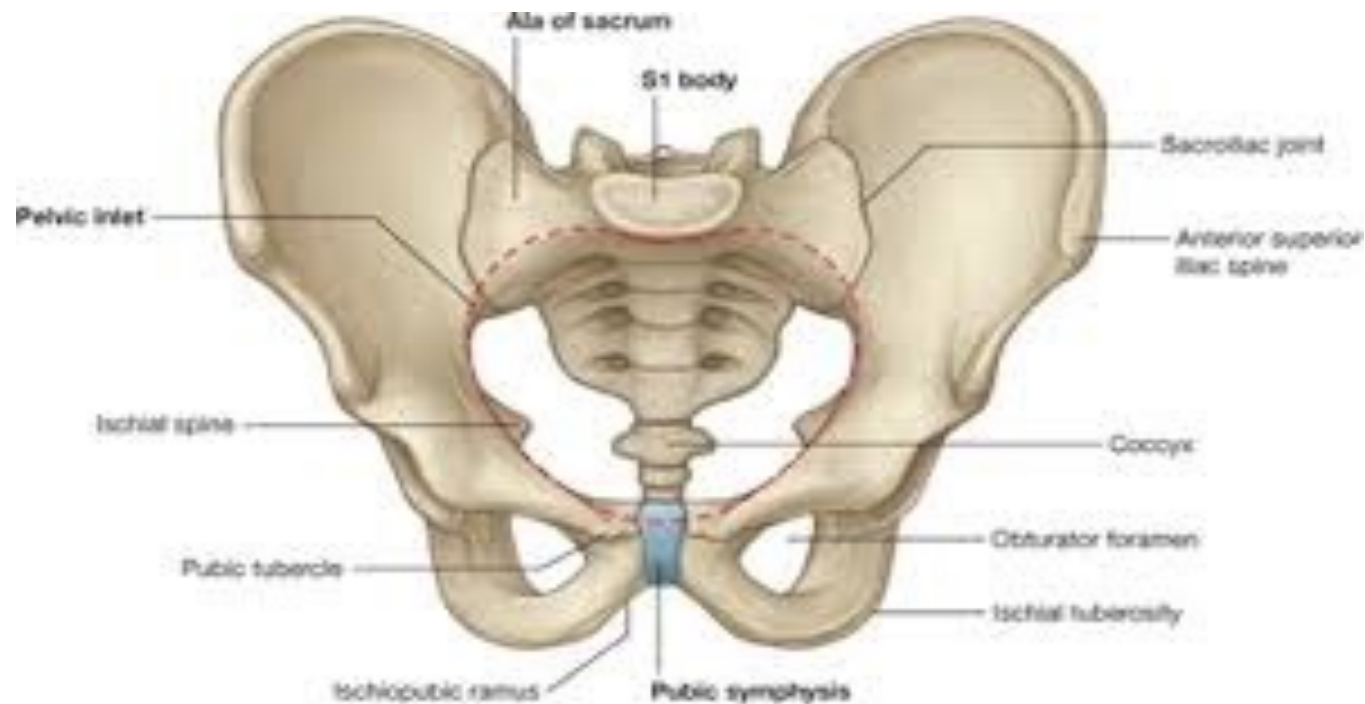
Ligament:

Superiorly : Superior pubic ligament

Inferiorly : The arcuate pubic ligament.

2) Sacrococcygeal Joint:

Type: it is a secondary cartilaginous joint between sacral apex and coccygeal base.



3) Sacroiliac Joint :

READ ONLY

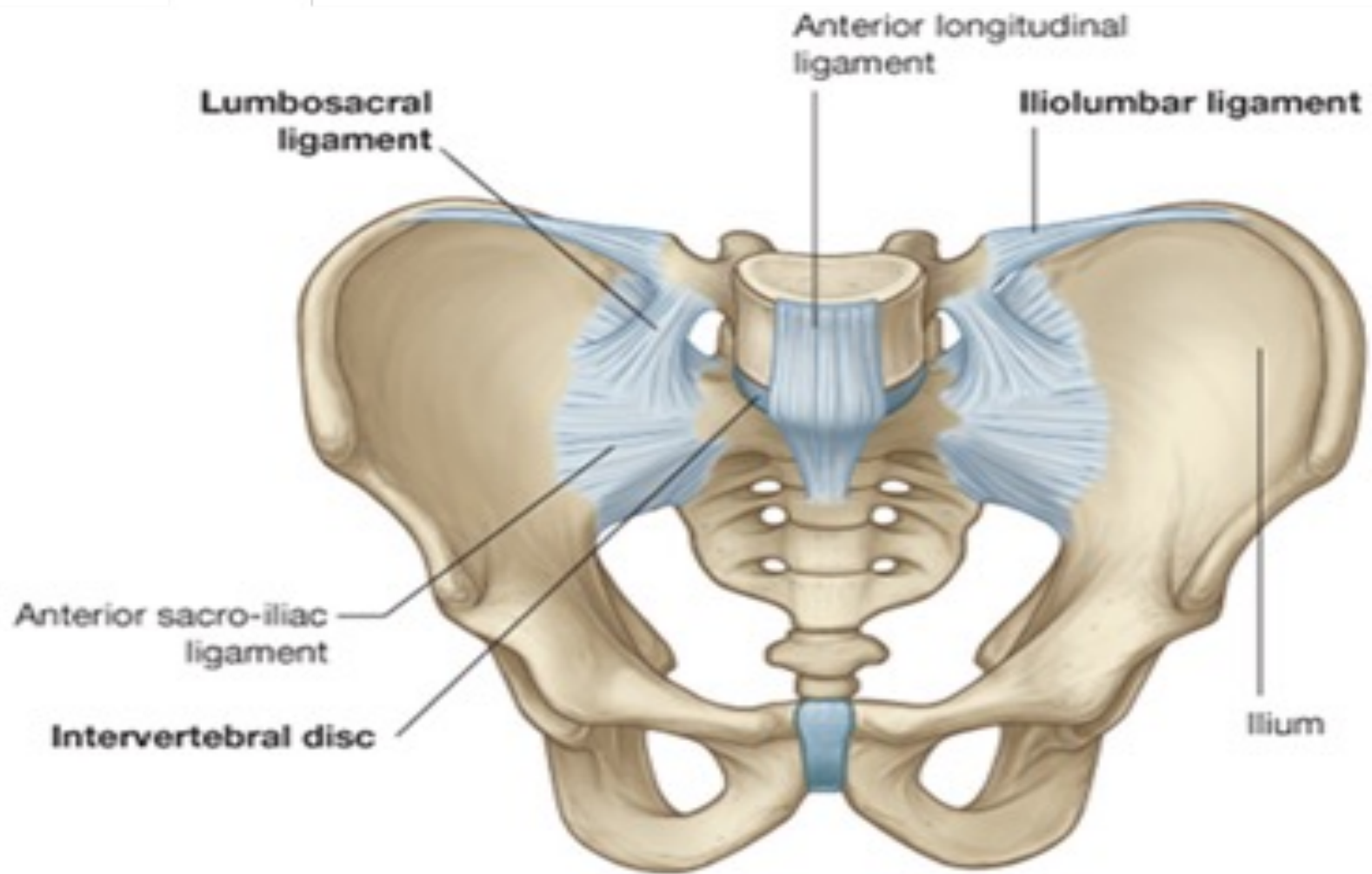
Type: plane synovial joint between sacral and iliac auricular surfaces.

Ligaments :

- The ventral sacroiliac ligament : it lies anteroinferior to the joint
- The interosseous sacroiliac ligaments : (the strongest ligament), lies posterior to the joint.
- The dorsal sacroiliac ligament: lies dorsal to the interosseous ligament.

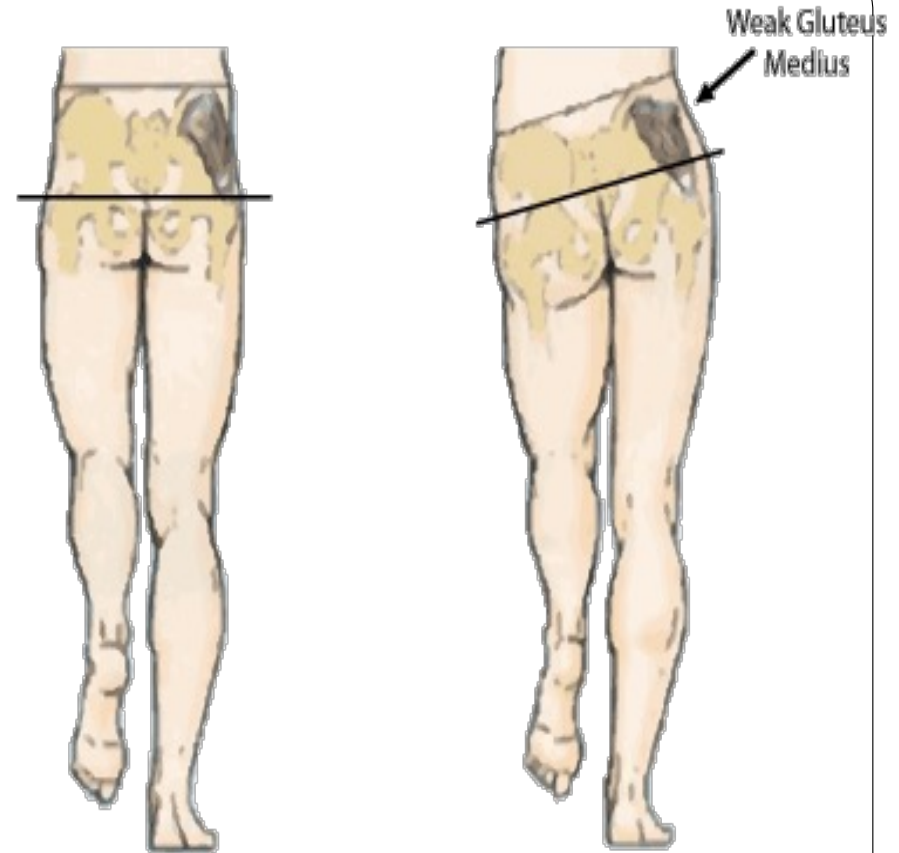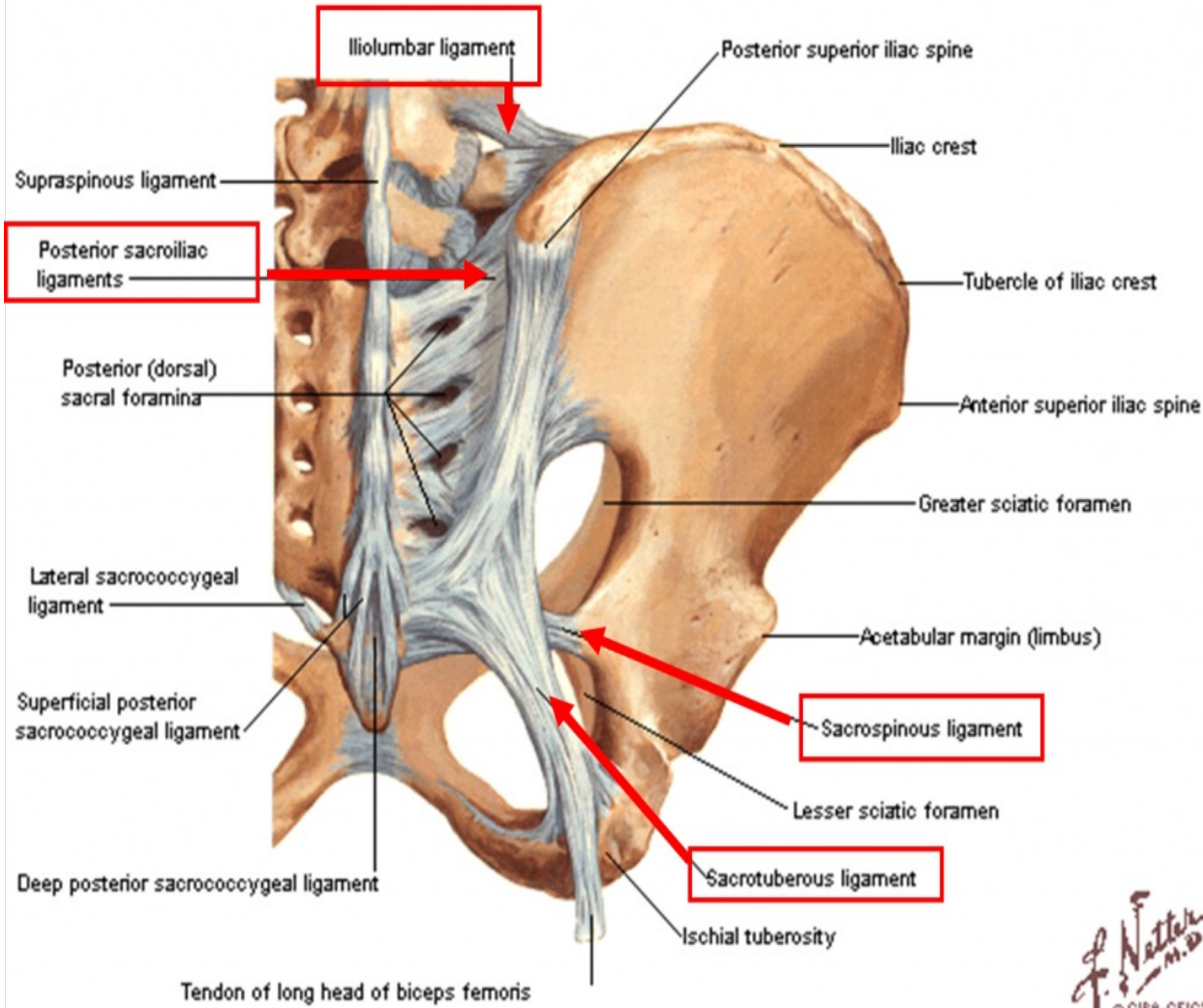
Movements and Functions:

- ✓ It transmits the body weight from lumbar spine to the hip bones.
- ✓ It allows slight rotation around a horizontal axis when the trunk is flexed on the hip joints.



Bones and Ligaments of Pelvis

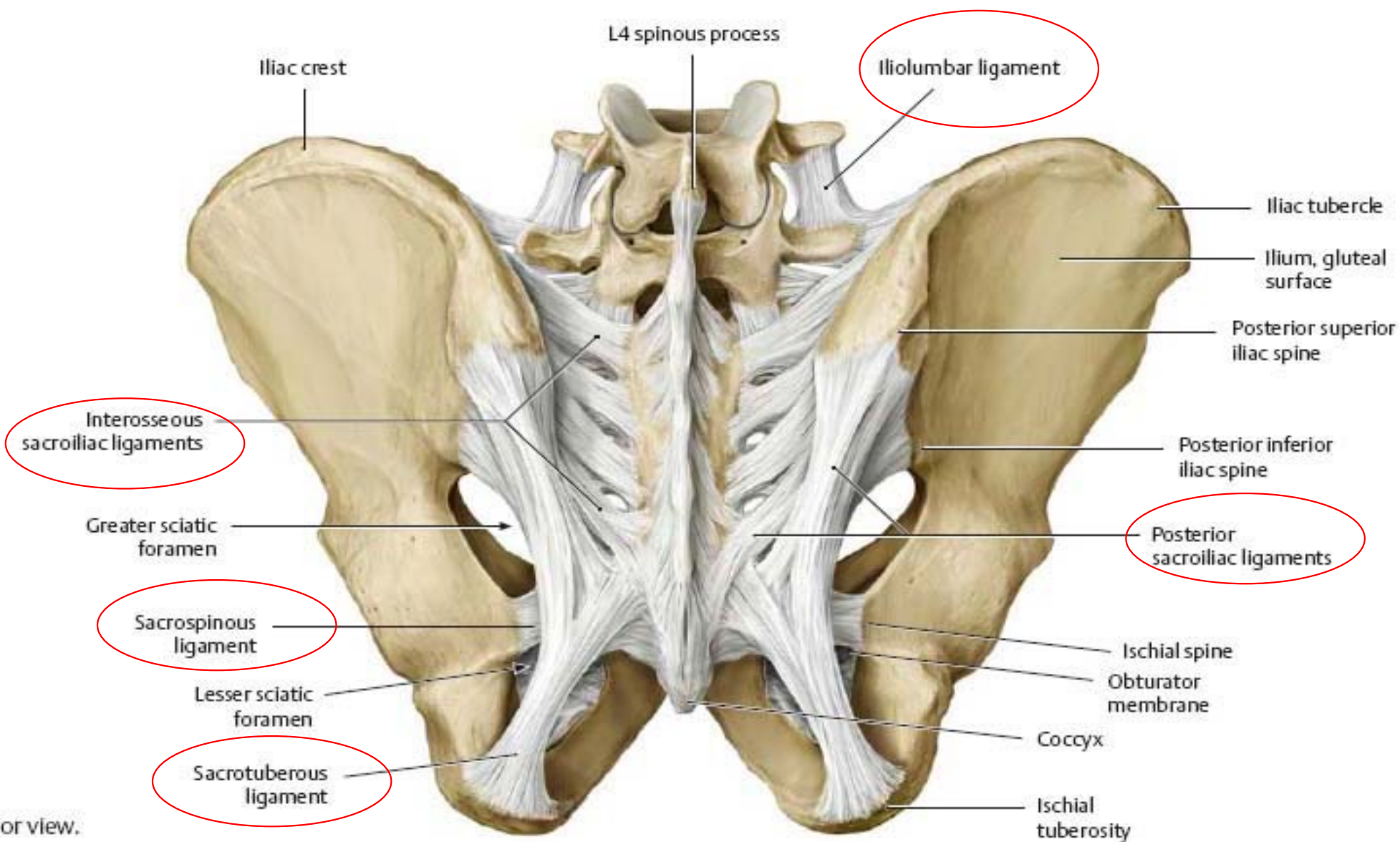
Posterior View



Normal

Trendelenburg Sign
Drop of pelvis when lifting leg opposite to weak gluteus medius

F. Natter
M.D.
© CIBA-GEIGY



B Posterior view.

Vertebropelvic ligaments:

1) Iliolumbar ligament : extends from the tip of the [L5 transverse process](#) to iliac crest.

2) Lumbosacral ligament : extends from the inferior aspect of [L5 transverse process](#) to the lateral part of the ala of sacrum.

3) Sacrotuberous ligament ;

It extends between lower part of the sacrum and coccyx and ischial tuberosity.

4) Sacrospinous ligament: Extends from ischial spine to the lateral margins of sacrum and coccyx.

KNOW THE FUNCTIONS ONLY

Functions of the Vertebropelvic Ligaments:

- ❖ The **iliolumbar and lumbosacral ligaments** prevent the anteroinferior displacement of L5 vertebra under effect of body weight.
- ❖ The **sacrotuberous and sacrospinous ligaments** convert the greater and lesser sciatic notches into foramina.

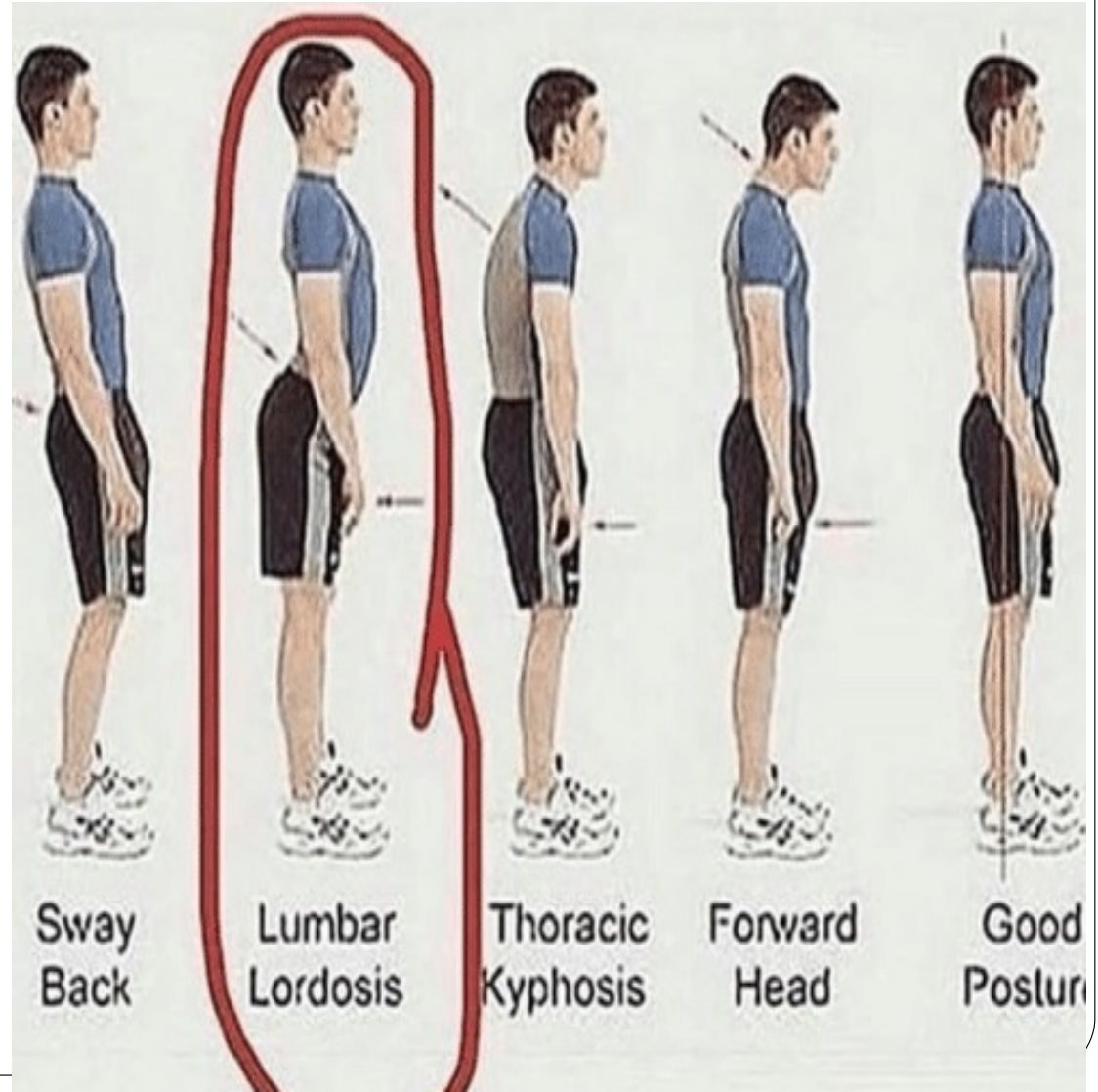
They also prevent the upward tilting of the lower part of sacrum under effect of body weight

Relaxation of Pelvic Ligaments and Increased Joint Mobility in Late Pregnancy

- Increased levels of sex hormones and the presence of the hormone relaxin cause the pelvic ligaments to relax during the last half of pregnancy.
- This allowing increased movement at the pelvic joints.
- Relaxation of the sacro-iliac joints and pubic symphysis permits as much as a 10–15% increase in diameters (mostly transverse, including the interspinous distance)
- The coccyx is also able to move posteriorly.
- This is facilitating passage of the fetus through the pelvic canal.

("swayback") posture

- ❖ Relaxation of sacro-iliac ligaments permitting greater rotation of the pelvis and contributing to this posture



3- Muscles Of the Pelvis

Muscles Of Pelvis

```
graph TD; A[Muscles Of Pelvis] --> B[Two Muscles in the pelvic wall]; A --> C[Two Muscles in the pelvic floor]; B --> B1[1-Piriformis]; B --> B2[2-Obturator internus]; C --> C1[1-Levator ani]; C --> C2[2-Coccygeus];
```

Two Muscles in the pelvic wall

1-Piriformis

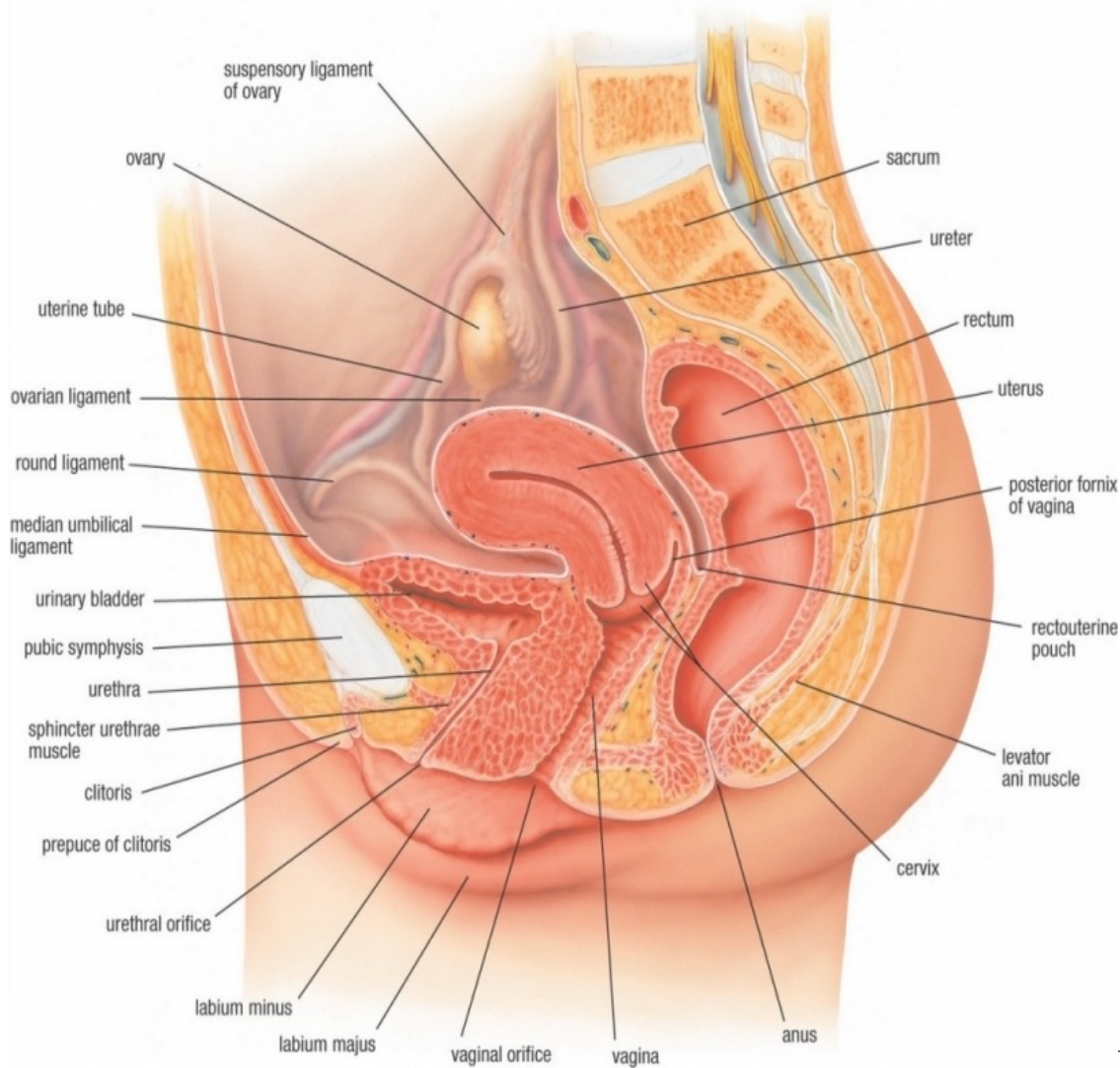
2-Obturator internus

Two Muscles in the pelvic floor

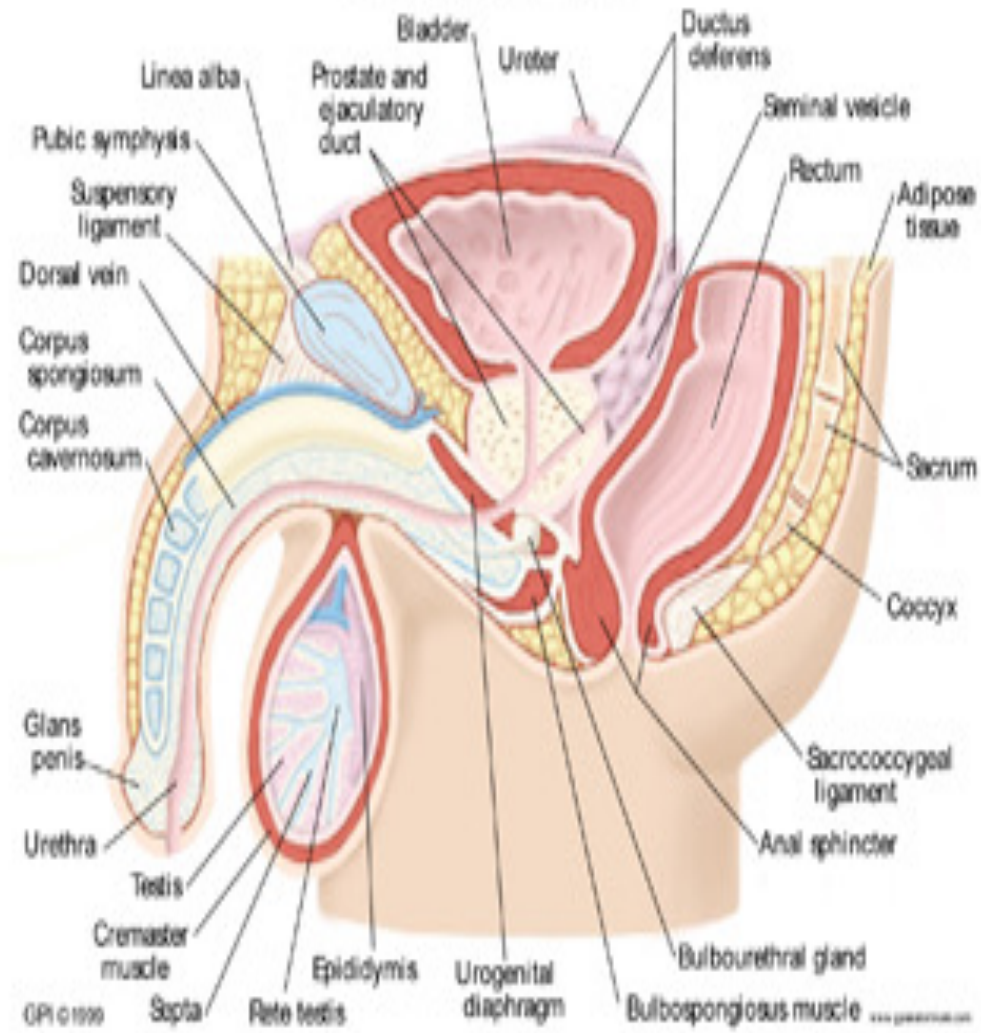
1-Levator ani

2-Coccygeus

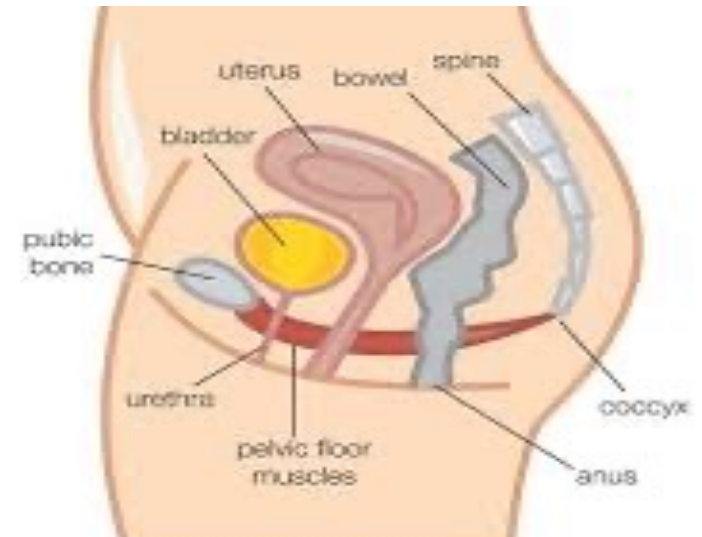
FEMALE UROGENITAL SYSTEM (MIDSAGITTAL VIEW)



MALE PELVIS



- Levator ani and coccygeus (of both sides) form the pelvic diaphragm which forms the pelvic floor
- The part of the pelvis **above** levator ani is the **pelvic cavity**.
- The part of the pelvis **below** levator ani is the **perineum**.
- The part of **obturator internus** **above** origin of levator ani is in the side wall of the pelvic cavity.
- The part of **obturator internus** **below** origin of levator is in the side wall of ischiorectal fossa of the perineum.
- Anterior borders of the 2 Levator ani muscles are separated by a gap which is filled by puboprostatic ligaments (in male) or pubovesical ligaments (in female).

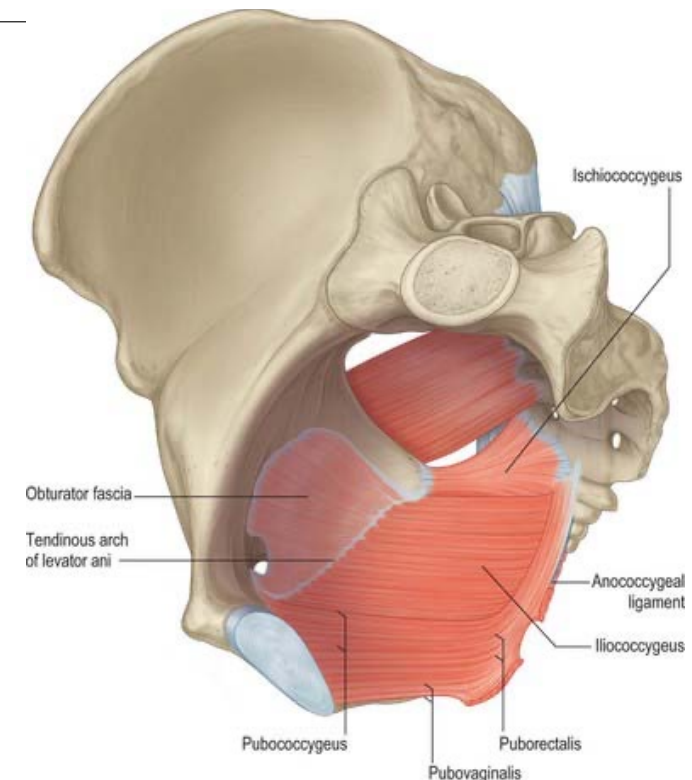


Pelvic Fascia

Piriformis fascia: is a part of parietal pelvic fascia
Anteriorly related to it internal iliac vessels
Posteriorly related to it sacral nerves

Obturator fascia

- ❑ It covers the pelvic surface of obturator internus.
- ❑ It fuses with the periosteum at the margins of the muscle except at **obturator groove** where it passes below obturator nerves and vessels.
- ❑ Between the lower border of pubic body and ischial spine, the fascia thickens to form tendinous arch (**white line**) which gives origin for levator ani muscle.
- ❑ Below level of levator ani, the fascia lies in the lateral wall of ischiorectal and form the **pudendal canal** around the internal pudendal A. and pudendal N.



Levator ani

Origin :

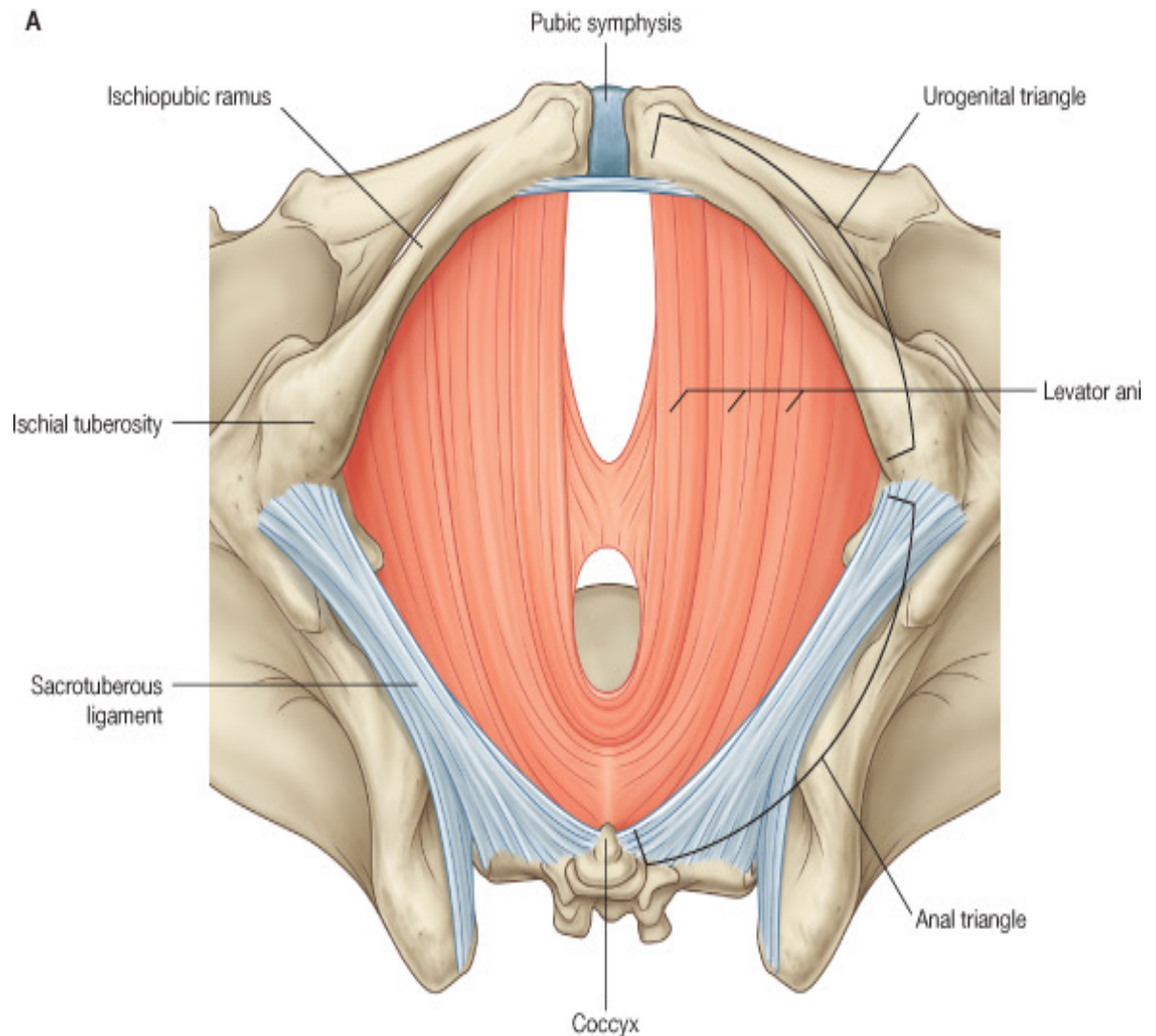
- Lower part of back Body of pubis
- White line of Obturator fascia
- Pelvis surface of Ischial spine

Nerve Supply :

- On its pelvic surface :
fourth sacral N. (sacral plexus)
- On its perineal surface :
perineal branch (of pudendal N.)

Action :

- 1-Supports and maintains the pelvic viscera in position.
- 2-It resist the rise in intra pelvic pressure during the straining
- 3-Sphincter action on the anorectal junction, and vagina.



Levator Ani Muscle

Pubococcygeus

Arises from body of pubis and anterior 1/2 of the white line

Iliococcygeus

Arises posterior 1/2 of the white line and ischial spine

Anterior fibres

form Levator prostate in males and Sphincter vaginae in females

Intermediate fibres

Puborectalis

Poserior fibres

pubococcygeus proper

1- Levator prostatae or sphincter vaginae ;

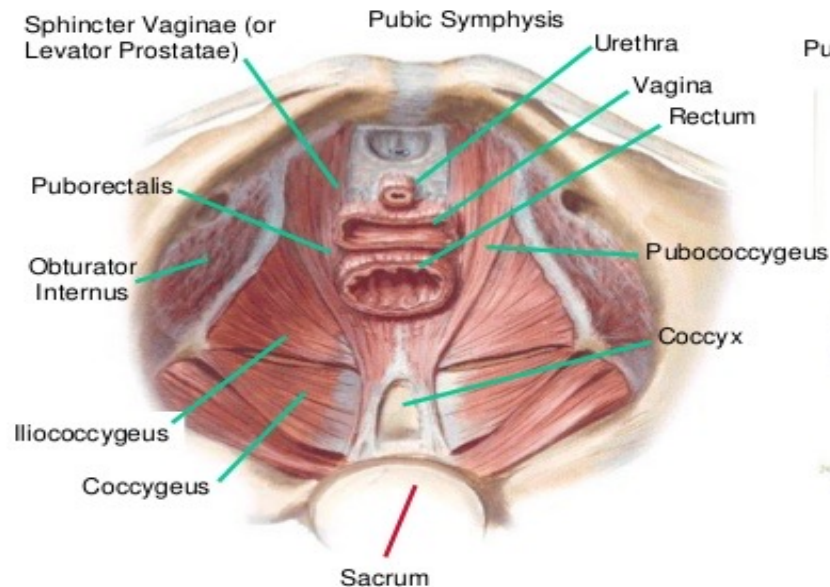
It pass horizontally and backwards around the sides of prostate in male or sides of vagina in female to insert into the **perineal body**

It supports the prostate , constrict the vagina and stabilize the perineal body.

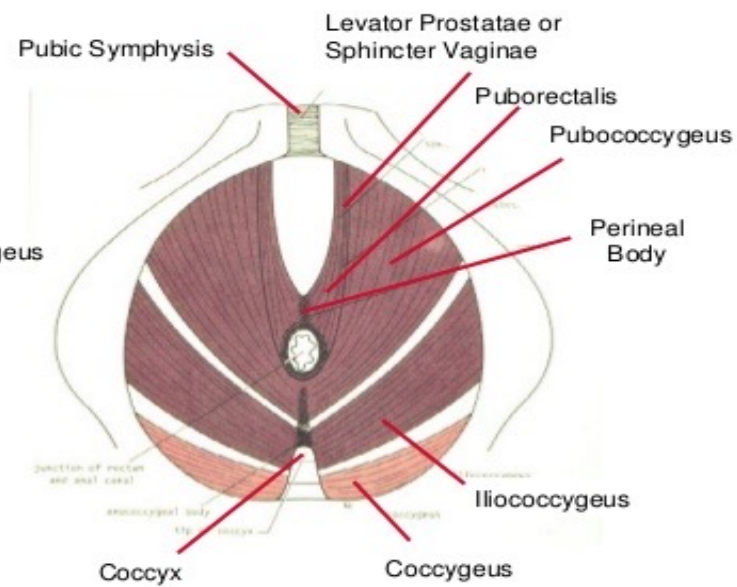
Perineal Body : is a mass of fibrous tissue, in front of the anal canal.

❖ **In the male** : it lies between anal canal and bulb of the penis.

❖ **In the female** : it lies between anal canal and lower part of vagina.



Superior View

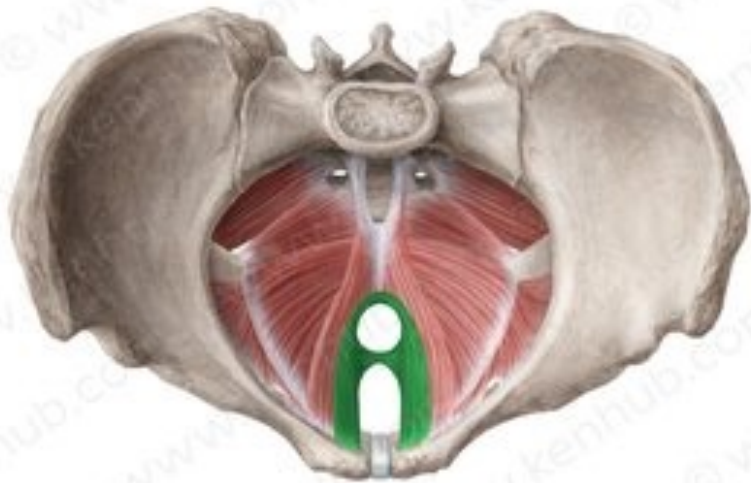


Inferior View

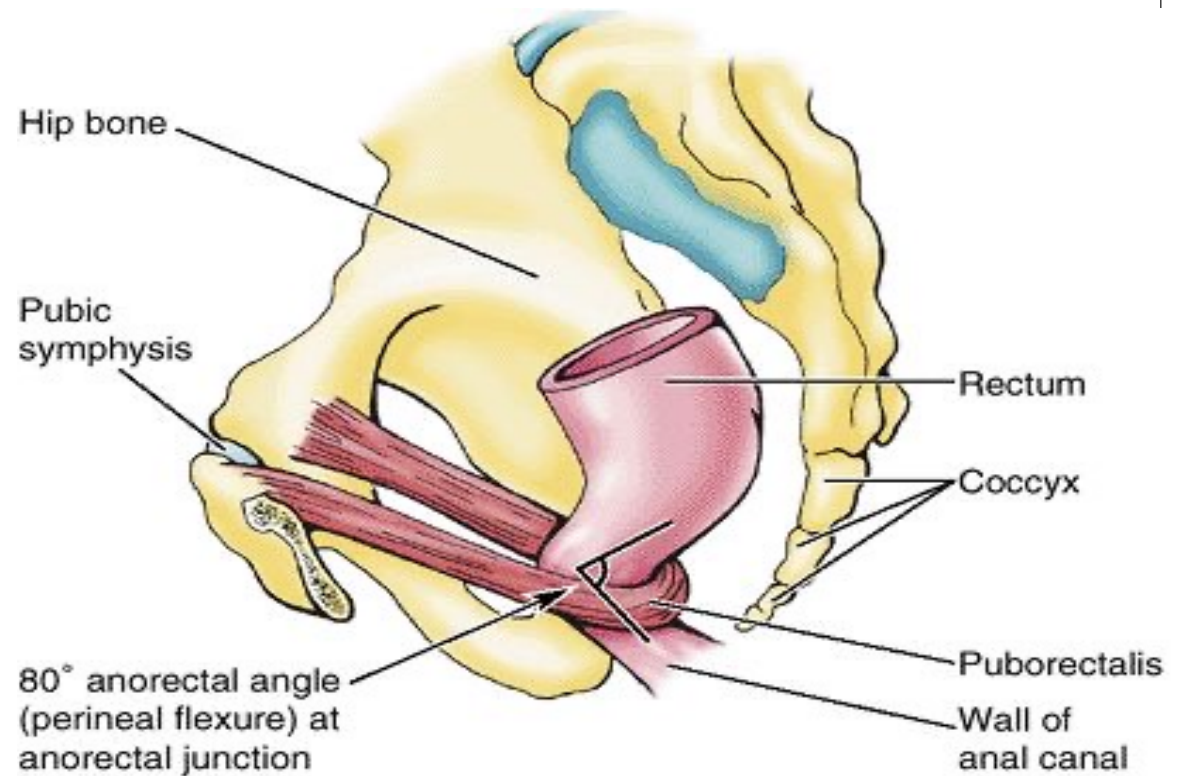
2. The puborectalis

It passes inferomedially to become continuous with the opposite ones behind the anorectal junction, so form a U-shaped sling.

It is inserted into Anococcygeal body



© www.kenhub.com

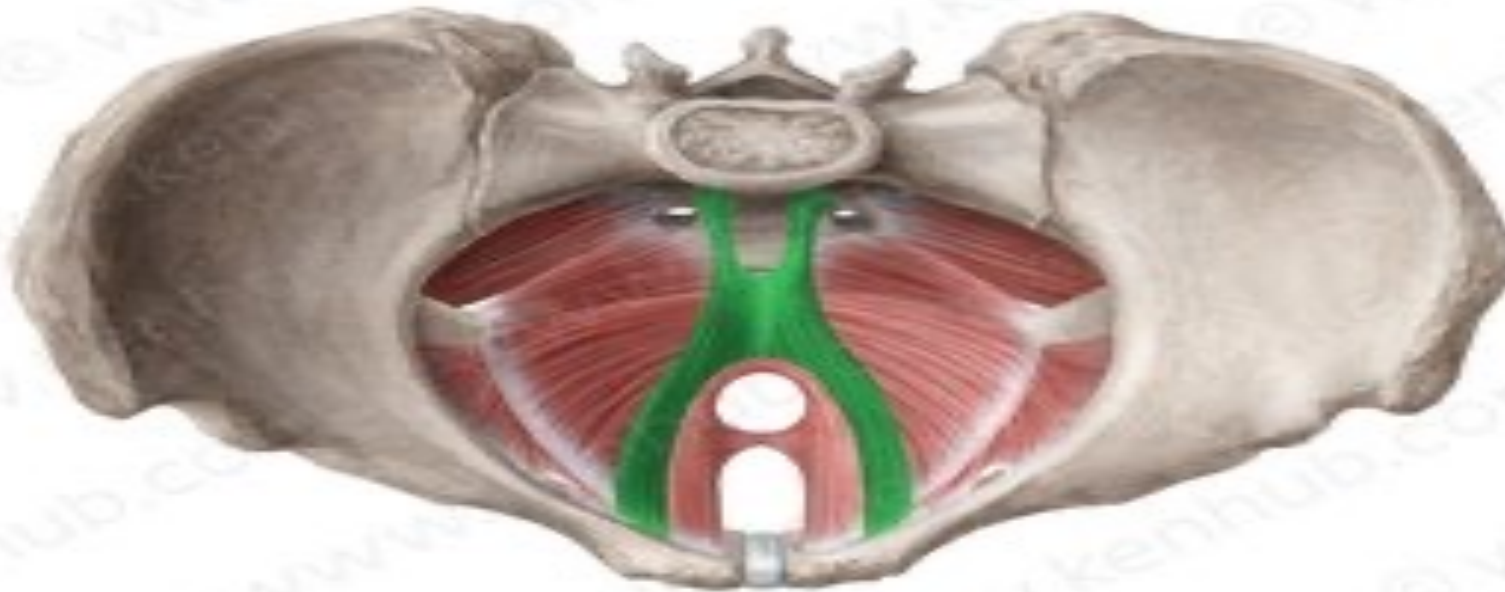

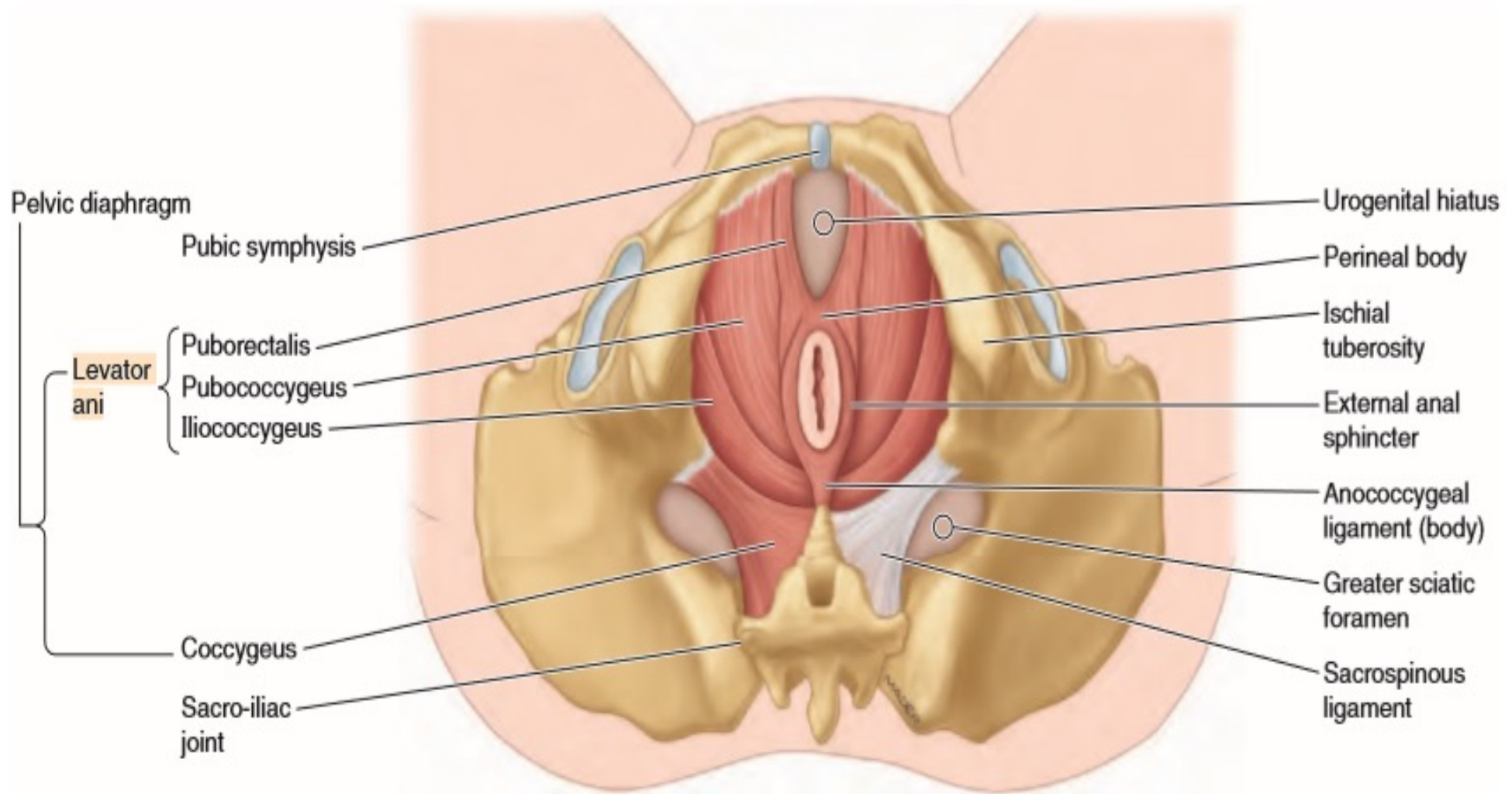
Medial view from left

3-Pubococcygeus proper

It pass medially to be attached to side of coccyx and anococcygeal Body

Anococcygeal body :A small fibrous mass between the tip of the coccyx and the anal canal.



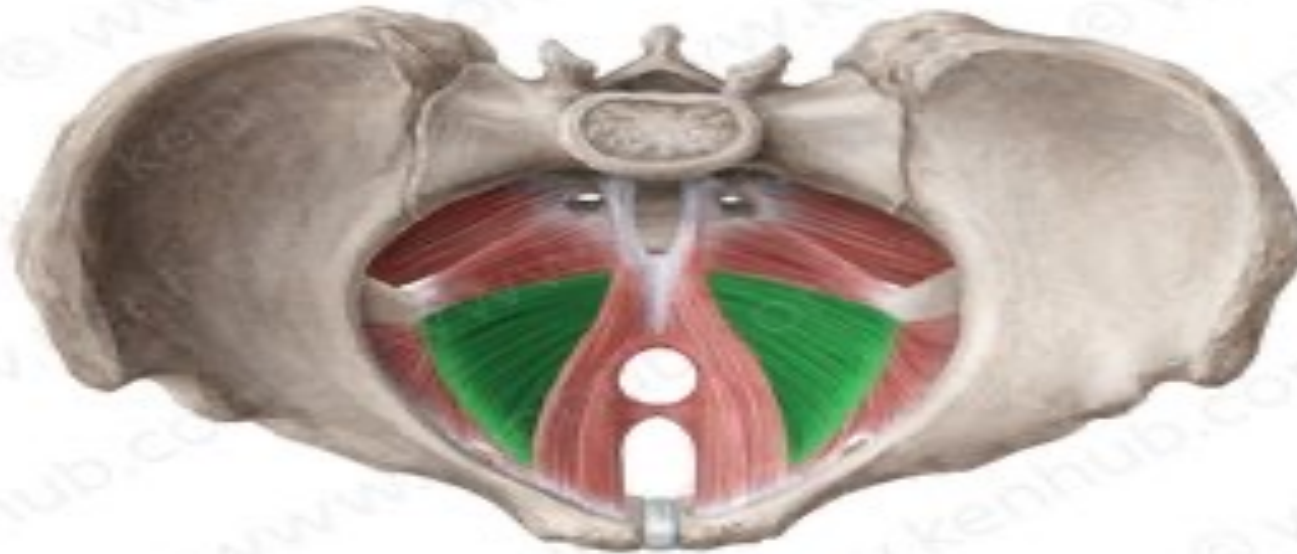

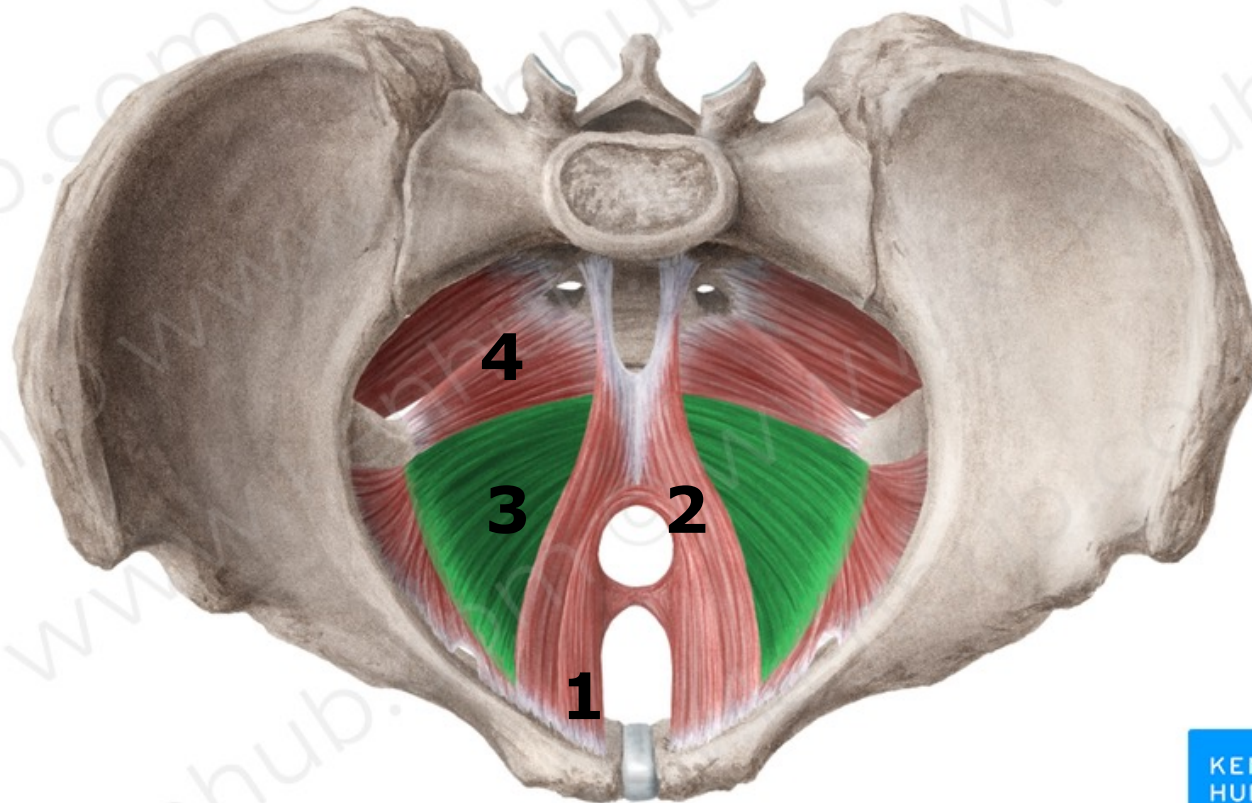
(A) Inferior view of perineum, lithotomy position

Iliococcygeus :

It arises from posterior 1/2 of the white line and ischial spine.

Its fibres pass medially inferior to the pubococcygeus proper and has the same insertion into side of coccyx and the anococcygeal raphe.





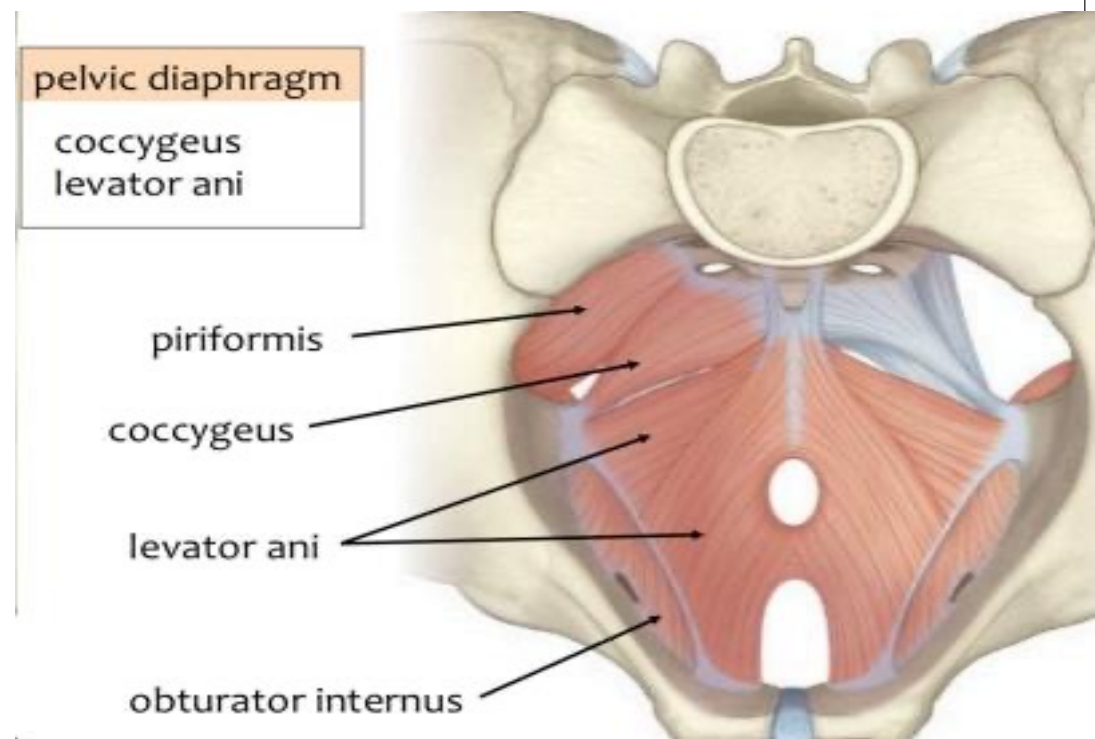
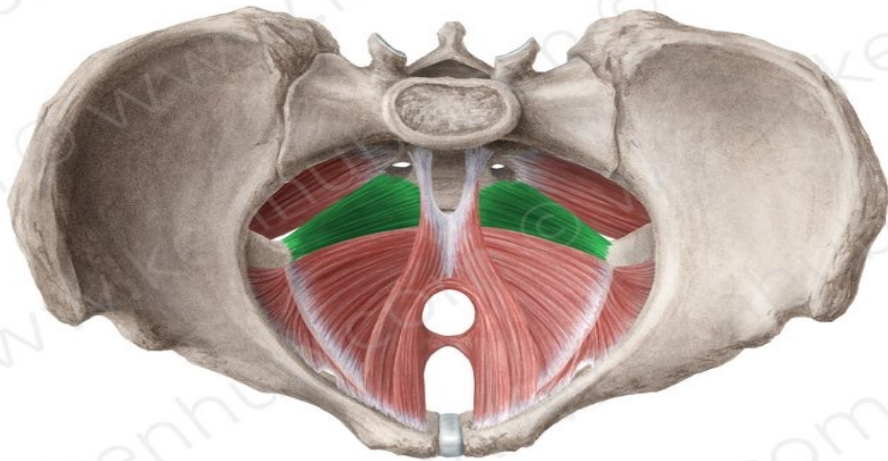
Coccygeus Muscle

Origin : Ischial spine

Insertion : lower end of the sacrum and into the coccyx

Nerve supply: A branch of the 4th and 5th sacral nerves

Action: The two muscles assist the levatore ani in supporting the pelvic viscera.

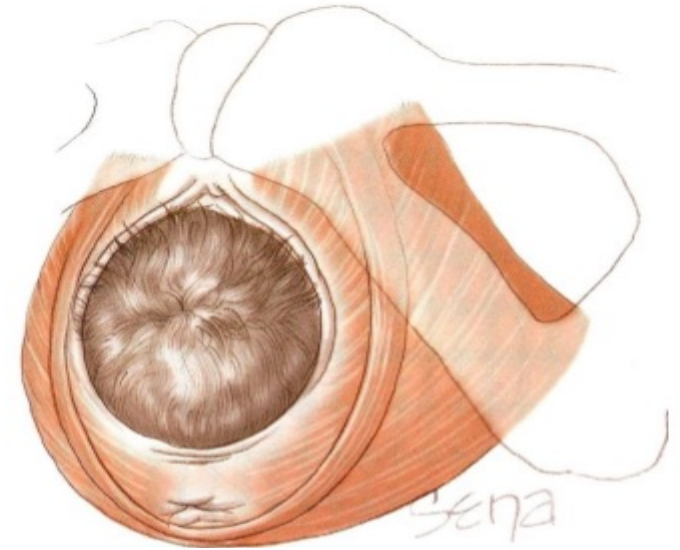


Functional Significance of the Pelvic Floor in the Female

It helps in head rotation during second stage of labour

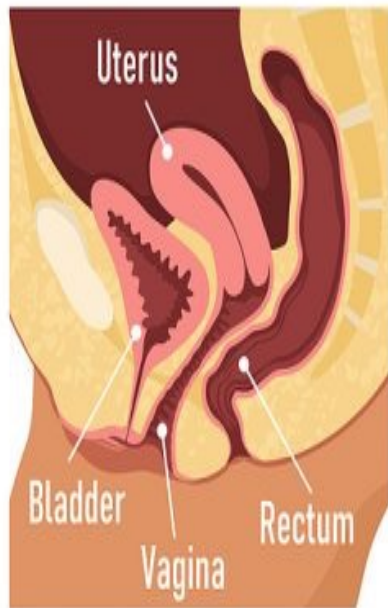Injury to the pelvic floor

- Can happen during a difficult childbirth
- This leads to loss of support for the pelvic viscera leading to
 - Uterine and vaginal prolapse,
 - Herniation of the bladder (cystocele),
 - Alteration in the position of the bladder neck and urethra, leading to **stress incontinence** (patient dribbles urine whenever the intra-abdominal pressure is raised, as in coughing).
 - Prolapse of the rectum may also occur.

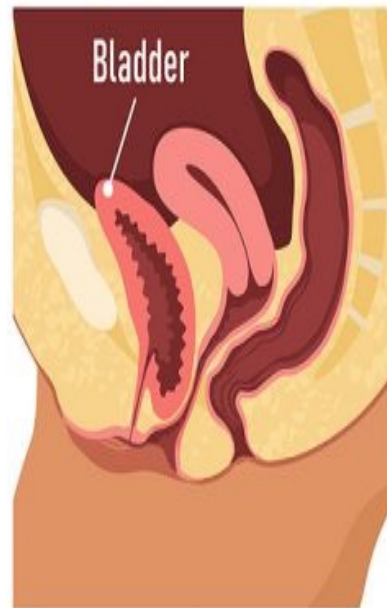

TYPES OF PELVIC ORGAN PROLAPSE

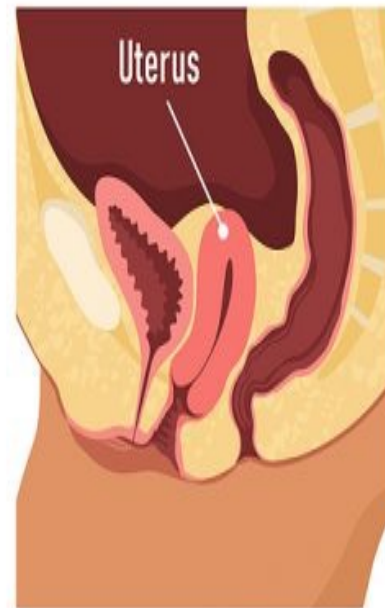Normal Anatomy



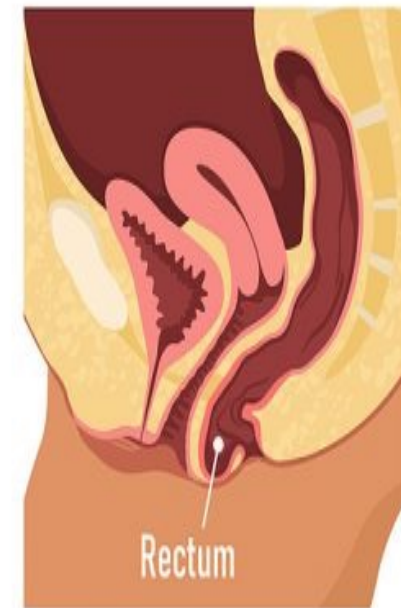Cystocele



Uterine Prolapse



Rectocele



Alteration in the position of the bladder neck and urethra, leading to **stress incontinence** (patient dribbles urine whenever the intra-abdominal pressure is raised, as in coughing).



THANK YOU