



Ovarian and Fallopian Tube Pathology

Nisreen Abu Shahin, MD

Professor of pathology

**University of Jordan, School of
Medicine**

Topics covered in this lecture:

- **Ovarian neoplasms:**

- Classification
- Serous tumors
- Mucinous tumors
 - Teratomas
- Clinical aspects

- **Fallopian tube diseases:**

- Ectopic pregnancy
- Tubal malignancies

Ovarian Neoplastic Diseases

- 5th most common cancer in women.
- 5th leading cause of cancer death in women.
- 3 Origins of primary ovarian tumors:
 - 1- epithelium**
 - 2- germ cells**
 - 3- sex cord/stromal cells.**
 - Each of these cell types gives rise to a variety of tumors
- Secondary tumors of the ovary are metastatic malignancies that spread to the ovaries.

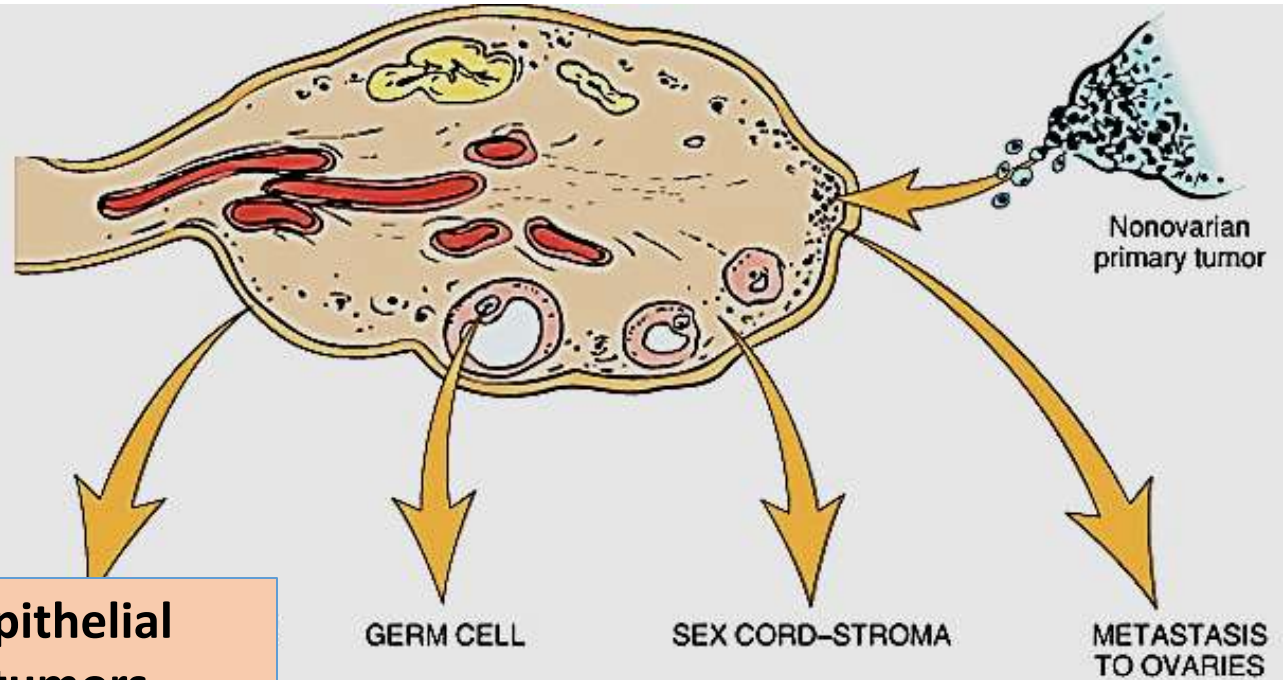
Epithelial Ovarian Neoplasms

- Account for the majority of ovarian tumors
- in their malignant forms, account for 90% of ovarian cancers
- Previously were thought to arise from coelomic epithelium that covers the ovarian surface
- Recent studies have shown that they actually arise from the fimbriated end of fallopian tube or epithelial cysts in the cortex of ovary.

Germ cell and sex cord–stromal cell tumors

- less frequent
- constitute 20% to 30% of ovarian tumors
- collectively responsible for less than 10% of malignant tumors of the ovary (so many of them are benign)

Ovarian Neoplasms



ORIGIN	Epithelial tumors	GERM CELL	SEX CORD-STROMA	METASTASIS TO OVARIES
Overall frequency	65%–70%	15%–20%	5%–10%	5%
Proportion of malignant ovarian tumors	90%	3%–5%	2%–3%	5%
Age group affected	20+ years	0–25+ years	All ages	Variable
Types	<ul style="list-style-type: none"> • Serous tumor • Mucinous tumor • Endometrioid tumor • Clear cell tumor • Brenner tumor • Cystadenofibroma 	<ul style="list-style-type: none"> • Teratoma • Dysgerminoma • Endodermal sinus tumor • Choriocarcinoma 	<ul style="list-style-type: none"> • Fibroma • Granulosa-theca cell tumor • Sertoli-Leydig cell tumor 	

Ovarian neoplasms - Pathogenesis:

- Risk factors:
- **nulliparity**
- **family history (Only 10%)**
- Note: OCPs **may reduce** risk.

Ovarian Epithelial Neoplasms- Pathogenesis:

- Sporadic cases
- **BRCA** 1 and 2 mutations: 10% of sporadic cases
- **p53** (serous)
- **HER2/NEU** over-expression (35%)
- **K-RAS** protein over-expression (30%) (mucinous)

- Familial cases
- **BRCA1** and **2**

EPITHELIAL TUMORS - types:

- **1- Serous**
 - **2- Mucinous**
 - **3- Endometrioid**
 - **4- Clear cell**
 - **5- Brenner**
-
- **All types include benign, borderline, and malignant tumors**

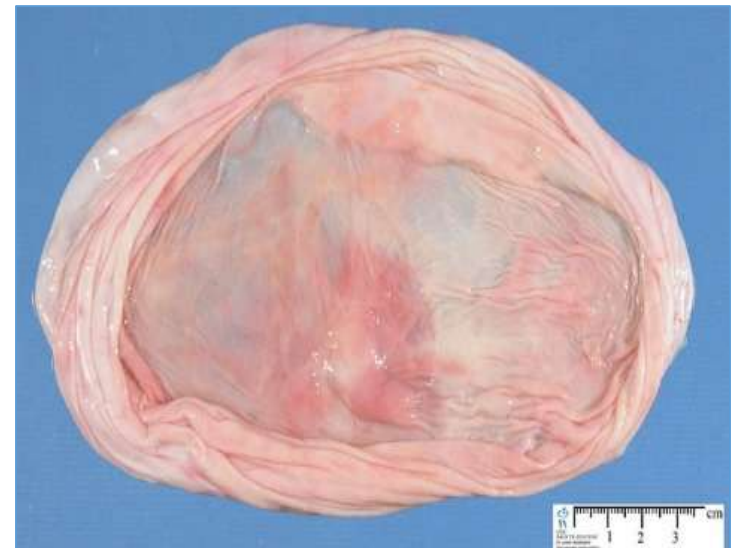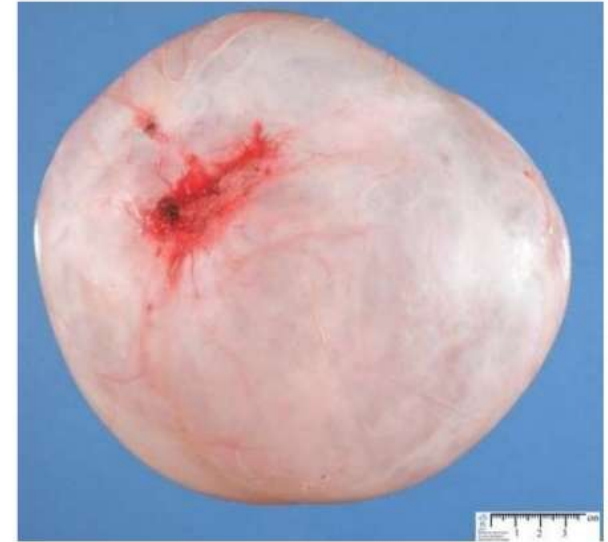1- Serous Tumors

- **the most frequent ovarian tumors.**
- Include: 60% benign, 15% borderline, and 25% malignant.
- **the most common malignant ovarian tumors (60%)**
- **Genetics:**
- ***BRAF* and *K-RAS* mutations → borderline & low grade serous carcinomas**
- ***p53* and *BRCA1* mutations → High-grade serous carcinomas**

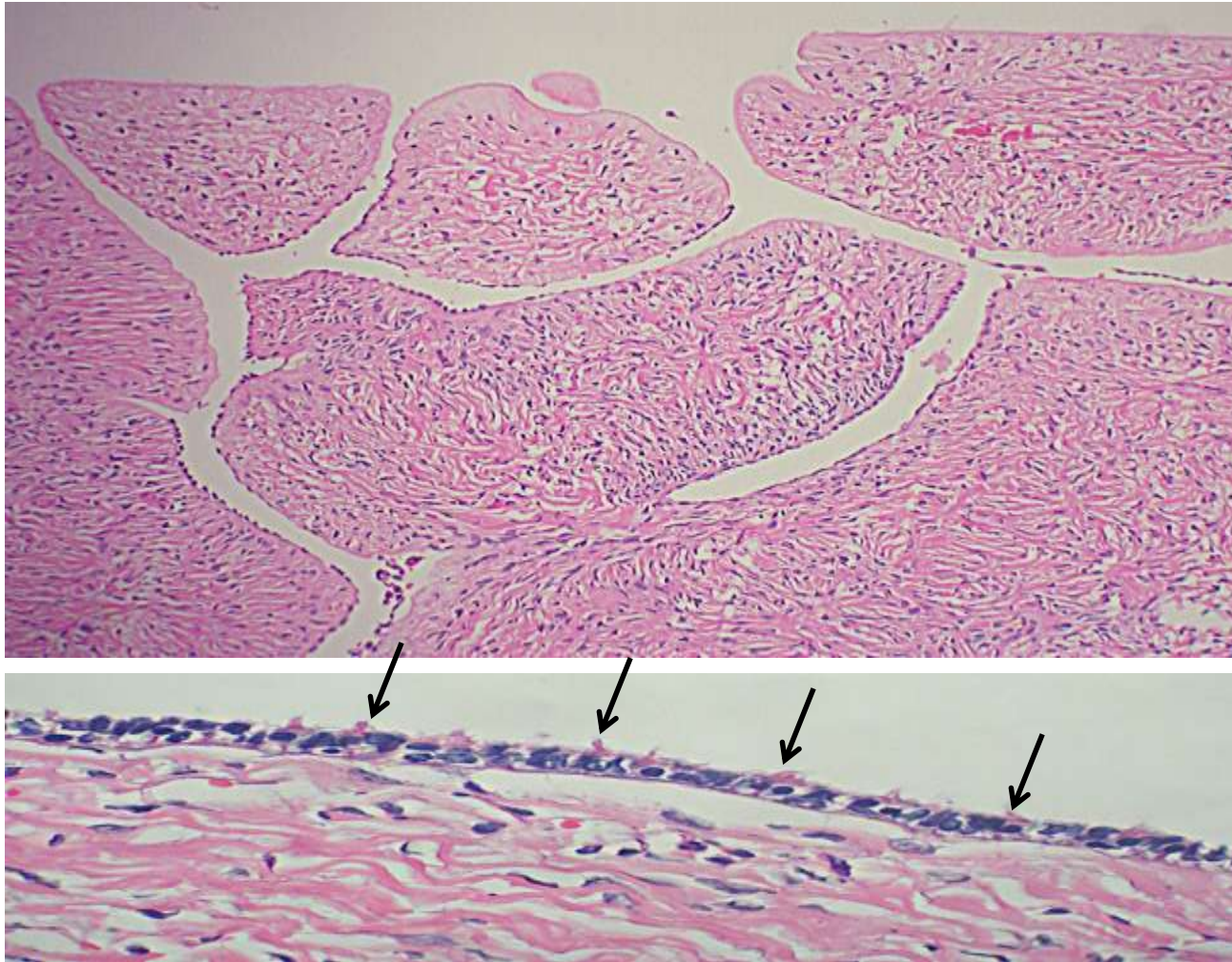
Benign serous tumors: Morphology

- **Benign serous tumors:**
- cystic ; large; (30 cm).
- May be bilateral.
- filled with a clear serous fluid
- **single layer** of columnar epithelium. Some cells are ciliated.
- **Psammoma bodies** (laminated calcified concretions) are common in tips of papillae of **all** serous tumors

SEROUS CYSTADENOMA

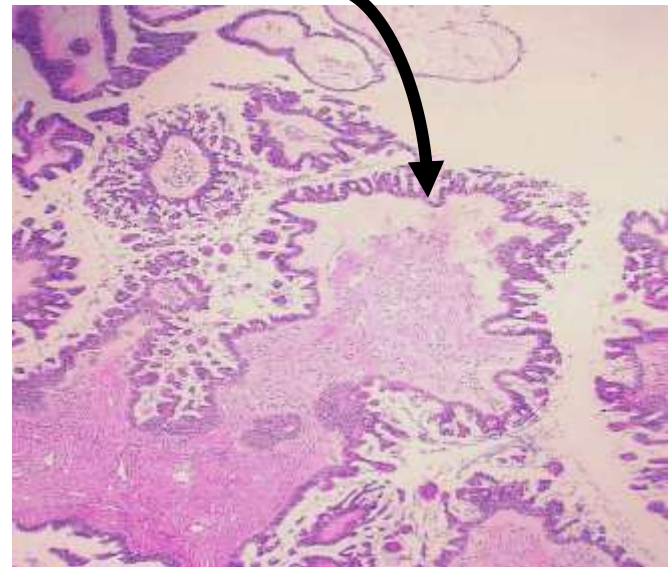
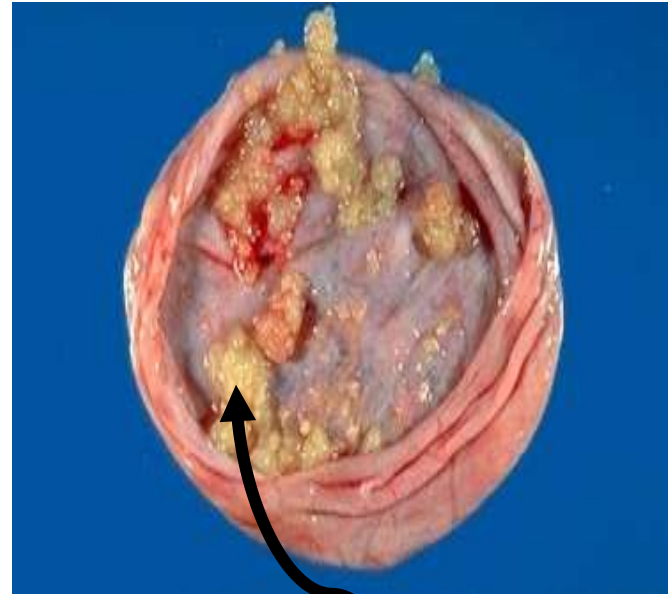


Benign serous tumors



Borderline Serous Tumors

- **Complex architecture**
- Mild cytologic atypia
- **No stromal invasion**
- May have peritoneal implants
- can recur and some can progress to carcinoma
- Prognosis: intermediate between benign and malignant types
- (survival with peritoneal metastases 75%)



Malignant Serous Tumors-There are two types of ovarian serous **carcinomas**:

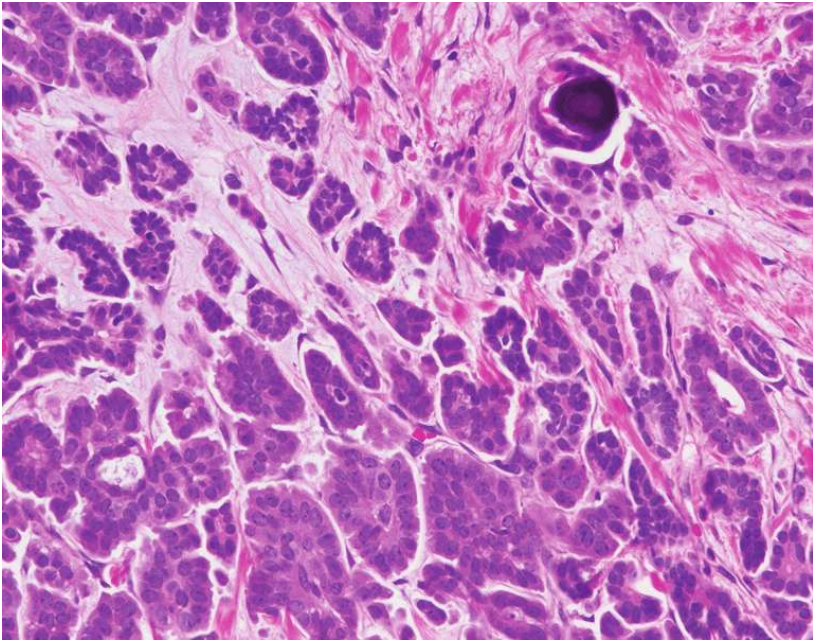
- low-grade serous carcinoma:

- arise from borderline lesions
- progress slowly to become invasive carcinoma
- Differentiated morphology
- mutations in **KRAS**

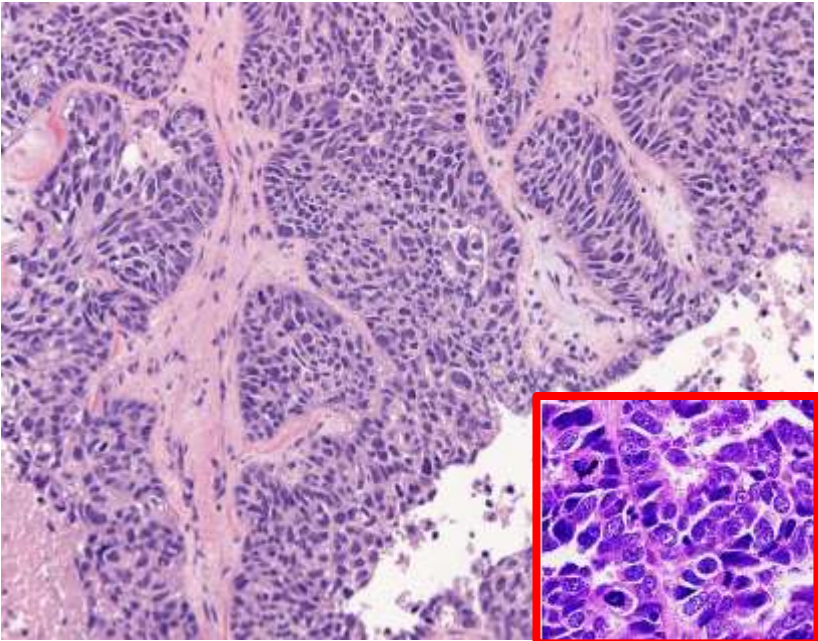
- high-grade serous carcinoma:

- develop rapidly
- many arise from fallopian tube via serous tubal intraepithelial carcinoma, rather than ovarian coelomic epithelium.
- mutations in **TP53**
- Anaplasia of cells and invasion of the stroma.
- prognosis poor, depends on stage at the time of diagnosis.

Low grade serous carcinoma



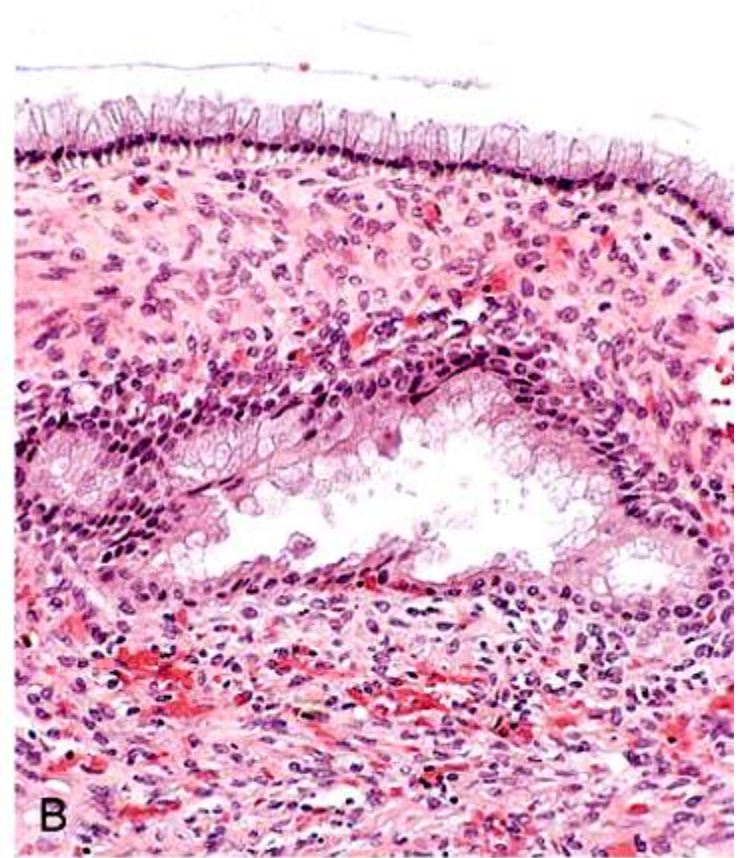
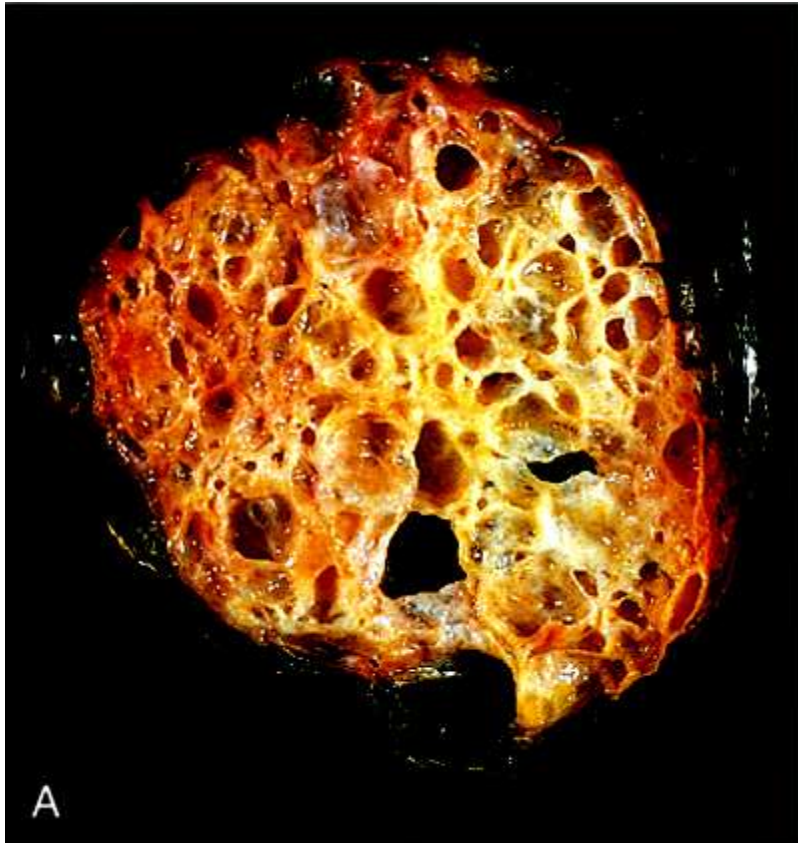
High grade serous carcinoma



2- Mucinous ovarian tumors

- **mucin-secreting** cells.
- 80% benign; 10% borderline; **10% malignant** (*cystadenocarcinoma*)
- **Usually large and multilocular** cystic tumors
- psammoma bodies **not** found
- stage is major determinant of prognosis

Mucinous ovarian tumors



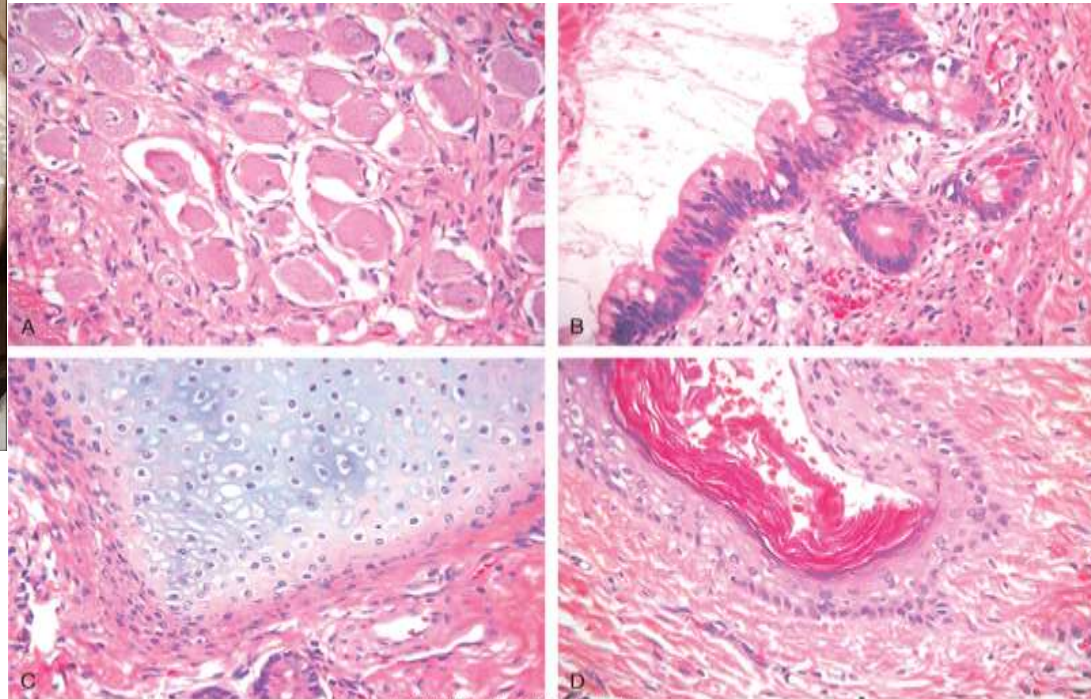
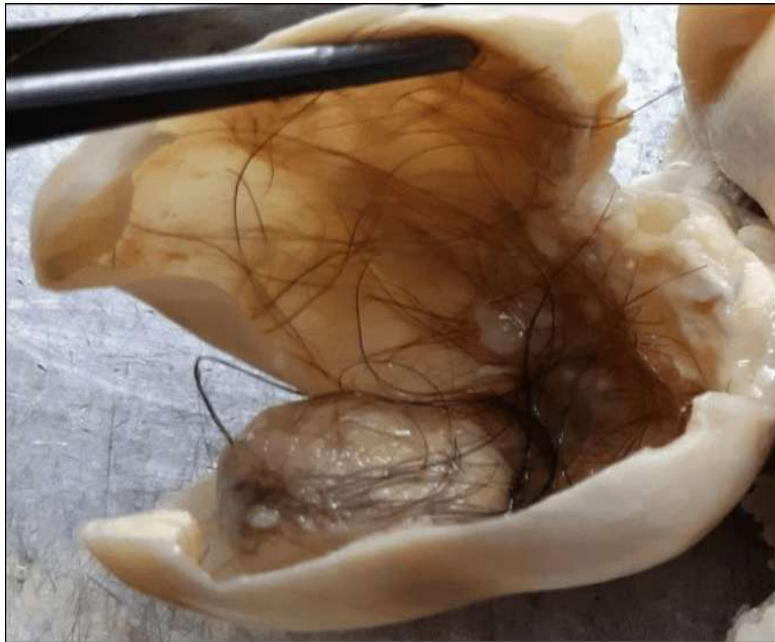Germ Cell Tumors

- Types according to differentiation:
- dysgerminoma (differentiation to oogonia)
- Embryonal carcinoma (differentiation to primitive embryonal tissue)
- yolk sac tumor (differentiation to endodermal sinus)
- choriocarcinoma (differentiation to placental tissue)
- Teratoma (differentiation to multiple tissue types).

Benign (Mature) Cystic Teratoma

- totipotential germ cells form mature tissues of all three germ cell layers
- 15% -20% of ovarian tumors
- Many discovered incidentally
- 90% unilateral
- cyst filled with sebaceous secretion and hair; bone and cartilage; epithelium, or teeth.
- > 90% are benign mature cystic teratomas
- immature (malignant variant) is rare.
- torsion (10% to 15% of cases)

Benign (Mature) Cystic Teratoma



Clinical Correlations for All Ovarian Tumors

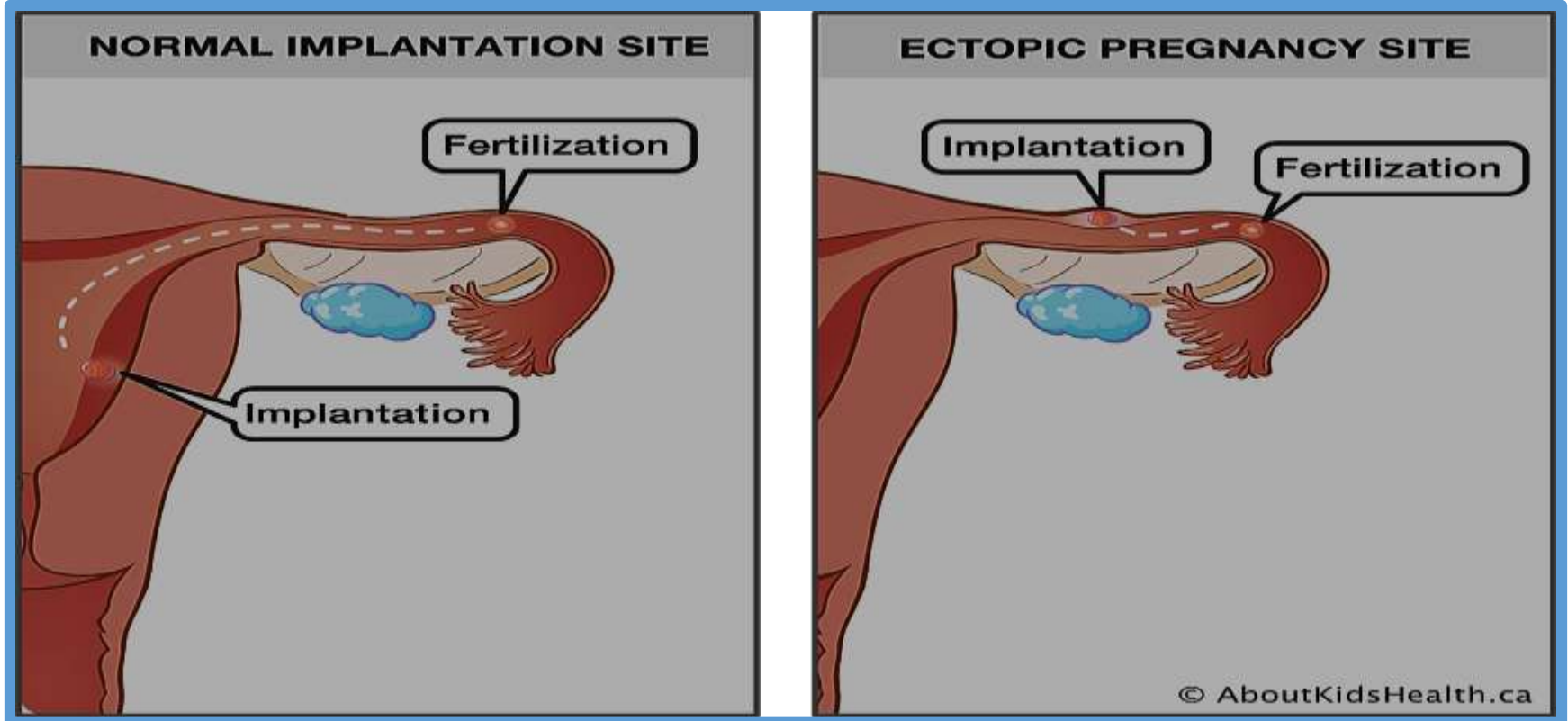
- Clinical presentation of all is similar:
 - Abd. pain, gastrointestinal complaints, urinary frequency; rarely torsion producing severe abdominal pain mimicking an "acute abdomen."
 - Ascites (in Fibromas and malignant serous tumors).
 - Functioning ovarian tumors : Estrogens or androgens.
- Treatment: surgery + chemotherapy + radiotherapy
- Outcome of ovarian **cancers** remains unsatisfactory
- **Malignant** tumors are usually discovered in advanced stages
- survival minimally improved since 1970s.
- No early Screening methods are yet available

Pathology of the Fallopian tubes

ECTOPIC PREGNANCY

- implantation of the fertilized ovum outside uterus
- Incidence: 1%
- 90% of cases occur in fallopian tubes
- other sites: ovaries, abdominal cavity
- Predisposing factors: tubal obstruction (50%); PID; tumors; endometriosis; **IUCD**...
- In 50% : no anatomic cause can be demonstrated.

Normal versus ectopic pregnancy



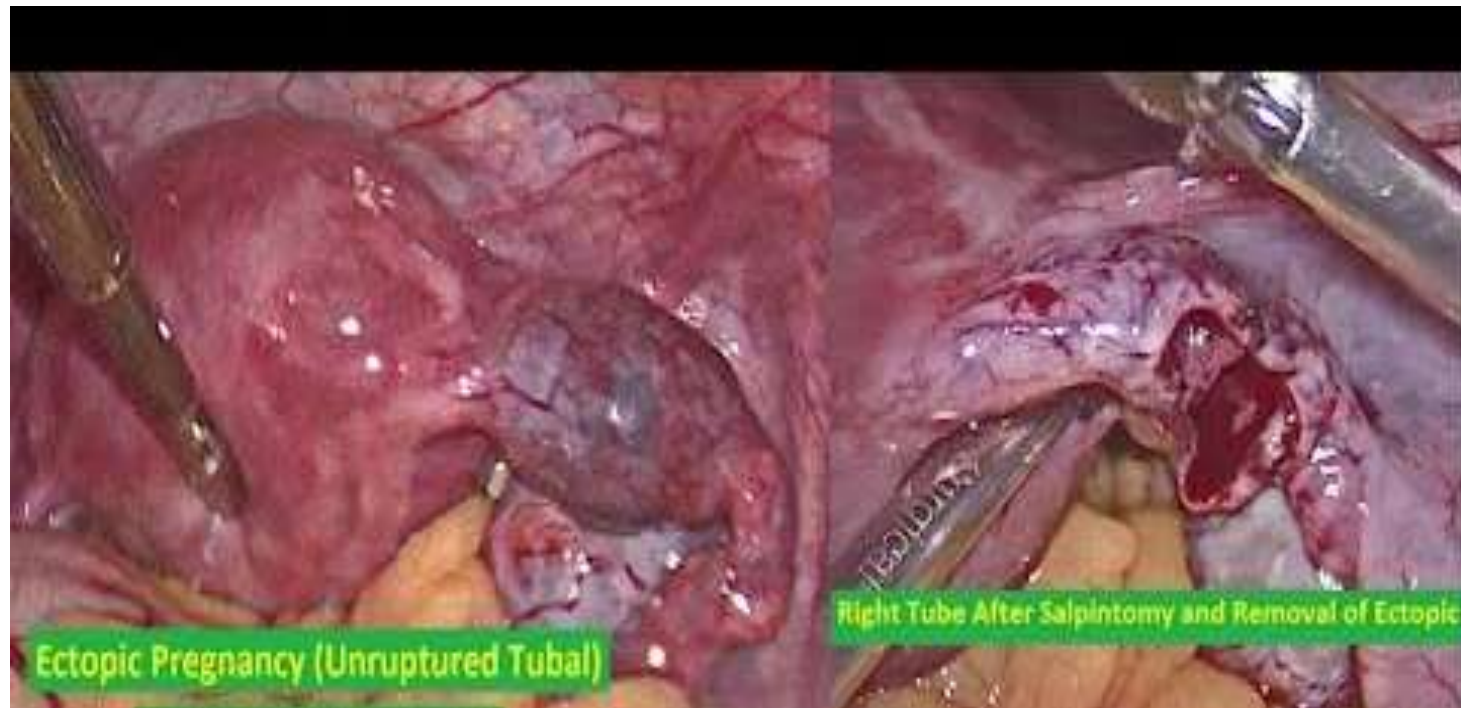
Early: development of embryo and placental tissue

Later: placenta burrows through tubal wall causing intratubal hematoma (hematosalpinx) and intraperitoneal hemorrhage.

Rupture: intense abdominal pain (acute abdomen), often followed by shock.

Prompt surgical intervention is necessary.

Ectopic pregnancy- Management



Tubal malignancies

- **most common histologic type is serous carcinoma.**
- may be the **origin** for many ovarian high-grade serous carcinomas
- **serous tubal intraepithelial carcinoma (STIC)** in fimbriated ends of fallopian tubes.
- STICs have mutations in TP53 in 90% of cases
- increased in women with **BRCA mutations**
- Because **of their access to peritoneal cavity**, fallopian tube carcinomas frequently spread to omentum and peritoneal cavity at time of presentation (advanced).