Lymphoma and Myleoma

Feras Fararjeh MD

Consultant in Haematology and Oncology

05.11.2026

Learning Objectives

- Define lymphoma
- Understand historical background
- Recognize major lymphoma types
- Understand classification systems
- Review basic pathophysiology
- Identify clinical presentation and diagnostic approach

Historical Background



1832: Thomas Hodgkin first described Hodgkin lymphoma



Early pathology studies distinguished lymphoid malignancies



20th century: Development of histologic classification systems



Modern era: WHO classification integrating morphology, immunophenotype, genetics, and clinical features

What is Lymphoma?

- • Malignant proliferation of lymphocytes
- • Originates in lymphoid tissues
- • Can involve lymph nodes, spleen, bone marrow, and extranodal organs
- • Two main categories: Hodgkin lymphoma (HL) and Non-Hodgkin lymphoma (NHL)

The Lymphatic System

- • Network of lymph nodes, lymphatic vessels, spleen, thymus, and bone marrow
- • Functions in immune surveillance
- • Contains B cells, T cells, and NK cells
- • Lymphomas arise from malignant transformation of these cells

Major Categories of Lymphoma

- • Hodgkin Lymphoma (HL)
- • Non-Hodgkin Lymphoma (NHL)
- • NHL accounts for ~85–90% of lymphomas
- • HL characterized by Reed–Sternberg cells

NHL/ HD(Lymphoma): common features

1- Lymph node enlargement: painless, decides stage

2- May be associated with B-symptoms: fever, night sweats, weight loss

3- Compression symptoms may occur

4- Extra-nodal involvement

5- Needs LN BX for diagnosis

6- Each has different histology types

7- Both have similar staging system

Staging System for Lymphomas (ANN ARBOR CLASSIFICATION)

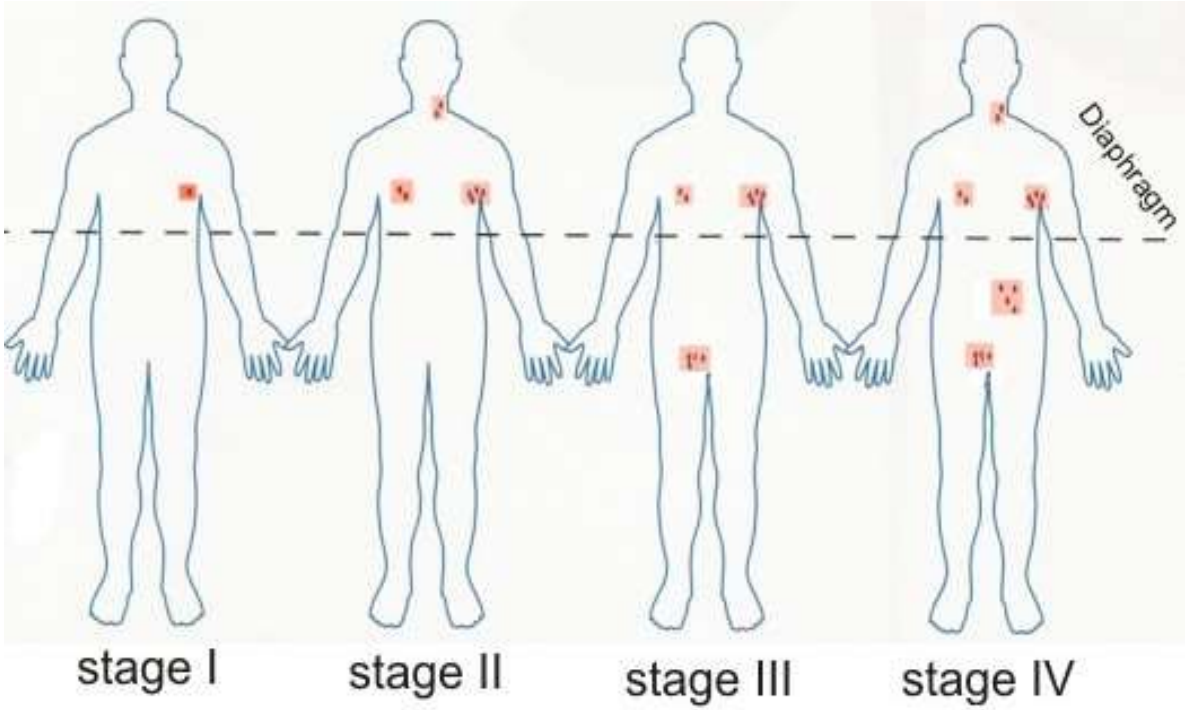

WHO Classification Concept

Based on:

– Cell of origin

– Morphology

– Immunophenotype

– Genetic abnormalities

– Clinical behavior

Allows more accurate diagnosis and treatment selection

Hodgkin Lymphoma Types

- Classical Hodgkin lymphoma (cHL)
  - Nodular sclerosis
  - Mixed cellularity
  - Lymphocyte rich
  - Lymphocyte depleted
- Nodular lymphocyte predominant HL

Reed–Sternberg Cells

- Large atypical B cells
- Multinucleated appearance
- “Owl-eye” nuclei
- Characteristic of classical Hodgkin lymphoma
- Usually CD30+ and CD15+

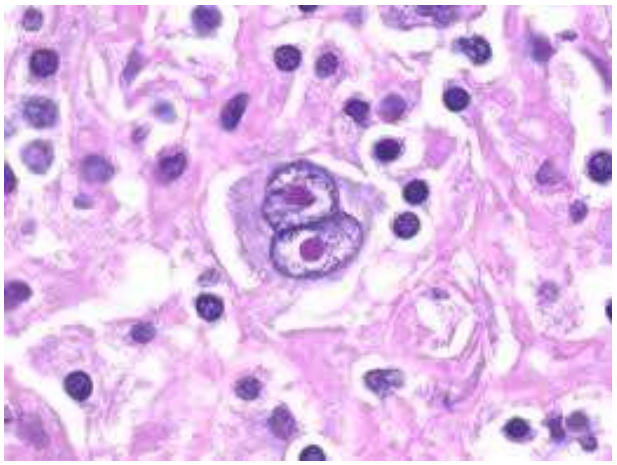

Non-Hodgkin Lymphoma Overview

- Heterogeneous group of lymphoid malignancies
- Majority are B-cell lymphomas
- Some arise from T cells or NK cells
- Wide spectrum: indolent → aggressive

Common B-Cell Lymphomas

- Diffuse large B-cell lymphoma (DLBCL)
- Follicular lymphoma
- Mantle cell lymphoma
- Marginal zone lymphoma
- Burkitt lymphoma
- Chronic lymphocytic leukemia / SLL

Common T-Cell Lymphomas

- Peripheral T-cell lymphoma
- Anaplastic large cell lymphoma
- Adult T-cell leukemia/lymphoma
- Mycosis fungoides / Sézary syndrome

Basic Pathophysiology

- Genetic mutations affecting lymphocyte proliferation
- Dysregulation of apoptosis
- Chromosomal translocations common
- Examples:
  - t(14;18) in follicular lymphoma
  - t(11;14) in mantle cell lymphoma
  - MYC translocation in Burkitt lymphoma

Risk Factors

- Immunodeficiency (HIV, transplant)
- Autoimmune diseases
- Chronic infections (EBV, H. pylori, HTLV-1)
- Radiation exposure
- Family history

Clinical Presentation

- Painless lymphadenopathy
- B symptoms:
  - Fever
  - Night sweats
  - Weight loss
- Fatigue
- Splenomegaly
- Extranodal symptoms depending on site

Diagnostic Approach

- History and physical examination
- Laboratory tests
- Imaging (CT, PET-CT)
- Lymph node biopsy (excisional preferred)

Pathologic Diagnosis

- Histology and morphology
- Immunohistochemistry
- Flow cytometry
- Cytogenetics and molecular studies

Staging

- • Ann Arbor staging system
- • Stage I – single lymph node region
- • Stage II – multiple regions same side diaphragm
- • Stage III – both sides of diaphragm
- • Stage IV – disseminated extranodal disease

Revised European-American Lymphoma (REAL) Classification: B-Cell Neoplasms

Indolent	Aggressive	Very Aggressive
•CLL/SLL	•PLL	•Precursor B-lymphoblastic lymphoma/Leukemia
•Lymphoplasmacytic/ IMC/WM	•Plasmacytoma/ Multiple myeloma	•Burkitt's lymphoma/ B-cell acute leukemia
•HCL	•MCL	•Plasma cell leukemia
•Splenic marginal zone lymphoma	•Follicle center lymphoma, follicular, grade III	
•Marginal zone lymphoma – Extranodal (MALT) – Nodal	•DLCL	
	•Primary mediastinal large B-cell lymphoma	
•Follicle center lymphoma, follicular, grade I-II	•High-grade B-cell lymphoma/Burkitt's-like	

Hiddemann. *Blood.* 1996;88:4085.

Treatment Options in Advanced Indolent Lymphomas

- ***Observation only.***
- ***Radiotherapy to site of problem.***
- ***Systemic chemotherapy***
  - ***oral agents: chlorambucil and prednisone***
  - ***IV agents: CHOP, COP-R, FC-R***
- ***Antibody against CD20: rituximab***
- ***Stem cell or bone marrow transplant.***
- *New monoclonal antibodies*

Reasons to Treat in Advanced Indolent Lymphomas

- Constitutional symptoms
- Anatomic obstruction
- Organ dysfunction
- Cosmetic considerations
- Painful lymph nodes
- Cytopenias

Case 11 B: Multiple Myeloma

67 yr old male has been complaining of back pain for several months. He recently noticed exertional dyspnea. He was admitted because of sever pain in his arm.



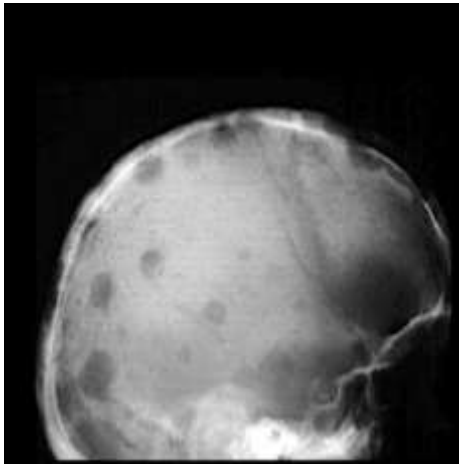

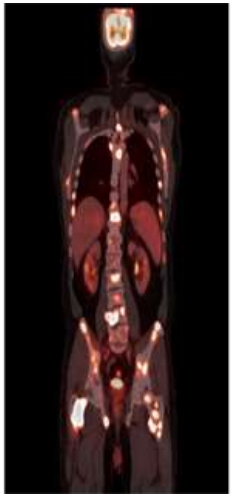

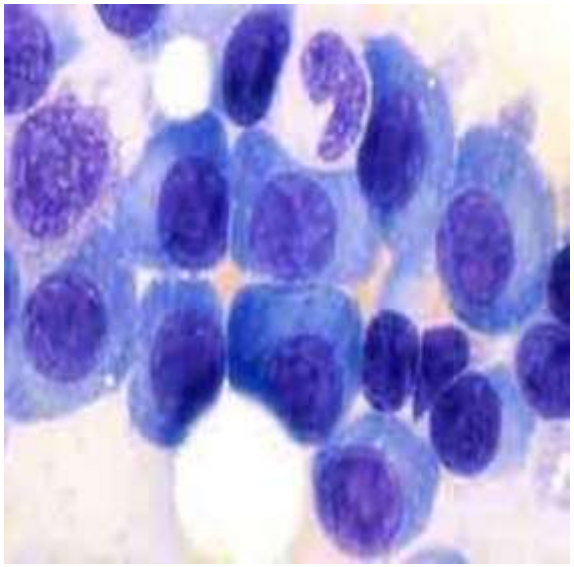

Case 11 B Investigation and Diagnosis

1- Hb 8 g/dl, normocytic normochromic, WBC 8K, Plt 180K, ESR 112mm/1st hr. Bld film. B2-microglobulin 6mg/l, serum albumin 3 g/dl,P/E 1gG 15 g/dl and IF/ igGK

2- Multiple myeloma igG/ƙ stage III (C).

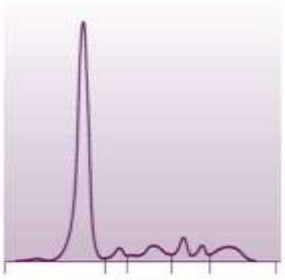

A/G 2.32
T.P.: 7

Fractions	%	Ref. %	g/dl	Ref. g/dl
Albumin	69.9	52.9–66.9	4.9	3.7–4.9
Alpha	3.5	3.0–5.8	0.2	0.2–0.4
Alpha 2	8.8	7.5–13.4	0.6	0.5–1.0
Beta	9.3	8.5–13.7	0.7	0.6–1.0
Gamma	8.5	8.8–19.2	0.6	0.6–1.4

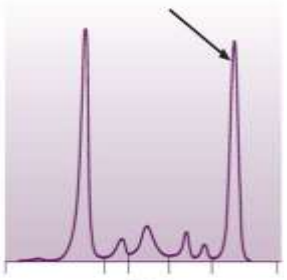

A/G 0.67
T.P.: 8.2

Fractions	%	Ref. %	g/dl	Ref. g/dl
Albumin	40.2	52.9–66.9	3.3 L	3.7–4.9
Alpha	4.8	3.0–5.8	0.4	0.2–0.4
Alpha 2	11.0	7.5–13.4	0.9	0.5–0.9
Beta	7.8	8.5–13.7	0.6	0.6–1.0
Gamma	36.2	8.8–19.2	3.0 H	0.6–1.4

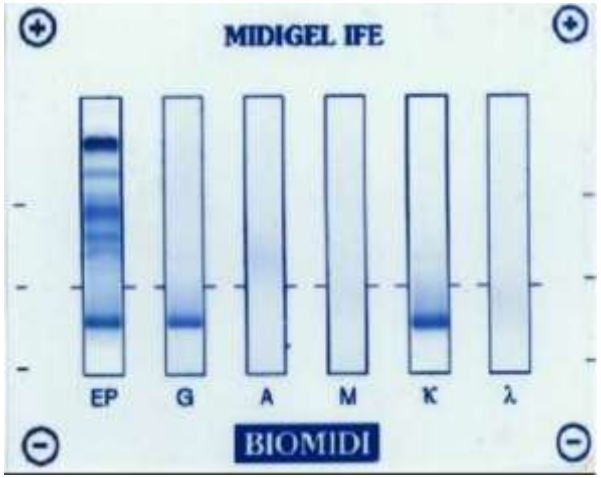

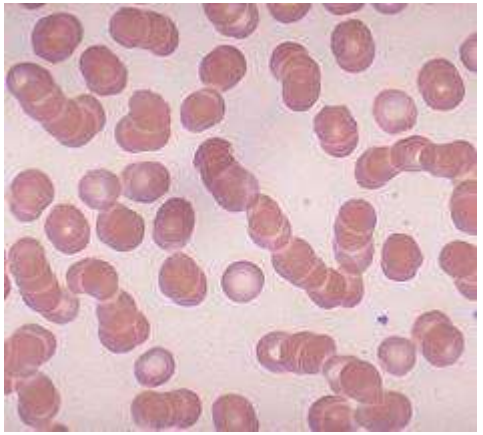

Clinical Features

- Symptoms related to BM infiltration: bone pain, osteolytic lesions and fractures, anemia, hypercalcemia
- Secretion of abnormal proteins: renal and neurological or visceral manifestations
- Hyperviscosity syndrome
- Recurrent infections
- Amyloidosis

Clinical features

- common tetrad of multiple myeloma is ***CRAB***
  - **C = Calcium (elevated)**
  - **R = Renal failure**
  - **A = Anemia**
  - **B = Bone lesions**

Active Multiple Myeloma

Both criteria must be met:

1- Clonal bone marrow plasma cells 10% or biopsy-proven bony or extramedullary plasmacytoma

2- Any one or more of the CRAB features

Smouldering MM

Both criteria must be met:

Serum monoclonal protein (IgG or IgA) 3 g/dL, or urinary monoclonal protein 500 mg per 24 h and/or clonal bone marrow plasma cells 10%–60%

Absence of myeloma defining events or amyloidosis Mu

Diagnosis and Staging Workup

- Bone marrow biopsy and aspirate
- Serum protein electrophoresis and immunofixation
- Skeletal survey/ MRI/PET Scan
  - Plain x-rays are better than bone scan.
  - Lytic lesions do not show up well on bone scan.
- Quantitative immunoglobulins