# STROKE

## ISCHEMIC STROKE

- Types
  - 1) Thrombotic
    - blood clot that forms in an artery that supplies blood to the brain
    - **atherosclerotic stroke( most commonly)**
    - primary hematological disease ( less common) — ( Polycythemia, Essential thrombocytosis or hypercoagulability, sickle cell, antiphospholipid )
    - Vessel wall pathologies leading to thrombosis — vasoconstriction, fibromuscular dysplasia and arterial dissection.
    - It affects mostly the large cervical and intracranial arteries.
    - Thrombosis of penetrating intracranial arteries is most often the consequence of hypertension, with hyperthrophy of the media and deposition of fibrinoid material( lipohyalinosis)
  - 2) Embolic
    - clot forms somewhere else in the body and travels through the blood vessels to the brain. It gets stuck there and stops the flow of your blood
      - The material arises proximally
        - **heart ( mostly)**
          - **Atrial fibrillation** increases the risk of clots forming in the heart that can then travels to the brain. — so if you have recurrant stroke regardless the treatment , it might be cardiac cause
          - sources
            - heart valves
            - endocardium ( infective endocarditis)
            - clots
            - tumors within atrial or ventricular cavities
        - major arties
          - aorta
          - ICA
          - VA.
        - Systemic veins
          - travel to brain through cardiac defect as
            - atrial septal defect
            - patent foramen ovale
          - process name: ( PARADOXICAL EMBOLISM) — dx by double bubble test
        - other sources ( occasionally) — air, fat, cholesterol crystals, bacteria and foreign bodies enter the vascular system and embolize to brain vessels
  - 3) Systemic hypoperfusion
    - Decreased blood flow to brain tissue may be caused by low systemic perfusion pressure ( generalised cause that affects brain diffusely and bilaterally)
    - The most common causes are
      - **cardiac pump failure** — most often due to **myocardial infarction or arrhythmia**
      - systemic hypoperfusion — **blood loss or hypovolemia**
    - Poor perfusion is most critical in border zone or so-called watershed regions at the periphery of the major vascular supply territories,

$$\frac{k.c.A}{P.C.A} \Leftrightarrow \frac{M.c.A}{}$$

- Risk factors
  - Age over 60 years old
  - History of hypertension, heart diseases, hyperlipidemia, or diabetes.
  - Arrythmia
  - Smoking History
  - Family history of strokes
- Complications
  - Permanent weakness
  - seizures — if it affect the cerebral cortex ( it will decrease threshold for seizure)
  - Vascular Dementia — due to cerebral ischemia, particularly when infarcts involve memory-related regions such as the hippocampus.
- Classification of Ischemic Stroke by Anatomy

| Site of the lesion | Associated effects |
|---|---|
| Anterior cerebral artery | Contralateral hemiparesis and sensory loss, lower extremity > upper |
| Middle cerebral artery | Contralateral hemiparesis and sensory loss, upper extremity > lower<br>Contralateral homonymous **hemianopsia**<br>Aphasia<br>**Memory and behavior effected** |
| Posterior cerebral artery | Contralateral homonymous hemianopsia with macular sparing<br>Visual agnosia |
| Wallen's syndrome (branches of the posterior cerebral artery that supply the midbrain) | Ipsilateral CN III palsy<br>Contralateral weakness of upper and lower extremity |
| Posterior inferior cerebellar artery (lateral medullary syndrome, Wallenberg syndrome) | Ipsilateral facial pain and temperature loss<br>Contralateral limb/torso pain and temperature loss — **Alternate to a side**<br>Ataxia, nystagmus<br>**Hoarseness** |
| Anterior inferior cerebellar artery (lateral pontine syndrome) | Symptoms are similar to Wallenberg's syndrome, but with **hearing loss**<br>Ipsilateral facial paralysis and deafness |
| Retinal/ophthalmic artery | Amaurosis fugax — **Sudden loss of vision** |
| Basilar artery | Locked-in syndrome |

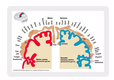

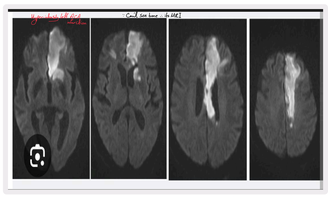

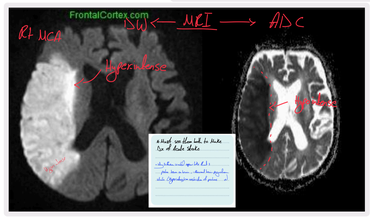


- Common Ischemic Stroke Syndromes
  - Anterior Circulation:
    - Left/Right cerebral hemisphere lesions are most often caused by carotid artery occlusion, embolism to the MCA or its branches or basal ganglionic intracerebral hemorrhages.

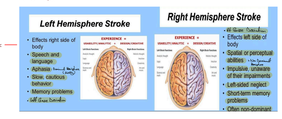


  - Posterior Circulation:
    - 1. Lateral medullary stroke
      - Wallenberg syndrome
      - usually due to :
        - intracranial VA occlusion
        - or posterior inferior cerebellar artery/ PICA occlusion
    - 2. Bilateral pontine base and often medial tegmentum stroke
      - usually due to
        - basilar artery occlusion
        - or pontine hemorrhage
      - will cause:
        - Quadriparesis
        - Unilateral or bilateral conjugate gaze paresis; sometimes internuclear ophthalmoplegia or 6th nerve palsy
        - When the medial tegmentum is involved bilaterally, COMA!!!
    - 3. Cerebellar infarction
      - usually due to
        - embolism to the PICA or SCA
        - or cerebellar hemorrhage

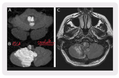

      - will cause:
        - Gait ataxia
        - Dysarthria
        - Ipsilateral arm dysmetria
    - 4. Left PCA territory stroke — will cause:
      - a) Right homonymous hemianopia
      - b) At times, amnesia
      - c) Alexia (disorder of reading) — without agraphia when the splenium of the corpus callosum is involved
    - PCA= Embolic stroke(mostly)
    - 5. Right PCA territory stroke
      - will cause
        - a) Left homonymous hemianopia
        - b) At times, left-sided visual neglect
      - PCA territory infarcts are most often caused by embolism arising from the heart, aorta or VAs
  - Lacunar syndromes

    - most often due to occlusion of a penetrating artery
    - may occur in either the Anterior or the posterior circulations
    - types
      - 1. Pure motor stroke:
        - Weakness of the contralateral arm, face and leg
        - without sensory, visual or cognitive/behavioral signs
        - Common locations include — corona radiata posterior limb of the internal capsule and pons.
      - 2. Pure sensory stroke:
        - Paresthesia of the contralateral body, limbs and face
        - without motor, visual or cognitive abnormalities
        - The most common location is due to infarction in the ventral posterior thalamus .
      - 3. Sensorimotor stroke:
        - Combination of motor and sensory lacunes
        - due to infarction in the ventral posterior thalamus and adjacent posterior limb of the internal capsule.
      - 4. Dysarthria-clumsy hand syndrome:
        - Slurred speech and clumsiness of the contralateral hand
        - The most common location is in the base of the pons.
      - 5. Ataxic hemiparesis
        - Weakness and ataxia of the contralateral limbs, often greater in the leg and foot than in the arm and hand.
        - The most common locations are the base of the pons, posterior limb of the internal capsule and corona radiata.
  - Arterial dissection: ( may lead to ischemic stroke)
    - **a) Carotid dissection:**
      - Typically presents with **severe retro-orbital headache ipsilateral to the lesion**
      - Strokes involve the anterior circulation and occur either by thrombosis of the ICA or more commonly by an **embolus arising from the dissection.**
      - On examination:
        - may have an **ipsilateral Horner's syndrome** — due to involvement of the ascending oculosympathetic tract.
        - Perspiration is preserved because those fibers ascend with the external carotid artery.
    - b) VA dissection
      - may be produced by neck manipulation or **trauma ( neck hyperextension)**
      - commonly associated with **ipsilateral neck pain and stroke in the posterior circulation**
  - Transient Ischemic Attack "mini-stroke"
    - temporary blockage in blood flow to your brain — symptoms usually last for just a few minutes or may go away in 24 hours( <24hrs)
    - 10% risk of stroke in the 90 days following the event, and the greatest risk is within the first 24 hours following a TIA.
    - evaluation should be identical to that for a completed stroke and should be conducted just as quickly.
      - use ABCD$^2$ score to estimate the short-term risk of stroke following a transient ischemic attack within days ( score 0–7)
        - **A-age >60**
        - **B-blood pressure >= 140/90 mmHg**
        - **C- clinical features** ( unilateral weakness →2 points /// Speech disturbance without weakness → 1 point)
        - **D – Duration** (>=60 min →2 points /// 10-59min →1 point)
        - **D- Diabetes mellitus** → 1 point
- Assessment of Ischemic Strokes
  - variant of **BE FAST** called the **ROSIER score** is useful for medical professionals.

  - **exclude hypoglycaemia first**
  - **A non-contrast Brain CT scan**
    - **the first line radiological investigation for suspected stroke**
    - **exclude hemorrhagic strokes** or another pathology such as brain tumors before considering the usage of any antiplatelets or thrombolytics and thrombectomy in acute Stroke Management.
    - acute ischemic stroke won't appear unless after **8-10 hrs** of symptoms

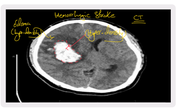


    - Acute ischemic strokes — show areas of low density in the grey and white matter of the territory.
    - Acute hemorrhagic strokes — show areas of hyperdense material (blood) surrounded by low density (oedema).

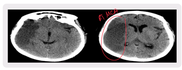

  - **MRI Brain with diffusion weighted imaging is more sensitive to acute brain infarction than is CT.**
- Diagnostic Work up for Ischemic Strokes
  - **1) fingerstick glucose**
  - Laboratory Work Up:
    - Complete blood count, PT, PTT, Kidney function test, liver function test, **Cardiac enzymes**, Electrolytes, RBS level, **HBA1C**, Lipid Profile
    - Rheumatological work up is sometimes needed when history is significant for (Antiphospholipid syndrome, Bechet disease or Vasculitis.)

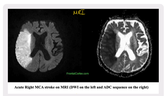


  - imaging:
    - **1- brain CT scan**
    - **2-brain MRA** — if MRI isnt available , use CT perfusion ( if available)
    - **3-neck MRA**

      - another option if cant be done : -Carotid ultrasound: shows buildup of fatty deposits called plaques and blood flow in the carotid arteries.
    - -Echocardiogram — can **find a source of clots in the heart** that may have traveled to the brain and caused a stroke.
    - In cases of suspected arterial dissection — CTA or MRA with fat-suppressed imaging ("fat sats") to evaluate the cervical carotid and vertebral arteries should be obtained.
  - -Intensive investigation for coagulopathy may be required for some patients.
  - If the Q asked for techniques — MRI
    - **1-DW**
    - **2-Flare**
    - **3-ADC**

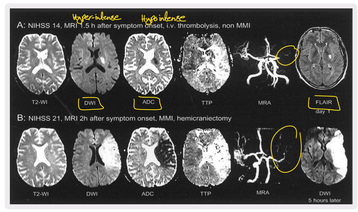


- Management of Ischemic Strokes
  - Blood glucose, hydration, oxygen saturation and temperature — should be maintained within normal limits.
  - Blood pressure should not be lowered in the acute phase unless there are complications such as Hypertensive Encephalopathy. — 200/110
  - **Aspirin 300mg orally or rectally** — give ASAP if the hemorrhagic stroke has been excluded.
  - **- Thrombolysis** with alteplase should only be given if:
    - administered **within 4.5 hours** of onset of stroke symptoms — NOTE: pt with **CT showing acute ischemic stroke** definitely exceeded 8–10 hr of symptoms , **so never give him thrombolytics**
    - Brain hemorrhage has been definitively excluded (imaging has been performed)
    - Patients with acute ischemic stroke otherwise eligible for treatment with thrombolysis should have their **blood pressure reduced to below 185/110 mmHg before treatment.** — we use β-blocker ( labetalol)
    - Absolute Contraindications for thrombolytics:

      - Symptoms suggestive of SAH even if CT scan of brain is normal.
      - - Large or ruptured aneurysm > 10 mm
      - - Use of therapeutic dose of LMWH in the last 24 hours
      - - Associated or suspected aortic arch dissection
      - - CT hypodensity > 1/3 MCA territory
      - - Major surgery in the last 14 days
      - - Moyamoya disease
- Floating Topic
  - Thrombectomy for acute ischemic strokes



- Secondary Prevention of ischemic strokes
  - **carotid artery endarterectomy** — if patient has suffered stroke or TIA in the carotid territory and are not severely disabled. It should only be considered if carotid stenosis.
    - > 70% according ECST (European Carotid Surgery Trialists' Collaborative Group) criteria
    - or > 50% according to NASCET (North American Symptomatic Carotid Endarterectomy Trial) criteria.
  - should be treated with **clopidogrel load in the first 24 hours followed by DAPT for 21 days.** — Patients with high-risk TIA and low NHSS stroke
  - **Statin** should be prescribed for — patients who have high lipid profile
  - **oral anticoagulant** therapy for secondary stroke prevention. — Patients with ischemic stroke or transient ischemic attack and atrial fibrillation should receive
  - **dual antiplatelet therapy with aspirin and clopidogrel is favored** — In patients with stroke due to intracranial atherosclerosis

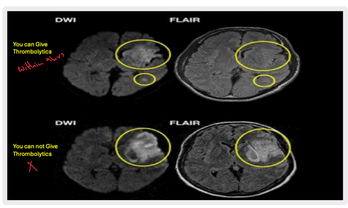


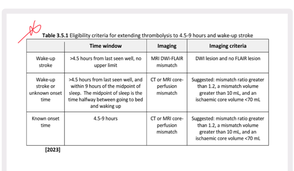

**Table 3.5.1** Eligibility criteria for extending thrombolysis to 4.5-9 hours and wake-up stroke

| | Time window | Imaging | Imaging criteria |
|---|---|---|---|
| Wake-up stroke | >4.5 hours from last seen well, no upper limit | MRI DWI-FLAIR mismatch | DWI lesion and no FLAIR lesion |
| Wake-up stroke or unknown onset time | >4.5 hours from last seen well, and within 9 hours of the midpoint of sleep. The midpoint of sleep is the time halfway between going to bed and waking up | CT or MRI core-perfusion mismatch | Suggested: mismatch ratio greater than 1.2, a mismatch volume greater than 10 mL, and an ischemic core volume <70 mL |
| Known onset time | 4.5-9 hours | CT or MRI core-perfusion mismatch | Suggested: mismatch ratio greater than 1.2, a mismatch volume greater than 10 mL, and an ischemic core volume <70 mL |

[2023]

## VASCULAR ANATOMY

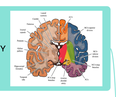

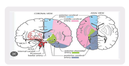

- Ant ( carotid ) circulation (4/5)
  - most (4/5) cerebral hemispheres
  - except: medial temporal lobes and a portion of the occipital lobes
  - origin
    - rt common carotid A — innominate A
    - ECA
    - left CCA — Aorta
    - ICA
      - Same as rt
      - anterior communicating artery connects the two ACAs.
      - ECA
  - ICA ( internal carotid a)
    - ophthalmic A — S shaped curve ( carotid siphone)
    - pentrate the dura and give
      - ant choroidal
      - post communicating arties
    - then it biforcate to
      - anterior cerebral a ( ACA)
        - anterior medial cerebral hemispheres
        - caudate nuclei
        - the basal frontal lobes.
      - middle cerebral a ( MCA)
        - lenticulostriate artery branches — lateral coarse to give — supply basal ganglia and internal capsule
        - trifurcates into
          - small anterior temporal branches
          - large superior
          - inferior divisions

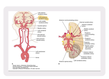

- post ( vertebrobasilar) circulation (1/5)
  - brainstem, thalami, cerebellum and the posterior portion of the cerebral hemispheres
  - origin
    - subclavian A
      - vertebral A (VA)
        - 2 vertebral artries join to form
          - Basilar A (at pontomedullary junction)
            - anterior inferior cerebellar artery ( AICA)
            - superior cerebellar artery ( SCA)
            - terminal branch : rt and left PCA — gives off penetrating arteries to the midbrain and thalamus, courses around the cerebral peduncles and then supplies the occipital lobe and the inferior surface of the temporal lobe.
          - intracranial VA gives off
            - post spinal artery
            - ant spinal artery
            - penetrating arteries to the medulla and the posterior inferior cerebellar artery ( PCA).

## HEMORRHAGIC STROKE

- Definition
  - life-threatening emergency
  - rapidly developing (acute) clinical signs of focal (or global) disturbance of cerebral function
  - symptoms lasting 24 hours or longer or leading to death
  - with no apparent cause other than vascular origin
- Bleeding inside the skull — diffenition
- **subarachnoid (SAH)**
  - causes
    - blood under arterial pressure is suddenly released into the space around the brain
    - often due to traumatic injury
    - More serious, though, is **SAH caused by bleeding from an aneurysm located along the circle of Willis ( forming web shape )**

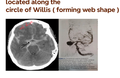

  - presentation
    - sudden-onset, severe headache.
    - Often ,they vomit and cease what they are doing at the time of the hemorrhage.
    - When the intracranial pressure increases rapidly or the insulae are affected — coma or death may ensue
  - Tx
    - aimed at preventing the rebleeding and vasoconstriction that often follow SAH.
    - Aneurysms can be clipped surgically or " coiled" by interventional techniques.
    - **The calcium-channel blocker nimodipine** — **used only in SAH !!!** — minimize vasoconstriction and delayed brain ischemia.
- **intracerebral(ICH)**



  - bleeding directly into brain parenchyma.
  - earliest symptoms are headache and neurologic signs referable to the region in which the bleeding occurs.
  - The most common locations — the basal ganglia– internal capsule, caudate nucleus, thalamus, pons and cerebellum .
  - Causes
    - **Hypertension (leading to Charcot-Bouchard microaneurysms) is the most common cause of ICH.**
    - Cerebral amyloid angiopathy is a cause of ICH that is **more frequent in the elderly** and preferentially affects the **parietal and occipital** lobes.
    - Trauma, vascular malformations and bleeding diathesis ( especially with **patients who are taking anticoagulants**) are other common causes.
    - Vascular malformations:
      - congenital and acquired vascular anomalies that have the potential to bleed, either within the brain ( ICH) or around it
      - Arteriovenous malformations ( AVMs) contain arteries that empty into arterialized veins.
      - these lesions contain no recognizable normal capillary bed, but abnormal gliotic parenchyma can be found between the component vessels.
      - **AVMs may result in seizures**
      - may be treated with embolization or surgical resection

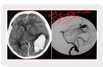

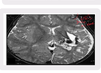

  - Tx
    - devastating condition , and large hemorrhages are associated with high mortality rates.
    - **decrease systolic Bp to ( 130-150)** — we use β-blocker ( labetalol)
    - correcting any coagulopathy
    - **in cerebellar hemorrhages** — **surgical decompression is necessary**
    - Management of risk factors for hemorrhage specifically hypertension, is necessary to prevent recurrence
- types



- almost always traumatic
  - **epidural**
  - **subdural**

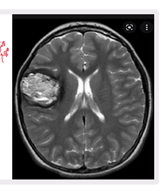

**Cavernous angiomas:** consist of a relatively compact mass **of sinusoidal vessels close together**, without intervening brain parenchyma.

The lesions are well **encapsulated.**

Cavernous angiomas bleed or lead to seizures, occasionally, but are not threatening as AVMs are.

They may be followed with serial neuroimaging studies.

**Surgery is required rarely.**

They may require **antiseizure drug treatment if recurrent seizures develop.**

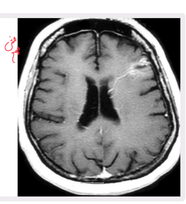

**Developmental venous anomalies (DVAs):** are composed of anomalous veins usually separated by morphologically normal brain parenchyma are the most common vascular malformations of the brain.

They seldom hemorrhage and are generally not treated surgically or followed with serial neuroimaging studies.

Telangiectasias are dilated capillaries with intervening brain parenchyma.

**They are incidental findings and do not require treatment.**



Presented with xmind